



The  
University  
Of  
Sheffield.

# **The use of small bowel capsule endoscopy in patients with coeliac disease and serology negative villous atrophy**

**Dr Stefania Chetcuti Zammit MD, MRCP(UK), MSc**

Academic Department of Gastroenterology and Hepatology,  
Royal Hallamshire Hospital,  
Sheffield Teaching Hospitals NHS Foundation Trust, United Kingdom

**Supervisors:** Professor Reena Sidhu, Professor David S Sanders and Dr  
Matthew Kurien

This is a hybrid thesis submitted in line with university and departmental regulations.

## **Statement of Probity**

I confirm that I shall abide by the University of Sheffield's regulations on plagiarism and that all written work shall be my own and will not have been PLAGIARISED from other paper-based or electronic sources. Where used, material gathered from other sources will be clearly cited in the text.

Name (Print): Dr. Stefania Chetcuti Zammit

Date: 15/03/2020

## **Acknowledgements**

I wish to thank my supervisors Professor Sidhu, Professor Sanders and Dr Kurien for their invaluable support and constructive feedback throughout my research. I am most grateful to Professor Sidhu for her patience, continuous encouragement and immense knowledge. Professor Sanders' guidance and objective critique has helped me look at my research from different perspectives and deliver in my research.

I am indebted to my colleagues within the gastroenterology department at Sheffield Teaching Hospitals who have made the last few years more than just a research experience and to researchers from other centres who collaborated with me in my studies.

I would also like to thank my family, who have always encouraged me during my research and supported my decisions throughout my career.



## TABLE OF CONTENTS

ACKNOWLEDGEMENTS .....	2
ABSTRACT .....	8
PUBLICATIONS ARISING FROM THESIS .....	11
LIST OF TABLES:.....	14
LIST OF FIGURES:.....	16
ABBREVIATIONS: .....	18
CHAPTER 1 - INTRODUCTION.....	19
<b>1.1 Background</b> .....	<b>19</b>
1.1.1 Coeliac disease .....	19
1.1.2 Small bowel capsule endoscopy .....	22
<b>1.2 Macroscopic features of coeliac disease</b> .....	<b>25</b>
<b>1.3 Sensitivity and specificity of small bowel capsule endoscopy</b> .....	<b>27</b>
<b>1.4 Comparison of coeliac disease findings to symptomatology</b> .....	<b>31</b>
<b>1.5 Correlation of SBCE findings to coeliac serology</b> .....	<b>31</b>
<b>1.6 Interobserver agreement of coeliac disease findings</b> .....	<b>32</b>
<b>1.7 Small bowel transit in patients with coeliac disease</b> .....	<b>33</b>
<b>1.8 Repeat small bowel capsule endoscopy in coeliac disease</b> .....	<b>34</b>
<b>1.9 Small bowel capsule endoscopy in refractory coeliac disease</b> .....	<b>35</b>
<b>1.10 Small bowel capsule endoscopy in equivocal coeliac disease</b> .....	<b>38</b>
1.10.1 Positive coeliac serology and negative histology .....	38
1.10.2 Seronegative villous atrophy.....	38
<b>1.11 Conclusions</b> .....	<b>40</b>
CHAPTER 2 – FRAMEWORK OF THESIS.....	41
<b>2.1 Null Hypothesis</b> .....	<b>41</b>
<b>2.2 Aims</b> .....	<b>41</b>
<b>2.3 General Methodology</b> .....	<b>43</b>
2.3.1 Patient population and expert reviewers.....	43
2.3.2 Duodenal histology .....	43
2.3.3 Small bowel capsule endoscopy .....	43
2.3.4 Design of studies .....	44

<b>2.4</b>	<b>Statistical analysis.....</b>	<b>45</b>
<b>2.5</b>	<b>Ethical considerations .....</b>	<b>46</b>

**CHAPTER 3– ASSESSMENT OF DISEASE SEVERITY & INTEROBSERVER AGREEMENT ON CAPSULE ENDOSCOPY IN PATIENTS WITH SMALL BOWEL VILLOUS ATROPHY..47**

<b>3.1</b>	<b>Abstract .....</b>	<b>47</b>
3.1.1	Introduction .....	47
3.1.2	Methodology .....	47
3.1.3	Results .....	47
3.1.4	Conclusion .....	47
<b>3.2</b>	<b>Introduction .....</b>	<b>48</b>
<b>3.3</b>	<b>Methodology .....</b>	<b>51</b>
3.3.1	Study design and patients.....	51
3.3.2	Duodenal histology .....	52
3.3.3	Small bowel capsule endoscopy .....	52
3.3.4	Ethical considerations .....	53
3.3.5	Statistical analysis .....	53
3.3.6	Sample size calculation.....	54
3.3.7	Establishing the coeliac disease score .....	55
<b>3.4</b>	<b>Results .....</b>	<b>55</b>
3.4.1	Characterization of the study population .....	55
3.4.2	Interobserver agreement.....	57
3.4.3	Correlation of extent of disease.....	60
3.4.4	Correlation of features of coeliac disease with extent of disease .....	61
3.4.5	Establishing the coeliac disease score .....	63
3.4.6	Overall scores.....	65
<b>3.5</b>	<b>Discussion .....</b>	<b>65</b>
<b>3.6</b>	<b>Conclusions.....</b>	<b>70</b>

**CHAPTER 4 – THE USE OF FLEXIBLE SPECTRAL IMAGING COLOUR ENHANCEMENT (FICE) IN COELIAC DISEASE ..... 71**

<b>4.1</b>	<b>Abstract .....</b>	<b>71</b>
4.1.1	Objectives .....	71
4.1.2	Methods.....	71
4.1.3	Results .....	71
4.1.4	Conclusions .....	71
<b>4.2</b>	<b>Introduction.....</b>	<b>71</b>
<b>4.3</b>	<b>Methods .....</b>	<b>73</b>
4.3.1	Patients and methods .....	73
4.3.2	Ethical approval .....	78
4.3.3	Statistical analysis .....	78
<b>4.4</b>	<b>Results .....</b>	<b>79</b>
<b>4.5</b>	<b>Discussion .....</b>	<b>81</b>
<b>4.6</b>	<b>Conclusions .....</b>	<b>84</b>

**CHAPTER 5 - SMALL BOWEL CAPSULE ENDOSCOPY IN PATIENTS WITH NEWLY DIAGNOSED COELIAC DISEASE..... 86**

<b>5.1</b>	<b>Abstract .....</b>	<b>86</b>
5.1.1	Background.....	86
5.1.2	Methods.....	86
5.1.3	Results .....	86
5.1.4	Conclusions .....	87
<b>5.2</b>	<b>Introduction.....</b>	<b>87</b>
<b>5.3</b>	<b>Methodology .....</b>	<b>88</b>
5.3.1	Study design and patients .....	88
5.3.2	Coeliac serology .....	88
5.3.3	Duodenal histology.....	89
5.3.4	Small bowel capsule endoscopy .....	89
5.3.5	Statistical analysis .....	91
5.3.6	Ethical considerations .....	91
<b>5.4</b>	<b>Results .....</b>	<b>91</b>
5.4.1	Correlation with age at small bowel capsule endoscopy .....	96
5.4.2	Differences related to gender .....	96
5.4.3	Correlation with signs and symptoms at presentation .....	97
5.4.4	Association with serology.....	99
5.4.5	Association with HLA status .....	101
5.4.6	Association with Marsh Classification on histology.....	101
5.4.7	Multivariate regression analysis .....	101
<b>5.5</b>	<b>Discussion .....</b>	<b>102</b>
<b>5.6</b>	<b>Conclusions.....</b>	<b>105</b>

**CHAPTER 6 – THE ROLE OF SMALL BOWEL CAPSULE ENDOSCOPY IN PATIENTS WITH ESTABLISHED COELIAC DISEASE WHEN COMPARED TO CONTROLS..... 106**

<b>6.1</b>	<b>Abstract .....</b>	<b>106</b>
6.1.1	Introduction .....	106
6.1.2	Methods .....	106
6.1.3	Results .....	106
6.1.4	Conclusions .....	107
<b>6.2</b>	<b>Introduction.....</b>	<b>107</b>
<b>6.3</b>	<b>Methodology .....</b>	<b>109</b>
6.3.1	Study design and patients.....	109
6.3.2	Duodenal histology .....	110
6.3.3	Small bowel capsule endoscopy .....	110
6.3.4	Statistical analysis .....	111
6.3.5	Ethical considerations .....	111
<b>6.4</b>	<b>Results .....</b>	<b>112</b>
6.4.1	Findings on small bowel capsule endoscopy .....	114
6.4.2	Small bowel transit .....	124
<b>6.5</b>	<b>Discussion .....</b>	<b>125</b>
<b>6.6</b>	<b>Conclusions.....</b>	<b>129</b>

**CHAPTER 7 – THE USE OF SMALL BOWEL CAPSULE ENDOSCOPY IN EQUIVOCAL CASES OF VILLOUS ATROPHY AND RAISED INTRAEPITHELIAL LYMPHOCYTES ..... 130**

<b>7.1</b>	<b>Abstract .....</b>	<b>130</b>
7.1.1	Introduction .....	130
7.1.2	Methods.....	130
7.1.3	Results .....	130
7.1.4	Conclusions .....	131
<b>7.2</b>	<b>Introduction.....</b>	<b>131</b>
<b>7.3.</b>	<b>Methodology.....</b>	<b>132</b>
7.3.1	Study design and participants .....	132
7.3.2	Duodenal histology .....	133
7.3.3	Coeliac serology .....	133
7.3.4	Criteria for diagnosis of seronegative villous atrophy .....	134
7.3.5	Small bowel capsule endoscopy .....	137
7.3.6	Statistical analysis .....	137
7.3.7	Ethical considerations .....	137
<b>7.4</b>	<b>Results .....</b>	<b>138</b>
7.4.1	Group 1 (seronegative villous atrophy- unknown) .....	139
7.4.2	Group 2 (seronegative villous atrophy – coeliac disease).....	140
7.4.3	Group 3 (identifiable cause).....	140
7.4.4	Group 4 (raised intraepithelial lymphocytes+/- crypt hyperplasia).....	142
7.4.5	Comparison of groups.....	145
<b>7.5</b>	<b>Discussion .....</b>	<b>155</b>
<b>7.6</b>	<b>Conclusion .....</b>	<b>157</b>

**CHAPTER 8 – SMALL BOWEL CAPSULE ENDOSCOPY IN PATIENTS WITH REFRACTORY COELIAC DISEASE ..... 159**

<b>8.1</b>	<b>Abstract .....</b>	<b>159</b>
8.1.1	Background.....	159
8.1.2	Materials and methods.....	159
8.1.3	Results .....	159
8.1.4	Conclusions .....	159
<b>8.2</b>	<b>Introduction.....</b>	<b>160</b>
<b>8.3</b>	<b>Methodology .....</b>	<b>162</b>
8.3.1	Study design and patients.....	162
8.3.2	Duodenal histology .....	162
8.3.3	Small bowel capsule endoscopy .....	162
8.3.4	Statistical analysis .....	165
8.3.5	Ethical considerations .....	165
<b>8.4</b>	<b>Results .....</b>	<b>165</b>
8.4.1	Comparison of patients with refractory coeliac disease and uncomplicated coeliac disease.....	165
8.4.2	Patients with refractory coeliac disease.....	169
<b>8.5</b>	<b>Discussion .....</b>	<b>173</b>
<b>8.6</b>	<b>Conclusions.....</b>	<b>176</b>

CHAPTER 9: SUMMARY OF KEY FINDINGS, RECOMMENDATIONS FOR FUTURE RESEARCH AND CONCLUSIONS.....	178
9.1 Outputs from this thesis: .....	186
CHAPTER 10 SUPPLEMENTARY MATERIAL .....	188
10.1 Permission to reuse figure 1 (Introduction).....	188
10.2 Permission to reuse articles from co-authors.....	195
10.3 Permission to reuse published articles from journals.....	217
10.4 Coeliac disease proforma .....	224
10.5 Flexible spectral imaging colour enhancement study proforma .....	226
10.6 Ethics – approval letter .....	248
CHAPTER 11 BIBLIOGRAPHY .....	250

## Abstract

The gold standard to diagnose coeliac disease (CD) is through histology obtained from the duodenum. However, diagnosing CD on histology has its limitations. Not all patients with suspected CD are willing to undergo gastroduodenoscopy for a confirmative diagnosis. An adequate number of biopsies that are properly prepared prior to histological assessment is required for a confirmative diagnosis. In suspected CD, small bowel capsule endoscopy (SBCE) has a sensitivity of 70% to 93% compared to duodenal histology (El-Matary et al, 2009; Hopper et al, 2007; Lujan-Sanchis et al, 2017; Murray et al, 2008; Petroniene et al, 2005; Rokkas & Niv, 2012; Rondonotti et al, 2007). SBCE can help identify macroscopic features of CD along the entire length of the small bowel (SB), thus having a complementary role to a histological diagnosis.

The reporting of CD features on SBCE can be subjective. The interobserver agreement (IOA) of features CD between expert reviewers was studied in chapter 3. This was a prospective cohort study that included de-identified SBCEs of 300 patients (78 CD (26%), 18 serology negative villous atrophy (SNVA) (6%) and 204 controls with normal duodenal histology (68%)). The aim was to compare IOA of features of CD between reviewers and formulate an objective and reproducible method of measuring extent and severity of CD in the SB. Agreement between reviewers for extent of affected SB mucosa was high (0.97). The median overall scores for patients increased significantly according to the independent classification of severity by the capsule reviewers: mild (34, 0-254), moderate (50, 27-133), severe (96, 69-128) ( $p=0.0001$ ).

Features of CD in the SB can be heterogenous and vary in extent. When these features are mild, their delineation can present a challenge to reviewers, especially to the novice SBCE reviewer. The role of Flexible Spectral Imaging Colour Enhancement (FICE) in the delineation of CD features was studied in chapter 4. This was a European, multicentre study that included 5 expert capsule reviewers who evaluated images from SBCEs of patients with CD to determine whether the use of FICE and blue light can improve the detection of CD-related changes. Sensitivity and specificity of conventional white light was the best in the delineation of CD related changes. There was a low agreement (Fleiss Kappa

0.107;  $p=0.147$ ) between expert reviewers in selecting the best image modification to detect CD-related changes confirming that FICE and blue light are not superior to conventional white light in the delineation of changes related to CD on SBCEs.

The utility of SBCE was assessed in 60 patients with newly diagnosed coeliac disease (CD) (Chapter 5; prospective cohort study). The aim was to study the association between clinical symptoms, duodenal histology and CD serology with extent of disease on SBCE in a group of patients with newly diagnosed CD. Red flag signs such as weight loss ( $p=0.027$ ) and iron deficiency anaemia ( $p=0.026$ ) and age at the time of diagnosis ( $p=0.025$ ) correlated with more extensive SB involvement. Patients presenting with iron deficiency anaemia ( $p=0.038$ ), weight loss ( $p=0.009$ ) and with a low serum albumin at presentation ( $p=0.007$ ) were significantly older at diagnosis.

The usefulness of SBCE in patients with established CD was also studied. Chapter 6 is a prospective case control study on 100 patients with established CD on a gluten free diet (GFD) and 200 control patients. The aim was to assess the relationship between symptoms, CD serology and Marsh classification of disease and extent of disease on SBCE in patients with established CD. Albumin ( $p=0.036$ ) and Marsh score of histology (D1) ( $p=0.019$ ), vitamin B12 ( $p=0.001$ ) and folate levels ( $p=0.008$ ) correlated with extent of CD changes in the SB.

The role of SBCE was assessed in a study of 177 patients with seronegative villous atrophy (SNVA) and intraepithelial lymphocytes (IELs) +/-crypt hyperplasia on duodenal histology (chapter 7). These patients all had an equivocal diagnosis of CD. The aim was to assess the role of SBCE in patients with different causes for SNVA and Marsh 1 and 2 histology. Patients with SNVA of an unknown cause with persistent villous atrophy ( $p=0.0001$ ) and those with SNVA secondary to underlying CD who eventually developed complications ( $p=0.022$ ) were more likely to have a positive SBCE at diagnosis. More extensive SB disease on SBCE correlated with a higher SNVA-related mortality unlike severity of histology which did not correlate with mortality ( $p=0.793$ ).

Literature on the follow-up of patients with refractory coeliac disease (RCD) is lacking. The role of SBCE in the follow up of patients with RCD was studied in chapter 8. This was a prospective case control study that included 23 patients with RCD and another group of 48 patients with non-complicated CD. The extent of SB disease ( $42.4\pm 34.1\%$  vs  $9.7\pm 21.7\%$ ,  $p=0.0001$ ) was significantly greater in patients with RCD when compared to patients with uncomplicated CD. There was also an improvement in the extent of SB disease ( $42.4\pm 34.1\%$  vs  $26.4\pm 28.9\%$   $p=0.012$ ) when SBCE was repeated following treatment with immunosuppressants +/- steroids in patients with RCD.

In conclusion, macroscopic features of CD are useful in delineating active disease. A score to quantify these features can be used to measure severity of disease. SBCE is beneficial in newly diagnosed patients with CD and red flag signs. Patients with underlying CD who are suspected of having persistent disease are more likely to have extensive disease when markers of malabsorption are low. SBCE is useful in the follow up of patients with RCD to monitor disease extent following initiation of treatment. SBCE can be used in those with equivocal disease to predict the course of disease. Chromoendoscopy in SBCE is not beneficial in improving the delineating of CD-related features.



## **Publications arising from thesis**

The work presented in several chapters of this thesis is already published. Therefore some chapters reproduce part or all of these publications with, in some cases, minor additions, explanatory notes or references. Permission to include the publications in this fashion has been sought and approved by all named co-authors and journals. Summarised below are my independent contributions to each thesis chapter and relevant articles.

### **Chapter 1:**

- a) Chetcuti Zammit S, Sanders DS, Sidhu R. A comprehensive review on the utility of capsule endoscopy in coeliac disease: From computational analysis to the bedside. *Comput Biol Med.* 2018 Nov 1;102:300-314. doi: 10.1016/j.compbimed.2018.06.025. Epub 2018 Jun 28. Review.
- b) Chetcuti Zammit S, Sanders DS, Sidhu R. Capsule endoscopy for patients with coeliac disease. *Expert Rev Gastroenterol Hepatol.* 2018 Aug;12(8):779-790. doi: 10.1080/17474124.2018.1487289. Epub 2018 Jun 19. Review.
- c) Chetcuti Zammit S, Sanders DS, Sidhu R. Refractory coeliac disease: what should we be doing different? *Curr Opin Gastroenterol.* 2020 Feb , 36:000–000. DOI:10.1097/MOG.0000000000000628. Review. [Epub ahead of print]

**Chapter 3:** This chapter has been submitted for consideration of publication. Together with guidance from Professor Sidhu, I designed this study.

I sought approval from the Sheffield Research Ethics Committee and the Health Research Authority for the project. I analysed de-identified SBCEs, independently collected data, analysed and interpreted the data and wrote the chapter and article.

**Chapter 4:** Chetcuti Zammit S, McAlindon ME, Ellul P, Rondonotti E, Carretero C, Sanders DS, Sidhu R. Improving Diagnostic Yield of Capsule Endoscopy in Coeliac Disease: Can Flexible Spectral Imaging Colour Enhancement Play a Role? *Digestion.* 2019 Aug 13:1-8. doi: 10.1159/000500906. [Epub ahead of print]

I sought approval from the Sheffield Research Ethics Committee and the Health Research Authority for the project. I contributed to the design of the study, independently collected, analysed and interpreted the data and wrote the chapter and article.

I independently wrote this chapter and articles with guidance from Professor Sidhu and Professor Sanders on the key topics to address in each review.

**Chapter 5:** Chetcuti Zammit S, Sanders DS, Sidhu R. Coeliac disease: older patients have the most extensive small bowel involvement on capsule endoscopy. *Eur J Gastroenterol Hepatol*. 2019 Dec;31(12):1496-1501. doi: 10.1097/MEG.0000000000001503.

I sought approval from the Sheffield Research Ethics Committee and the Health Research Authority for the project. I contributed to the design of the study, independently collected, analysed and interpreted the data and wrote the chapter and article.

**Chapter 6:** Chetcuti Zammit S, Kurien M, Sanders DS, Sidhu R. What is the role of small bowel capsule endoscopy in established coeliac disease? *Clin Res Hepatol Gastroenterol*. 2020 Jan 9. pii: S2210-7401(19)30265-7. doi: 10.1016/j.clinre.2019.11.011. [Epub ahead of print] I sought approval from the Sheffield Research Ethics Committee and the Health Research Authority for the project.

I contributed to the design of the study, independently collected, analysed and interpreted the data and wrote the chapter and article.

**Chapter 7:** Chetcuti Zammit S, Schieppatti A, Aziz I, Kurien M, Sanders DS, Sidhu R. The use of small-bowel capsule endoscopy in cases of equivocal celiac disease. *Gastrointest Endosc*. 2020 Jan 7. pii: S0016-5107(20)30005-5. doi: 10.1016/j.gie.2019.12.044. [Epub ahead of print]

I sought approval from the Sheffield Research Ethics Committee and the Health Research Authority for the project. I contributed to the design of the study,

collected the data together with A Schiepatti, I Aziz, and M Kurien, independently analysed and interpreted the data and wrote the chapter and article.

**Chapter 8:** Chetcuti Zammit S, Sanders DS, Cross SS, Sidhu R. Capsule endoscopy in the management of refractory coeliac disease. *J Gastrointestin Liver Dis.* 2019 Mar;28(1):15-22. doi: 10.15403/jgld.2014.1121.281.cel..

I sought approval from the Sheffield Research Ethics Committee and the Health Research Authority for the project. I contributed to the design of the study, independently collected, analysed and interpreted the data and wrote the chapter and article.

## List of tables:

Table 1: Marsh classification of histological changes in coeliac disease; .....	22
Table 2: Sensitivity, specificity, positive and negative predictive value of SBCE in patients with CD or suspected CD .....	29
Table 3: Features of CD on SBCE.....	57
Table 4: Correlation analysis of different CD features between the 2 reviewers.....	58
Table 5: Percentage of affected small bowel mucosa vs overall severity of disease.....	60
Table 6: Correlation between extent of affected small bowel mucosa and Marsh classification of disease.....	60
Table 7: Univariate analysis of features of CD against extent of affected small bowel mucosa.....	62
Table 8: The coeliac disease score .....	64
Table 9: Studies on interobserver agreement between duodenal histology and CD findings on SBCE and between different reviewers of SBCE .....	69
Table 10: Reviewer sensitivities and specificities, mean sensitivity and specificity for normal light, FICE and blue light.....	79
Table 11: Favoured modality of normal light or different FICE settings by all the 5 reviewers.....	80
Table 12: Fleiss' Kappa co-efficient for normal light and FICE settings .....	81
Table 13: Signs and symptoms of patients at presentation .....	92
Table 14: Serology results at the time of diagnosis.....	94
Table 15: Marsh classification of disease .....	94
Table 16: Gastric and small bowel passage time and percentage of abnormal small bowel mucosa.....	95
Table 17: Features of coeliac disease on small bowel capsule endoscopy .....	95
Table 18: Age at diagnosis according to HLA status.....	96
Table 19: Significance of small bowel capsule endoscopy parameters according to mode of presentation; .....	98
Table 20: Correlation of small bowel capsule endoscopy parameters with serology at diagnosis .....	100

<b>Table 21: Multivariate regression analysis of signs, symptoms, serology and histology and extent of disease.....</b>	<b>102</b>
<b>Table 22: Sensitivity, Specificity, positive and negative predictive value of small bowel capsule endoscopy in patients with suspected, newly diagnosed and established coeliac disease .....</b>	<b>108</b>
<b>Table 23: Signs and symptoms at SBCE in patients with coeliac disease and in controls at the time of SBCE.....</b>	<b>114</b>
<b>Table 24: Features of coeliac disease in the proximal, mid and distal small bowel on SBCE.....</b>	<b>117</b>
<b>Table 25: Correlation of factors with positive / negative small bowel capsule endoscopy .....</b>	<b>119</b>
<b>Table 26: Correlation of factors with percentage of affected small bowel mucosa .....</b>	<b>122</b>
<b>Table 27: Overall severity of affected small bowel mucosa as graded by the expert reviewers.....</b>	<b>123</b>
<b>Table 28: Features on capsule endoscopy in patients with raised IELs +/- crypt hyperplasia and SNVA.....</b>	<b>138</b>
<b>Table 29: Causes for SNVA in group 3 .....</b>	<b>142</b>
<b>Table 30: Causes of raised intraepithelial lymphocytes +/- crypt hyperplasia in group 4</b>	<b>145</b>
<b>Table 31: HLA status in patients with SNVA (p=0.0001) .....</b>	<b>146</b>
<b>Table 32: Ethnicity across different groups (p=0.001).....</b>	<b>147</b>
<b>Table 33: Ethnicity across different groups (p=0.002).....</b>	<b>148</b>
<b>Table 34: Positive SBCE / diagnostic yield and extent of disease on SBCE .....</b>	<b>150</b>
<b>Table 35: Features of all patients on SBCE .....</b>	<b>151</b>
<b>Table 36: Marsh classification of histology in both groups of patients .....</b>	<b>166</b>
<b>Table 37: Differences on capsule endoscopy in both groups.....</b>	<b>168</b>
<b>Table 38: Characteristics of patients with refractory coeliac disease .....</b>	<b>171</b>
<b>Table 39: Comparison of features on first and repeat SCBE in patients with refractory coeliac disease .....</b>	<b>173</b>
<b>Table 40: Summary of studies, important points and future studies to be considered. ...</b>	<b>183</b>

## List of figures:

Figure 1: Underlying mechanisms in coeliac disease pathogenesis.....	20
Figure 2: (a) Capsocam with 4 cameras provides 360° view; (b) Pillcam provides 156° view of the small bowel;.....	23
Figure 3: Comparison of small bowel pathologies on axial and panoramic SBCE: (a) aphthous ulcers, (b) fresh blood, (c) angioectasias, (d) diverticulum.....	23
Figure 4: Fissuring of mucosa on small bowel capsule endoscopy in a patient with coeliac disease. ....	25
Figure 5: Mosaic pattern of mucosa on small bowel capsule endoscopy in a patient with coeliac disease. ....	26
Figure 6: Scalloping of mucosal folds on small bowel capsule endoscopy in a patient with coeliac disease.....	26
Figure 7: Normal small bowel mucosa on small bowel capsule endoscopy.....	27
Figure 8: Enteropathy-associated T-cell lymphoma in a patient with coeliac disease.....	36
Figure 9: Ulcerative jejunoileitis on small bowel capsule endoscopy in a patient with coeliac disease. ....	37
Figure 10: Villous atrophy and scalloping on SBCE in a patient with coeliac disease .....	48
Figure 11: Mosaic pattern of mucosa on SBCE in a patient with coeliac disease.....	49
Figure 12: Nodularity of small bowel mucosa in a patient with coeliac disease .....	49
Figure 13: Fissuring of folds on SBCE in a patient with coeliac disease .....	50
Figure 14: Small bowel ulcers in a patient with coeliac disease .....	51
Figure 15: Bland-Altman plot indicating interobserver agreement for percentage extent of disease between reviewers 1 and 2 .....	59
Figure 16: Scores of patients for reviewers 1 and 2 combined according to the overall severity of disease .....	65
Figure 17: Images on small bowel capsule endoscopy modified by FICE ((b), (c), (d), (f), (h) show features of coeliac disease, (a), (e), (g), (i), (j) are normal images;) .....	75
Figure 18: Fissuring of mucosa in a patient with coeliac disease on small bowel capsule endoscopy: (a) conventional white light; (b) FICE 1; (c) FICE 2; (d) FICE 3; (e) blue light.....	77

<b>Figure 19: Features of coeliac disease on small bowel capsule endoscopy .....</b>	<b>90</b>
<b>Figure 20: Algorithm for the diagnosis and management of patients with seronegative villous atrophy or having duodenal histology of Marsh 1 and 2 .....</b>	<b>136</b>
<b>Figure 21: Mortality in group 1 (SNVA-UO) and 2 (SNVA-CD) from CD-related causes....</b>	<b>153</b>
<b>Figure 22: Mortality in group 1 (SNVA-UO) and 2 (SNVA-CD) patients from CD-related causes according to severity of duodenal histology.....</b>	<b>154</b>
<b>Figure 23: Scalloping of mucosa in a patient with uncomplicated coeliac disease.....</b>	<b>163</b>
<b>Figure 24: Fissuring and scalloping of mucosa in a patient with type I refractory coeliac disease. ....</b>	<b>164</b>
<b>Figure 25: Mucosal ulceration in a patient with refractory coeliac disease type II. ....</b>	<b>164</b>

**Abbreviations:**

Coeliac disease (CD)

Human leukocyte antigen (HLA)

Tissue transglutaminase (TTG)

Refractory coeliac disease (RCD)

Small bowel capsule endoscopy (SBCE)

Small bowel (SB)

European Society of Gastrointestinal Endoscopy (ESGE)

Gluten free diet (GFD)

Endomysial antibody (EMA)

Interobserver agreement (IOA)

Intraepithelial lymphocytes (IELs)

Enteropathy-associated T-cell lymphoma (EATL)

Seronegative coeliac disease (SCD)

Seronegative non-coeliac disease (S-non-CD)

Non-steroidal anti-inflammatory drugs (NSAIDs)

British Society of Gastroenterology (BSG)

American College of Gastroenterology (ACG)

Flexible Spectral Imaging Colour Enhancement (FICE)

Bone mineral density (BMD)

Villous atrophy (VA)

Duodenal bulb (D1)

Second part of the duodenum (D2)

Small bowel transit (SBT)

Small intestinal bacterial overgrowth (SIBO)

Seronegative villous atrophy (SNVA)

Seronegative villous atrophy of unknown cause (SNVA-UO)

Seronegative villous atrophy secondary to coeliac disease (SNVA-CD)

Partial villous atrophy (PVA)

Subtotal villous atrophy (SVA)

Total villous atrophy (TVA)

Odds ratio (OR)



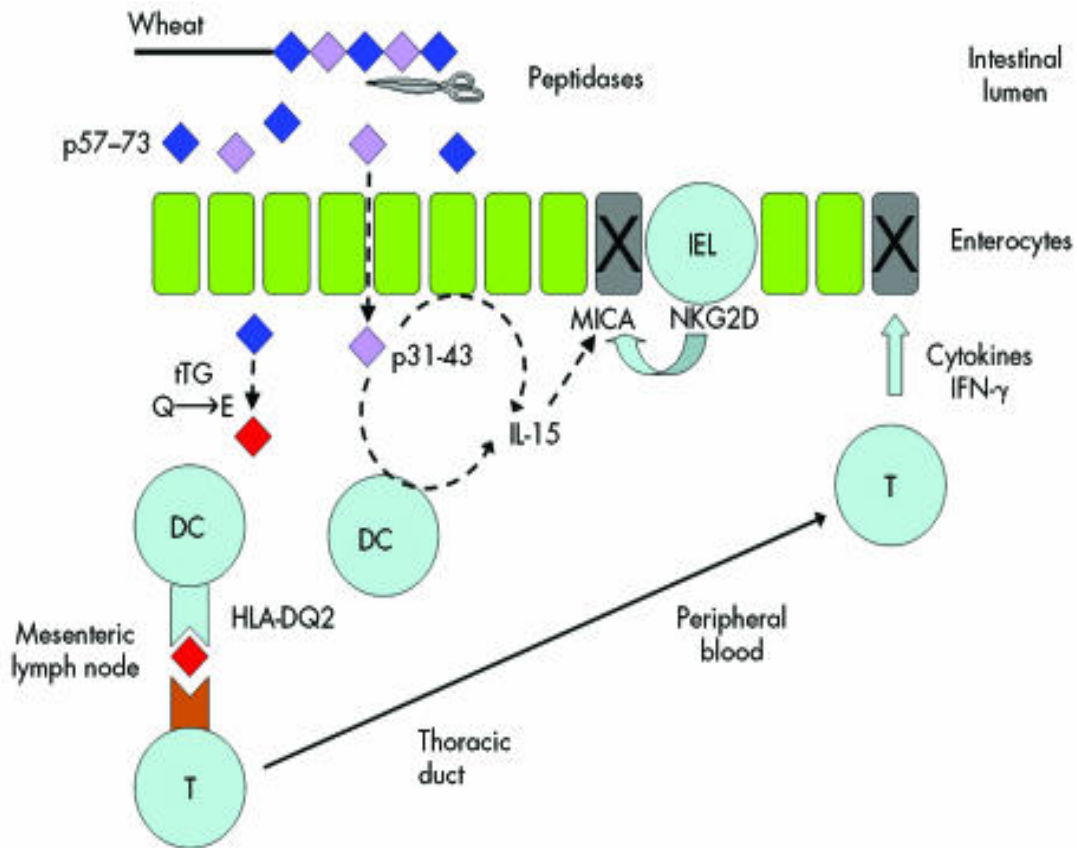
## Chapter 1 - Introduction

### 1.1 Background

#### 1.1.1 Coeliac disease

CD is defined as a chronic small intestinal immune-mediated enteropathy precipitated by exposure to dietary gluten in genetically predisposed individuals (Ludvigsson et al, 2013). CD has a prevalence rate of up to 10% among first degree relatives of CD patients (Ellis, 1981; Hogberg et al, 2003) Susceptibility to developing CD has been linked to a gene region on the short arm of chromosome 6 (Bahram et al, 1999; Mearin et al, 1983) that codes for 2 peptide-presenting DQ molecules: DQ2 and to a lesser extent DQ8. The presence of human leukocyte antigen (HLA)-DQ2 and DQ8 in patients with CD can be as high as 96.2% (Basturk et al, 2017; Karell et al, 2003; Selleski et al, 2018). T cells of patients with CD that are DQ2 or DQ8 positive have been shown to recognise gluten fragments presented by the respective HLA-DQ2 or DQ8 molecules (Lundin et al, 1994; Lundin et al, 1993). This in turn leads to rapid activation of the T cells in the lamina propria of CD patients (Halstensen et al, 1993). It is not known what initiates this T cell response and the intolerance to gluten. Gluten might have innate properties or alternatively infections may play a role (Jabri & Sollid, 2009).

Tissue transglutaminase (TTG) plays a role in the catalysis of deamidation of gliadin (Molberg et al, 1998; van de Wal et al, 1998). TTG-specific B cells may selectively bind and internalise gliadin-TTG complexes via specific surface immunoglobulins. The gliadin fragment then gets processed and presented by DQ2 or DQ8 to gliadin-specific T cells, thus providing help for B cell maturation, isotype switching and antibody secretion. This can explain why TTG antibody levels in CD patients correlate with gliadin in the diet because when gliadin is removed, this will also stop the T cell help needed for antibody production (Figure 1).



**Figure 1:** Underlying mechanisms in coeliac disease pathogenesis.

Wheat gluten is partially digested but key toxic sequences are resistant to intestinal proteases. One gluten peptide (p31-43/49) may directly induce interleukin 15 (IL-15) production from enterocytes and dendritic cells but precise details remain unclear. IL-15 upregulates MICA, a stress molecule on enterocytes. Another gluten peptide (p57-73) is deamidated by tissue transglutaminase and is presented to T cells by HLA-DQ2 on antigen presenting cells. The initial triggering event occurs in the mesenteric lymph nodes but the importance of presentation in the mucosa is uncertain. Epithelial cytotoxicity occurs via at least two mechanisms: cytokine release (especially interferon  $\gamma$  (IFN- $\gamma$ )) by antigen specific T cells and directly by intraepithelial lymphocytes via MICA-NKG2D interaction (van Heel & West, 2006). (see supplementary material section, permission to reuse figure 1)

Activation of T cells has been shown to induce villous atrophy (VA) and crypt hyperplasia in the gut (Lionetti et al, 1993). This in turn forms the basis for the histological Marsh classification of CD (Oberhuber et al, 1999). Extracellular matrix receptors help enterocytes adhere to the basement membrane. Evidence

for extracellular matrix degeneration in CD exists (Daum et al, 1999). This degeneration is likely to be secondary to increased metalloproteinases (Ciccocioppo et al, 2005) produced by macrophages, subepithelial fibroblasts and might be induced by activated T cells (Pender et al, 1997).

Mucosal microscopic changes lead to macroscopic changes in the SB mucosa, which may be picked up on SBCE. These include fissuring of the SB mucosa, scalloping of folds and a mosaic pattern appearance of the SB mucosa.

The gold standard for the diagnosis of CD in adults remains duodenal histology. Severity of changes on histology are classified according to the Marsh score of disease (Table 1)(Sasamura et al, 1991). Patients with gastrointestinal signs and symptoms suggestive of CD and positive serology are recommended to undergo a gastroduodenoscopy, which permits biopsy sampling from the duodenum. National guidelines recommend that at least four biopsies including a biopsy from the duodenal bulb should be taken (Ludvigsson et al, 2014) from the duodenum. Previous studies however have suggested that duodenal biopsy sampling can be sub-optimal (Collin et al, 2005) leading to false negative results, as the topographic distribution of CD changes may be patchy (Green, 2008; Hopper et al, 2008; Pais et al, 2008). Not all patients are willing or able to undergo a gastroduodenoscopy for duodenal biopsies resulting in some patients remaining undiagnosed with CD. This can have long term implications such as osteoporosis, iron deficiency anaemia, RCD and SB malignancy (Majsiak et al, 2018).


Table 1: Marsh classification of histological changes in coeliac disease;

\*IEL: intraepithelial lymphocytes

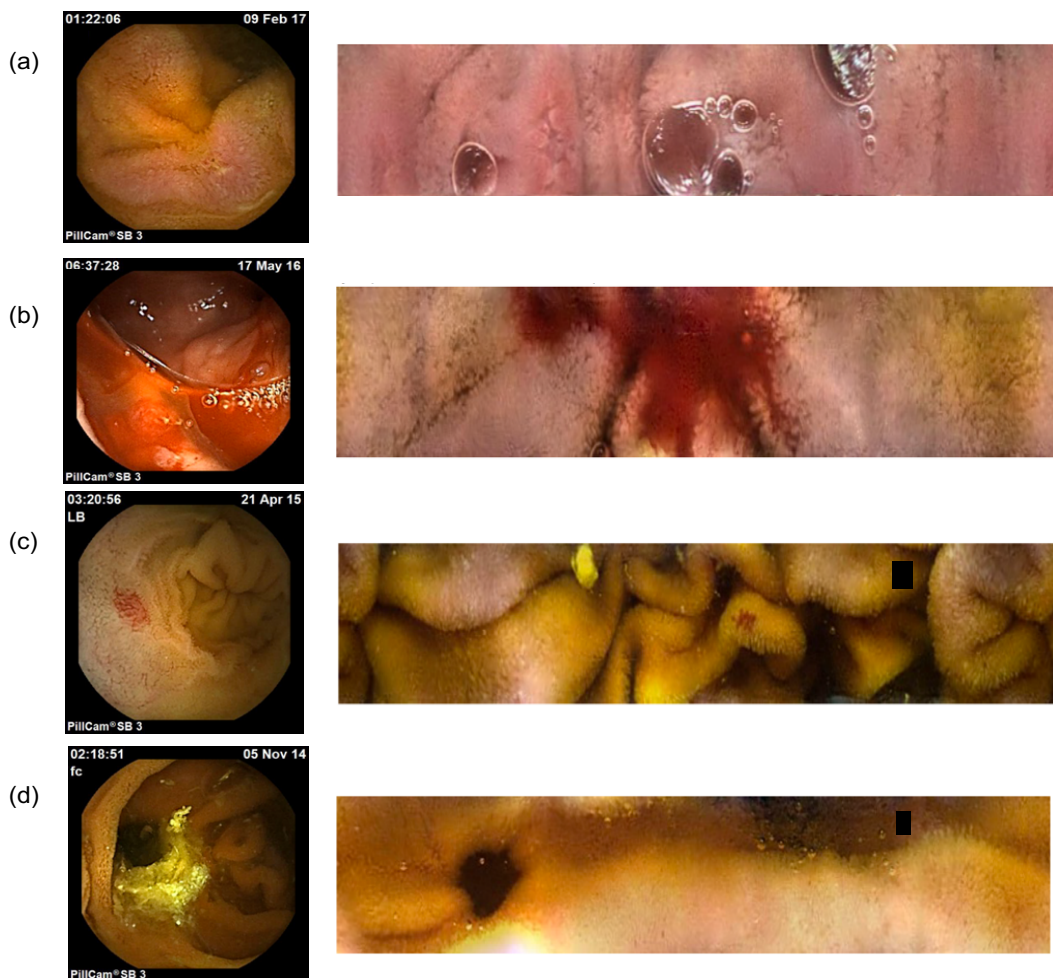Marsh Type	IEL* / 100 enterocytes jejunum	IEL / 100 enterocytes duodenum	Crypt hyperplasia	Villi
0	<40	<30	Normal	Normal
1	>40	>30	Normal	Normal
2	>40	>30	Increased	Normal
3a	>40	>30	Increased	Mild atrophy
3b	>40	>30	Increased	Marked atrophy
3c	>40	>30	Increased	Complete atrophy

### 1.1.2 Small bowel capsule endoscopy

SBCE is a form of wireless endoscopy that was first adopted into clinical practice in 2000 and since then, it has enabled non-invasive visualisation of the entire SB mucosa (Iddan et al, 2000). There are different capsule endoscopy systems, which are available that differ slightly in size, weight, image capture rate, battery life (8 – 15 hours) and image transmission method. The main difference is in the type of image that is transmitted. Axial SBCE provides luminal views of the SB through the use of a camera located at the front of the capsule. Panoramic SBCE provides 360° views of the SB by means of four cameras, 2 located at either end (Figure 2, Figure 3).



**Figure 2:** (a) Capsocam with 4 cameras provides 360° view; (b) Pillcam provides 156° view of the small bowel;



**Figure 3:** Comparison of small bowel pathologies on axial and panoramic SBCE: (a) aphthous ulcers, (b) fresh blood, (c) angioectasias, (d) diverticulum

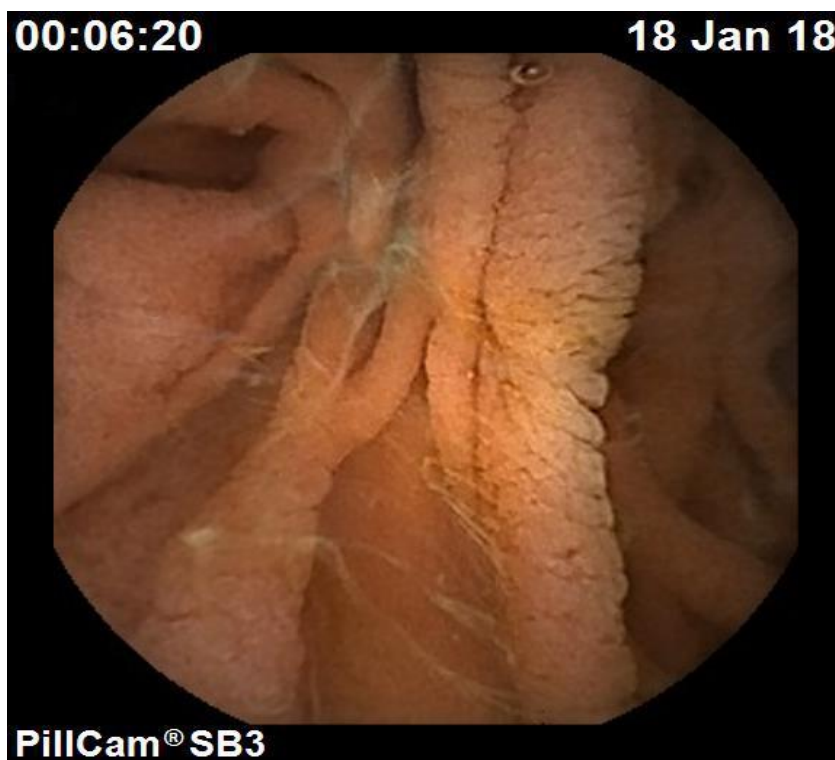
Following appropriate bowel preparation, the patient ingests the capsule that in turn transmits 512 by 512-pixel, high-resolution images at an adaptive frame rate of 2 to 6 frames (Medtronic, 2018; Monteiro et al, 2018) per second. The adaptive frame rate helps to make better use of the available battery life by only recording significantly different images of the small bowel. The battery life of SBCE varies between 8 to 12 hours (Ou et al, 2015). Images are detected and recorded by the help of a sensor belt or sensor array and a recorder. These are then transferred onto computer systems that trained reviewers (physician / nurse who has achieved competence to interpret SBCE) can view.

Duodenal histology remains the gold standard. However SBCE is recommended in the initial assessment of CD patients who are not willing / cannot undergo (e.g. coagulation disorders) an upper gastrointestinal endoscopy to obtain duodenal histology (Rubio-Tapia et al, 2013). The European Society of Gastrointestinal Endoscopy (ESGE) suggests the use of SBCE in equivocal cases of CD (Pennazio et al, 2015) where features of CD are present on histology but with negative serology or vice versa. Patients with negative serology might have another underlying cause for VA such as medications or an immune-mediated or inflammatory response or atypical infections (Aziz et al, 2017). The patchy nature of CD can explain the positive CD-related serology but negative histology (Bonamico et al, 2004; Hopper et al, 2008; Ravelli et al, 2005). SBCE is also recommended in patients with non-responsive CD or RCD (Rubio-Tapia et al, 2013).

Gastroduodenoscopy is a short procedure that allows views to the second part of the duodenum and enables duodenal biopsies to be taken. However, it is invasive and patients may require sedation for this procedure. SBCE is a non-invasive procedure that is better tolerated by patients and enables the whole length of the small bowel to be examined. However, it is a longer procedure and also requires a significant length of time for images to be reviewed. It is also more expensive than a gastroduodenoscopy (Catassi C et al, 2001). Patients require bowel preparation prior to a SBCE unlike for a gastroduodenoscopy where fasting for 4 hours is an adequate preparation.

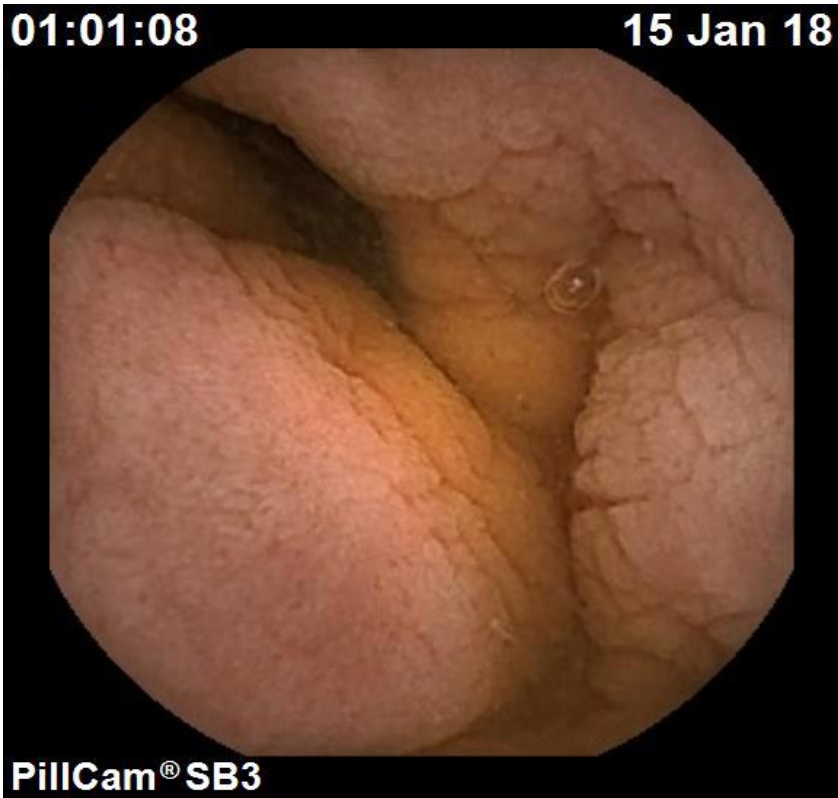
## 1.2 Macroscopic features of coeliac disease

Several macroscopic endoscopic features in the duodenum may suggest CD: e.g. reduction of mucosal (Kerckring) folds, scalloping and fissuring of mucosa, mosaic pattern and nodularity. Certain features have a higher specificity than others for the detection of CD (Dickey & Hughes, 1999). Bulb atrophy and reduced folds have been shown to have a low diagnostic sensitivity for CD. Scalloping, mosaic pattern and fissures are highly specific for CD (Balaban et al, 2015; Dickey & Hughes, 1999). Adaptation from upper gastrointestinal endoscopy has enabled physicians over the years to pick up the same features on SBCE (Figure 4, Figure 5, Figure 6). Villi lining the SB give the mucosa a velvety appearance in healthy people (Figure 7). Better magnification enables the detection of lack of villi on SBCE in CD (Murray et al, 2008). Biagi et al also described the existence of hypotrophic folds that can be found in intermediate cases of CD (Biagi et al, 2006).

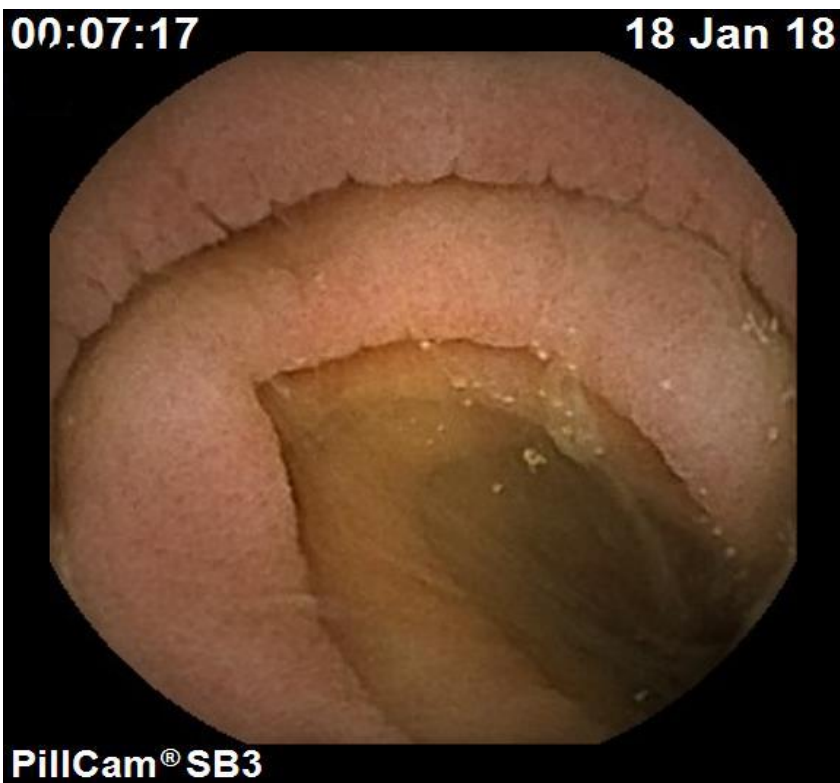


**Figure 4:** Fissuring of mucosa on small bowel capsule endoscopy in a patient with coeliac disease.



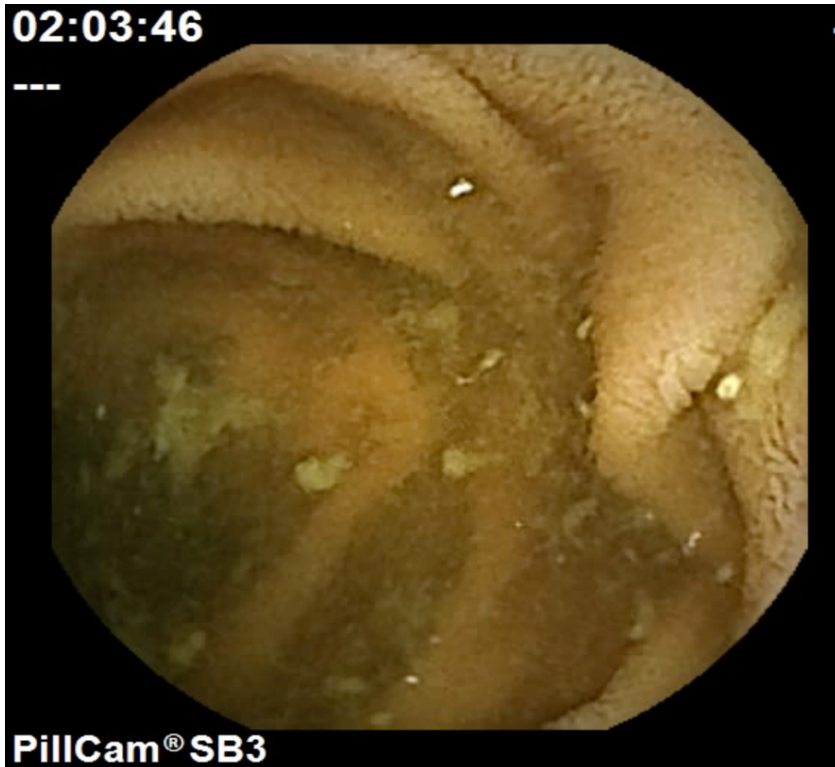


**Figure 5:** Mosaic pattern of mucosa on small bowel capsule endoscopy in a patient with coeliac disease.



**Figure 6:** Scalloping of mucosal folds on small bowel capsule endoscopy in a patient with coeliac disease.





**Figure 7:** Normal small bowel mucosa on small bowel capsule endoscopy

Macroscopic features of CD on SBCE can vary from subtle to more extensive changes. CD can manifest itself as very patchy or continuous within the SB. It can also be present for a very short distance or more extensively beyond the duodenum.

### 1.3 Sensitivity and specificity of small bowel capsule endoscopy

SBCE has been compared to what is considered the gold standard for diagnosing CD – duodenal histology. The sensitivity and specificity of SBCE in CD varies between 70%-93% and 90%-100% respectively ( Table 2) (El-Matary et al, 2009; Hopper et al, 2007; Lujan-Sanchis et al, 2017; Murray et al, 2008; Petroniene et al, 2005; Rokkas & Niv, 2012; Rondonotti et al, 2007). These findings support the high diagnostic accuracy of SBCE. In a more recent multicentre European study by Robles et al, the diagnostic yield (DY) was higher in patients with positive serology and in elderly patients (Perez-Cuadrado-Robles et al, 2018). Other authors have demonstrated that the benefits of SBCE are greater for patients found to have Marsh III vs Marsh I-II (diagnostic yield 28% vs 7%) histology (Kurien et al, 2013).

Sensitivity of SBCE for CD varies according to the reviewer's pre-study experience. In a study by Petroniene et al, the sensitivity was 100% when reviewers with a considerable experience were considered. This decreased to 70% when the four reviewers as well as those with limited experience were included (Petroniene et al, 2005).

The sensitivity and specificity of SBCE for CD are much higher than those of upper endoscopy in the detection of macroscopic features of CD. The reported sensitivity of endoscopic markers of CD ranges from 50% to 87% and the specificity varies between 83% and 100% (Bardella et al, 2000; Brocchi et al, 1988; Brocchi et al, 2002; Corazza & Gasbarrini, 1995; Dickey & Hughes, 2001; Maurino et al, 1993; McIntyre et al, 1992; Niveloni et al, 1998; Olds et al, 2002; Oxentenko et al, 2002; Tursi et al, 2002). These can be explained by better features of SBCE such as wider angle of view, 8-fold magnification (Petroniene et al, 2005), absence of insufflation and underwater navigation that can help increase the detection of CD features (Adler & Bjarnason, 2012).

The accuracy obtained from SBCE is similar to that of magnification endoscopy (sensitivity 95%, specificity 99%) or of endoscopy with the 'immersion technique' (sensitivity 95%, specificity 98%) in detecting the presence or absence of villi (Cammarota et al, 2004).

In RCD, the sensitivity of SBCE to detect VA is 87.5%. This is superior to upper gastrointestinal endoscopy, where the sensitivity to detect VA is only 64.7%(Rubio-Tapia et al, 2009)

**Table 2:** Sensitivity, specificity, positive and negative predictive value of SBCE in patients with CD or suspected CD

Author (et al)	Study design	Sensitivity	Specificity	Positive Predictive Value	Negative Predictive Value
(Petroniene et al, 2005)	4 investigators reviewed SBCEs of 10 CD patients and 10 controls; (2 with and 2 without pre-study experience)	70%	100%	100%	77%
(Biagi et al, 2006)	3 investigators reviewed SBCEs of 32 (26 CD; 5 IBS, 1 Crohn's disease)	90.5% - observer 1; 95.2% - observers 2 and 3;	63.6% (average for all observers)	/	/
(Hopper et al, 2007)	21 patients (EMA positive) and 23 controls underwent SBCE;	85%	100%	100%	88.9%
(Rondonotti et al, 2007)	43 patients were studied (11 normal duodenal histology; 32 CD);	87.5%	90.9%	96.5%	71.4%
(Murray et al, 2008)	38 patients with untreated CD and age, sex-matched controls; SBCE was repeated after 6 months of gluten withdrawal;	92%	100%	/	/
(El-Matary et al, 2009)	3 prospective, controlled trials; literature review performed by 2 independent reviewers;	83%	98%	/	/
(Rubio-Tapia et al, 2009)	Comparison of clinical characteristics and outcome in 57 patients with RCD: (42 RCD I; 15 RCD II);	87.5%	/	/	/

(Maiden et al, 2009)	19 patients with CD on a GFD for at least 12 months underwent gastroscopy with duodenal biopsies and SBCE;	67%	100%	100%	60%
(Lidums et al, 2011a)	22 patients with positive EMA or anti-TTGTTG; (8 normal and 14 had duodenal CD histology) underwent SBCE;	93%	100%	100%	89%
(Atlas et al, 2011)	SBCEs from 42 consecutive patients with nonresponsive CD and 84 age and sex-matched controls were included;	56%;	85%	/	/
(Rokkas & Niv, 2012)	Meta-analysis – 2 investigators identified 6 studies that met inclusion criteria (166 patients);	89%	95%	/	/
(Lujan-Sanchis et al, 2017)	Multi-centre study; SBCEs from 163 patients divided into 4 groups were compared;	47.4%, (seronegative CD with atrophy), 64.1% (seropositive CD without atrophy), 50% (contraindication to gastroscopy), 28.3% (seronegative CD without atrophy);	/	/	/

Some of the studies did not include specificity, positive and negative predictive values as indicated by / in the table below.

#### 1.4 Comparison of coeliac disease findings to symptomatology

There is currently a paucity of studies about the correlation of symptoms in CD with the extent of SB involvement on SBCE.

In two studies (n=499; 226), no correlation was found between the severity of VA (Marsh histological grading of disease) and the severity of clinical symptoms in patients with CD (Brar et al, 2007; Kalhan et al, 2011). Murray et al (n=38) also failed to establish a relationship between extent of SB involvement on SBCE and CD symptoms (Murray et al, 2008).

Contrary to this, another two studies suggest a correlation between the severity of symptoms and the extent of SB involvement. In a study by Petroniene et al, patients (n=10) with extensive SB involvement had typical symptoms of malabsorption (diarrhoea, weight loss) unlike those with mild / non-specific symptoms who had limited proximal SB involvement (Petroniene et al, 2005). In another multicentre study by Rondonotti et al, patients (n=43) with more severe symptoms had disease extending beyond the duodenum, in some involving the whole length of the SB (Rondonotti et al, 2007).

Lidums et al. were able to correlate extent of SB involvement following a gluten free diet (GFD) with an improvement in symptom score. However, the same study failed to show a correlation between symptoms and extent of SB involvement at baseline (Lidums et al, 2011b).

#### 1.5 Correlation of SBCE findings to coeliac serology

A positive correlation exists between severity of histology and serology (anti-TTG) of CD in both children and adults (Alessio et al, 2012; Bhattacharya et al, 2014; Dahlbom et al, 2010; Kalhan et al, 2011; Singh et al, 2015).

Few authors have investigated the relationship between SBCE findings and CD serology in their studies. Patients with suspected CD who underwent a SBCE, had a higher yield on SBCE if their serology was positive (Lujan-Sanchis et al, 2017). Murray et al, demonstrated that there was a longer time with SB mucosal abnormality in patients who had positive endomysial antibody (EMA) and / or anti-

TTG at the time of SBCE (Murray et al, 2008). Though not many studies have explored the relationship between serology and SBCE findings for patients with CD, these studies point to a positive correlation between severity of disease and positive serology. Further data is needed to correlate different CD serology (anti-TTG, EMA, anti-gliadin antibodies) at diagnosis and at the time of SBCE, to the findings and extent of disease on SBCE.

### 1.6 Interobserver agreement of coeliac disease findings

Interobserver agreement (IOA) is an important factor when assessing the reliability of tests that employ subjective visual evaluation. It can vary significantly between SBCE reviewers (Biagi et al, 2006).

IOA can vary according to different features of CD. At upper gastrointestinal endoscopy using methylene blue (1%), IOA was excellent for mosaic pattern (kappa: 0.76 for both videoendoscopic inspection and dye staining), and mucosal scalloping (kappa: 0.83 and 0.76 for videoendoscopic inspection and dye staining respectively). Agreement was fair (kappa: 0.41, 0.59 respectively) for the reduction in the number or loss of duodenal folds (Niveloni et al, 1998). The overall IOA between the 2 reviewers for 38 patients with CD undergoing SBCE was highest ( $\kappa=0.77$ ) for mosaic pattern followed by scalloping ( $\kappa=0.59$ ), fissuring ( $\kappa=0.41$ ), VA ( $\kappa=0.37$ ) (Murray et al, 2008). In another study by Rondonotti et al, the SBCE of 32 patients with CD and 11 patients with normal duodenal mucosal biopsies were studied by four reviewers. Kappa values for IOA ranged between 0.56 and 0.87, with scalloping having the highest kappa values (0.65–0.85) (Rondonotti et al, 2007). Mucosal scalloping and mosaic pattern were the most picked up features of CD in the above studies.

IOA can also vary according to the previous experience of SBCE reviewers. In a study by Petroniene et al, SBCEs for 10 CD patients and 10 controls were reviewed by 4 reviewers, 2 of whom had previous considerable experience in SBCE reading. IOA was excellent ( $K=1$ ) when only the experienced reviewers were considered but this was poor when reviewers with low pre-study experience were included ( $K=0.2$ ) (Petroniene et al, 2005).

There is only a small number of studies on IOA for CD features on SBCE in the literature. The studies are very heterogenous with not all reviewers reading all the SBCEs for all patients and with varying degrees of experience. The number of patients studied is also considerably small in most studies. My study aims to address this knowledge gap.

### 1.7 Small bowel transit in patients with coeliac disease

Gut motility is regulated by a combination of muscular, immune and environmental factors. Patients with CD suffer from disordered gut motility (Bassotti et al, 1994). This can affect the oesophagus and stomach and has been demonstrated on manometry (Usai et al, 1995) and on C-octanoic breath test (Rocco et al, 2008) resulting in delayed gastric emptying. There is evidence that the oro-caecal transit time is also delayed in patients with CD when compared to controls (Benini et al, 2012). Another study reported normalisation of oro-caecal transit time in CD following a GFD (Chiarioni et al, 1997).

Intestinal dysmotility in patients with CD has been proven to normalise after a GFD (Chiarioni et al, 1997; Sadik et al, 2004). One mechanism is related to acetylcholine release from the myenteric plexus and muscle hypercontractility secondary to gliadin exposure (Verdu et al, 2008). Another mechanism is disruption of the complex hormonal and neuroimmune regulation due to the damaged intestinal lining in patients with CD (Tursi, 2004). Post prandial cholecystokinin levels are low resulting in gallbladder inertia and impairment of SB transit (Hopman et al, 1995).

SBCE can provide a non-invasive method of calculating SB transit. A prolonged SB transit in CD can help distinguish patients with CD from healthy controls. SB transit measurement would also be useful to assess improvement of patients with CD following a GFD or immunosuppressants +/- steroids. Ciaccio et al, have estimated SB motility by comparing changes in luminal width along the SB on SBCE. There was less variation in luminal width in CD patients than in controls (Ciaccio et al, 2012). In contrast, a study by Urgesi et al, showed that there was no difference in the SB transit in 30 CD patients on a normal gluten-containing diet ( $252.2 \pm 67.4$  minutes) and 30 controls ( $244.7 \pm 88.4$  minutes). One limitation of the study was that there was no mention of the use of prokinetics (Urgesi et al,

2013). A lower rate of prokinetic use in the CD group might have approximated the SB transit time to that of controls. Another observation is that despite not being statistically significant from that in the CD group, the gastric emptying time in controls was longer than in CD. This might have had an impact on the SB transit in controls (Westerhof et al, 2009). Further clarification is needed on the SB transit in patients with CD undergoing SBCE.

#### 1.8 Repeat small bowel capsule endoscopy in coeliac disease

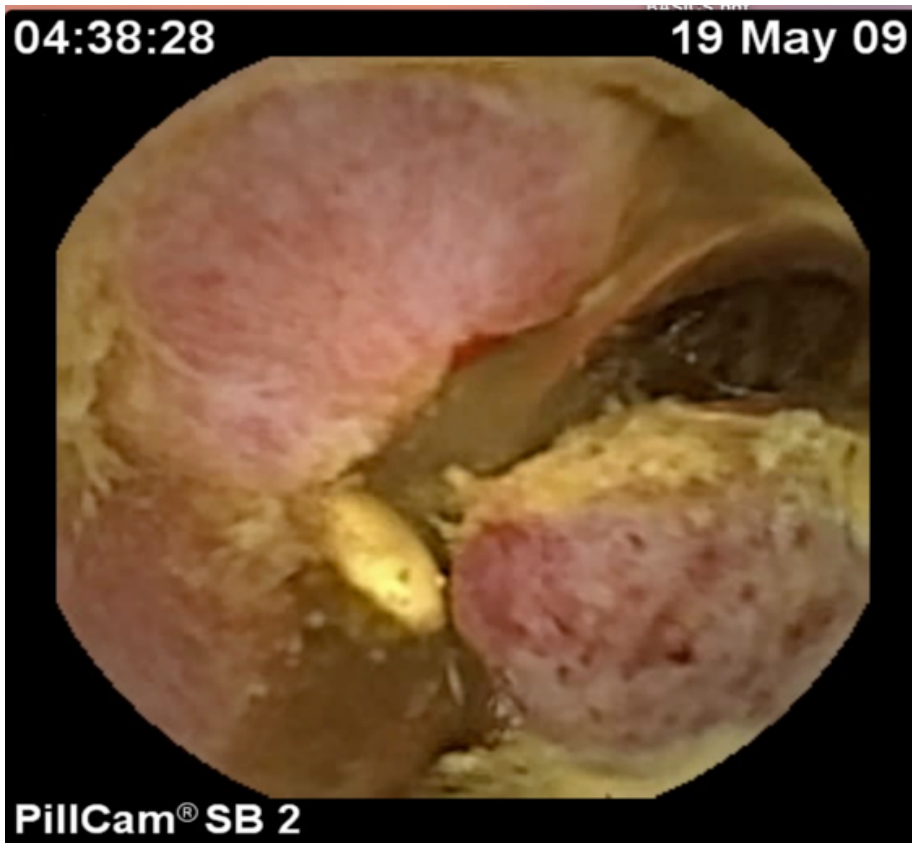
Older guidelines have recommended that patients with CD undergo a repeated endoscopy following a GFD (Ciclitira et al, 2001) to document histological improvement, confirm clinical remission and dietary adherence. More recent papers have recommended endoscopy after 6 to 12 months on a GFD to evaluate dietary adherence (Anderson, 2008; Pietzak, 2005). The 2014 British Society of Gastroenterology (BSG) guidelines and the American College of Gastroenterology (ACG) 2013 guidelines recommend repeating histology only when CD complications are suspected or when patients do not improve on a GFD (Ludvigsson et al, 2014; Rubio-Tapia et al, 2013). These recommendations reflect the patchy nature of CD, where histology might not be representative of SB mucosal healing. Persistent VA on histology may reflect non-adherence to a GFD or a super-sensitive immunological response to gluten or may be secondary to slow mucosal healing. Histology on its own cannot distinguish amongst these. Extent of disease can be compared between SBCEs and therefore can help distinguish patients with slow mucosal healing from those with persistent / worsening mucosal disease that are more likely to develop complications. Patients with persistent macroscopic changes of CD but a shorter extent of disease on repeat SBCE are likely to have slow mucosal healing. In a study by Murray et al, 30 patients underwent repeat SBCE at least 6 months after starting a GFD (Murray et al, 2008). The extent of the intestinal lesions improved in 79%. The same group of authors also demonstrated an improvement in the average time with abnormality, the percentage time with abnormality and total SB transit (Murray et al, 2008). In a more recent study by Lidums et al, 12 adult patients showed improvement in SB VA on repeat SBCE ( $18.2 \pm 3.7\%$  to  $3.4 \pm 1.2\%$ ) at 12 months on a GFD but 42% of patients showed persistent villous abnormality on duodenal histology (Lidums et al, 2011b). This confirms that SBCE can better assess the extent of mucosal healing of CD. However, there is a paucity of



literature on this subject. The current ESGE guidelines on the diagnosis of SB disorders state that there is no role for SBCE in assessing the extent of disease or response to a gluten-free diet (Pennazio et al, 2015). This is on the basis that no relationship has been established so far between extent of SB involvement at diagnosis on SBCE and clinical severity of disease (Lidums et al, 2011b; Murray et al, 2008). This might however change in the future when a clearer relationship between symptoms and extent of disease is confirmed.

#### 1.9 Small bowel capsule endoscopy in refractory coeliac disease

RCD has a reported prevalence of between 0.3% to 10% in patients with CD (Woodward, 2016). It is defined as persistent or recurrent malabsorptive symptoms and signs with VA despite a strict GFD for more than 12 months (Ludvigsson et al, 2013). In RCD I, IELs have normal surface CD3 and CD8 expression and a polyclonal T-cell receptor arrangement, similar to uncomplicated CD. In RCD II, an aberrant lymphocyte population is present with loss of surface CD3 and CD8 expression, retention of CD3 expression within the cell, and a monoclonal T-cell receptor arrangement. RCD II has a poor prognosis with increased mortality because of the development of enteropathy-associated T-cell lymphoma (EATL) (Figure 8), a complication occurring in over 50% of patients (Al-Toma et al, 2007; Cellier et al, 2000).

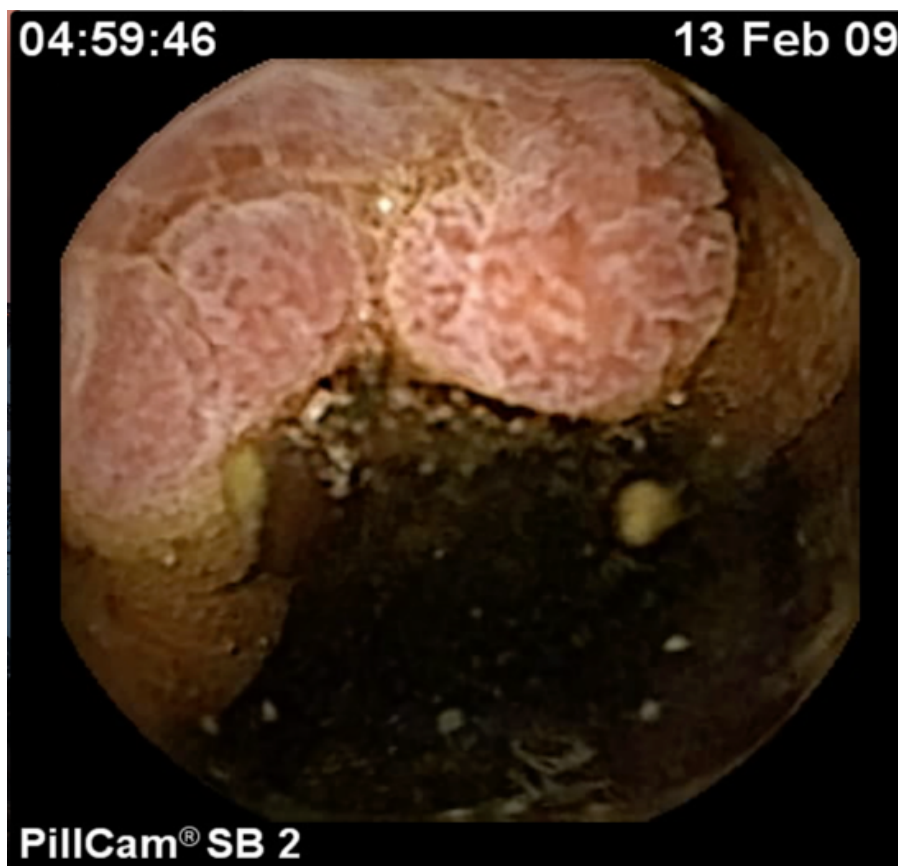

**Figure 8:** Enteropathy-associated T-cell lymphoma in a patient with coeliac disease.

The histological diagnosis of RCD especially type II can be challenging. The presence of an aberrant immunophenotype and monoclonality of IELs is not specific to RCD. These findings can also be seen in uncomplicated CD especially in those who are not compliant to a GFD or shortly after a CD diagnosis is made (Liu et al, 2010; Prisco et al, 1997; Ubiali et al, 2007). Immunostaining for CD3 and CD8 helps localisation (Liu et al, 2010), but can lead to a very rough approximation of the proportion of CD8- CD3+ cells. Also, it cannot differentiate between surface and intracellular CD3, a feature that is important in RCD II where only the surface CD3 is lost (Patey-Mariaud De Serre et al, 2000). Flow cytometry is affected by variable cell yields, the need for fresh biopsies, and the lack of localisation of the cells isolated (Leon, 2011; Verbeek et al, 2008). Different cut-offs of the proportion of aberrant IELs are used to define RCD II depending on the techniques used to quantify them.

ESGE recommends initial assessment by SBCE followed by device-assisted enteroscopy in nonresponsive CD or RCD (Pennazio et al, 2015) to assess for

complications such as EATL and ulcerative jejunoileitis (Figure 9) that most commonly occur in the SB beyond reach of conventional upper gastrointestinal endoscopy (Atlas et al, 2011; Daum et al, 2007; Elli et al, 2017; Maiden et al, 2009; Mooney et al, 2012). SBCE might also help distinguish between RCD I and II. In a study by Barret et al, patients (n=11 type I and 18 type II) with RCD II (54 %) were more likely to have extensive lesions involving the distal jejunum and ileum on SBCE than patients with RCD I (9 %) ( $p < 0.02$ ) (Barret et al, 2012). This is important as RCD II carries a 5 year mortality of about 50% (Nasr et al, 1000). However, this is the only study that compares the severity of lesions between RCD I and II.



**Figure 9:** Ulcerative jejunoileitis on small bowel capsule endoscopy in a patient with coeliac disease.

Improvement in patients with RCD has been documented symptomatically and histologically with oral budesonide (Mukewar et al, 2017), azathioprine (Ianiro et al, 2013), steroids (Goerres et al, 2003; Maurino et al, 2002) and infliximab (Costantino et al, 2008). Patients with RCD I respond well to azathioprine or tioguanine (Rowinski & Christensen, 2016). RCD II requires more aggressive

treatment with antimetabolite cladribine (Al-Toma et al, 2006) or autologous haematopoietic stem cell transplantation (Tack et al, 2011b). There are no studies so far on the routine use of repeat SBCE in RCD following the initiation of treatment. SBCE might be superior to imaging in patients with CD as strictures can be missed on SB imaging (Kastin et al, 2004).

#### 1.10 Small bowel capsule endoscopy in equivocal coeliac disease

ESGE suggests the use of SBCE in cases of equivocal diagnosis of CD including those with positive serology and negative histology and in those with histology suggestive of CD but with negative serology for CD (Pennazio et al, 2015).

##### 1.10.1 Positive coeliac serology and negative histology

In a study by Lujan-Sanchis et al, the diagnostic yield (DY) of SBCE in this group of patients was 69.2%. 64.1% of these patients had evidence of intestinal atrophy and 2.6% showed evidence of complicated CD (Lujan-Sanchis et al, 2017). However, there were some limitations to this study including its retrospective design, the use of different systems of SBCE and subjective criteria for CD diagnosis on SBCE. In contrast, another study by Lidums et al reported normal SBCE in all patients with positive coeliac serology and negative duodenal biopsies emphasizing the lack of utility of SBCE in this subgroup (Lidums et al, 2011a). The study by Kurien et al, supports the low yield of SBCE in patients with positive serology and negative histology for CD. Thirty patients with non-specific duodenal histology (Marsh I or Marsh II) were studied. Of these, only 6 (20%) had positive serology and only 1 was diagnosed with CD and another 1 with Crohn's disease (Kurien et al, 2013).

Evidence for this equivocal group of patients is lacking. More data is needed on the use of SBCE to evaluate patients with positive serology and negative histology for CD before SBCE can be recommended in the evaluation of these patients.

##### 1.10.2 Seronegative villous atrophy

VA can occur due to seronegative coeliac disease (SCD) or seronegative non-coeliac disease (S-non-CD). One explanation for SCD is the patchy nature of CD (Bonamico et al, 2004; Hopper et al, 2008; Ravelli et al, 2005). Another reason is

patients might be on a low gluten containing diet, thus enabling the mucosa to heal in some areas. Low serum IgA can be associated with serology negative VA. More commonly patients with seronegative VA do not have CD (S-non-CD). Reasons for S-non-CD include infections, inflammatory / immune-mediated disorders, drugs. This group also encompasses a group of patients with idiopathic S-non-CD that can have normalisation of duodenal mucosa despite continuing a gluten containing diet (Aziz et al, 2017).

This group of patients have also been studied by Kurien et al (Kurien et al, 2013). Thirty-two patients with antibody negative VA who underwent SBCE had a DY of 28%. 63% of these were HLA DQ2/8 positive. 22% had findings of CD while 6% had evidence of SB Crohn's disease. This group of patients with seronegative VA and negative CD serology had a much higher DY on SBCE than patients with nonresponsive CD (7%) within the same study.

Increased IEL counts in an otherwise normal SB biopsy specimen can be a feature of early CD, Marsh classification I (Oberhuber et al, 1999) but may be associated with other conditions such as non-steroidal anti-inflammatory drugs (NSAIDs) use, infections, small intestinal bacterial overgrowth, immunological disorders, and lymphocytic or collagenous colitis among others (Shmidt et al, 2014; Tortora et al, 2014). Further review of histology can potentially identify features that might point to CD such as the CD8, CD3 positivity of T lymphocytes. This tends to increase towards the tip of the villi in patients with CD. In other causes of SNVA, villi show the reversed pattern (Goldstein, 2004; Goldstein & Underhill, 2001; Shmidt et al, 2013).

There is only one study by Kurien et al, that shows the low yield of SBCE in patients with raised IELs (classified as group B – equivocal) (Kurien et al, 2013). There is insufficient data to state whether SBCE might be useful in this group of patients. However, SBCE in patients on regular NSAIDs might show other pathology in the SB including erosions and ulcers.

The role of SBCE in equivocal cases of CD will be clarified further in this thesis.

## 1.11 Conclusions

There are some limitations to using histology for the diagnosis of CD. SBCE can help provide additional information by detecting morphological features of CD, give information on SB transit and the extent of diseased mucosa, thus distinguishing patients with CD from age and gender matched controls with similar symptomatology but where CD has been ruled out and provide information on severity of disease. However, there is very limited data to correlate serology, symptoms at the time of SBCE and histological severity with findings on SBCE.

Larger studies on IOA can help establish which morphological features on SBCE are more important for the diagnosis of CD enabling better uniformity in reporting CD findings and potentially establish a role for severity as determined by morphological features. This will in turn help set up a score of severity of CD related features on SBCE. Grading findings on SBCE according to a score can help grade severity of CD objectively and enable a more objective comparison of SBCEs to be made.

More studies are needed to help establish a role for SBCE in antibody negative and equivocal cases of CD. Despite the low DY of SBCE to date in this group of patients, it has an important role to play in the exclusion of other SB pathologies.

SBCE can have a very pertinent role in the follow up of patients with RCD as it can demonstrate mucosal healing from distal to proximal SB following the initiation of treatment. However, bigger prospective studies are needed to validate the use of SBCE in this particular cohort of patients with CD.

## Chapter 2 – Framework of thesis

### 2.1 Null Hypothesis

There is no role for small bowel capsule endoscopy (SBCE) in the diagnosis, further investigation and follow up of patients with coeliac disease (CD) and seronegative villous atrophy (SNVA). In order to reject the null hypothesis, I evaluated the utility of SBCE in 6 studies which will form the chapters of my thesis.

### 2.2 Aims

1. To characterize the findings on small bowel capsule endoscopies of patients with newly diagnosed CD.
  - a) To identify any correlations with symptoms at presentation;
  - b) To identify the relationship with CD serology;
  - c) To identify an association with Marsh classification of histology;
  
2. To study a cohort of patients with established CD who underwent a SBCE and compare them to a group of control patients.
  - a) To identify any correlations with symptoms at the time of SBCE;
  - b) To identify the relationship with CD serology;
  - c) To identify an association with Marsh classification of histology;
  - d) To determine the sensitivity and specificity of SBCE in delineating CD changes;
  - e) To compare SB transit in CD patients and controls
  
3. To assess the role of SBCE in patients with distinct causes of SNVA and raised intraepithelial lymphocytes (IELs) on duodenal histology.
  
4. To assess findings on SBCE in patients with refractory coeliac disease (RCD).
  - a) To compare findings on SBCE in patients with RCD to findings in uncomplicated CD patients.
  - b) To assess small bowel (SB) mucosal healing in patients with RCD on repeat SBCE after initiation of treatment.

5. To determine the interobserver agreement (IOA) of 2 expert reviewers of SBCE in patients with CD and establish a score of severity of CD on SBCE.
  
6. To assess the use of Flexible Spectral Imaging Colour Enhancement (FICE) to improve detection of CD features on SBCE.



## 2.3 General Methodology

### 2.3.1 Patient population and expert reviewers

Patients with histologically confirmed CD, SNVA, raised IELs and normal duodenal biopsies were recruited in different studies. CD, SNVA, raised IELs were confirmed histologically from biopsies taken from the duodenal bulb and the second part of the duodenum during gastroduodenoscopy. All patients underwent a SBCE. SBCE was carried out as part of the patient's clinical care when it was deemed to be a necessary investigation by the caring physician. Age and gender matched controls recruited did not have any major comorbidities and had duodenal biopsies ruling out CD. Serological markers of patients recruited were taken within 4 weeks of patients undergoing SBCE.

The studies were carried out at Sheffield Teaching Hospitals where the number of capsules endoscopies carried out is more than 800 per year. Sheffield Teaching Hospitals is a tertiary centre for the management of CD and a national referral centre for RCD. SBCE expert reviewers for the purpose of this study were involved in reading more than 300 capsules per year in a centre with a high flow volume of SBCEs. This was to ensure that reviewers had expert knowledge in identifying macroscopic features of CD on SBCE.

### 2.3.2 Duodenal histology

At least 2 biopsies were taken from the duodenal bulb and 4 biopsies from the second part of the duodenum during gastroduodenoscopy. Histology was then classified according to the modified Marsh criteria (Oberhuber et al, 1999). The most severe histological grade was considered as the overall histological grade for each patient.

### 2.3.3 Small bowel capsule endoscopy

Each patient was asked to drink 2 litres of Klean-Prep® prior to undergoing SBCE. All patients underwent SBCE using the Pillcam SB3 (Medtronic, Minneapolis, USA) (Zwinger et al, 2018). Details on gastric and SB passage time, extent of abnormal SB and macroscopic features of CD on SBCE were determined by expert SBCE reviewers.

#### 2.3.4 Design of studies

All studies were carried out prospectively except for the study on patients with an equivocal diagnosis of CD where patients recruited where twenty-seven (15.3%) patients were also subjects in studies by Aziz and Kurien et al (Aziz et al, 2017; Kurien et al, 2013). Including patients with SNVA from other studies has enabled me to follow up patients for a longer period of time. Chapters on established CD, RCD and severity of disease (interobserver agreement study) included a control group of patients.

Information on SBCE such as gastric passage time, SB transit, extent of affected SB mucosa and the corresponding percentage of affected mucosa was collected. Information on macroscopic features of CD such as the presence of mosaic pattern, fissuring of mucosa, scalloping of folds, villous atrophy, nodularity of mucosa, hypotrophic folds and the presence of ulcers was gathered for each SB tertile. Reviewers were asked to classify the overall severity of disease as mild, moderate or severe (see coeliac disease proforma in the supplementary material section 10.4). The use of prokinetic drugs such as metoclopramide and erythromycin whilst patients underwent SBCE according to local protocol, was also recorded.

Other data collected on patients recruited included past medical and surgical history, drug history, gender, age at diagnosis and when SBCE performed, signs and symptoms at presentation, histological criteria according to the Marsh classification (Marsh & Crowe, 1995) of disease of duodenal biopsies. Human leukocyte antigen (HLA) status was available for most patients. Serological markers measured refer to endomysial antibody (EMA), anti-tissue transglutaminase (TTG), albumin, CRP, haemoglobin, vitamin B12, folic acid level, vitamin D level and calcium.

Expert reviewers read de-identified SBCEs of patients with CD, SNVA and controls. They were blinded to the histology result of patients. Information on features of SBCE was collected by reviewers as described above. In some studies, findings from all reviewers were compared.

My role in each chapter was to collect data including details on features of CD on SBCE and clinical features of patients, carry out the statistical analysis in each chapter and write the chapters. I also was one of the expert reviewers of SBCE in each chapter except for the chapter on the role of virtual chromoendoscopy (FICE) in the delineation of CD changes. In this chapter, I was involved in the design of the study by identifying and distributing images to expert reviewers for assessment.

#### 2.4 Statistical analysis

Statistical analysis was carried out using SPSS version 23 (IBM Corp. Released 2015. IBM SPSS Statistics for Mac, Version 23.0. Armonk, NY: IBM Corp.). Frequencies, means and standard deviations were calculated to characterize the cohort studied.

Results were considered to be statistically significant if the p value was less than 0.05.

Non-parametric statistical tests were used namely, Fisher's exact test to assess statistical significance between categorical variables and Spearman's rho to assess the correlation between continuous variables. The Mann-Whitney U test was used to compare 2 independent, continuous variables and the Kruskal-Wallis test was used to compare multiple independent, continuous variables.

Multivariate regression analysis were constructed to assess the relationship between multiple factors and extent of disease on SBCE.

The degree of correlation between different macroscopic features of CD on SBCE according to expert pairs of reviewers reading SBCEs was assessed by Cohen's kappa co-efficient or intraclass correlation coefficient (ICC). The former was used in the case of binary ordinal variables such as for example the presence of mosaic pattern affecting the proximal SB mucosa. The latter was used to assess the degree of correlation between continuous variables such as the percentage of abnormal SB mucosa between different reviewers. A Bland-Altman plot was also constructed to depict correlation between extent of disease between reviewers.

Fleiss' kappa co-efficient was also used to measure the degree of agreement amongst the 5 reviewers in the FICE study..

## 2.5 Ethical considerations

Ethical approval was granted by Sheffield Research Ethics Committee and the Health Research Authority (IRAS project ID 232382, STH reference 19998) (see supplementary material approval letter, section 10.5).

## **Chapter 3– Assessment of disease severity & interobserver agreement on capsule endoscopy in patients with small bowel villous atrophy.**

### 3.1 Abstract

#### 3.1.1 Introduction

There is a lack of uniformity of reporting on features of coeliac disease (CD) on small bowel capsule endoscopy (SBCE). This makes determining extent of disease and comparison of severity of disease challenging.

#### 3.1.2 Methodology

De-identified SBCEs of 300 patients (78 CD (26%), 18 serology negative villous atrophy (SNVA) (6%), 204 controls with normal duodenal histology (68%)) were included. Videos were reviewed by 2 experts. All patients had duodenal histology taken within 2 weeks of SBCE. The degree of agreement in CD features and extent of disease was then determined. The resulting score for each factor was used to determine overall severity of disease.

#### 3.1.3 Results

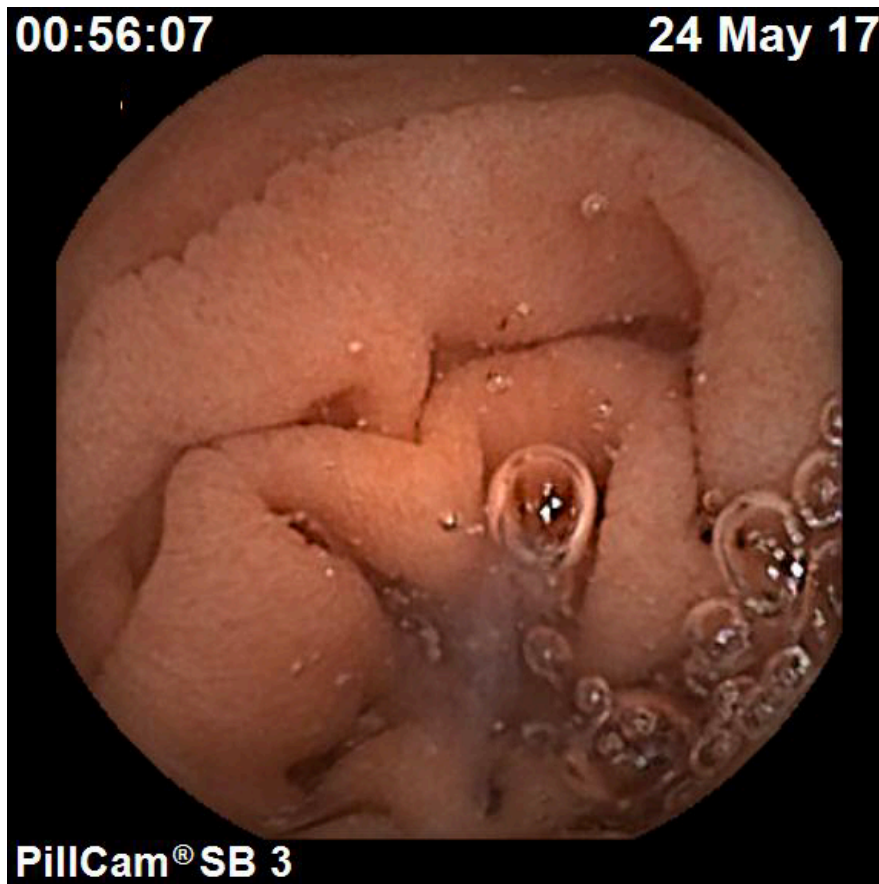There was substantial agreement in the kappa co-efficient for the detection of CD features between reviewers (0.67). Agreement for extent of affected SB mucosa was high (0.97). On multivariate regression analysis several features of CD correlated with extent of affected small bowel (SB) mucosa for both reviewers. The odds ratios derived from this analysis were then used to score features of CD, enabling scores of severity to be calculated for each patient. The median overall scores for patients increased significantly according to the independent classification of severity by the capsule reviewers: mild (34, 0-254), moderate (50, 27-133), severe (96, 69-128) ( $p=0.0001$ ).

#### 3.1.4 Conclusion

The good correlation of CD scores between expert reviewers confirms the validity of features of CD on SBCE. An objective score of CD features in the SB is useful in the follow up of patients with CD and SNVA.

### 3.2 Introduction

Reporting of features of celiac CD on SBCE is very subjective. Features of CD such as VA (figure 15), scalloping of folds (figure 15), mosaicism (figure 16), nodularity of mucosa (figure 17), fissuring of folds (figure 17) and ulcers (figure 19)) (Murray et al, 2008; Rondonotti et al, 2007) have only been reported by a few studies. Nomenclature referring to features of CD can vary amongst reviewers with limited SBCE experience resulting in under reporting of features (Petroniene et al, 2005). Although features of CD have been shown to affect mostly the proximal SB (Lidums et al, 2011a; Murray et al, 2008), extent of disease beyond the duodenum may have clinical implications which are still being studied (Chetcuti Zammit et al, 2019a; Lidums et al, 2011b; Murray et al, 2008).



**Figure 10:** Villous atrophy and scalloping on SBCE in a patient with coeliac disease

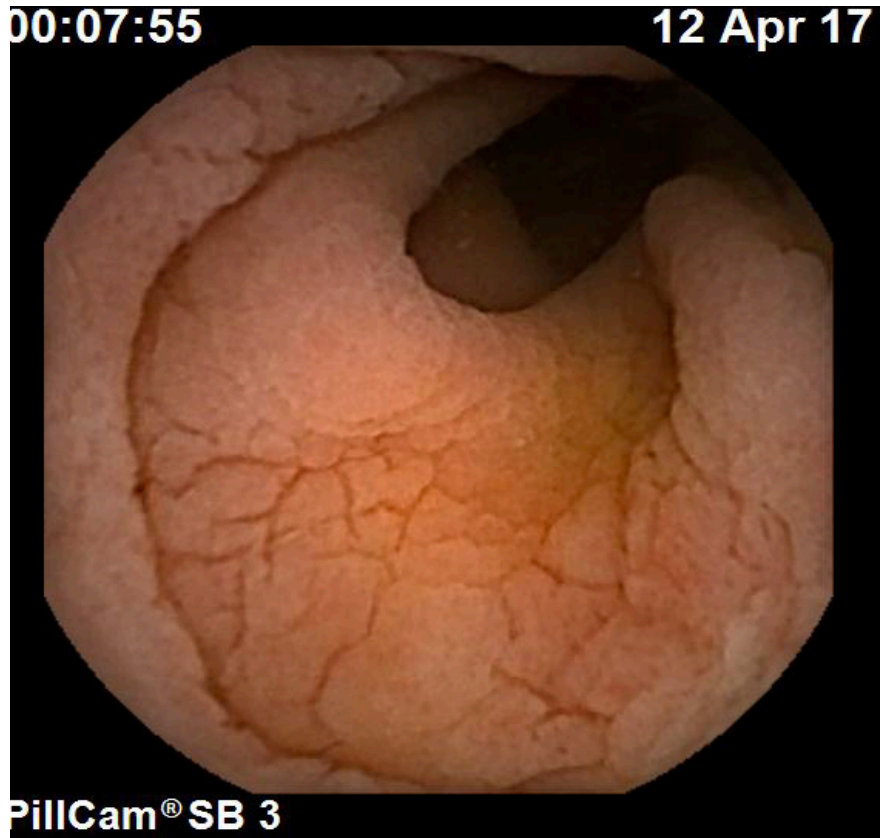


Figure 11: Mosaic pattern of mucosa on SBCE in a patient with coeliac disease

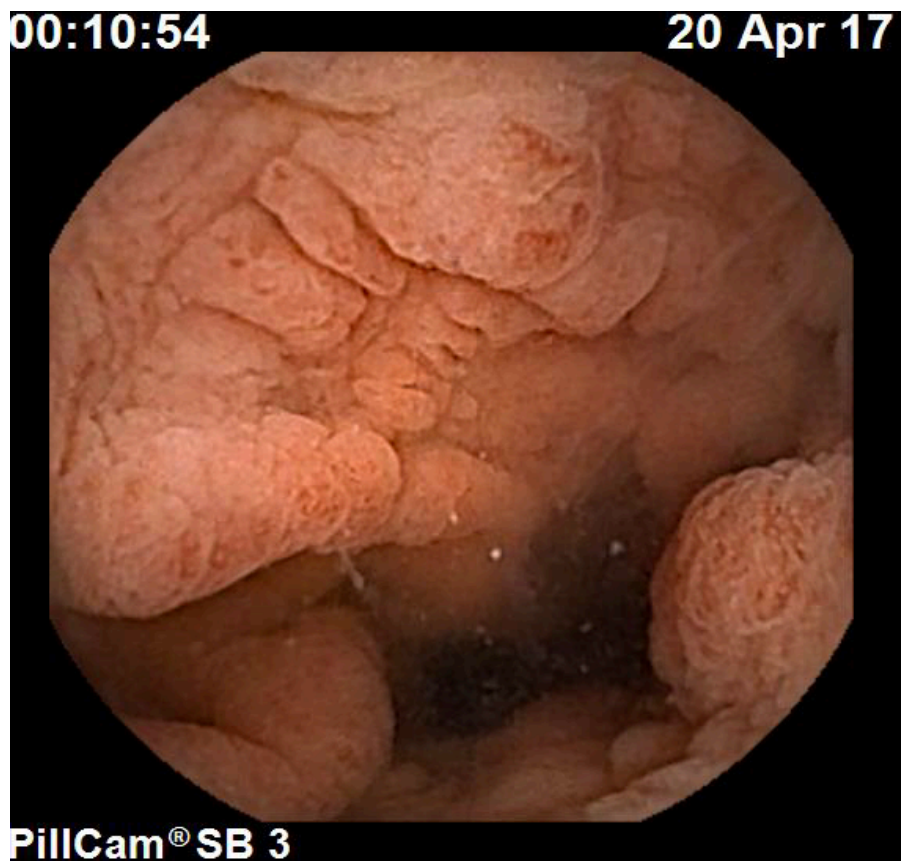


Figure 12: Nodularity of small bowel mucosa in a patient with coeliac disease



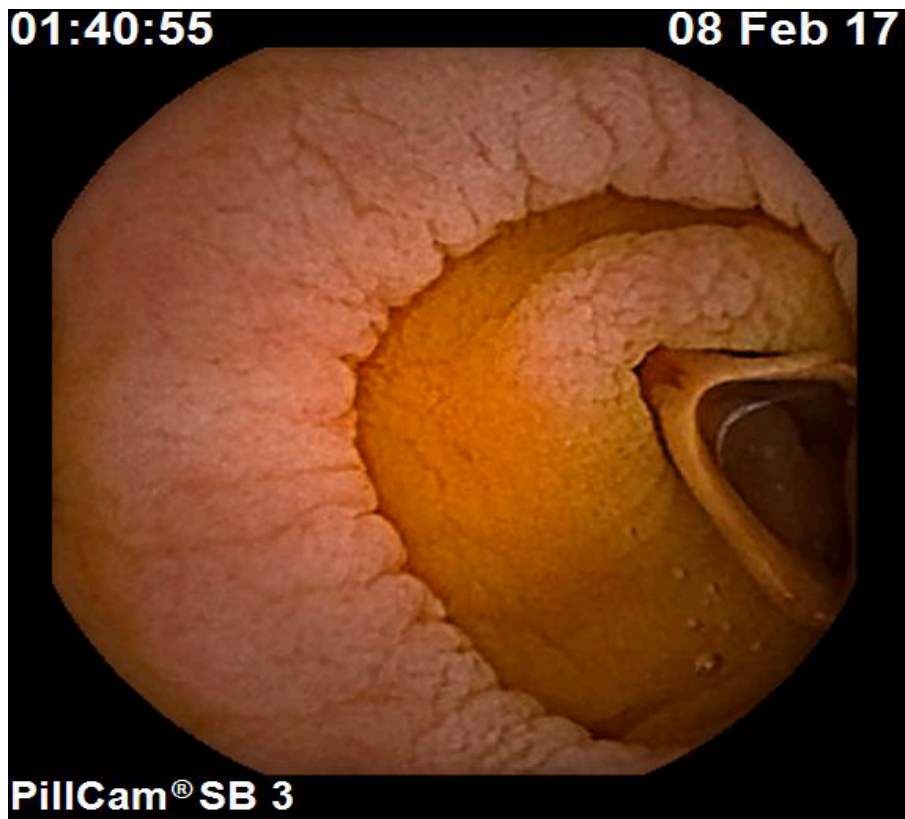
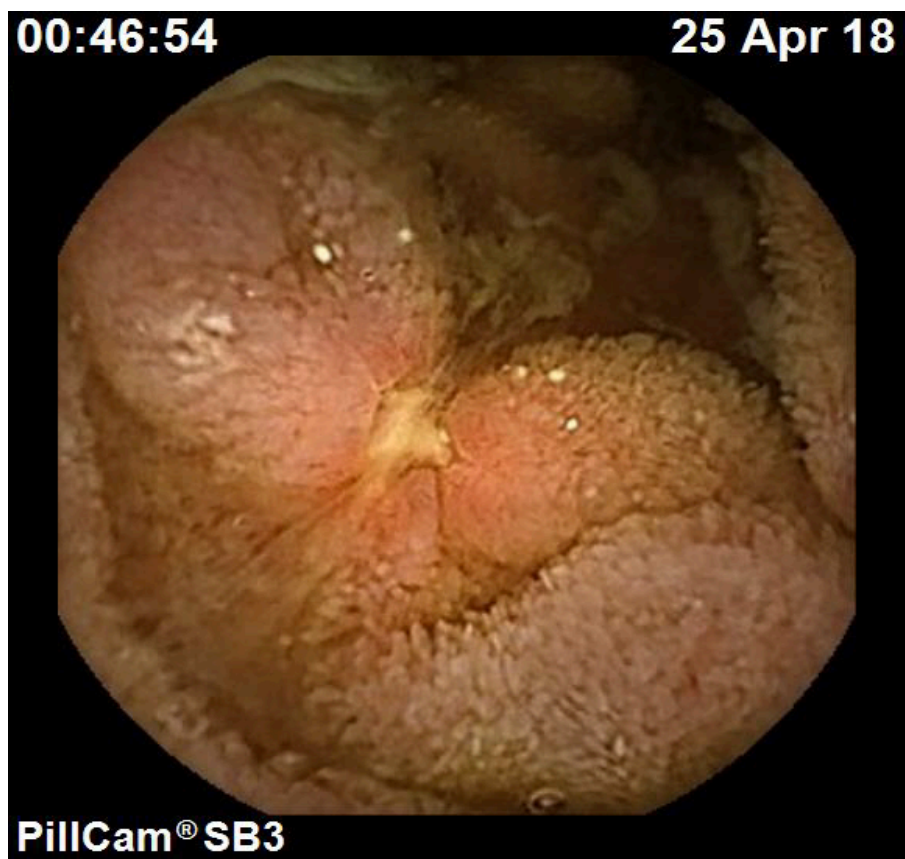


Figure 13: Fissuring of folds on SBCE in a patient with coeliac disease





## **Figure 14:** Small bowel ulcers in a patient with coeliac disease

The lack of uniformity of reporting on features of CD on SBCE makes it difficult to compare severity of CD. I have recently reported on the utility of SBCE in patients with RCD following administration of immunosuppressants demonstrating an improvement in extent of disease (Chetcuti Zammit et al, 2019a).

The reporting of SB Crohn's disease has been standardised by the introduction of Lewis score (Gralnek et al, 2008)(Cotter et al, 2015) which has been integrated into the capsule reading software. It provides objective evidence of the severity of Crohn's disease, enables comparisons between SBCEs and provides grounds for escalation of therapy.

My aim was to compare IOA of features of CD and formulate an objective and reproducible method of measuring extent and severity of CD in the SB. Such methodology, would help to standardise terminology used to refer to features of CD and establish a range of scores that indicate severity of disease based on the number of features and extent of affected SB mucosa.

### 3.3 Methodology

#### 3.3.1 Study design and patients

Consecutive patients with newly diagnosed and established CD (78; 26%), SNVA (18, 6%) and control patients (204; 68%) who underwent a SBCE as part of their clinical care were included over a 1 year period in a tertiary centre for the management of CD and the national centre for the management of RCD. All patients had a confirmative diagnosis from serology and histology. Patients with SNVA had negative CD serology and were not on a gluten free diet at the time of histological diagnosis. They were investigated extensively for other causes of disease including HIV, Tuberculosis, autoimmune enteropathy, giardiasis, Helicobacter pylori, Whipple's disease, Crohn's disease (Aziz et al, 2017; DeGaetani et al, 2013). They underwent a SBCE to assess for features of CD and to rule out other causes of VA. Control patients had normal CD serology and duodenal histology with no evidence of CD. These patients had been referred

for SBCE as a secondary investigation for investigations of gastrointestinal signs and symptoms namely: change in bowel habits, iron deficiency anaemia (IDA), vitamin B12, folate or vitamin D deficiency, persistent nausea and vomiting, bloating, weight loss, fatigue, high inflammatory markers and bleeding per rectum. They also had no significant underlying co-morbidities and had undergone upper and lower gastrointestinal endoscopies that did not reveal the cause of signs and symptoms. They were therefore referred for a SBCE as a second line investigation into their symptoms.

Patients with CD, SNVA and controls were identified by SCZ. Their SBCEs were de-identified and put together in 1 group. These were then read by 2 expert reviewers (RHS and SCZ) (more than 300 capsules per year) who were blinded to each other's findings, to the indication for a SBCE and the histology result from duodenal biopsies. I then analysed the data, calculated Cohen's kappa coefficient (K) and intraclass correlation coefficient (ICC) for features of CD and extent of SB disease respectively. Following this, I formulated a score for severity of CD and calculated the score for the patients in the cohort studied.

### 3.3.2 Duodenal histology

At least 4 biopsy specimens (including a duodenal bulb biopsy) were taken from the duodenum during gastroduodenoscopy according to current guidelines, 2 weeks from SBCE (Ludvigsson et al, 2014; Pais et al, 2008) Histology was classified according to the modified Marsh Criteria in patients with CD and SNVA (Oberhuber et al, 1999). All histological samples were reviewed by 2 expert histopathologists. In the case of discrepancy, a third histopathologist was involved in the adjudication process.

### 3.3.3 Small bowel capsule endoscopy

Each patient was asked to stay on clear fluids for 24 hours before SBCE and to drink 2 litres of Klean-Prep® the day before SBCE. Even though there is some uncertainty about the utility of bowel preparation prior to SBCE, this is the current practice in my centre (Gkolfakis et al, 2018). All patients underwent SBCE using Pillcam SB3 (Medtronic, Minneapolis, USA) (Zwinger et al, 2018).

Details on features of CD were determined by 2 expert SBCE reviewers (>300 capsules /year). Prokinetics were used if the capsule remained in the stomach according to local protocol. SB transit was divided into equal tertiles (Goldstein et al, 2005). Features of CD were recorded by each reviewer for each tertile namely, mosaicism, scalloping and fissuring of folds, nodularity of mucosa, atrophic and hypotrophic mucosa (intermediate) (Biagi et al, 2006) and ulcers. Expert reviewers were also asked to grade overall severity of disease as mild, moderate or severe according to their subjective expert opinion.

In this study, extent of abnormal SB mucosa refers to SB mucosa with macroscopic features of CD.

#### 3.3.4 Ethical considerations

The study protocol was approved by the Yorkshire and the Humber Research Ethics committee (IRAS 232382) on 15/8/2017 and registered with the local research and development department of Sheffield Teaching Hospital NHS Foundation Trust under the registration number STH 19998. All SBCE videos used in this study were de-identified. No additional consent was required for the study with the use of de-identified videos as assessed and approved formally by the Research Ethics Committee. The study protocol conforms to the ethical guidelines of the 1975 Declaration of Helsinki as reflected in a priori approval by the institution's human research committee.

#### 3.3.5 Statistical analysis

Statistical analysis was carried out using SPSS version 23 (IBM Corp. Released 2015. IBM SPSS Statistics for Mac, Version 23.0. Armonk, NY: IBM Corp.). Frequencies, medians were calculated to characterize the cohort of patients studied. Pearson correlation co-efficient was used to determine the relationship between two continuous variables such as extent of affected SB mucosa and patient scores. The Mann-Whitney U test was used to compare two independent, continuous variables and the Kruskal–Wallis test was used to compare multiple independent, continuous variables.

Cohen's kappa co-efficient (K) was used to measure the degree of agreement between the 2 expert reviewers for CD features represented as categorical

variables. Degree of agreement for percentage of affected SB mucosa (continuous variable) was determined by calculating the Intraclass Correlation Co-efficient (ICC). Agreement according to K value was considered as follows: less than 0 indicated poor agreement, 0.00-0.20 slight agreement, 0.21-0.40 fair agreement, 0.41-0.60 moderate agreement, 0.61-0.80 substantial agreement, and 0.81-1.00 almost perfect agreement (Landis & Koch, 1977). Agreement was considered significant if the p value was less than 0.05. A Bland–Altman plot was drawn to demonstrate the difference in scores of percentage extent of disease between reviewers and to show how this differed from the mean. Linear regression was carried out to calculate the degree of proportional bias and its significance.

Multiple regression analysis was carried out to assess the impact of CD features on the extent of abnormal SB mucosa and the weighting (odds ratio) of each of these factors on the extent of abnormal SB mucosa.

Results were considered to be statistically significant if the p value was less than 0.05.

### 3.3.6 Sample size calculation

Currently the sensitivity of SBCE in patients with suspected CD (newly-diagnosed CD and control patients with similar symptoms but normal duodenal histology) on a gluten-containing diet is reported to be approximately 81% (71-93%) (El-Matary et al, 2009; Hopper et al, 2007; Lujan-Sanchis et al, 2017; Murray et al, 2008; Petroniene et al, 2005; Rokkas & Niv, 2012; Rondonotti et al, 2007). In view of the limited literature available in this area, an extrapolation has been carried out on the reported sensitivity for use in this study on a group of patients with newly diagnosed and established CD, SNVA and controls. To improve the sensitivity of SBCE from 81% to 95% by introducing the novel SBCE score, it was estimated that a sample size of 66 patients would be needed to correctly identify patients with CD with 95% power and a 5% two-sided significance level. The number of patients required to reach the 95% power by recruiting more patients was exceeded, thus improving the strength of the study.

### 3.3.7 Establishing the coeliac disease score

Macroscopic features of CD (VA, scalloping of folds, mosaicism, nodularity of mucosa, fissuring of folds, hypotrophic folds, ulcers (Biagi et al, 2006) were initially identified by a panel of expert reviewers. Two expert reviewers, reviewed the SBCEs and findings were recorded as detailed above. Relevance of CD features was assessed by the level of agreement (K) in identifying the macroscopic features of CD between the expert reviewers.

Correlation between CD features and extent of affected SB mucosa was determined by univariate analysis. The relationships between the presence of CD features, extent of affected SB mucosa and overall severity of disease and duodenal histology were determined. These formed the basis for the use of extent of affected SB mucosa as the dependent variable in multiple regression analysis to determine the relationship (odds ratio) between CD features and the extent of affected SB mucosa. Odds ratios for reviewers were then averaged. Odds ratios were recoded into their rank order from smallest to largest using an inbuilt function in SPSS. The rank order function assigned optimal values to the set of values according to the rank of the value in the original dataset. This gave a more favourable value for each CD feature in each SB tertile and made it easy for patient scores to be calculated. Scores for all patients were then calculated. Patient scores were separated into categories depending on the overall severity of disease that had originally been assigned by each reviewer establishing score ranges for mild, moderate or severe disease.

## 3.4 Results

### 3.4.1 Characterization of the study population

300 patients (185 females, 61.7%) were included in this study. Seventy-eight patients (26.0%) had a histological diagnosis of CD (established CD 25, 8.3%; newly diagnosed CD 53, 17.7%). Features of RCD were present in 16 CD (20.5%) (type 1: 12, type 2: 4) patients on histology. Eighteen patients (6.0%) had a diagnosis of SNVA. One patient (0.3%) had underlying common variable immunodeficiency. Three patients (1.0%) responded to a gluten free diet and were therefore diagnosed as having serology negative CD. In the other 14 patients (4.7%) a cause for SNVA was not found despite extensive investigations.

Two hundred and four patients (68.0%) had normal duodenal histology and underwent SBCE for investigation of IDA (100, 49.1%) and other symptoms: constipation 10 (4.9%), low folic acid levels 6 (2.9%), low vitamin B12 levels 15 (7.4%), nausea and vomiting 15 (7.3%), abdominal pain 58 (28.4%), bloating 12 (5.9%), weight loss 23 (11.3%), fatigue 1 (0.5%), high inflammatory markers 3 (1.5%), bleeding per rectum 9 (4.4%).

Median age at the time of SBCE was as follows in both groups: CD 50.5 (2-78 years), SNVA 52.5 years (23-77 years), controls 50.5 (23-82 years), ( $p=0.318$ ). EMA was positive in 30 (38.5%) patients with CD at the time of SBCE. Median anti-TTG was 12.5, 0.1-128 U/ml in patients with CD.

Features on SBCE were recorded by the 2 expert reviewers (Table 3). Features were most commonly present in the proximal SB.

**Table 3: Features of CD on SBCE**

Feature present	Reviewer 1 n (%)		Reviewer 2 n (%)	
	CD / serology negative villous atrophy	Controls	CD / serology negative villous atrophy	Controls
Proximal mosaic pattern	67 (72.0)	1 (0.5)	61 (63.5)	1 (0.5)
Proximal fissuring	81 (87.1)	3 (1.5)	83 (86.5)	1 (0.5)
Proximal scalloping	45 (48.9)	0 (0)	51 (53.1)	0 (0)
Proximal villous atrophy	21 (23.1)	0 (0)	14 (14.6)	0 (0)
Proximal nodularity	17 (18.5)	0 (0)	17 (17.7)	1 (0.5)
Proximal ulcers	7 (7.3)	0 (0)	7 (7.3)	0 (0)
Proximal hypotrophic folds	5 (5.4)	0 (0)	1 (1.0)	0 (0)
Mid mosaic pattern	17 (19.3)	0 (0)	12 (13.2)	0 (0)
Mid fissuring	15 (17.0)	0 (0)	9 (9.9)	0 (0)
Mid scalloping	7 (2.3)	0 (0)	7 (7.7)	0 (0)
Mid villous atrophy	3 (3.4)	0 (0)	/	/
Mid nodularity	4 (4.5)	0 (0)	3 (3.3)	0 (0)
Mid ulcers	3 (3.1)	0 (0)	3 (3.1)	0 (0)
Mid hypotrophic folds	1 (1.1)	0 (0)	/	/
Distal mosaic pattern	4 (4.7)	0 (0)	4 (4.5)	0 (0)
Distal fissuring	3 (3.5)	0 (0)	2 (2.2)	0 (0)
Distal scalloping	2 (2.3)	0 (0)	3 (3.4)	0 (0)
Distal villous atrophy	/	/	/	/
Distal nodularity	1 (1.2)	0 (0)	1 (1.0)	0 (0)
Distal ulcers	4 (4.2)	0 (0)	2 (2.2)	0 (0)
Distal hypotrophic folds	/	/	/	/

### 3.4.2 Interobserver agreement

Features including proximal and distal mucosal fissuring and ulcers in proximal, mid and distal SB had the highest average kappa co-efficient for the 2 expert reviewers. The overall kappa co-efficient for all features was 0.67 (Table 4).

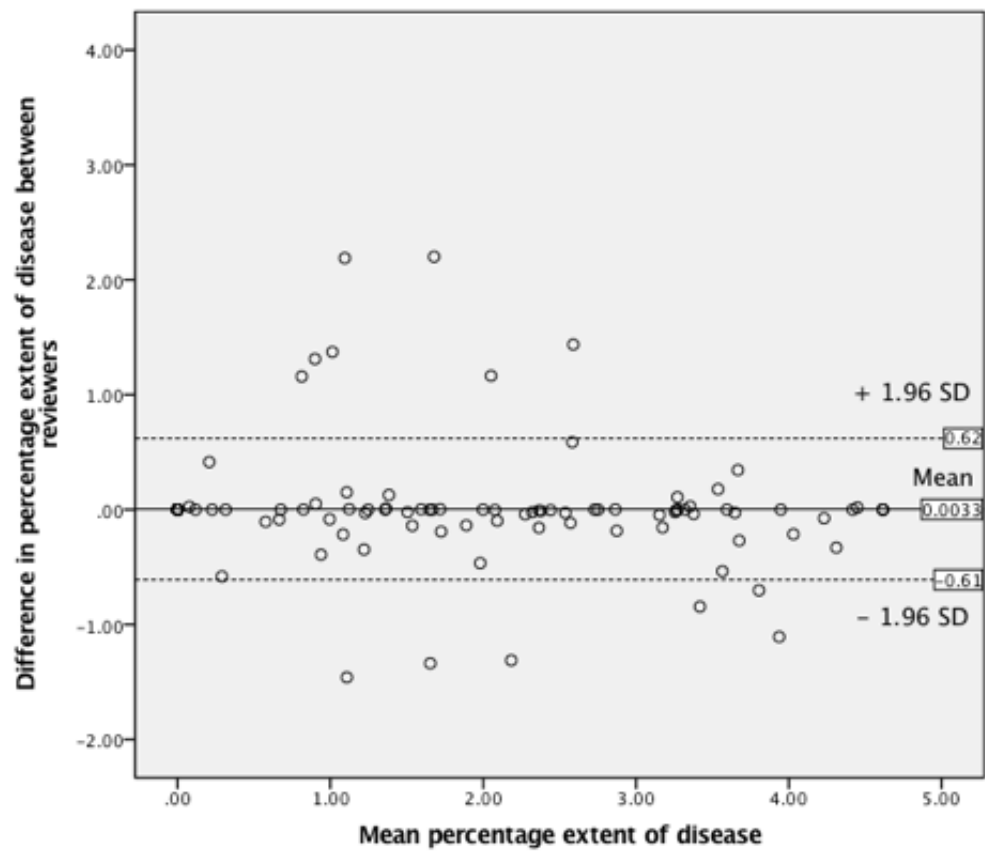
**Table 4:** Correlation analysis of different CD features between the 2 reviewers

Region	Feature	Reviewer 1 & 2	
		Cohen's kappa coefficient	P value
proximal	Continuous / patchy	0.879	0.0001
proximal	Mosaic pattern	0.920	0.0001
proximal	Fissuring	0.958	0.0001
proximal	Scalloping	-0.014	0.535
proximal	Villous atrophy	0.564	0.0001
proximal	Nodularity	0.750	0.0001
proximal	Ulcers	0.607	0.0001
proximal	Hypotrophic fold	0.330	0.0001
mid	Continuous / patchy	0.687	0.0001
mid	Mosaic pattern	0.775	0.0001
mid	Fissuring	0.729	0.0001
mid	Scalloping	0.607	0.0001
mid	Villous atrophy	Perfect match	/
mid	Nodularity	0.566	0.0001
mid	Ulcers	1.0	0.0001
mid	Hypotrophic fold	0.0001	1
Distal	Continuous / patchy	0.631	0.0001
Distal	Mosaic pattern	0.746	0.0001
Distal	Fissuring	0.798	0.0001
Distal	Scalloping	0.798	0.0001
Distal	Villous atrophy	Perfect match	/
Distal	Nodularity	1.0	0.0001
Distal	Ulcers	0.664	0.0001
Distal	Hypotrophic fold	Perfect match	/
Overall kappa		0.67	

The ICC for percentage extent of affected SB mucosa was 0.97 (p=0.0001). There was no proportional bias between the scores of both reviewers in



determining percentage extent of affected SB mucosa (B -0.019; p=0.199) (Figure 15).



**Figure 15:** Bland-Altman plot indicating interobserver agreement for percentage extent of disease between reviewers 1 and 2

### 3.4.3 Correlation of extent of disease

Percentage of affected SB mucosa correlated with the overall severity of disease (Table 5) as classified by each reviewer.

**Table 5:** Percentage of affected small bowel mucosa vs overall severity of disease

Reviewer	Overall severity of disease				Significance / p value
	Normal % (range)	Mild % (range)	Moderate % (range)	Severe % (range)	
1	0	5.28 (9-81.9)	25.6 (0.8-100.0)	88.1 (4.3-100.0)	0.0001
2	0	4.5 (0.1-81.9)	27.8 (15.1-100.0)	49.6 (4.3-100.0)	0.0001

Overall histology correlated with extent (%) of affected SB mucosa (p=0.0001) (Table 6).

**Table 6:** Correlation between extent of affected small bowel mucosa and Marsh classification of disease

	Extent of affected (%) SB mucosa	
	Reviewer 1 extent (%)	Reviewer 2 extent (%)
Marsh 0	0 (0.25.4)	0 (0.25.4)
Marsh 1	1.0 (0-88.1)	0.9 (0.1-28.5)
Marsh 2	/	/
Marsh 3a	6.7 (1.8-26.7)	6.7 (2.3-26.7)
Marsh 3b	4.2 (0.3-100.0)	4.2 (2.1-100.0)
Marsh 3c	70.4 (1.3-86.9)	62.1 (1.3-81.9)

#### 3.4.4 Correlation of features of coeliac disease with extent of disease

On univariate analysis, all features correlated significantly with percentage of affected SB mucosa for both reviewers except for hypotrophic folds in the case of reviewer 2 (Table 7).

**Table 7:** Univariate analysis of features of CD against extent of affected small bowel mucosa.

Reader	Region	Feature	Median % extent of diseases SB (range)		Significance (p value)
			Feature absent	Feature present	
Reviewer 1	proximal	Normal continuous/ patchy /	0 (0)	Continuous 15.2 (0.3-100.0) Patchy 4.0 (0-100.0)	0.0001
Reviewer 1	proximal	Mosaic pattern	0 (0-100.0)	10.5 (0-100.0)	0.0001
Reviewer 1	proximal	Fissuring	0 (0-9.7)	8.5 (0-100.0)	0.0001
Reviewer 1	proximal	scalloping	0 (0-100.0)	13.6 (0.4-100.0)	0.0001
Reviewer 1	proximal	Villous atrophy	0 (0-100.0)	25.2 (6.1-100.0)	0.0001
Reviewer 1	proximal	nodularity	0 (0-100.0)	23.0 (2.3-100.0)	0.0001
Reviewer 1	proximal	ulcers	0 (0-100.0)	61.6 (12.9-100.0)	0.0001
Reviewer 1	proximal	Hypotrophic folds	0 (0-100.0)	25.4 (8.9-62.8)	0.0001
Reviewer 1	mid	Normal continuous/ patchy /	0 (0-88.1)	Continuous 12.9 (8.9-100.0) Patchy 61.6 (10.5-100.0)	0.0001
Reviewer 1	mid	Mosaic pattern	0 (0-88.1)	61.6 (8.9-100.0)	0.0001
Reviewer 1	mid	Fissuring	0 (0-100.0)	44.4 (8.9-100.0)	0.0001
Reviewer 1	mid	scalloping	0 (0-100.0)	26.7 (8.9-100.0)	0.0001
Reviewer 1	mid	Villous atrophy	0 (0-100.0)	37.2 (12.9-61.6)	0.001
Reviewer 1	mid	nodularity	0 (0-100.0)	57.4 (12.9-100.0)	0.0001
Reviewer 1	mid	ulcers	0 (0-100.0)	88.1 (61.6-100.0)	0.0001
Reviewer 1	mid	Hypotrophic folds	0 (0-100.0)	/	/
Reviewer 1	distal	Normal continuous/ patchy /	0 (0-88.1)	Continuous / Patchy 90.9 (61.6-100.0)	0.0001
Reviewer 1	distal	Mosaic pattern	0 (0-100.0)	100.0 (81.9-100.0)	0.0001
Reviewer 1	distal	Fissuring	0 (0-100.0)	/	0.001
Reviewer 1	distal	scalloping	0 (0-100.0)	/	0.002
Reviewer 1	distal	Villous atrophy	0 (0-100.0)	/	/
Reviewer 1	distal	nodularity	0 (0-100.0)	/	0.014
Reviewer 1	distal	ulcers	0 (0-100.0)	88.1 (61.6-100.0)	0.0001
Reviewer 1	distal	Hypotrophic folds	0 (0-100.0)	/	/
Reviewer 2	proximal	Normal continuous/ patchy /	0 (0-8.53)	Continuous 10.5 (0.7-100.0) Patchy 3.7 (0.1-100.0)	0.0001
Reviewer 2	proximal	Mosaic pattern	0 (0-100.0)	10.5 (0.5-85.3)	0.0001
Reviewer 2	proximal	Fissuring	0 (0-8.53)	7.0 (0-100.0)	0.0001
Reviewer 2	proximal	scalloping	0 (0-100.0)	10.9 (0.4-85.3)	0.0001
Reviewer 2	proximal	Villous atrophy	0 (0-100.0)	17.9 (3.6-30.6)	0.0001
Reviewer 2	proximal	nodularity	0 (0-81.9)	26.7 (1.8-100.0)	0.0001
Reviewer 2	proximal	ulcers	0 (0-100.0)	30.6 (0.4-100.0)	0.0001
Reviewer 2	proximal	Hypotrophic folds	0 (0-100.0)	/	0.197
Reviewer 2	mid	Normal continuous/ patchy /	0 (0-36.9)	Continuous 85.3 (8.5-100.0) Patchy 63.7 (49.6-100.0)	0.0001
Reviewer 2	mid	Mosaic pattern	0 (0-36.9)	65.2 (8.5-100.0)	0.0001
Reviewer 2	mid	Fissuring	0 (0-100.0)	62.1 (8.5-100.0)	0.0001
Reviewer 2	mid	scalloping	0 (0-100.0)	50.8 (8.5-100.0)	0.0001
Reviewer 2	mid	Villous atrophy	0 (0-100.0)	/	/
Reviewer 2	mid	nodularity	0 (0-100.0)	85.3 (28.5-100.0)	0.0001
Reviewer 2	mid	ulcers	0 (0-100.0)	49.6 (28.5-100.0)	0.0001
Reviewer 2	mid	Hypotrophic folds	0 (0-100.0)	/	/
Reviewer 2	distal	Normal continuous/ patchy /	0 (0-85.3)	Continuous 100.0 (4.3-100.0) Patchy /	0.0001
Reviewer 2	distal	Mosaic pattern	0 (0-85.3)	100.0 (81.9-100.0)	0.0001
Reviewer 2	distal	Fissuring	0 (0-100.0)	/	0.010
Reviewer 2	distal	scalloping	0 (0-100.0)	52.1 (4.3-100.0)	0.001
Reviewer 2	distal	Villous atrophy	0 (0-100.0)	/	/
Reviewer 2	distal	nodularity	0 (0-100.0)	/	0.014
Reviewer 2	distal	ulcers	0 (0-100.0)	52.1 (4.3-100.0)	0.010
Reviewer 2	distal	Hypotrophic folds	0 (0-100.0)	/	/

The multivariate regression analysis showed a statistically significant correlation of CD features with extent of affected SB mucosa for both reviewers ( $p < 0.05$ ). The odds ratios obtained for each feature affecting the percentage of affected SB mucosa was utilized to generate a score for features of CD on SBCE.

#### 3.4.5 Establishing the coeliac disease score

The OR for both reviewers was averaged to obtain an overall OR for each feature. Where the feature was not statistically significant for one reviewer, the OR of the other reviewer that was statistically significant, was considered. Some of the features of CD such as proximal nodularity of the mucosa were statistically not significant for both reviewers. However, they were still considered as part of the final score to ensure stability of the overall score as all features can be present in all 3 SB tertiles. Ranks were then used to optimize the overall OR resulting in a better score (Table 8).

**Table 8:** The coeliac disease score

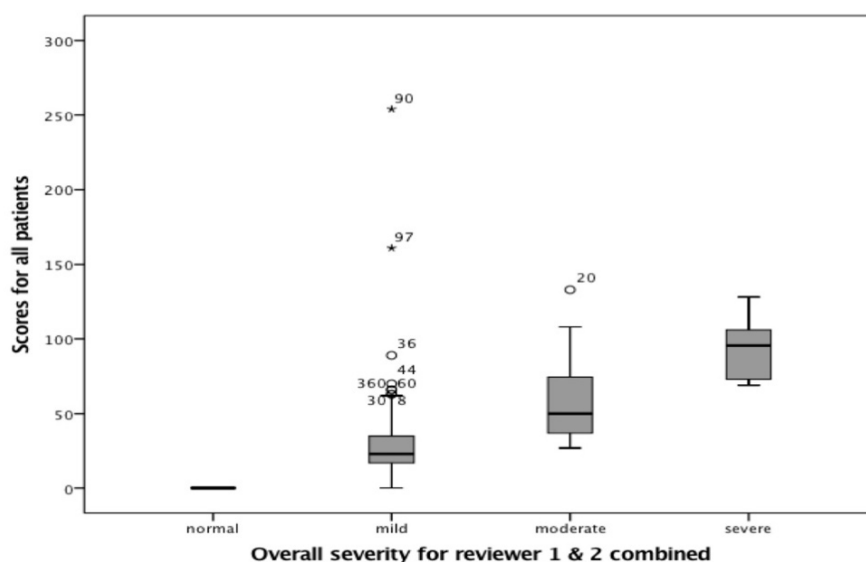
	Feature	Reviewer 1 & 2 average OR	Ranks to optimise score*
1	Proximal mosaic pattern	8	12
2	Proximal fissuring	3	10
3	Proximal scalloping	-3	5
4	Proximal villous atrophy	10	13
5	Proximal nodularity	1	8
6	Proximal ulcers	14	14
7	Proximal hypotrophic folds	15	16
1	Mid mosaic pattern	31	19
2	Mid fissuring	15	15
3	Mid scalloping	-25	2
4	Mid villous atrophy	-67	1
5	Mid nodularity	17	17
6	Mid ulcers	-12	3
7	Mid hypotrophic folds	1	9
1	Distal mosaic pattern	51	21
2	Distal fissuring	45	20
3	Distal scalloping	-10	4
4	Distal villous atrophy	0	7
5	Distal nodularity	4	11
6	Distal ulcers	18	18
7	Hypotrophic folds	0	7

Odds ratio (OR)

\*Numbers in this column were used to score severity of disease

### 3.3.6 Overall scores

The overall scores for patients studied were calculated. The overall scores correlated with extent of affected SB mucosa for reviewer 1 (Pearson correlation co-efficient 0.662,  $p=0.001$ ) and 2 (Pearson correlation co-efficient 0.838,  $p=0.001$ ). Assessing the scores of patients according to the overall severity of disease graded independently by reviewers, there was a statistically significant difference between categories (mild /moderate /severe) (both  $p=0.0001$ ). The 25<sup>th</sup> and 75<sup>th</sup> percentiles of each category was used as the upper and lower score value for each category: normal (0), mild (1-35), moderate (36-75) and severe (>76) (Figure 16).



**Figure 16:** Scores of patients for reviewers 1 and 2 combined according to the overall severity of disease

### 3.5 Discussion

In this study the validity of the common nomenclature used to refer to features of CD was highlighted and assessed. There was good IOA between experts and a good correlation with histology. This is also the first study to quantify changes of CD within a standardized scoring system.

Similar to the study by Murray et al (Murray et al, 2008) it has been shown that agreement can vary according to CD features. I have also gone a step further in analyzing the IOA for different features in each SB tertile. The same group of

authors also report the IOA of affected SB mucosa (Lin's concordance correlation coefficient 0.92) (Murray et al, 2008). In my study the ICC for affected SB mucosa was also similarly high confirming that extent of CD can be delineated by expert reviewers. The Bland-Altman plot shows the distribution of differences in scores between reviewers with most points lying close to the mean and between the upper and lower limits of agreement. The same plot also shows that interobserver agreement may be higher for more extensive disease as the points are less spread out than for shorter extent of disease (Figure 15).

The gold standard for diagnosing CD is histology from the duodenum (Ludvigsson et al, 2014). This offers only a limited insight of CD in the SB. CD can affect the SB mucosa in a discontinuous manner resulting at times in biopsies from normal SB mucosa that will not represent the true occurrence of disease (Hopper et al, 2008). It can also present a challenge on repeating duodenal biopsies to assess improvement of disease activity following treatment. Features of CD, although well recognized are not standard and not uniformly used by reviewers of SBCE. The CD score will provide a more objective way of quantifying mucosal features of CD throughout the SB. It can enable comparison of severity of CD between patients. The score would be useful to assess for mucosal healing in response to therapy in patients with RCD who have received immunosuppressants (Chetcuti Zammit et al, 2019a). This is a new concept in RCD. It can also be helpful for trainees/ reviewers with a low experience SBCEs. The likelihood of patients having CD can also be determined in patients with equivocal duodenal histology similar to determining the likelihood of underlying Crohn's disease in patients with subtle ulcers (Rosa et al, 2012). However, at diagnosis, the CD SBCE score cannot be used as a solitary test to diagnose CD. It must be used in conjunction with CD serology and histology to give a more complete picture of the likelihood of patients having CD. This score cannot distinguish between the different causes of VA but can quantify disease activity. This can be useful in patients with SNVA where the diagnosis of CD is equivocal. SBCE in this group of patients can help substantiate the diagnosis in serology negative CD. It can also help identify features of Crohn's disease that can present with VA such as circumferential ulceration and a predominance of distal mucosal abnormalities rather than proximal mucosal changes that are commonly found in patients with CD (Kurien et al, 2013; Pennazio et al, 2015).



Reviewers were blinded to the results of the underlying duodenal histology and to each other's results. Another strong point of this study is the inclusion of control patients with negative duodenal histology and patients with SNVA. This increased the reliability of the study and of reviewers detecting features of CD. The inclusion of a group of patients with SNVA in the formulation of the score, will allow its use in these patients irrespective of the underlying cause. Unlike the Lewis score, the CD score is a simple score that takes into consideration features along the entire SB and only requires the addition of scores to obtain a final overall score (Gralnek et al, 2008). Given its simplicity to calculate, the CD score can be calculated manually by experts whilst reviewing SBCEs.

One limitation of the study was that this was a single centre study with a high volume of SBCEs based on the expert opinion of 2 reviewers. Although other studies included more than 2 reviewers, the number of patients in these studies was small (Table 9). In my study these limitations have been overcome by including a larger cohort of patients with CD, SNVA and control patients. In addition, the range of scores of severity (mild / moderate / severe) onto which severity scores were based, were determined by expert reviewers. Overall disease activity was therefore subjective and dependent on the opinion of each expert reviewer. Basing the scores of severity of CD features on other characteristics such as symptoms and CD serology would have made the score even more subjective as it is known from current literature that there is a poor correlation between these features and extent of disease on SBCE (Murray et al, 2008; Petroniene et al, 2005; Rondonotti et al, 2007; Silvester et al, 2017). In order to build up the score of severity of disease, SB tertiles were considered and features of CD in each tertile were scored. However the implication for this is that we relied on the assumption that SB tertiles were equally split, based on the total SB transit and on the fact that both reviewers assumed equal lengths for each tertile. On validation of the score of severity in a separate study in another group of patients, the concept of ensuring tertiles have the same length between reviewers can be addressed. Another interesting aspect would be to look at intraobserver agreement for each reviewer. This will enable us to check how scores for features of CD vary amongst tertiles for the same reviewer. Another limitation is the overall lower kappa co-efficient for the detection of CD features

between reviewers (0.67) when compared to the higher agreement for extent of affected SB mucosa (0.97). This reflects the heterogenous nature of CD that can present as a variety of macroscopic features that might not be easy to delineate.

**Table 9:** Studies on interobserver agreement between duodenal histology and CD findings on SBCE and between different reviewers of SBCE

Authors	Year	Number of reviewers	Number of patients	Kappa co-efficient of SBCE with histology	Kappa co-efficient of SBCE findings between reviewers
(Petroniene et al, 2005)	2005	4 (2 with, 2 without pre-study experience)	20 (10 CD)		0.2 – poor pre study experience, 1.0 – good pre-study experience;
(Biagi et al, 2006)	2006	3	36 (26 CD)	0.45, 0.49, 0.51	0.49, 0.67, 0.70
(Rondonotti et al, 2007)	2007	4	43 (32 CD)		Overall: 0.56 – 0.87; erosions (0.27 – 0.72, scalloping (0.65 – 0.85)
(Maiden et al, 2009)	2007	1	19 CD	0.65	
(Murray et al, 2008)	2008	2	38 CD		0.37 – atrophy; 0.41 – fissuring; 0.59 – scalloping, 0.77 – mosaic pattern
(Barret et al, 2012)	2012	1	83 (38 CD)	0.45 (better than optic endoscopy 0.24, p=0.001)	

Small bowel capsule endoscopy (SBCE), coeliac disease (CD), refractory coeliac disease (RCD);

### 3.6 Conclusions

This study proposes a novel scoring system for changes of CD using SBCE with good IOA between expert reviewers. It has the potential to be utilised for standardization of reporting of SBCE in CD and in monitoring of response to treatment (steroids and / or immunosuppressants) in patients with RCD. Additional studies are needed to validate this score in patients with suspected CD, established CD, those with SNVA and in RCD patients. These studies can also confirm the validity of severity of disease scores that have been suggested in this study.

## **Chapter 4 – The use of Flexible Spectral Imaging Colour Enhancement (FICE) in coeliac disease**

### 4.1 Abstract

#### 4.1.1 Objectives

Flexible Spectra Imaging Colour Enhancement (FICE) is a form of virtual chromoendoscopy that is incorporated in the capsule reading software and that can be used by reviewers to enhance the delineation of lesions in the small bowel. This has been shown to be useful in the detection of pigmented (ulcers, angioectasias) lesions. However, its application to coeliac disease (CD) images from small bowel capsule endoscopies (SBCEs) has rarely been studied.

#### 4.1.2 Methods

This was a European, multicentre study that included 5 expert capsule reviewers who were asked to evaluate a number of normal and abnormal deidentified images from SBCEs of patients with CD to determine whether the use of FICE and blue light can improve the detection of CD related changes.

#### 4.1.3 Results

Sensitivity and specificity of conventional white light in the delineation of CD related changes were 100%. The next best image modification was FICE 1 with a sensitivity of 80% and a specificity of 100%. There was no difference between conventional white light, FICE and blue light for the identification of CD related changes. There was a low agreement (Fleiss Kappa 0.107;  $p=0.147$ ) between expert reviewers in selecting the best image modification that detected CD related changes.

#### 4.1.4 Conclusions

FICE and blue light were not found to be superior to conventional white light in the delineation of macroscopic changes related to CD on SBCEs.

### 4.2 Introduction

Although most guidelines on adult CD recommend gastroduodenoscopy and duodenal biopsies in patients with positive CD serology and suggestive symptoms (Downey et al, 2015; Ludvigsson et al, 2014), some patients are unwilling to undergo this procedure to establish a definitive diagnosis of CD. SBCE can play a useful role in this cohort of patients (Hopper et al, 2007). Even in patients undergoing a gastroduodenoscopy and duodenal biopsies, pitfalls in the diagnosis of CD still exist mainly due to the patchy nature of CD (Green, 2008; Hopper et al, 2008; Pais et al, 2008). Unless at least 4 biopsy specimens (including a duodenal bulb biopsy) are taken from the duodenum (Ludvigsson et al, 2014; Pais et al, 2008) and the samples are properly oriented during preparation for histological assessment (Collin et al, 2005), duodenal biopsy sampling may be sub-optimal. These factors establish a further role for SBCE in patients with a high suspicion of CD but negative duodenal histology, due to its panoramic underwater view that magnifies changes in the SB and improves delineation of lesions.

Over the years, attempts have been made to improve the detectability of pathological lesions on SCBE. One such modality is the application of FICE, a form of virtual chromoendoscopy. It can be applied to images from SBCE by adjusting settings on the RAPID reading software (Sato et al, 2014). As the capsule travels through the SB, images in the white light spectrum are captured. Post-production computer algorithms then select single wavelength images in the red, green and blue spectra to reconstruct FICE enhanced images (Fedeli et al, 2011; Togashi et al, 2009). The aim is to improve the detection of mucosal changes such as the delineation of SB vessels, enhance the resolution of mucosal patterns and augment colour differences (Pohl et al, 2007). Blue light is an additional image-enhancing setting available on the RAPID software that enables light in the wavelength range of 490–430nm to be picked up from white light images.

Macroscopic changes of CD occur secondary to different degrees of VA resulting in scalloping of folds, fissuring and mosaic pattern of mucosa. Other features include complete absence of villi giving the appearance of VA. Ulcers can also be present at times (Biagi et al, 2006; Tursi et al, 2002). These changes can be identified on conventional white light SBCE. However, the detection of findings

can be challenging due to subtle changes only affecting the duodenal bulb in ultra-short CD (Mooney et al, 2016). The manifestation of CD is also often patchy in nature (Hopper et al, 2008). Image modification to enhance features of CD may help the delineation of CD related changes particularly for novice SBCE reviewers. There is only one study that reports on the use of FICE for the detection of changes related to CD in the SB. However, only one macroscopic feature – VA was studied and the same cohort included patients with other pathologies apart from CD (Cotter et al, 2014). My study is the first to report on the utility of FICE and blue light in a cohort of patients with CD alone on SBCE.

The sensitivity of SBCE in detecting CD related changes is reported to be as low as 70% in some studies (Petroniene et al, 2005). The sensitivity of SBCE depends on the reviewer's pre-study experience declining when the reviewer's pre-study experience is low (Petroniene et al, 2005). Changes related to CD in the small bowel can vary from very mild to more severe features. Subtle changes can contribute to decreasing the sensitivity of SBCE to detect CD related changes. The aim of this study was to assess whether there is any additional benefit in using FICE or blue light over conventional white light for the detection of changes related to CD on SBCE.

#### 4.3 Methods

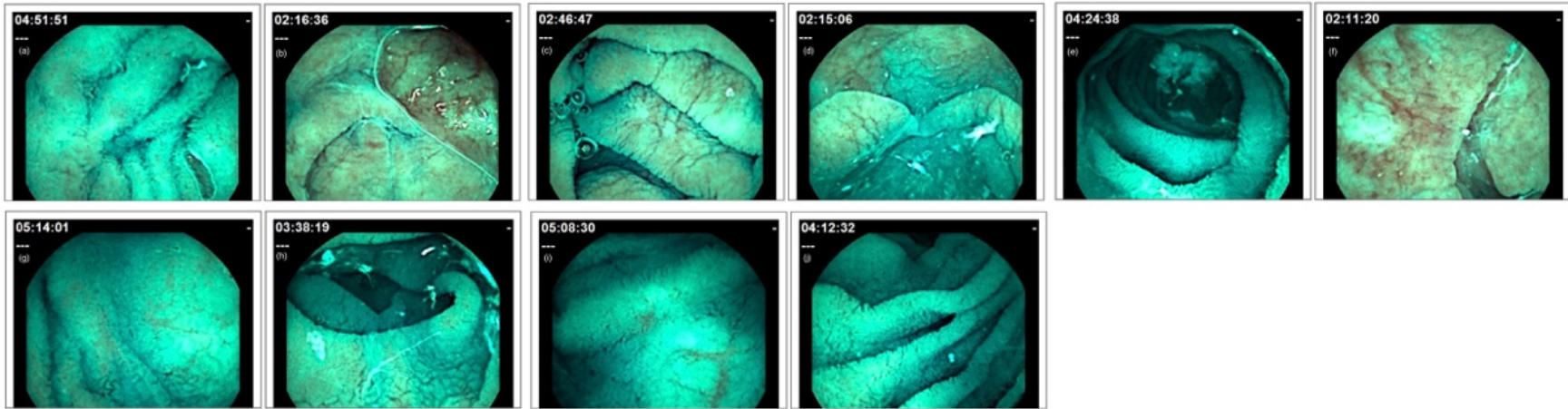
##### 4.3.1 Patients and methods

This was a multicentre, European study that included 5 expert capsule endoscopy reviewers (more than 300 capsules per year). They were asked to evaluate a number of deidentified images from SBCEs of patients with confirmed CD on duodenal histology to determine whether the use of FICE and blue light can improve the detection of CD related changes on SBCE. Features of CD on SBCE images and normal SBCE images were initially identified and features of CD confirmed by 2 expert SBCE reviewers (more than 300 capsules per year). These 2 expert reviewers (including myself) involved in the initial preparation of the images, were not involved in the actual study. Findings on these images were then set as the standard to which results from each reviewer were compared to. Features of CD included: 1: scalloping of the mucosa, 2: fissuring of folds, 3:

mosaic pattern, 4: VA, 5: nodularity of mucosa. The reviewers were blinded to each other's findings and to the histological Marsh classification of disease.

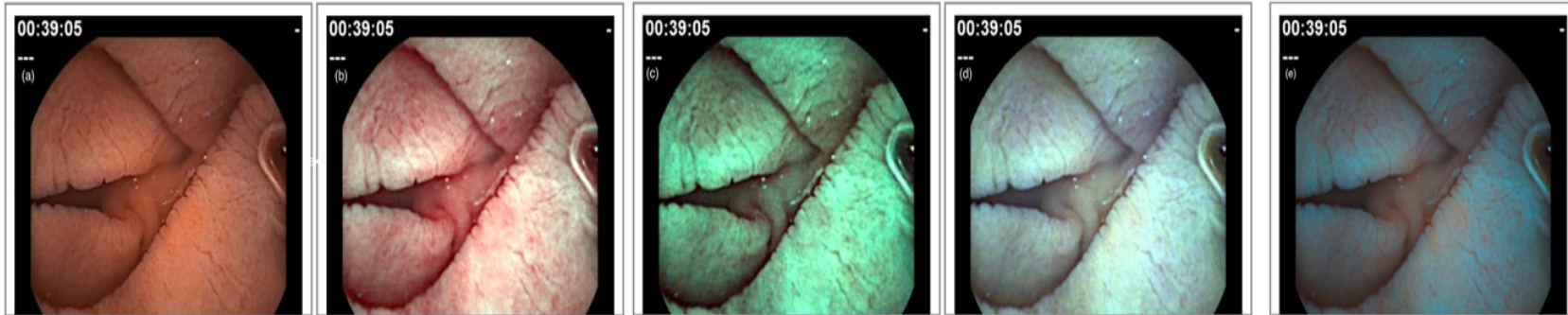
In the first part of the study, the reviewers were asked to examine a set of 50 images consisting of both normal (25) SB images and 25 images showing CD-related changes. Conventional white light, FICE I, II, III and blue light were represented in one question each in this section. Each question, consisted of 5 normal and 5 abnormal images from the SBCE of the same patient (Figure 17). The reviewers were asked to pick up abnormal images (Which images show features of coeliac disease?). Depending on the number of abnormal images correctly picked up by each reviewer, the sensitivity and specificity of conventional white light, different FICE settings and blue light were calculated.





**Figure 17:** Images on small bowel capsule endoscopy modified by FICE ((b), (c), (d), (f), (h) show features of coeliac disease, (a), (e), (g), (i), (j) are normal images;)

In the second part of the study, reviewers were asked to go through 55 abnormal images (11 questions) and to compare between conventional white light, different FICE (I, II, III) settings and blue light as the best modality to delineate changes of CD on SBCE. Each question consisted of abnormal images in conventional white light, different FICE settings or blue light (Figure 18). Images showed either moderate (5 questions), severe features of CD (5 questions) or ulcers (1 question). Severity of features on each image, were pre-determined by an expert SBCE reviewer (>300 capsules / year) before the commencement of this study depending on the presence of patchy / continuous pattern and prominence of lesions. This was confirmed by a second SBCE reviewer (>300 capsules / year). The interobserver agreement between reviewers was then calculated.



**Figure 18:** Fissuring of mucosa in a patient with coeliac disease on small bowel capsule endoscopy: (a) conventional white light; (b) FICE 1; (c) FICE 2; (d) FICE 3; (e) blue light

#### 4.3.2 Ethical approval

The study protocol was approved by the Yorkshire and the Humber Research Ethics committee (IRAS 232382) and registered with the local research and development department of Sheffield Teaching Hospital NHS Foundation Trust under the registration number STH 19998. All images used in this study were deidentified. No additional consent was required for the study with the use of deidentified videos as assessed and approved formally by the Research Ethics Committee.

#### 4.3.3 Statistical analysis

IBM SPSS Statistics version 23 and Microsoft Excel for Mac version 16.16.4 were used to analyse the data. Frequencies of choice were calculated for each expert reviewer. Fleiss' kappa co-efficient (K) was used to measure the degree of agreement amongst the 5 reviewers. Agreement according to K value was considered as follows: less than 0 indicated poor agreement, 0.00-0.20 slight agreement, 0.21-0.40 fair agreement, 0.41-0.60 moderate agreement, 0.61-0.80 substantial agreement, and 0.81-1.00 almost perfect agreement (Landis & Koch, 1977). A significance level of more than 0.05 ( $p > 0.05$ ) meant that there was not enough evidence to conclude that the reviewers' agreement was different from what would be expected to be achieved by chance.

Contingency tables were also constructed to calculate the sensitivity and specificity of conventional white light, different FICE settings and blue light.

#### 4.3.4 Power Calculation

Currently the sensitivity of SBCE in detecting CD related changes using conventional white light, varies between 70 and 93% (El-Matary et al, 2009; Hopper et al, 2007; Lujan-Sanchis et al, 2017; Murray et al, 2008; Petroniene et al, 2005; Rokkas & Niv, 2012; Rondonotti et al, 2007). To improve the sensitivity of SBCE from the lowest recorded value of 70.0% to 93.0% by the introduction of FICE on reviewing SBCE images, (using G Power) it was estimated that a sample size of 28 would be needed to correctly identify changes of CD with 95% power and a 5% two-sided significance level. The required number to reach the 95% power in both sections of the study has been exceeded.

My study is the first to report on the utility of FICE and blue light in a cohort of patients with CD alone on SBCE.

#### 4.4 Results

All patients had duodenal atrophy (Marsh 3a: 18.8% (n=3), Marsh 3b: 50% (n=8), Marsh 3c: 31.3% (n=5)) on biopsies taken from the second part of the duodenum. All reviewers identified the abnormal images in conventional white light resulting in 100% sensitivity and specificity. FICE 1 had the next best sensitivity in the identification of abnormal images followed by sensitivities for FICE 2 and FICE 3. Blue light had the lowest sensitivity in detecting features of CD (Table 10).

**Table 10:** Reviewer sensitivities and specificities, mean sensitivity and specificity for normal light, FICE and blue light.

	Conventional white light	FICE 1	FICE 2	FICE 3	Blue light
Reviewer 1	100%	80%	60%	0%	40%
Reviewer 2	100%	80%	100%	100%	60%
Reviewer 3	100%	80%	60%	60%	20%
Reviewer 4	100%	60%	60%	40%	20%
Reviewer 5	100%	100%	100%	100%	100%
Mean sensitivity	100%	80%	76%	60%	48%
Reviewer 1	100%	100%	100%	100%	100%
Reviewer 2	100%	100%	100%	100%	100%
Reviewer 3	100%	100%	100%	100%	100%
Reviewer 4	100%	100%	80%	60%	80%
Reviewer 5	100%	100%	100%	100%	100%
Mean specificity	100%	100%	96%	92%	96%

Although FICE 1 and 2 were the most popular settings chosen by reviewers to delineate changes of CD in the second section, there was no statistically significant difference between reviewers ( $p=0.193$ ) (**Table 11**).

**Table 11:** Favoured modality of normal light or different FICE settings by all the 5 reviewers

Severity of changes		Conventional white light n (%)	FICE 1 n (%)	FICE 2 n (%)
Mild	1. Which capsule endoscopy image shows fissuring of the mucosa best?	0	4 (80)	1 (20)
	2. Which capsule endoscopy image shows scalloping of the mucosa best?	1 (20)	1 (20)	0
	3. Which capsule endoscopy image shows villous atrophy best?	1 (20)	3 (60)	0
	4. Which capsule endoscopy image shows nodularity of the mucosa best?	0	3 (60)	2 (40)
	5. Which capsule endoscopy image shows mosaic pattern of the mucosa best?	1 (20)	0	1 (20)
Moderate	6. Which capsule endoscopy image shows fissuring of the mucosa best?	0	3 (60)	2 (40)
	7. Which capsule endoscopy image shows scalloping of the mucosa best?	1 (20)	3 (60)	1 (20)
	8. Which capsule endoscopy image shows villous atrophy best?	0	5 (100)	0
	9. Which capsule endoscopy image shows nodularity of the mucosa best?	1 (20)	1 (20)	3 (60)
	10. Which capsule endoscopy image shows mosaic pattern of the mucosa best?	1 (20)	1 (20)	3 (60)
Ulcers	11. Which image shows ulceration of the mucosa best?	0	4 (20)	1 (20)

The low overall K (K 0.107; p=0.147) was consistent with poor correlation of the preferred modality amongst different expert reviewers (Table 12). The overall K were similarly low for moderate (K=0.107; p=0.147) and severe (K=0.107; p=0.147) changes of CD. The K was low even when considered separately for different light settings and it was not statistically significant in all cases (conventional white light K=-0.122, p=1.801, FICE I K=0.189, p=0.148, FICE II K=0.149, p=0.255). None of the reviewers favoured FICE 3 and blue light.

Therefore these have been left out of Table 12. and Table 13. This also means that the K could not be calculated for FICE 3 and blue light.

**Table 12:** Fleiss' Kappa co-efficient for normal light and FICE settings

	Total	Conventional white light	FICE 1	FICE 2
K	0.107	-0.122	0.189	0.149
Standard error	0.073	0.095	0.129	0.129
Z	1.451	-1.284	1.447	1.151
P	0.147	1.801	0.148	0.250
Lower	-0.037	-0.309	-0.066	-0.104
Upper	0.250	0.064	0.440	0.402

#### 4.5 Discussion

This study confirms that FICE and blue light do not have any additional benefit in helping the delineation of CD changes on SBCE when compared to conventional white light.

Dye chromoendoscopy has been utilised in the context of IBD surveillance to help the visualisation of subtle lesions and to define surface staining patterns enabling targeted biopsies to be taken (Sekra et al, 2018). Virtual chromoendoscopy has been applied to identifying adenomatous polyps and areas of dysplasia during upper gastrointestinal endoscopy and in helping the identification of polyps during colonoscopy (Akarsu et al, 2017; Lami et al, 2017). It has also been shown to be useful in detecting high grade dysplasia in Barrett's epithelium (Camus et al, 2012).

The use of FICE to aid reporting of SBCE has been widely debated in the context of SB ulcers and vascular lesions. FICE can improve the detection of ulcerative lesions by highlighting inflammatory halos and increasing the contrast between pathological areas and surrounding mucosa (Cotter et al, 2014; Duque et al, 2012; Konishi et al, 2014; Nogales Rincón et al, 2013; Rimbaş et al, 2015; Sakai et al, 2012; Sato et al, 2014). Whilst some early studies showed that FICE

performed better than conventional white light for the detection of SB ulcers, other studies have contradicted this finding (Boal Carvalho et al, 2016).

FICE has also been studied for the detection of angioectasias with some studies showing benefit (Boal Carvalho et al, 2016; Cotter et al, 2014; Duque et al, 2012; Imagawa et al, 2011; Nogales Rincón et al, 2013; Sakai et al, 2012; Sato et al, 2014). This is because it improves the detection of light in certain spectrums that is absorbed by haemoglobin. In two studies on patients with occult gastrointestinal bleeding, patients with negative SBCEs in standard view were enrolled. FICE was able to detect significant lesions in 5.8 to 21% of patients (Dias de Castro et al, 2015; Minami-Kobayashi et al, 2016). However FICE has been shown to have a high false positive rate in the delineation of angioectasias (Nakamura et al, 2012).

This is the first and largest study on the use of FICE and blue light to help delineate changes related to CD on SBCE. In this study, experts were asked to determine which FICE setting, blue light or conventional white light was the best modality to detect mucosal abnormalities. Both FICE and blue light were inferior to conventional white light in detecting CD changes on SBCE images. The calculation of sensitivity and specificity of FICE add further to the current evidence on FICE when compared to conventional white light. The sensitivity and specificity of detecting SB pathologies using FICE were similar to conventional white light in a study by Kobayashi et al (Kobayashi et al, 2012). Similarly, the sensitivity and specificity of FICE in detecting CD related lesions in this study were similar in the case of FICE 1, 2 and 3 but inferior to conventional white light.

The low K co-efficient confirms the lack of agreement between reviewers to favour any FICE settings or blue light in the detection CD changes on SBCE. K co-efficient was low irrespective of the severity of CD changes on SBCE suggesting that FICE will not help increase the detection of CD changes on SBCE even if the changes are subtle.

My findings on the use of FICE on SBCE images to help detect features of CD, reflect literature previously published on the use of dye chromoendoscopy during gastroduodenoscopy to improve the detection of macroscopic features of CD



(Johnston et al). In the study by Johnston et al, chromoendoscopy identified an additional number of patients with CD (54% with chromoendoscopy vs 42% on normal endoscopy) on gastroduodenoscopy. However the sensitivity of chromoendoscopy was by far inferior to the sensitivity of CD serology (89% anti-TTG, 78% for EMA). Thus, it was concluded that chromoendoscopy could not be recommended for routine clinical practice during gastroduodenoscopy in patients with suspected and established CD.

One limitation of this study is the exclusion of mild macroscopic CD related changes due to the assumption that these would have been much harder to delineate, thus impacting negatively on the degree of agreement between expert reviewers. It was assumed that all the expert reviewers had the same pre-study experience of reviewing SBCEs from patients with CD. Inclusion of a section prior to this study, with images to ensure familiarisation of expert reviewers with macroscopic CD related changes on SBCEs might have resulted in an improvement in the agreement between reviewers.

In a recent meta-analysis, the delineation of SB pathologies using FICE was studied (Yung et al, 2017). The meta-analysis included 3 studies that assessed the improvement in delineation of lesions and 5 studies that evaluated the detection of lesions. Overall, FICE did not help to improve the detection of SB lesions except for pigmented lesions where FICE performed better. FICE 1 setting improved the delineation of 89% of angioectasias and 45% of ulcers and erosions. The recently published ESGE technical guidelines (Rondonotti et al, 2018) do not recommend the routine use of virtual chromoendoscopy during SBCE as this does not improve the delineation of lesions. This statement mainly refers to vascular and ulcerative lesions, since studies referring to images taken from SBCE of patients with CD are lacking.

Only one group of authors have studied the role of FICE in the detection of CD related changes. Two gastroenterologists, blinded to each other's results, were asked to rank the quality of delineation of SB pathologies as better, equivalent or worse than conventional white light. FICE 1 and 2 improved the detection of villous atrophy (VA) with a high K between expert reviewers (Cotter et al, 2014). There are considerable differences between the way this study was conducted

and the methodology I utilised. Cotter et al, included other SB pathologies in their study apart from CD-related changes including angioectasias and ulcers unlike in my case where the main focus was on CD. Cotter et al only considered oedema and VA but did not assess the effect of FICE on the delineation of other macroscopic features of CD. They also asked reviewers to grade FICE images as better, equivalent or worse compared to conventional white light unlike in my case where a comparison of different FICE settings and conventional white light was done for each question. Having only 2 images to study might explain the much higher K values obtained in this study unlike in my study where the agreement between reviewers was very poor. In addition, a greater number of expert reviewers were included in my study.

Narrowing the bandwidth with FICE enhances the hypervascularity of lesions. Most of the macroscopic changes of CD occur due to various degrees of villous shortening and not due to vascular changes (Pohl et al, 2010). This can explain the lack of additional benefit of FICE on SBCE in patients with CD.

Data on the use of FICE and blue light is very sparse and at times contradictory. Some studies evaluate the use of FICE on multiple pathologies that can exist in the SB resulting in evaluation of virtual chromoendoscopy in even smaller groups of patients. Authors have used different methodologies to evaluate the use of FICE, making it harder to compare results between studies and questioning further the utility of FICE.

Despite the negative results of this study, the results are useful as they add to the limited literature that is available on the use of FICE on SBCE in suspected CD. They provide evidence that there is no additional benefit for gastroenterologists to rereview SBCE in different FICE settings or blue light after reviewing the SBCE using conventional white light when the suspicion of CD is high. The use of FICE will not help the detection of subtle CD related changes by novice SBCE reviewers.

#### 4.6 Conclusions

This study has demonstrated that amongst five expert SBCE reviewers, FICE settings and blue light were not better than conventional white light in the identification of macroscopic changes of CD. Reviewing SBCE images with different FICE settings where CD is suspected, will not help to delineate these changes better

## **Chapter 5 - Small bowel capsule endoscopy in patients with newly diagnosed coeliac disease**

### 5.1 Abstract

#### 5.1.1 Background

The relationship between symptomatology, serology and findings on small bowel capsule endoscopy (SBCE) in patients with coeliac disease (CD) remains unclear. Clarifying such associations will help determine if symptoms and serology can predict severity and extent of disease on SBCE.

#### 5.1.2 Methods

Patients with newly diagnosed CD (villous atrophy on duodenal histology and positive CD serology) were recruited. Patients underwent a SBCE at the time of diagnosis. Information on SBCE was recorded. Signs and symptoms at presentation, serological markers, and histological classification of the disease in the duodenum were noted.

#### 5.1.3 Results

Sixty patients with newly diagnosed CD (mean age 44.9 years  $SD \pm 17.4$ , 17 - 76) were included in this study. Older patients (Pearson correlation 0.291,  $p=0.025$ ) and patients presenting with iron deficiency anaemia (25.7% vs 13.5%,  $p=0.026$ ) had more extensive small bowel (SB) involvement. Patients presenting with weight loss were more likely to have SB involvement beyond the duodenum (37.5% vs 5.8%,  $p=0.027$ ). Patients presenting with iron deficiency anaemia (53.5 vs 42.4 years,  $p=0.038$ ) and weight loss (60.5 vs 42.4 years,  $p=0.009$ ) were older at diagnosis. Serum albumin was lower in those patients diagnosed later on in life (Pearson correlation -0.0361,  $p=0.007$ ).

There was no significant association between anti-tissue transglutaminase antibody ( $p=0.396$ ) and extent of affected SB mucosa.

Patients with more severe Marsh classification of disease on histology from the duodenal bulb had more extensive SB involvement ( $p=0.017$ ).

#### 5.1.4 Conclusions

This is the largest study on the use of SBCE in newly diagnosed CD. Older patients are likely to have more extensive disease on SBCE at diagnosis. Symptoms and serology had little impact on the findings on SBCE.

#### 5.2 Introduction

Macroscopic features of CD such as fissuring of mucosa, scalloping of folds, mosaic pattern and nodularity of mucosa occur secondary to the inflammatory reaction generated by gluten when it comes into contact with the SB mucosa in genetically predisposed individuals mainly in the proximal SB (Biagi et al, 2006; Tursi et al, 2002). These features can be identified and quantified on SBCE. SBCE is currently recommended where the diagnosis of CD is equivocal, where patients refuse or cannot undergo a gastroduodenoscopy for duodenal biopsies to enable a histological diagnosis or where complications are suspected (Pennazio et al, 2015).

The association of clinical symptoms with SBCE findings in patients with CD has been questioned. Most studies on the use of SBCE in CD have been carried out in patients with established CD (Atlas et al, 2011; Collin et al, 2012; Efthymakis et al, 2017; Maiden et al, 2009; Perez-Cuadrado-Robles et al, 2018). Being already on a gluten free diet for months or years makes the relationship between findings on SBCE and clinical symptoms harder to define. Previous studies on SBCE in patients with newly diagnosed CD on duodenal biopsies have only included a limited number of patients ranging from 10 to 35 (Hopper et al, 2007; Lidums et al, 2011b; Murray et al, 2008; Petroniene et al, 2005; Rondonotti et al, 2007). Evidence on the association of SB disease and symptomatology, serology and histology at the time of SBCE is also contradictory (Hopper et al, 2007; Lidums et al, 2011b; Murray et al, 2008; Petroniene et al, 2005; Rondonotti et al, 2007). Current guidelines do not recommend SBCE as part of the diagnostic work up of patients with newly diagnosed CD because the relationships between extent of disease in the SB and CD serology, duodenal histology and symptoms at presentation have not been clearly defined (Pennazio et al, 2015).

The aim was to study the association between clinical symptoms, duodenal histology and CD serology with extent of disease on SBCE in a group of patients with newly diagnosed CD.

### 5.3 Methodology

#### 5.3.1 Study design and patients

This was a prospective study where consecutive patients with newly diagnosed CD (60) who were referred for SBCE were recruited over a 1 year period in a tertiary teaching hospital serving a population of 645,000 in addition to receiving tertiary referrals. All patients had anti-endomysial antibody IgA (EMA) and anti-tissue transglutaminase (TTG) IgA measured at the time of diagnosis to provide supportive evidence of CD. These were positive in all patients. They all had villous atrophy on histology taken from the duodenal bulb and the second part of the duodenum during gastroduodenoscopy following their presentation. Patients presenting with villous atrophy (VA) who were older than 60 years, also had a colonoscopy as part of the investigation when they presented with lower gastrointestinal symptoms or iron deficiency anaemia. Findings on colonoscopy included adenomatous polyps with low grade dysplasia, diverticular disease or a normal endoscopy. This was followed by a SBCE within 2 months of histological diagnosis whilst the patients were still on a gluten containing diet. Signs and symptoms at presentation (neurological symptoms {headaches, ataxia, paraesthesia, forgetfulness}, dermatitis herpetiformis, hypotension, constipation, osteoporosis related fractures, alopecia, dyspepsia, iron deficiency anaemia, vitamin D, folic acid, vitamin B12 deficiency, high inflammatory markers, nausea and vomiting, abdominal pain, mouth ulcers, bloating, diarrhoea, weight loss, palpitations, and fatigue), serological markers (EMA, anti-TTG, albumin, CRP, haemoglobin, ferritin, vitamin B12, folic acid, vitamin D and calcium), histological classification of disease in the duodenum (Marsh classification) (Oberhuber et al, 1999) and human leucocyte antigen (HLA) were noted.

#### 5.3.2 Coeliac serology

Anti-TTG was assayed using enzyme-linked immunosorbent assay (ELISA) kits (Aesku Diagnostics, Wendelsheim, Germany). An anti-TTG titre of more than 7 U/ml was regarded as positive as per the manufacturer's guidance. EMA was

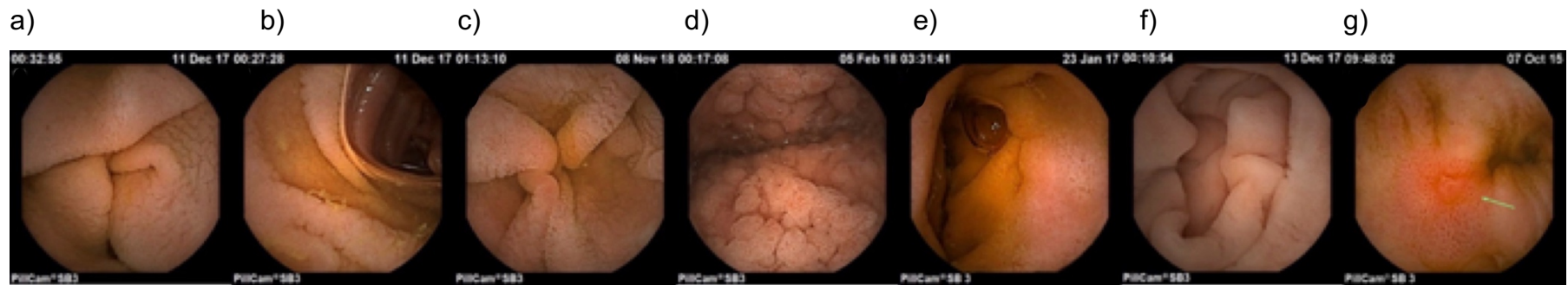
detected by immunofluorescence on primate oesophagus sections (Binding Site, Birmingham, UK). Total IgA was measured on a Behring BN2 nephelometer (Haywards Heath, West Sussex, UK).

### 5.3.3 Duodenal histology

At least 2 biopsies from the duodenal bulb and 4 biopsies from the second part of the duodenum were taken during gastroduodenoscopy. Each biopsy was fixed in formalin at the time of the gastroscopy. Specimens were then processed, orientated and embedded in paraffin wax by the pathology department. All histological samples were reviewed by gastrointestinal histopathologists who are experts in the field of CD. Histology was then classified according to the modified Marsh Criteria (Oberhuber et al, 1999).

### 5.3.4 Small bowel capsule endoscopy

Each patient was asked to remain on a liquid diet for 24 hours before the SBCE and drink 2 litres of Klean-Prep® prior to undergoing SBCE. All patients underwent SBCE using Pillcam SB3 (Medtronic, Minneapolis, USA) (Zwinger et al, 2018). Details on gastric and SB passage time, extent of abnormal SB (with features of CD), extent of villous atrophy and macroscopic features of CD on SBCE were determined by two expert SBCE reviewers (>300 capsules each / year). Where there was a discrepancy in results, a third expert reviewer was involved in the adjudication process. Features of CD were recorded in the proximal, mid and distal SB including: mosaic pattern of mucosa (Figure 19a), scalloping (Figure 19b) and fissuring of folds (Figure 19c), nodularity of mucosa (Figure 19d), atrophic (Figure 19e) and hypotrophic mucosa (intermediate) (Biagi et al, 2006) (figure 8f) and ulcers (Figure 19g).



**Figure 19:** Features of coeliac disease on small bowel capsule endoscopy

a) mosaic pattern of mucosa, b) scalloping and c) fissuring of folds, d) nodularity of mucosa, e) atrophic and f) hypotrophic mucosa (intermediate) and g) ulcers.



### 5.3.5 Statistical analysis

Statistical analysis was carried out using SPSS version 23 (IBM Corp. Released 2015. IBM SPSS Statistics for Mac, Version 23.0. Armonk, NY: IBM Corp.). Frequencies, means and standard deviations were calculated to characterize the cohort studied. Non-parametric statistical tests were used namely, Fisher's exact test to assess statistical significance between categorical variables. Pearson's correlation co-efficient and Spearman's correlation co-efficient were used to assess the correlation between continuous variables. The Mann-Whitney U test was used to compare two independent, continuous variables and the Kruskal-Wallis test was used to compare multiple independent, continuous variables. Multivariate regression analysis was constructed to assess the relationship between several factors such as symptoms, serology and histology and extent of disease. Results were considered to be statistically significant if the p value was less than 0.05.

### 5.3.6 Ethical considerations

The study was approved by the local research and development team within the department of Sheffield Teaching Hospital NHS Foundation Trust under the registration number STH19998.

## 5.4 Results

Sixty patients (63.3% females, n=38) with newly diagnosed CD were included in this study. The mean age at diagnosis was 44.9 years (SD±17.4, 17 - 76).

Most patients presented with diarrhoea (21/60, 35.0%) and fatigue (17/60, 28.3%) (Table 13).

**Table 13:** Signs and symptoms of patients at presentation

Presenting signs / symptoms	Number of patients (%)*
Diarrhoea	21 (35.0%)
Fatigue	17 (28.3%)
Cardiovascular, neurological symptoms	15 (25%)
Iron deficiency anaemia	13 (21.7%)
Abdominal pain	13 (21.7%)
Bloating	9 (15.0%)
Irritable bowel syndrome	9 (15.0%)
Weight loss	8 (13.3%)
Low folic acid level	7 (11.7%)
Positive family history	3 (5.0%)
Vitamin D deficiency	5 (8.3%)
Low vitamin B12	3 (5.0%)

\*Total number of patients = 60

Table 14 shows the mean values of blood investigations at diagnosis. Most of the patients had a Marsh classification of 3b or 3c of histology taken from the duodenal bulb (46/60, 76.7%) and the second part of the duodenum (45/60, 75%). Four patients (n=60, 6.7%) had a Marsh score of 1 or 2 on histology from the second part of the duodenum. All these patients had a Marsh score of 3a – 3c on histology from the first part of the duodenum. Most patients were HLA DQ2 heterozygous (40/60; 66.7%). 21.7% of patients (13/60) were HLA DQ2 homozygous. 10.0% of patients (6/60) were heterozygous for both DQ2 and DQ8 and one patient (n=60, 1.7%) was HLA DQ8 heterozygous.

**Table 14:** Serology results at the time of diagnosis.

	Mean	SD±
Anti-TTG (0 - 7.0 U/mL)	70.3	58.2
Albumin (35 – 50 g/L)	45.7	3.8
CRP (0 – 5 mg/L)	4.1	11.1
Hb (131 – 166 g/L)	138.9	16.1
Ferritin (30 - 400 µg/L)	65.7	68.4
Vitamin B12 (197 – 771 ng/L)	422.4	290.9
Folic acid (< 3.9µg/L deficient)	8.3	6.0
Vitamin D (< 30 mmol/L deficient)	60.3	23.4
Calcium (2.20 - 2.60 mmol/L)	2.4	0.4

**Table 15:** Marsh classification of disease

Histology region	Marsh classification	n (%)*
Duodenal bulb	1	5 (8.3)
	2	1 (1.7)
	3a	8 (13.3)
	3b	27 (45.0)
	3c	19 (31.7)
Second part of duodenum	1	3 (5.0)
	2	1 (1.7)
	3a	11 (18.3)
	3b	22 (36.7)
	3c	23 (38.3)

\*Total number of patients = 60

Table 16 shows the gastric and SB passage time and the percentage of abnormal SB mucosa as well as the percentage of SB mucosa with VA.

**Table 16:** Gastric and small bowel passage time and percentage of abnormal small bowel mucosa

Mean gastric passage time (minutes) ( $\pm$ SD)	34.2 (49.6)
Mean small bowel passage time (minutes) ( $\pm$ SD)	236.7 (97.0)
Mean time with abnormal small bowel mucosa (minutes) ( $\pm$ SD)	39.7 (65.3)
Mean time with villous atrophy (minutes) ( $\pm$ SD)	6.2 (24.9)
Mean % abnormal small bowel ( $\pm$ SD)	16.2 (22.8)
Mean % time without villi ( $\pm$ SD)	0.24 (1.85)

Features of CD were most commonly found in the proximal SB (Table 17). Five patients (5/60, 8.3%) had a normal SBCE. These patients had a mean age at diagnosis of  $47 \pm$ SD 12.8 (30 – 62) years and an anti-TTG of  $119.8 \pm$ SD 129.9 U/mL.

**Table 17:** Features of coeliac disease on small bowel capsule endoscopy

	Proximal n (%)	Mid n (%)	Distal n (%)
Normal	7 (11.7)	55 (91.7)	58 (96.7)
Continuous changes	35 (58.3)	3 (5.0)	2 (3.3)
Patchy changes	18 (30.0)	2 (3.3)	0
Mosaic pattern	42 (70.0)	5 (8.5)	1 (1.7)
Fissuring of mucosa	48 (80.0)	3 (5.0)	0
Scalloping of mucosa	35 (58.3)	3 (5.0)	0
Villous atrophy	15 (25.0)	0	0
Nodularity of mucosa	11 (18.3)	1 (1.7)	0
Ulcers present	4 (7.0)	1 (1.7)	1 (1.7)
Hypotrophic (intermediate)	1 (1.7)	0	0

Total number of patients = 60

#### 5.4.1 Correlation with age at small bowel capsule endoscopy

Older patients had more extensive disease in the SB (time with SB mucosal abnormality: Pearson correlation 0.261,  $p=0.048$ ; percentage of abnormal SB mucosa: Pearson correlation 0.291,  $p=0.025$ ) but there was no statistical correlation with SB transit ( $p=0.766$ ). Older patients had more than 20% of SB involved (36.9 vs 27.2 years,  $p=0.05$ ).

Patients presenting with iron deficiency anaemia (53.5 vs 42.4 years,  $p=0.038$ ) and weight loss (60.5 vs 42.4 years,  $p=0.009$ ) were older at diagnosis of CD. Younger patients commonly presented with vitamin D deficiency (29.6 vs 46.2 years,  $p=0.037$ ).

HLA status varied according to age at diagnosis ( $p=0.026$ ) (Table 18). Younger patients were more likely to be HLA dq2 homozygous.

**Table 18:** Age at diagnosis according to HLA status

	Mean (years)	Std. Deviation
dq2 dq8 heterozygous	58.00	17.922
dq8 heterozygous	53.00	0.0001
dq2 heterozygous	51.29	15.835
dq2 homozygous	35.62	13.938

Kruskal–Wallis test,  $p=0.026$

Serum albumin was lower in those patients diagnosed with CD later on in life (Pearson correlation -0.0361,  $p=0.007$ ).

#### 5.4.2 Differences related to gender

There was no significant difference between sexes in the extent of affected SB mucosa (18.1% males, 15.1% females  $p=0.879$ ).

#### 5.4.3 Correlation with signs and symptoms at presentation

Patients presenting with iron deficiency anaemia had more extensive SB involvement (25.7% vs 13.5%  $p=0.026$ ) (Table 19). Patients with weight loss were more likely to have SB involvement beyond the duodenum (37.5% vs 5.8%  $p=0.027$ ). Other clinical symptoms at presentation did not correlate with extent of SB disease. Number of symptoms did not affect the SB transit (Spearman's correlation co-efficient 0.131,  $p=0.328$ ) and the percentage of affected SB mucosa (Spearman's correlation co-efficient 0.076,  $p=0.565$ ).

There was no correlation between symptoms at presentation and Marsh grading of duodenal histology.

**Table 19:** Significance of small bowel capsule endoscopy parameters according to mode of presentation;

Presentation	Time with mucosal abnormality (minutes)			Time with atrophic mucosa (minutes)			Total small bowel transit (minutes)			% abnormal small bowel mucosa			% with atrophic mucosa		
	Yes	No	p value	Yes	No	p value	Yes	No	p value	Yes	No	p value	Yes	No	p value
Iron deficiency anaemia*	63.9	35.6	0.188	2.5	7.3	0.423	220.0	241.0	0.336	25.8	13.5	0.026	0.01	0.3	1.0
Vitamin D deficiency*	39.6	41.5	0.667	17.8	5.2	0.634	207.0	239.0	0.431	23.6	15.7	0.150	0.01	0.3	1.0
Low folic acid*	23.4	43.5	0.870	0.3	6.9	0.700	10.5	17.0	0.512	0.01	0.3	0.935	0.01	0.3	0.954
Low vitamin B12*	15.0	37.0	0.192	0.5	6.5	0.964	264.0	235.0	0.398	41.1	14.9	0.222	0.01	0.3	1.0
Abdominal pain*	18.2	47.7	0.563	15.3	3.6	0.805	250.2	232.8	0.543	7.6	18.7	0.311	0.01	0.3	1.0
Bloating*	20.0	44.9	0.542	0.2	7.0	0.484	246.8	234.8	0.485	6.7	17.9	0.261	0.01	0.3	1.0
Diarrhoea*	58.9	30.4	0.479	0.6	9.8	0.059	237.1	236.5	0.752	20.8	13.7	0.709	0.01	0.4	1.0
Weight loss*	81.8	34.4	0.698	0.01	7.1	0.194	293.7	227.6	0.085	26.3	14.6	0.675	0.01	0.3	1.0
Fatigue*	22.5	47.7	0.880	8.4	5.5	0.344	222.3	242.2	0.272	13.7	17.1	0.882	0.8	0.1	0.283

\*Kruskal–Wallis test – to compare parameters on small bowel capsule endoscopy according to symptoms;



#### 5.4.4 Association with serology

There was no statistical correlation between parameters on SBCE including percentage of affected SB mucosa with serological markers (Table 20).

**Table 20:** Correlation of small bowel capsule endoscopy parameters with serology at diagnosis

Serology	Time with mucosal abnormality (p value)		Time with atrophic mucosa (p value)		Total small bowel transit (p value)		% abnormal small bowel mucosa (p value)		% with atrophic mucosa (p value)	
	Pearson Correlation co-efficient	p value	Pearson Correlation co-efficient	p value	Pearson Correlation co-efficient	p value	Pearson Correlation co-efficient	p value	Pearson Correlation co-efficient	p value
Anti-TTG*	-0.065	0.660	0.127	0.422	-0.141	0.340	-0.042	0.779	/	0.0001
Albumin*	-0.052	0.712	-0.011	0.942	0.070	0.622	-0.005	0.972	/	0.0001
CRP*	-0.012	0.451	-0.038	0.823	0.039	0.802	-0.129	0.417	/	0.0001
Haemoglobin*	-0.145	0.316	-0.078	0.621	-0.146	0.312	-0.108	0.462	/	0.0001
Ferritin*	0.003	0.981	-0.016	0.915	-0.108	0.429	0.076	0.576	-0.085	0.524
Vitamin B12*	0.365	0.009	-0.116	0.453	0.045	0.756	0.437	0.002	/	0.0001
Folic acid*	0.230	0.108	-0.164	0.288	0.151	0.296	0.234	0.105	/	0.0001
Vitamin D*	-0.095	0.539	-0.284	0.088	0.091	0.557	-0.060	0.702	/	0.0001
Calcium*	-0.246	0.082	-0.131	0.398	0.058	0.688	-0.174	0.226	/	0.0001

\* Pearson Correlation between continuous variables

#### 5.4.5 Association with HLA status

There was no statistical association between HLA status and extent of abnormal SB mucosa ( $p=0.487$ ), extent of mucosal atrophy ( $p=0.354$ ), total SB transit ( $p=0.243$ ), percentage length of abnormal SB mucosa ( $p=0.481$ ) and percentage length of SB mucosal atrophy ( $p=0.841$ ).

#### 5.4.6 Association with Marsh Classification on histology

Patients with more severe Marsh classification of disease on histology from the duodenal bulb had more extensive SB involvement (Marsh 3a 5.95%; Marsh 3b 8.63%; Marsh 3c 22.7%  $p=0.017$ ). There was no significant difference in the duration of mucosal abnormality ( $p=0.150$ ), extent of atrophic mucosa ( $p=0.530$ ), total SB transit ( $p=0.616$ ), percentage of abnormal SB mucosa ( $p=0.261$ ) and percentage of atrophic mucosa ( $p=0.846$ ) according to the Marsh classification of histology from the second part of the duodenum.

#### 5.4.7 Multivariate regression analysis

On assessing the relationship of multiple factors including signs and symptoms, serology and Marsh grade of histology, haemoglobin was inversely correlated with extent of disease on SBCE ( $p=0.029$ ) (Table 21).

**Table 21:** Multivariate regression analysis of signs, symptoms, serology and histology and extent of disease

	Standardized	t	P value
	Coefficients		
	Beta		
Haemoglobin	-.501	-2.296	.029
Albumin	.065	.312	.757
Anti-TTG at diagnosis	.012	.071	.944
Iron deficiency anemia	.042	.195	.847
Weight loss	.101	.539	.594
Diarrhoea	-.044	-.263	.794
Fatigue	.074	.405	.688
Cardiac & neurological symptoms	.162	.933	.358
Marsh at diagnosis (D1)	.140	.694	.493
Marsh at diagnosis (D2)	-.175	-.812	.423

## 5.5 Discussion

This is the largest study on patients with newly diagnosed CD undergoing a SBCE. Other studies that have included a significant number of patients with CD were carried out in patients with established CD (Atlas et al, 2011; Collin et al, 2012; Efthymakis et al, 2017; Maiden et al, 2009; Perez-Cuadrado-Robles et al, 2018). Patients with established CD would have been on a gluten free diet for a variable length of time, making the relationship between features of CD on SBCE and symptomatology, duodenal histology and serology more difficult to study.

The prevalence of CD in elderly patients is increasing (Lohi et al, 2007). A significant proportion of elderly patients have subtle or no symptoms leading to a

delayed diagnosis of CD (Hankey GL & GKT, 1994; Vilppula et al, 2008). Some elderly patients have had long standing gastrointestinal symptoms that might not have been attributed to gluten sensitive enteropathy or have a delayed diagnosis due to reluctance to being investigated. Iron deficiency, weight loss and malabsorptive symptoms are common presentations amongst elderly patients (Freeman, 1994). These patients will have had a long exposure to gluten, making them more prone to present with red flag signs such as iron deficiency anaemia, weight loss and signs of malabsorption and are more likely to develop complications (Swinson et al, 1983). In a study by Muhammad et al, 2.5% of older patients undergoing SBCE for iron deficiency anaemia had changes consistent with CD on the SBCE. These changes were confirmed on duodenal histology taken at the time of gastroduodenoscopy. This study also shows that most (71%) of these patients had normal looking proximal SB mucosa but classical features of CD in the beyond the duodenum (Muhammad & Pitchumoni, 2008). Patients with iron deficiency anaemia (53.5 vs 42.4 years,  $p=0.038$ ), weight loss (60.5 vs 42.4 years,  $p=0.009$ ) and low albumin (Pearson correlation  $-0.0361$ ,  $p=0.007$ ) were significantly older than their counterparts in this study. Older patients also had more extensive disease on SBCE than younger patients (Pearson correlation  $0.291$ ,  $p=0.025$ ; more than 20% of SB involved (36.9 vs 27.2 years,  $p=0.05$ ). It is hypothesized that older patients with a new diagnosis of CD have had a longer exposure to gluten and are potentially at higher risk of complications. This is the first study that shows a direct correlation between age at diagnosis and extent of disease in the SB.

Most patients had proximal SB changes similar to other studies (Collin et al, 2012; Maiden et al, 2009; Murray et al, 2008). This study confirms the lack of association between extent of SB disease on SBCE with signs and symptoms at presentation except for anaemia and weight loss. Patients presenting with iron deficiency anaemia and weight loss had more extensive SB disease secondary to CD. Severity of CD according to Marsh grading of duodenal histology has not shown correlation with symptoms at presentation (Brar et al, 2007). However severity of malabsorption at presentation represented by degree of anaemia has been shown to correlate with histological severity of CD (Kalhan et al, 2011). Two studies report on the association of extent of disease on SBCE with symptomatology in patients with CD (Petroniene et al, 2005; Rondonotti et al,

2007). However, the correlation is reported qualitatively in both studies and failed to reach statistical significance in the first study. Another study by Murray et al, failed to confirm the association of extent of disease on SBCE with clinical manifestations in 38 untreated patients with CD (Murray et al, 2008). A study by Lidums et al, correlated extent of SB involvement and an improvement in symptom score following a gluten free diet but the same study was unable to demonstrate a correlation between extent of disease and symptomatology at baseline (Lidums et al, 2011b).

Most studies on CD correlate symptomatology, serology with duodenal histology which is the gold standard diagnosis for CD in adults (Ludvigsson et al, 2014). However, over the past few years, more insight has been gained into the extent and severity of CD by the introduction of SBCE. SBCE enables the detection of macroscopic changes of CD better than standard upper gastrointestinal endoscopes owing to the wider field of view, better magnification and underwater navigation due to the presence of fluid in the SB.

There is evidence of a direct correlation between anti-TTG levels and severity of Marsh classification of histology (Alessio et al, 2012; Bhattacharya et al, 2014). However, data on the correlation of serology and histology to findings on SBCE is limited. One study reports a significantly longer extent of affected SB mucosa in patients with positive EMA and a positive correlation with anti-TTG in a group of patients with newly diagnosed, untreated CD (Murray et al, 2008). Another study showed no correlation between extent of SB involvement and severity of Marsh histology taken from the duodenum (Rondonotti et al, 2007). There was no correlation between serology and Marsh grade from duodenal histology and extent of affected SB mucosa.

The literature suggests that serology does not always correlate with histological findings in patients undergoing repeated duodenal biopsies after being started on a gluten free diet (Leonard et al, 2017). Also, symptoms in CD patients who are already on a gluten free diet might not necessarily be secondary to persistent active disease but can be due to other causes such as lactose intolerance or small intestinal bacterial overgrowth (Losurdo et al, 2017; McNeish & Sweet, 1968). One of the strengths of this study is the inclusion of patients with newly

diagnosed CD who have not been exposed to a gluten free diet and therefore the relationship between extent of disease affecting the SB and serology, symptomatology and severity of histology has been more accurately studied. This is also the largest study that reports on the findings of CD on SBCE in newly diagnosed patients.

The proportion of females in this study was higher than males reflecting published literature that reports a prevalence of female: male ratio of approximately 2:1 (Howdle & Losowsky, 1992).

One limitation of this study is that this was a single-centre study and therefore prone to both referral and regional bias.

### 5.6 Conclusions

This is the largest collection of data on the use of SBCE in patients with newly diagnosed CD. Patients diagnosed with CD later on in life are likely to have more extensive disease which equates to other deficiencies. Symptoms and serology had no impact on the findings on SBCE except for weight loss and iron deficiency anaemia. Elderly patients and those with red flag signs, namely weight loss and iron deficiency anaemia at presentation should be monitored more closely in view of more extensive SB involvement.

## **Chapter 6 – The role of small bowel capsule endoscopy in patients with established coeliac disease when compared to controls**

### 6.1 Abstract

#### 6.1.1 Introduction

Patients with established coeliac disease (CD) can present with signs and symptoms requiring small bowel capsule endoscopy (SBCE) to assess for persistent disease beyond the duodenum and to rule out complications. There is paucity of data on extent of disease on SBCE in relation to histology, clinical and serological parameters.

The aim of this study was to assess the relationship between symptoms, CD serology and Marsh classification of disease and extent of disease on SBCE in patients with established CD.

#### 6.1.2 Methods

Hundred patients with established CD and 200 controls underwent a SBCE. SBCEs were reviewed by expert reviewers. Extent of disease on SBCE, CD findings and small bowel transit were recorded.

#### 6.1.3 Results

Considering histology from the second part of the duodenum (D2) (Marsh 3a or above) as the gold standard for diagnosing CD activity, the sensitivity of SBCE to delineate active disease was 87.2%. The specificity was 89.0%.

Age at SBCE ( $p=0.006$ ), albumin ( $p=0.004$ ) and haemoglobin ( $p=0.0001$ ), Marsh score of histology from the first part of the duodenum (D1) ( $p=0.0001$ ) and the second part of the duodenum ( $p=0.0001$ ), refractory CD ( $p=0.007$ ) on histology correlated with extent of affected small bowel (SB) mucosa on univariate analysis. On multiple regression analysis, albumin ( $p=0.036$ ) and Marsh score of histology (D1) ( $p=0.019$ ), vitamin B12 ( $p=0.001$ ) and folate levels ( $p=0.008$ ) were statistically significant.



Extent of affected SB mucosa (11.0% vs 1.35%) was greater in patients with complications including those with refractory CD ( $p=0.008$ ).

#### 6.1.4 Conclusions

This is the first study showing correlation between extent of disease and severity of duodenal histology, markers of malabsorption such as folate levels and vitamin B12 and complications of CD.

#### 6.2 Introduction

A proportion (7 – 30%) of patients with established CD present with recurrent or persisting signs and symptoms despite being on a gluten free diet (GFD) for at least 12 months (Abdulkarim et al, 2002; Leffler et al, 2007; O'Mahony et al, 1996). This can be secondary to non-adherence to a GFD, refractory coeliac disease (RCD) or other causes unrelated to CD such as irritable bowel syndrome (Di Sabatino et al, 2012; Högberg et al, 2003). Repeat duodenal histology can provide objective evidence of ongoing disease activity. However, this can only provide information on active disease in the duodenum. Also, not all patients are willing to undergo a repeat gastroduodenoscopy in view of the invasive nature of this procedure. There is evidence to show that symptoms (Murray et al, 2008; Petroniene et al, 2005; Rondonotti et al, 2007) and CD serology (sensitivity less than 50%) (Silvester et al, 2017) are not reliable predictors of ongoing villous atrophy. A non-invasive SBCE can instead be carried out to assess for macroscopic evidence of CD. The sensitivity of SBCE in the delineation of features of CD in patients with established CD varies between 56 – 95% (Atlas et al, 2011; Biagi et al, 2006; Maiden et al, 2009; Rubio-Tapia et al, 2009) (Table 22)

**Table 22:** Sensitivity, Specificity, positive and negative predictive value of small bowel capsule endoscopy in patients with suspected, newly diagnosed and established coeliac disease

Author, year	Suspected CD / newly diagnosed CD / established CD	Study design	Sensitivity	Specificity	Positive Predictive Value	Negative Predictive Value
Petroniene et al, 2005	New CD	4 investigators reviewed SBCEs of 10 CD patients and 10 controls; (2 with and 2 without pre-study experience)	70%	100%	100%	77%
Hopper et al, 2007	Suspected CD	21 patients (EMA positive) and 23 controls underwent SBCE;	85%	100%	100%	88.9%
Rondonotti et al, 2007)26	Suspected CD	43 patients were studied (11 normal duodenal histology; 32 CD);	87.5%	90.9%	96.5%	71.4%
Murray et al, 2008	New CD	38 patients with untreated CD and age, sex-matched controls; SBCE was repeated after 6 months of gluten withdrawal;	92%	100%		
Rubio-Tapia et al, 2009	Established CD	Comparison of clinical characteristics and outcome in 57 patients with RCD: (42 RCD I; 15 RCD II);	87.5%			
Maiden et al, 2009	Established CD	19 patients with CD on a GFD for at least 12 months underwent gastroscopy with duodenal biopsies and SBCE;	67%	100%	100%	60%
Lidums et al, 2011	Suspected CD	22 patients with positive EMA or anti-TTGTTG; (8 normal and 14 had duodenal CD histology) underwent SBCE;	93%	100%	100%	89%
Atlas et al, 2011	Established CD	SBCEs from 42 consecutive patients with nonresponsive CD and 84 age and sex-matched controls were included;	56%;	85%		
Lujan-Sanchis et al, 2017	Suspected CD	Multi-centre study; SBCEs from 163 patients divided into 4 groups were compared;	47.4% seronegative CD with atrophy, 64.1% seropositive CD without atrophy, 50% contraindication to gastroscopy, 28.3% (seronegative CD without atrophy);			

Patients with CD suffer from disordered gut motility (Bassotti et al, 1994). This has been demonstrated in several parts of the gastrointestinal tract (Benini et al, 2012; Iovino et al, 1998; Usai-Satta et al, 2016) using manometric studies (Bassotti et al, 1994). Damage to the SB mucosa results in a disruption of hormones regulating gut motility (Sjölund et al, 1979) and dysfunction of the autonomic nervous system (Gibbons & Freeman, 2005). Literature on small bowel transit (SBT) in patients with CD using SBCE is very limited (Ciaccio et al, 2012; Urgesi et al, 2013). SBT is of relevance in CD as its alteration can have an impact on the pharmacokinetics of medications (Digenis, 1990) and on predisposition to other conditions such as small intestinal bacterial overgrowth (SIBO).

The main aim of this study was to assess the relationship between symptoms, CD serology and Marsh classification of disease and extent of disease on SBCE in established CD. Secondary aims were to establish sensitivity and specificity of SBCE in delineating CD features on SBCE and to assess how SBT varied in patients with CD when compared to controls. Confounders that could influence SBT were also examined.

### 6.3 Methodology

#### 6.3.1 Study design and patients

Consecutive patients with established CD referred for SBCE (100; group 1) (on a GFD) and age and gender matched control patients (200; group 2) were prospectively recruited from a tertiary CD referral centre during a 2 year period. Patients with CD in group 1 underwent a SBCE as part of their clinical care to assess for complications in view of persistent symptoms or features of RCD on histology. They all had a gastroduodenoscopy within 2 months prior to SBCE for duodenal histology and contemporary CD serology was checked. CD serology measured included endomysial antibodies (EMA) and anti-tissue transglutaminase antibodies (IgA) (tTg-IgA) (range 0 – 7 U/mL). Consecutive patients with CD were included in group 1. Other features such as signs and symptoms at presentation, serological markers, and human leukocyte antigen (HLA) were noted.

Patients in group 2 had negative CD serology, normal bidirectional endoscopies and duodenal histology with no evidence of CD within 2 months prior to SBCE. These patients had been referred for SBCE for investigations of gastrointestinal signs and symptoms as a secondary investigation into their symptoms. These included: change in bowel habits, iron deficiency anaemia, vitamin B12, folate levels, vitamin D deficiency, persistent nausea and vomiting, bloating, weight loss, fatigue, high inflammatory markers and bleeding per rectum. They also had no significant underlying co-morbidities. Patients in group 2 were age and gender matched to those in group 1.

### 6.3.2 Duodenal histology

At least 2 biopsies from the D1 and 4 biopsies from D2 were taken during gastroduodenoscopy in both groups of patients. Histology was then classified according to the Marsh score (Oberhuber et al, 1999). Histology from D1 and D2 was regarded separately. All histological samples were reviewed by 2 expert histopathologists. In the case of discrepancy, a third histopathologist was involved in the adjudication process.

### 6.3.3 Small bowel capsule endoscopy

Each patient was asked to stay on clear fluids for 24 hours before the SBCE and to drink 2 litres of Klean-Prep® the day before the SBCE. All patients underwent SBCE using Pillcam SB3 (Medtronic, Minneapolis, USA) (Zwinger et al, 2018). Details on gastric and SB passage time, extent of abnormal SB and villous atrophy on SBCE were determined by two expert SBCE reviewers (>300 capsules each/ year). CD findings such as fissuring of mucosa, scalloping of folds, mosaic pattern, nodularity, villous atrophy and ulcers were recorded. Expert reviewers were blinded to the results of duodenal histology and each other's findings. Use of prokinetics such as metoclopramide (after 30 minutes) or erythromycin (after 60 minutes) if the capsule was in the stomach after ingestion was recorded. Features of CD including: mosaic pattern of mucosa, scalloping and fissuring of folds, nodularity of mucosa, atrophic and hypotrophic mucosa (intermediate) (Biagi et al, 2006) and ulcers, and distribution (proximal, mid or distal SB) were recorded. Where there was a discrepancy in results, a third expert reviewer was involved in the adjudication process. In addition, expert reviewers

were asked to grade overall severity of disease as mild, moderate or severe according to their subjective expert opinion.

In this study, extent of abnormal SB mucosa refers to SB mucosa with macroscopic features of CD. Villous atrophy refers to SB mucosa with absent villi. Since prokinetics can affect gastrointestinal motility, patients who received prokinetics were left out of the analysis of gastric transit and SBT.

#### 6.3.4 Statistical analysis

Statistical analysis was carried out using SPSS version 23 (IBM Corp. Released 2015. IBM SPSS Statistics for Mac, Version 23.0. Armonk, NY: IBM Corp.). Frequencies, medians and ranges were calculated to characterise group 1 and 2. Non-parametric statistical tests were used namely, Fisher's exact test to assess statistical significance between categorical variables and Spearman's correlation co-efficient to assess the correlation between continuous variables. The Mann-Whitney U test was used to compare two independent, continuous variables and the Kruskal–Wallis test was used to compare multiple independent, continuous variables. Binary logistic regression analysis was carried out to analyse the effect of multiple factors on the positive result of a SBCE. Multinomial logistic regression analysis was carried out to assess the effect of multiple factors on extent of abnormal SB mucosa and SBT. Results were considered to be statistically significant if the p value was less than 0.05.

#### 6.3.5 Ethical considerations

The study protocol was approved by the Yorkshire and the Humber Research Ethics committee (IRAS 232382) and registered with the local research and development department of Sheffield Teaching Hospital NHS Foundation Trust under the registration number STH 19998. All images used in this study were deidentified. No additional consent was required for the study with the use of deidentified videos as assessed and approved formally by the Research Ethics Committee.

## 6.4 Results

100 patients with histologically established CD and 200 age (mean age 53.2 SD±15.7 vs 50.0 SD±15.6 years,  $p=0.088$ ) and gender (females  $n=70$ , 70.0% vs  $n=119$ , 59.8%,  $p=0.099$ ) matched controls were included. There were 7 (7.0%) incomplete procedures in the CD group and no incomplete procedures in the controls. All incomplete SBCEs did not reach the caecum but retention was ruled out on abdominal x-ray. Only 2 patients with incomplete SBCE were administered prokinetics during the procedure. There was no statistical difference in the number of patients given prokinetics between the 2 groups ( $p=0.558$ ). Prokinetics were administered to 12 patients (12%) within the CD group and to 20 patients (10%) within the control group. There was also no statistical difference in patients on opioids in both groups of patients ( $p=0.227$ ). More CD patients ( $n=9$ , 9%) were on beta blockers than controls ( $n=1$ ; 0.5%,  $p=0.0001$ ). BMI was higher in patients in group 2 than in group 1 (median 27.5 range 17.3 – 159.8 kg/m<sup>2</sup> vs median 23.7; range 15.1 – 43.4 kg/m<sup>2</sup>,  $p=0.008$ ).

Patients with CD had a median duration of disease of 7 years (1 – 59 years). All patients were started on a GFD immediately or when they were seen by a dietician within 2 months from their diagnosis of CD. Anti-endomysial antibody (EMA) was positive in 23 patients (23.0%) and the median tissue transglutaminase (TTG)-IgA was 2.9 (0.3 – 300) U/mL at the time of SBCE. Twenty-nine (29.0%) had a positive TTG-IgA (higher than 7 U/mL). Patients had the following Marsh score on histology in the D1: Marsh 0: 13.9%, Marsh 1: 19.0%, Marsh 2: 7.6%, Marsh 3a 24.1%, Marsh 3b: 21.5%, Marsh 3c 13.9% and D2: Marsh 0: 13.4%, Marsh 1: 28.0%, Marsh 2: 11.0%, Marsh 3a 14.6%, Marsh 3b: 13.4%, Marsh 3c 19.5%. Control patients had normal duodenal histology.

Sixty-four patients (64.0%) in group 1 had symptoms at the time of presentation. Controls had similar presenting symptoms to patients with CD (Table 23).

**Table 23:** Signs and symptoms at SBCE in patients with coeliac disease and in controls at the time of SBCE

	Group 1 (CD)	Group 2 (controls)	Significance (p value)
Positive CD antibodies (EMA)	23 (23.0)	0	/
Neurological symptoms (headaches, ataxia, forgetfulness, paraesthesia)	2 (2.0)	0	/
Dermatitis herpetiformis	0	0	/
Failure to thrive	0	0	/
Constipation	1 (1.0)	10 (5.0)	0.107
Osteoporosis	0	0	/
Iron deficiency anaemia	15 (15.0)	25 (12.5)	0.0001
Vitamin D deficiency	0	1 (0.5)	/
Low folate	1 (1.0)	3 (1.5)	0.431
Low B12	1 (1.0)	3 (1.5)	0.026
Dyspepsia	0	0	/
Vomiting	3 (3.0)	7 (3.5)	0.559
Nausea	5 (5.0)	8 (4.0)	0.766
IBS symptoms	0	0	/
Abdominal pain	27 (27.0)	58 (29.0)	0.786
Bloating	5 (5.0)	12 (6.0)	0.798
Diarrhoea	31 (31.0)	70 (35.0)	0.519
Weight loss	12 (12.0)	23 (11.5)	0.899
Positive family history of CD	0	0	/
Fatigue	11 (11.0)	1 (0.5)	0.0001
High inflammatory markers (ESR, CRP)	2 (2.0)	3 (1.5)	0.540
Bleeding per rectum	2 (2.0)	9 (4.5)	0.347

#### 6.4.1 Findings on small bowel capsule endoscopy

Considering duodenal histology (D2) (Marsh score of 1 or above) as the gold standard for diagnosing CD activity, the sensitivity of SBCE to delineate active disease was 76.4% (true positive 55). The specificity was 97.2% (true negative 209). Considering only a Marsh histology of 3 or above, the sensitivity of SBCE

to delineate CD changes was 87.2% (true positive 34). The specificity was 89.0% (true negative 219).

Considering histology from the D1 (Marsh score of 1 or above), the sensitivity of SBCE to delineate active disease was 73.5% (true positive 50). The specificity was 98.1% (true negative 207). Considering only a Marsh histology of 3 or above, the sensitivity of SBCE to delineate CD changes was 82.6% (true positive 38). The specificity was 93.1% (true negative 217).

The positive and negative predicative values of SBCE in relation to duodenal histology (D2) were 90.2% and 92.5% respectively.

In CD patients, 30 patients (30.0%) had a normal SBCE, 56 patients (56.0%) had proximal SB involvement, 7 patients (7.0%) had proximal and mid SB involvement and another 7 patients (7.0%) had diffuse disease. Features of CD on SBCE included: mosaic pattern of mucosa, fissuring and scalloping of folds, villous atrophy, nodularity, hypotrophic folds and the presence of ulcers (Table 24). CD patients with a normal SBCE (30) had a median ttg-IgA of 2.0 (0.5 – 78.0) U/mL.



**Table 24:** Features of coeliac disease in the proximal, mid and distal small bowel on SBCE

Proximal small bowel n (%)		Mid small bowel n (%)		Distal small bowel n (%)	
Mosaic pattern	40 (40.0)	Mosaic pattern	9 (9.0)	Mosaic pattern	1 (1.0)
Fissuring of mucosa	39 (39.0)	Fissuring of mucosa	7 (7.0)	Fissuring of mucosa	1 (1.0)
Scalloping of mucosa	43 (43.0)	Scalloping of mucosa	11 (11.0)	Scalloping of mucosa	3 (3.0)
Villous atrophy	19 (19.0)	Villous atrophy	4 (4.0)	Villous atrophy	2 (2.0)
Nodularity of mucosa	9 (9.0)	Nodularity of mucosa	4 (4.0)	Nodularity of mucosa	1 (1.0)
Ulcers	5 (5.0)	Ulcers	3 (3.0)	Ulcers	2 (2.0)
Hypotrophic folds	0	Hypotrophic folds	0	Hypotrophic folds	0

There was a discrepancy between SBCE findings and histology in 21 CD patients (21%). Seventeen patients had a normal SBCE but abnormal D2 histology (Marsh 1: 11, Marsh 2: 1, Marsh 3a: 3, Marsh 3b: 2). In 4 patients, D2 histology was normal but SBCE was positive (proximal changes: 3, mid, distal changes: 1) In these patients where there was a discrepancy between the histopathology result and findings on SBCE, a third expert capsule reviewer and a histopathologist were asked to review the SBCE and the duodenal biopsies respectively. The original findings on SBCE and histopathology were confirmed in all these cases.

In patients with CD, on univariate analysis, age at the time of SBCE ( $p=0.021$ ), EMA result ( $p=0.015$ ), haemoglobin level ( $0.016$ ), Marsh score of disease in the D1 ( $p=0.003$ ) and D2 ( $p=0.001$ ), presence of RCD on histology ( $p=0.006$ ) all correlated significantly with a positive SBCE (macroscopic evidence of CD on SBCE) (

Table 25). On multiple regression analysis, only histology in D1 ( $p=0.043$ ) maintained statistical significance in being correlated to a positive SBCE.

**Table 25:** Correlation of factors with positive / negative small bowel capsule endoscopy

Factor	Univariate analysis			Binary logistic regression analysis	
	SBCE Positive	SBCE Negative	Significance (P value)	Unstandardized Coefficients	Significance (P value)
Age at the time of SBCE (median, years)	55	49	0.021	1.16	0.079
Age at diagnosis of CD (median, years)	48.5	40.5	0.169	0.940	0.334
Presence of symptoms n(%)	44 (64.7)	20 (66.7)	0.521	0.168	0.129
EMA positive at SBCE n(%)	21 (34.4)	2 (8.3)	0.015	1.1	0.955
Anti-TTG at SBCE (U/mL)	3.0	2.7	0.102	1.0	0.783
Albumin at SBCE (g/L)	44	46	0.136	1.12	0.529
Vitamin B12 at SBCE (ng/L)	443	351	0.259	0.997	0.201
Folic acid level at SBCE (µg/L)	9.9	10.5	0.554	0.871	0.292
Haemoglobin level at SBCE (g/L)	132	139	0.016	1.0	0.989
Marsh score of D1 biopsies	0 4 (7.4%)	7 (28.0%) 8 (32.0%) 1 (4.0%) 7 (28.0%) 1 (4.0%) 10 (18.5%)	0.003	9.04	0.043
Marsh score of D2 biopsies	0 4 (6.9%)	7 (29.2%) 11 (45.8%) 1 (4.2%) 3 (12.5%) 2 (8.3%) 0 (0%)	0.001	0.275	0.169
Refractory celiac disease (RCD)	29 (41.4%)	4 (13.3%)	0.006	0.153	0.130

Age at time of SBCE ( $p=0.006$ ), serum albumin ( $p=0.004$ ) and haemoglobin ( $p=0.001$ ), Marsh score of D1 ( $p=0.001$ ) and D2 ( $p=0.001$ ), the presence of RCD features ( $p=0.007$ ) on histology all statistically correlated with the percentage of affected mucosa on univariate analysis in CD. Histological features diagnostic of RCD on duodenal mucosa included: persistent villous atrophy in patients on a GFD who had been formally assessed by a dietician (RCD I and II), loss of surface CD 3 and CD8 from intraepithelial lymphocytes (RCD II) and monoclonal T cell receptor rearrangement in patients with RCD II. A multiple regression analysis was run to predict percentage of affected SB mucosa. Serum albumin level ( $p=0.036$ ) and Marsh score on histology taken from D1 ( $p=0.019$ ) maintained statistical significance. Serum vitamin B12 ( $p=0.001$ ) and folate levels ( $p=0.008$ ) gained statistical significance on multiple regression analysis and correlated inversely with extent of disease (Table 26). Nine patients had a low vitamin B12 level ( $< 197$  ng/L) and 5 patients had a low folate level ( $< 3.9$  ug/L) at the time of SBCE.

**Table 26:** Correlation of factors with percentage of affected small bowel mucosa

Factor	Univariate analysis		Multiple regression analysis	
	Spearman's rho / Mean	Significance (P value)	Unstandardized Coefficients	Significance (P value)
Age at the time of SBCE	Spearman's rho 0.283	0.006	0.057	0.854
Age at diagnosis of CD	Spearman's rho 0.171	0.106	0.018	0.941
Presence of symptoms	No symptoms 19.1% vs symptoms 15.9%	0.613	-3.475	0.543
EMA at SBCE	Spearman's rho 0.0001	0.140	5.645	0.512
Anti-TTG at SBCE	Spearman's rho 0.131	0.245	-0.001	0.986
Albumin at SBCE	Spearman's rho -0.312	0.004	-1.623	0.036
Vitamin B12 at SBCE	Spearman's rho -0.061	0.587	-0.034	0.001
Folic acid level at SBCE	Spearman's rho 0.001	0.992	-1.475	0.008
Haemoglobin level at SBCE	Spearman's rho -0.382	0.0001	-0.302	0.117
Marsh score of D1 biopsies	Spearman's rho 0.558	0.0001	10.494	0.019
Marsh score of D2 biopsies	Spearman's rho 0.558	0.0001	-5.835	0.174
Refractory celiac disease (RCD)	No RCD 11.6% vs RCD I 24.5% vs RCD II 41.5%	0.007	5.552	0.212

Duration of disease did not correlate with percentage length of abnormal SB mucosa (Spearman's rho -0.019, p=0.863). There was no correlation between duration of disease / GFD and ttg-IgA at the time of SBCE (Spearman's rho -0.091, p=0.422) and there was no difference in duration of disease / GFD between patients with positive and negative EMAs (p=0.365).

There was no correlation between ttg-IgA and percentage of abnormal SB mucosa ( $p=0.194$ ) and no difference in percentage length of abnormal SB mucosa ( $p=0.087$ ) in patients with positive and negative EMAs.

Extent of abnormal SB mucosa and of villous atrophy correlated with the overall severity of disease on SBCE (mild / moderate / severe) as graded by the expert reviewers (Table 27) ( $p=0.0001$ ).

**Table 27:** Overall severity of affected small bowel mucosa as graded by the expert reviewers

	Grading by expert reviewers	Percentage of affected mucosa		
		Median (%)	Minimum (%)	Maximum (%)
Percentage of abnormal small bowel mucosa (with macroscopic features of celiac disease*)	Normal	0	0	0
	Mild	3.6	0	45.5
	Moderate	44.7	37.3	85.3
	Severe	100.0	44.4	100.0
Percentage of small bowel with atrophic mucosa (absent villi)	Normal	0	0	0
	Mild	0.1	0.1	0.2
	Moderate	0	0	0
	Severe	1.0	0.1	1.0

\*macroscopic features of coeliac disease include: fissuring of folds, mosaicism, scalloping of folds, nodularity, hypotrophic folds, villous atrophy, ulcers

There was no statistical significant difference in affected SB mucosa according to symptoms at the time of SBCE both when symptoms were considered separately and when the presence or absence of symptoms were considered in group 1.

Extent of affected SB mucosa (11.0% (0 – 100%) vs 1.35% (0 – 100%)) was greater in patients with complications including those with RCD ( $p=0.008$ ). Thirty-three (33%) patients had RCD (23% type I, 9% type 2) confirmed on duodenal histology. One patient who had an incomplete SBCE due to an ulcerated stricture

which was eventually diagnosed with adenocarcinoma. Another patient had diffuse ulcers throughout the SB and was diagnosed with ulcerative jejunoileitis.

#### 6.4.2 Small bowel transit

In view of the possibility of prokinetics having an impact on gastric transit and SBT, patients who received prokinetics were left out of the following analyses.

Gastric passage time (21.0; range 0.01 – 163.0 group 1 vs 17.0; range 0.01 - 273 minutes group 2  $p=0.737$ ) did not vary significantly between the 2 groups. Patients with CD had a longer SBT than controls (277.0; range 60.0 – 981.0 group 1 vs 235.0; range 38.0 – 544.0 minutes group 2,  $p=0.0001$ ).

Median SBT was shortest in controls (235 minutes; range 38 – 544), followed by those with established CD but a normal SBCE (256 minutes; range 104 – 427), SBT was longest in those with established CD and macroscopic evidence of CD on SBCE (260 minutes; range 104 – 427) ( $p=0.001$ ).

BMI correlated with SBT in patients with CD (Spearman's rho -0.375,  $p=0.026$ ) but not in controls (Spearman's rho 0.013,  $p=0.927$ ). Other comorbidities and medications that might have affected motility in patients with CD included: microscopic colitis (2), SIBO (1), hypothyroidism (4), ulcerative colitis (1), right hemicolectomy for adenocarcinoma (1), pancreatic insufficiency (1). One patient was on morphine sulphate. Another patient was on bisoprolol.

Age at the time of SBCE (Spearman's rho 0.303,  $p=0.006$ ) and at the time of diagnosis of CD (Spearman's rho 0.244,  $p=0.032$ ), haemoglobin level (Spearman's rho -0.272,  $p=0.024$ ) measured at the time of SBCE correlated with SBT on univariate analysis in patients with CD. However, all factors lost statistical significance on multiple regression analysis. Grade of histology from D1 ( $p=0.489$ ) and D2 ( $p=0.827$ ) did not correlate with SBT.

Duration of disease / GFD did not correlate with SBT (Spearman's rho 0.174,  $p=0.125$ ). There was no difference in SBT in patients with positive and negative SBCEs ( $p=0.140$ ). There was also no correlation between anti-TTG and SBT (Spearman's rho 0.057,  $p=0.645$ ) and no difference in SBT ( $p=0.149$ ) in patients

with positive and negative EMAs. There was no statistical difference in SBT for most of the CD features in the SB.”

## 6.5 Discussion

In this study, low serum albumin and vitamin deficiencies secondary to malabsorption correlated with extent of disease in the SB. This suggests that more extensive SB disease has a significant impact on malabsorption. Severity of Marsh classification of disease on duodenal histology in the D1 correlated with a positive SBCE and extent of affected SB mucosa. Complicated CD patients (RCD) had more extensive SB disease. A prolonged SBT has also been confirmed in patients with CD when compared to controls.

Sensitivity and specificity of SBCE in delineating CD changes were similar to those reported in other studies on SBCE in patients with CD (Table 22) (Atlas et al, 2011; Hopper et al, 2007; Lidums et al, 2011a; Lujan-Sanchis et al, 2017; Maiden et al, 2009; Murray et al, 2008; Petroniene et al, 2005; Rondonotti et al, 2007; Rubio-Tapia et al, 2009). The sensitivity of SBCE in detecting active disease in D1 and D2 were similar. Sensitivity of SBCE was higher, when only histology of marsh 3a or above was considered. This is significant as it is still uncertain if Marsh score of 1 and 2 can be considered as active CD on repeat duodenal histology. It also confirms that SBCE is better at detecting active CD of higher Marsh scores.

Most patients with CD had evidence of active disease in the proximal SB. Only a few patients had disease extending beyond the duodenum and only one patient had a malignant complication secondary to CD. This confirms that persistent disease most commonly affects the proximal SB and that malignant complications are rare and do not usually account for the persistent signs and symptoms in patients with underlying CD. EMA was only positive in 27% of patients and the median TTG-IgA was low confirming that serology is a poor marker of persistent disease (Silvester et al, 2017) There was no correlation between symptoms and extent of disease on SBCE as demonstrated by previous studies (Murray et al, 2008; Petroniene et al, 2005). This study has also confirmed



that both CD serology and symptoms at the time of presentation do not correlate with extent of disease in these patients.

This study confirms the findings of previous studies that correlate serological markers of malabsorption with SBCE findings (Barret et al, 2012; Efthymakis et al, 2017). However, I have gone a step further and shown that vitamin B12 and folate levels correlate inversely with extent of disease on SBCE. In a study by Efthymakis et al, albumin and haemoglobin correlated inversely with DY of SBCE in CD patients (Efthymakis et al, 2017). Serum albumin has been shown to correlate inversely with disease extent in another study (Barret et al, 2012). Older patients were also found to have more extensive disease on univariate analysis. This is clinically relevant as it confirms that patients with non-responsive CD and abnormal serology are more likely to have extensive disease on SBCE.

Traditionally, severity of CD has been determined by severity of villous atrophy on duodenal histology according to the Marsh classification of CD (Oberhuber et al, 1999). Previous studies have failed to confirm a correlation between extent of disease in the SB and severity of duodenal histology (Lidums et al, 2011b; Murray et al, 2008). In this study, extent of affected SB mucosa correlated with severity of disease on duodenal histology. This is the first study that shows such a positive correlation and therefore defines the complementary role that SBCE can play to duodenal histology in the follow up of patients with established CD. This can help to overcome the inaccuracies that can occur from an inadequate number and preparation of duodenal histological samples and target those with extensive disease more aggressively by ensuring a strict GFD and a closer follow up with experts in CD and specialized dieticians.”

A similar correlation was also true for patients with RCD. These patients had a greater extent of affected SB mucosa than patients with uncomplicated disease. The correlation of extent of disease to RCD is also reported in another study (Barret et al, 2012). This is of clinical relevance. SBCE in patients with extensive disease, should be followed by a gastroduodenoscopy or device assisted enteroscopy for a histological exclusion of RCD, pre-malignant and malignant complications (Elli et al, 2017).

The immune mediated reaction to gluten and tissue transglutaminase antibody in patients with CD results in large quantities of undigested gluten (van de Wal et al, 1999) remaining in the SB. This heightens the inflammatory response in the intestinal lining, resulting in villous atrophy that in turn slows oro-caecal transit. The inflammatory changes in the SB wall can result in decreased contractions, disruption of hormones involved in gut motility (Sjölund et al, 1979) and autonomic nervous system dysfunction (Gibbons & Freeman, 2005). Undigested carbohydrates have been shown to delay gastric emptying and prolong oro-caecal transit time in patients with CD (Ropert et al, 1996). Intestinal dysmotility normalises after a GFD (Sadik et al, 2004). This pathogenesis can explain the distinction in SBT between patients with CD and controls. In a study by Urgesi et al, there was no difference in the SBT between CD patients and controls (252.2±67.4 minutes vs 244.7±88.4 minutes) on SBCE (Urgesi et al, 2013). Ciaccio et al, have estimated SB motility by comparing changes in luminal SB width on SBCE. There was less luminal width variation in CD patients than in controls signifying delayed SBT in CD patients (Ciaccio et al, 2012). These are the only 2 studies on SBT utilising SBCE. The former study only included a small number of patients and there was an insignificant difference in SBT. The latter study describes a laborious and unconventional method to estimate SBT. This study is the first to show a difference in SBT time between patients with CD and controls utilising capsule reviewing software that is routinely used and does not require any extra calculations.

An increase in mucosal permeability in patients with CD and histological remission has been demonstrated in older studies (Bjarnason et al, 1985). A significant proportion of patients with CD and an normal SBCE in this cohort of patients, also had normal duodenal histology (60%). Persistent microscopic changes in the SB mucosa can explain the prolonged SBT in patients with CD in remission. Persistent prolonged SBT can also be unrelated to CD such as irritable bowel syndrome (Connolly & Chang, 2011) and pancreatic enzyme insufficiency (Hedsund et al, 2012).

Several factors have been identified as risk factors for incomplete SBCE including patient mobility, performance of a SBCE in hospitalised patients, prior abdominal surgery or bowel obstruction, elderly patients and poor bowel preparation during

SBCE (Westerhof et al, 2009). In a meta-analysis by Elli et al on the use of SBCE and enteroscopy in patients with CD, SBCE completion was reported to range between 62 and 100% (Elli et al, 2017). In this study there was an incomplete SBCE rate of 7% which is within the reported range. An incomplete SBCE due to insufficient capsule battery life is one of the possible implications of a slower SBT that can lead to secondary investigations such as SB radiology or a repeat SBCE with prokinetic medications. One suggestion would be to carry out SBCEs with a longer battery life in patients with CD to overcome the potential problem of a slower SBT that can be encountered in patients with CD (Rahman et al, 2015).

A prolonged SBT in patients with CD can also have clinical implications. CD patients frequently have other co-morbidities in particular autoimmune conditions (Ferrari et al, 2019) and neurological conditions (Campagna et al, 2017) that require medications. A delayed SBT can have an impact on absorption of medications complicating management. A prolonged SBT can promote SB bacterial overgrowth leading to a rise in serum bile acids due to the action of bacteria in the gut on undigested food leading to a higher risk of gallstones (Kaur et al, 2014).

One of the CD features described in the methodology - hypotrophic folds was not identified in any of the CD patients in this study. This was a feature of intermediate changes in the mucosa identified by Biagi et al (Biagi et al, 2006). In their study, this feature was associated with any histological pattern. This aspect and the fact that none of these patients had this feature on SBCE, raises the question of its significance in patients with CD.

The inclusion of a control group with similar symptoms to those of CD at the time of SBCE is one of the strengths of the study as this enabled comparison of SBT between a group of patients with CD and controls. Expert SBCE reviewers were blinded to the results of duodenal histology and each other's findings. This resulted in a stronger study to distinguish between patients with CD and controls and helped us determine the sensitivity and specificity in delineating CD changes.

Some limitations to this study exist. This was a single centre study carried out at a tertiary centre where patients with established CD, persistent symptoms and a

number of patients with RCD are routinely followed up. This might have introduced bias in the selection of patients with CD. More patients with CD were on beta-blockers than controls. Some CD patients had co-morbidities such as hypothyroidism. Both beta-blockers and co-morbidities might have led to a delayed SBT in CD patients when compared to controls. BMI had a significant impact on SBT in both groups, thus making BMI an unlikely parameter to have contributed to the difference in SBT between both groups of patients.

## 6.6 Conclusions

This is the first study that links extent of SB disease to severity of duodenal histology suggesting an important role for SBCE as a non-invasive marker in the follow up of patients with CD. Patients with lower albumin, vitamin B12 and folate levels are most likely to benefit from SBCE as they are more likely to have active SB disease. Ongoing SB disease can be one explanation for persistent signs and symptoms in patients with CD.

## **Chapter 7 – The use of small bowel capsule endoscopy in equivocal cases of villous atrophy and raised intraepithelial lymphocytes**

### 7.1 Abstract

#### 7.1.1 Introduction

Seronegative villous atrophy (SNVA), raised intraepithelial lymphocytes (IELs) and crypt hyperplasia on duodenal histology can be secondary to coeliac disease (CD) or other causes such as medications or infections. My aims were to assess the role of small bowel capsule endoscopy (SBCE) in these patients and to ascertain whether findings on SBCE at diagnosis can predict disease outcome.

#### 7.1.2 Methods

Patients (177) with SNVA, IELs +/-crypt hyperplasia on duodenal histology were studied. These patients all had an equivocal diagnosis of CD.

#### 7.1.3 Results

Overall, 56 (31.6%) patients had a positive SBCE. Most patients had disease affecting the proximal third of the SB (33, 58.9%).

The diagnostic yield (DY) of SBCE was 40.0% (22 patients), 51.4% (18 patients), 27.0% (10 patients) and 14.0% (7 patients) in patients with an unknown cause for SNVA (SNVA-UO), patients with SNVA who responded to a gluten free diet (SNVA-CD), SNVA-KNOWN CAUSE, patients with raised intraepithelial lymphocytes +/- crypt hyperplasia respectively.

In SNVA-UO, SBCE at diagnosis was more likely to be positive in patients with persistent SNVA (10, 90.9%) and persistent SNVA with lymphoproliferative features (4, 80.4%) than patients with spontaneous resolution of SNVA (8, 20.5%) ( $p=0.0001$ ).

All patients in the SNVA-CD group who eventually developed complications had a positive SBCE ( $p=0.022$ ). They also had more extensive small bowel (SB) disease than those without complications (50% vs 1%  $p=0.002$ ).

More extensive SB disease on SBCE correlated with a higher SNVA-related mortality in patients with SNVA-UO and SNVA-CD ( $p=0.019$ ). Severity of histology did not correlate with overall mortality (mean duration of follow-up  $8\pm 6$  years) ( $p=0.793$ ).

#### 7.1.4 Conclusions

A positive SBCE at diagnosis in patients with SNVA-UO and SNVA-CD predicts a worse outcome. More importantly, more extensive disease in these patients is associated with poor survival. Targeting patients with extensive disease at diagnosis with more aggressive therapy can help to improve prognosis.

## 7.2 Introduction

Although the gold standard for the diagnosis of CD is duodenal histology, celiac serology and genetic studies can be negative in the presence of VA (Ludvigsson et al, 2014; Rubio-Tapia et al, 2013). This has led to the introduction of another term: SNVA.

In patients with suspected CD, SNVA on duodenal histology can be secondary to IgA deficiency or a low gluten intake at the time of diagnosis (Abrams et al, 2004; Cataldo et al, 1998). SNVA can also be secondary to drugs, infections and immune-mediated conditions (Aziz et al, 2017). In some patients, the cause remains unknown (Pallav et al, 2012). The most common causes for SNVA are: CD (SNVA-CD) (28-31%), medication-related (6-26%), infective (7-27%) and idiopathic (14-18%) (Aziz et al, 2017; DeGaetani et al, 2013). Despite undergoing extensive investigations, determining the aetiology of disease in most of these patients is challenging and requires further secondary investigations. The introduction of SBCE has enabled us to study this condition further.

Similar to SNVA, milder changes on duodenal histology of raised IELs and/or crypt hyperplasia can occur secondary to immune-mediated conditions, medications and infections (Al-Toma et al, 2019; Parihar et al, 2017). These patients do not have enough changes on duodenal histology to support a diagnosis of CD as villous atrophy (VA) and positive CD serology are required features (Ludvigsson et al, 2014). Some of these patients will eventually have a

confirmative diagnosis of CD (Aziz et al, 2010). One explanation is that CD can affect the SB with varying degrees of severity (Hopper et al, 2008). Some patients might be following a low gluten-containing diet and changes will only become evident following a gluten challenge.

As recommended by the European guidelines, SBCE is indicated in patients with equivocal CD (Pennazio et al, 2015). Up to 30% of patients with CD present with persisting signs and symptoms, which necessitates further investigations, including repeat duodenal histology and SBCE (Leffler et al, 2007). SBCE can play a major role in patients with refractory coeliac disease (RCD) in assessing disease extent and ruling out complications at diagnosis (Elli et al, 2017) and at follow up (Chetcuti Zammit et al, 2019a).

The aim was to assess the role of SBCE in patients with distinct causes for SNVA and Marsh 1 and 2 histology. Firstly, the role of SBCE at diagnosis in addition to conventional investigations was determined. Secondly, examination findings on SBCE were assessed to see whether they could predict outcomes.

### 7.3 Methodology

#### 7.3.1 Study design and participants

177 patients with SNVA or raised IELs +/- crypt hyperplasia on duodenal histology were recruited over a 19-year period (2000 – 2019). They all had a SBCE following a histological diagnosis, total immunoglobulin A levels (IgA) and contemporary CD serology (IgA endomysial antibodies, endomysial antibody (EMA) and IgA tissue transglutaminase antibodies (anti-TTG). All patients had negative EMA and anti-TTG levels. This work followed previously started work by *Dr Aziz* and *Dr Kurien*. Twenty-seven (15.3%) patients were also subjects in studies by Aziz and Kurien et al (Aziz et al, 2017; Kurien et al, 2013). Including patients with SNVA from other studies has enabled me to follow up patients for a longer period of time.

Patients with SNVA or raised IELs +/- crypt hyperplasia on duodenal histology referred to the SB unit for SBCE by their respective caring physician within the study period were included in this study. The caring physician, then determined

the type of follow up (repeat duodenal histology and SBCE) these patients received.

A separate group of patients with Marsh 1 and 2 histology was included in this study as these patients form part of the group of patients with an equivocal diagnosis of CD (Rubio-Tapia et al). Absence of VA and negative CD serology in these patients can be explained by the patchy nature of CD in the SB, low gluten intake in the diet and incorrect orientation of the duodenal specimens (Collin et al, 2005; Green, 2008; Hopper et al, 2008; Pais et al, 2008). They do not have enough histological changes (VA) to fulfil a diagnosis of CD and their CD serology is negative. However they have changes (raised IELs or / and crypt hyperplasia) that could be found in patients with CD or in those who will eventually develop CD as shown in previous studies (Aziz et al, 2015; Ierardi et al, 2015). My study provides a broader overview of patients with equivocal changes on histology that could potentially be related to CD by including patients with Marsh 1 and 2 histology.

### 7.3.2 Duodenal histology

At least four biopsies including a biopsy from the duodenal bulb were taken from the duodenum. All histological samples were reviewed by 2 expert histopathologists. In the case of discrepancy, a third histopathologist was involved in the adjudication process. IELs was defined as >25 per 100 enterocytes (Veress et al, 2004). VA was identified according to the Marsh-Oberhuber criteria, using the most severe lesion present: Marsh 1 (raised IELs), Marsh 2 (crypt hyperplasia), Marsh 3a (partial villous atrophy, PVA), Marsh 3b (subtotal villous atrophy, SVA), or Marsh 3c (total villous atrophy, TVA) (Oberhuber et al, 1999).

Histological samples were also assessed for differences in immunohistochemistry based on CD3 pan-lymphocyte marker and specific CD8-T cytotoxic and CD4-T helper intraepithelial lymphocyte expression.

### 7.3.3 Coeliac serology

CD serology testing was IgA based. EMA were detected on immunofluorescence on primate oesophagus sections from The Binding Site (Birmingham, UK). Anti-



TTG levels were assayed using ELISA kits (Aesku Diagnostics, Wendelsheim, Germany). Titres less than or equal to 7 U/mL were considered normal.

#### 7.3.4 Criteria for diagnosis of seronegative villous atrophy

Criteria for the diagnosis of SNVA were similar to those used by previous researchers (Aziz et al, 2017; DeGaetani et al, 2013) including:

1. Review of past medical, surgical history and medication use.
2. Patients underwent the following investigations including HLA-DDQ2 and DQ8 genetic studies, HIV serology, Tuberculosis quantiferon, antienterocyte and antigoblet cell antibodies, stools for giardia antigen and other bacteria.
3. The biopsies were reviewed by expert gastrointestinal histopathologists to confirm the diagnosis.
4. If patients were on a GFD at the time of presentation, they were asked to undergo a gastroduodenoscopy following a gluten-challenge of 10g/day for 6 weeks.
5. Further biopsies were obtained to rule out *Helicobacter pylori*, Whipples PCR and SB aspirate to rule out infection.
6. In case of persistent symptoms or where the suspicion of Crohn's disease / microscopic colitis was high, an ileo-colonoscopy was carried out.
7. SBCE at the time of diagnosis was carried out at the discretion of the physician but based on clinical need.

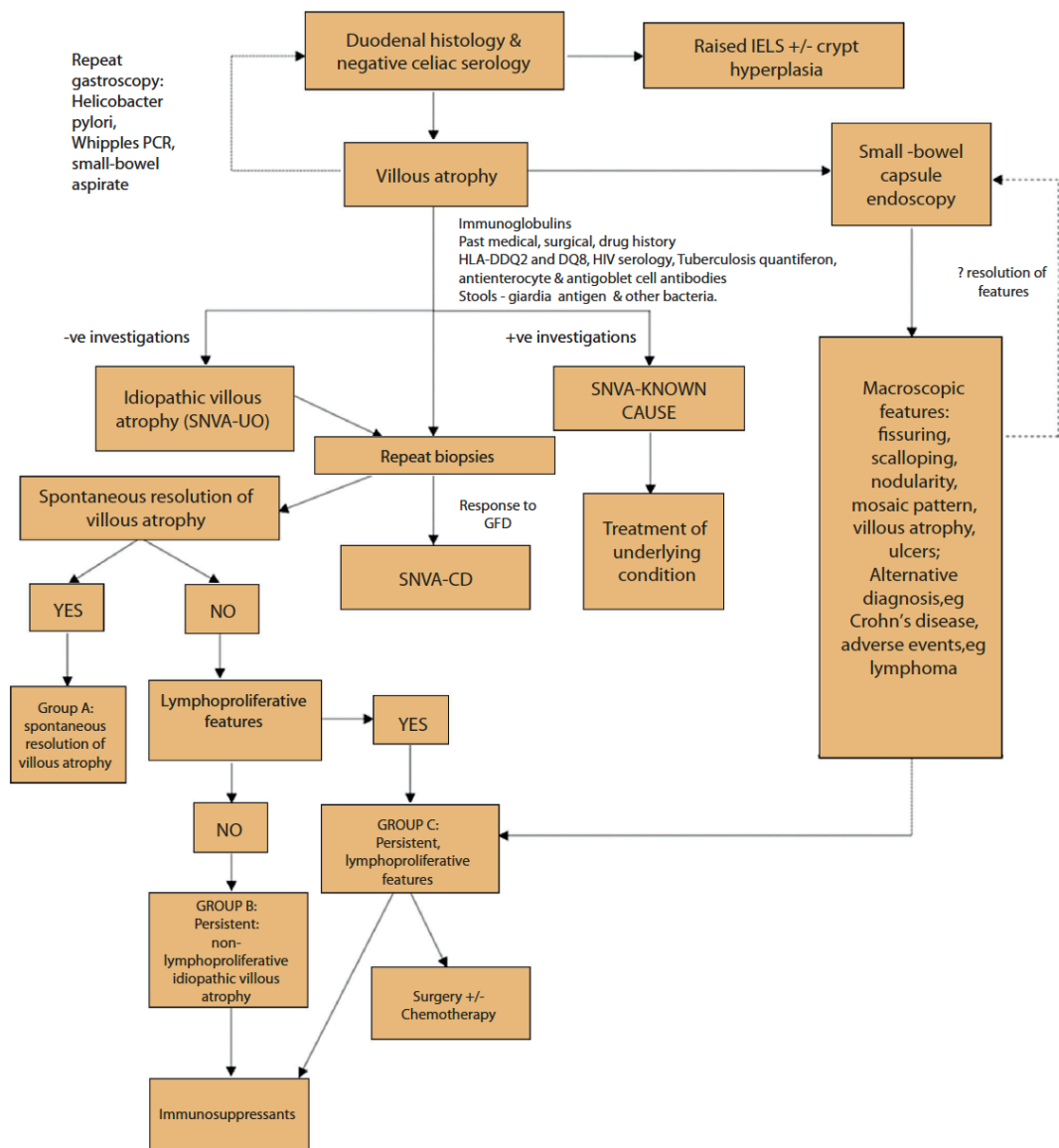
For the purpose of this paper, a histological response (as opposed to a clinical response) to a GFD was considered to be diagnostic of SNVA-CD (group 2). This is a stricter criteria than a clinical response to a GFD and eliminates the risk of diagnosing patients incorrectly as it is well known that in some patients, a clinical response to a GFD does not mirror a histological response (Pallav et al, 2012).

Patients with no identifiable cause for SNVA (SNVA-UO) all had alternative causes for SNVA excluded. They were further subclassified into patients with: a) resolving /transient SNVA, b) persistent histological changes and no response to a GFD, c) persistent histology despite a trial of GFD and with lymphoproliferative disorders before or after the diagnosis of SNVA (Figure 20).

Patients with SNVA-CD (group 2) had a histological response to a GFD. Other supporting features included raised IgG celiac serology, features such as dermatitis herpetiformis, a positive first degree family history of CD and HLA genotype supportive of a diagnosis of SNVA-CD.

Patients in group 3 had a cause for VA in their past medical history or by testing for infective and inflammatory conditions. Patients in group 4 had a diagnosis of Marsh grade 1 or 2 but no evidence of VA.

All of these patients underwent extensive investigations as outlined in the criteria above and in Figure 20.



**Figure 20:** Algorithm for the diagnosis and management of patients with seronegative villous atrophy or having duodenal histology of Marsh 1 and 2

IELs: raised intraepithelial lymphocytes, SNVA: seronegative villous atrophy; SNVA-UO: seronegative villous atrophy of unknown cause; SNVA-CD: seronegative villous atrophy secondary to coeliac disease

### 7.3.5 Small bowel capsule endoscopy

Each patient was asked to stay on clear fluids for 24 hours before the SBCE and to drink 2 liters of Klean-Prep® the day before the SBCE. All patients underwent SBCE using Pillcam SB 2 or 3 (Medtronic, Minneapolis, USA) (Scapa et al, 2002; Zwinger et al, 2018). SBCEs were reviewed by expert SBCE reviewers (>300 capsules each/ year). The expert reviewers of the capsule endoscopies were aware of the clinical picture including symptoms at presentation, findings on duodenal histology, serological results and findings on previous SBCEs. Findings such as fissuring of mucosa, scalloping of folds, mosaic pattern, nodularity, VA and ulcers were recorded. Currently there is no validated scoring system for the diagnosis of CD on SBCE. Features associated with CD have been studied before. These include fissuring of mucosa, scalloping of folds, mosaic pattern, nodularity, VA and ulcers (Culliford et al, 2005; Murray et al, 2008; Rondonotti et al, 2007). Hence a similar assessment was used for patients in this study at the time of reporting. A SBCE was considered to be positive (positive diagnostic yield, DY) if three or more features of CD mentioned above were present.

The distribution (proximal, mid, distal, diffuse SB) and extent of affected SB mucosa was also recorded.

In this study, extent of abnormal SB mucosa refers to SB mucosa with macroscopic features of CD.

### 7.3.6 Statistical analysis

Statistical analysis was carried out using SPSS version 23 (IBM Corp. Released 2015. IBM SPSS Statistics for Mac, Version 23.0. Armonk, NY: IBM Corp.). Frequencies and means were calculated to characterise each group. Non-parametric statistical tests were used namely, Fisher's exact test and Kruskal-Wallis test Results were considered to be statistically significant if the p value was less than 0.05.

### 7.3.7 Ethical considerations

The study protocol was approved by the Yorkshire and the Humber Research Ethics committee (IRAS 232382) and registered with the local research and

development department of Sheffield Teaching Hospital NHS Foundation Trust under the registration number STH 19998. All images used in this study were deidentified. No additional consent was required for the study with the use of deidentified videos as assessed and approved formally by the Research Ethics Committee.

#### 7.4 Results

A total of 177 patients (107 females, 60.5%; mean age of 49.7+/-16.9 years) were included in this study. They underwent a SBCE within a median of 93 days from histological diagnosis. The median time between index SBCE and repeat histology was 125 days. Most patients only had proximal SB disease (33, 58.9%) (Table 28).

**Table 28:** Features on capsule endoscopy in patients with raised IELs +/- crypt hyperplasia and SNVA

<b>Features on SBCE</b>	<b>N (%)</b>
Fissuring	13 (7.3)
Scalloping	18 (10.2)
Nodularity	3 (1.7)
Mosaicism	20 (11.3)
Villous atrophy	23 (13.0)
Ulcers	16 (9.0)
<b>Region</b>	<b>N (%)</b>
Proximal	33 (58.9)
Proximal, mid	7 (12.5)
Proximal, distal	1 (1.79)
Mid	3 (5.36)
Mid, distal	1 (1.79)
Distal	6 (10.7)
Diffuse	5 (8.93)

Only 5 patients (2.8%) had incomplete visualisation of the SB on SBCE. One patient with diffuse features of SNVA on SBCE had a repeat complete SBCE that showed duodenitis only. This patient had SNVA-UO. Repeat duodenal histology showed persistent TVA. Two patients (1 had raised IELs on histology, another patient had SNVA-UO) did not have any features of SNVA on SBCE and they did not undergo a repeat SBCE. The patient with SNVA-UO and a normal SBCE had spontaneous resolution of SNVA confirmed on repeat duodenal histology. Two patients with incomplete SBCE had proximal SB ulcers. One patient was treated for *Helicobacter pylori*. Another patient with a history of non-steroidal anti-inflammatory drug (NSAID) use underwent repeat duodenal histology that was normal after stopping NSAIDs for 6 months.

There was no statistical difference in DY according to age at diagnosis (median age SBCE positive: 51 years, SBCE negative: 50 years;  $p=0.804$ ), human leukocyte antigen (HLA) status ( $p=0.608$ ), ethnicity ( $p=0.531$ ) and gender ( $p=0.188$ ).

#### 7.4.1 Group 1 (seronegative villous atrophy- unknown)

Fifty-five patients (31.1%) had no identifiable cause for SNVA. The DY of SBCE was 40% (22) in this group of patients.

Thirty-nine patients (70.9%) had spontaneous resolution of SNVA on histology. Eleven (20.0%) patients had persistent SNVA. Five (9.1%) patients had persistent SNVA and developed lymphoproliferative features. SBCE was positive in 8 (20.5%) of those with spontaneous resolution of SNVA, 10 (90.9%) of patients with persistent SNVA and 4 (80.4%) patients with persistent SNVA who developed lymphoproliferative features ( $p=0.0001$ ).

Eight patients ( $n=11$ ; 72.7%) with persistent SNVA on histology received further treatment including steroids +/- immunosuppressants: (Budesonide - 4 patients, budesonide and 6-mercaptopurine – 1 patient, prednisolone and azathioprine – 2 patients, prednisolone and adalimumab – 1 patient). One patient received vedolizumab for a diagnosis of ulcerative colitis. Six patients ( $n=11$ ; 54.5%) underwent a repeat SBCE which showed persistent changes on SBCE. Another

patient (n=11; 9.0%) had a normal repeat SBCE. All 11 patients with persistent SNVA underwent repeat duodenal biopsies showing persistent VA.

In the group of patients with persistent SNVA and lymphoproliferative features, 3 patients had a history of chronic lymphocytic leukaemia, large B-cell lymphoma and non-Hodgkin's lymphoma respectively. One patient received budesonide. Another patient received prednisolone and azathioprine. The same patients who received treatment also underwent a repeat SBCE that showed persistent changes of SNVA on SBCE. Another 2 patients developed angioimmunoblastic T-cell lymphoma and indolent mature B-Cell lymphoma following their diagnosis of SNVA.

#### 7.4.2 Group 2 (seronegative villous atrophy – coeliac disease)

19.8% (35) of patients in this study had a histological response to a GFD and were therefore classified as having SNVA-CD. Five of these patients (14%) were IgA deficient. The DY of SBCE in this group of patients was 51.4% (n=35; 18). Seven patients developed complications: three patients developed RCD I and two developed RCD 2. Two patients developed RCD 2 and ulcerative jejunoileitis. All had a positive SBCE at the time of diagnosis (p=0.022). They also had more extensive SB disease than those without complications (50% vs 1% p=0.002).

#### 7.4.3 Group 3 (identifiable cause)

37 patients (20.9%) had alternative causes for SNVA (Table 29). The DY of SBCE in patients with identifiable causes for SNVA was 10 (27.0%). Three of these patients had SB ulcers secondary to Helicobacter pylori, NSAIDs and Crohn's disease respectively. From those patients with a positive SBCE, who had repeat duodenal histology, only one patient had persistent SNVA.

**Table 29:** Causes for SNVA in group 3

<b>Causes</b>	<b>N (%)</b>
NSAIDs	5 (13.5)
H pylori	13 (35.1)
Giardia	6 (16.2)
Tuberculosis	3 (8.1)
Medications*	3 (8.1)
Infective **	4 (10.8)
Crohn's disease	1 (2.7)
Autoimmune	1 (2.7)
Radiation enteritis	1 (2.7)

\* Aspirin: 1 patient; Angiotensin receptor blocker: 2 patients;

\*\* Recent diagnosis of gastroenteritis: 2 patients; Positive duodenal aspirate (small intestinal bacterial overgrowth): 1 patient; hookworm infection: 1 patient;

#### 7.4.4 Group 4 (raised intraepithelial lymphocytes+/- crypt hyperplasia)

Fifty patients (28.2%) had raised IELs (Marsh class I). In addition, 5 of these patients (10.0%) also had crypt hyperplasia (Marsh grade 2). All patients had negative endomysial antibodies (EMA) and anti-tissue transglutaminase (TTG) except for 4 patients who had a mean anti-TTG of 20 (U/mL).

On repeat (36 patients) duodenal histology, 26 patients (72.2%) had normal histology after a mean of 45 +/-SD 40.8 months. Seven patients (19.4%) had persistence of Marsh 1 and 2 disease, 1 patient (2.78%) had non-specific duodenitis on repeat histology. Two patients (5.56%) had Marsh grade 3 disease.

The DY of SBCE was only 14% (7 patients). One patient had proximal VA. Six patients had ulcers in their SB (4 distal, 1 mid, 1 diffuse). Two of these were eventually diagnosed with Crohn's disease. The others had underlying infective aetiologies, which included tuberculosis in 2 patients.



Three patients with a positive SBCE, had repeat duodenal histology that was normal. Four patients with a normal SBCE had repeat duodenal histology which was normal in 3 cases.

Causes for histological changes in group 4 can be found in Table 30.

**Table 30:** Causes of raised intraepithelial lymphocytes +/- crypt hyperplasia in group 4

Causes	N (%)
H pylori	6 (12)
Celiac disease	2 (4)
Tuberculosis	2 (4)
Medications*	6 (12)
Transient /Infective	10 (20)
Crohn's disease	3 (6)
Small intestinal bacterial overgrowth	2 (4)
Sarcoidosis**	1 (2)
Undiagnosed in	18 (36)

\*aspirin: 3, NSAIDs: 3; \*\*patient with an established history of gastric sarcoidosis

#### 7.4.5 Comparison of groups

There was no statistical difference in age at diagnosis across study groups (median age: group 1: 50, group 2: 52, group 3: 51, group 4: 48.5 years;  $p=0.704$ ).

The HLA status is shown in Table 31 ( $p=0.0001$ ).

**Table 31: HLA status in patients with SNVA (p=0.0001)**

	DQ2 DQ8 heterozygous n(%)	DQ2 DQ8 homozygous n(%)	DQ2 heterozygous n(%)	DQ8 heterozygous n(%)	DQ2 homozygous n(%)	DQ8 homozygous n(%)	DQ2 DQ8 negative n(%)
Group 1 (SNVA- UO)	2 (3.6)	0 (0)	17 (30.9)	6 (10.9)	2 (3.6)	0 (0)	26 (47.3)
Group 2 (SNVA- CD)	4 (11.4)	0 (0)	10 (28.6)	2 (5.7)	15 (42.9)	1 (2.9)	3 (8.6)*
Group 3 (SNVA- KNOWN CAUSE)	1 (2.7)	0 (0)	13 (35.1)	2 (5.4)	0 (0)	0 (0)	16 (43.2)
Group 4 (Raised IELs)	0 (0)	1 (2.0)	18 (36.0)	5 (10.0)	5 (10.0)	0 (0)	21 (42.0)

\*Two of the patients who were HLA-DQ2, DQ8 negative in the SNVA-CD group were HLA D Qa1\*05 positive which is a genotype that is also compatible with CD.

There was no statistical difference in gender across groups (p=0.178). Most patients were predominantly Caucasian (p=0.001, p=0.002) (Table 32, Table 33).

**Table 32:** Ethnicity across different groups (p=0.001)

	Ethnicity	
	Caucasian n(%)	Non-white n(%)
Group 1 - SNVA-UO	50 (90.9)	5 (9.1)
Group 2 - SNVA-CD	35 (100)	0 (0)
Group 3 - SNVA-KNOWN CAUSE	27 (73.0)	10 (27.0)
Group 4 - Raised IELs +/- crypt hyperplasia	39 (78.0)	11 (22.0)

SNVA-UO: Seronegative villous atrophy of unknown cause; SNVA-CD: Seronegative villous atrophy secondary to coeliac disease; IELs: intraepithelial lymphocytes.

**Table 33:** Ethnicity across different groups (p=0.002)

	British Caucasian n(%)	African n(%)	Asian n(%)	Bangladeshi n(%)	Chinese n(%)	Irish n(%)	Pakistani n(%)	Spanish n(%)
Group 1 - SNVA-UO	50 (90.9)	1 (1.8)	2 (3.6)	0 (0)	1 (1.8)	0 (0)	1 (1.8)	0 (0)
Group 2 - SNVA-CD	35 (100)	0 (0)	0 (0)	0 (0)	0 (0)	0 (0)	0 (0)	0(0)
Group 3 - SNVA- KNOWN CAUSE	27 (73.0)	2 (5.4)	8 (21.6)	0 (0)	0 (0)	0 (0)	0 (0)	0 (0)
Group 4 - Raised IELs +/-crypt hyperplasia	38 (76.0)	1 (2.0)	3 (6.0)	2 (4.0)	0 (0)	1 (2.0)	4 (8.0)	1 (2.0)

SNVA-UO: Seronegative villous atrophy of unknown cause; SNVA-CD: Seronegative villous atrophy secondary to coeliac disease; IELs: intraepithelial lymphocytes.

Patients with SNVA-UO and those with SNVA-CD were more likely to have positive SBCEs. Those with raised IELs /crypt hyperplasia were more likely to have normal SBCEs ( $p=0.001$ ) (Table 34). Patients with SNVA-UO and SNVA-CD also had the most extensive disease ( $p=0.018$ ) (Table 34).

**Table 34:** Positive SBCE / diagnostic yield and extent of disease on SBCE

	Findings of SNVA on SBCE (p=0.001)		Mean percentage extent of disease (p=0.018)
	Absent N (%)	Present N (%)	(%+/-SD)
Group 1 (SNVA-UO)	33 (60.0)	22 (40.0)	10.2 (+/-26.5)
Group 2 (SNVA-CD)	17 (48.6)	18 (51.4)	8.41 (+/-20.3)
Group 3 (SNVA-KNOWN CAUSE)	27 (73.0)	10 (27.0)	5.49 (+/-22.9)
Group 4 (Raised IELs +/- crypt hyperplasia)	43 (86.0)	7 (14.0)	2.47 (+/-14.2)

Features of SNVA were similar in groups 1 (SNVA-UO) and 2 (SNVA-CD). Patients in groups 3 (SNVA KNOWN CAUSE) and 4 (raised IELs +/- crypt hyperplasia) more commonly had ulcers (Table 35).

**Table 35:** Features of all patients on SBCE

	Group 1 (SNVA-UO)	Group 2 (SNVA-CD)	Group 3 (SNVA KNOWN CAUSE)	Group 4 (Raised IELs)	P value
Fissuring	8 (14.5)	5 (14.3)	0 (0)	0 (0)	0.0001
Scalloping	11 (20.0)	6 (17.1)	1 (2.7)	0 (0)	0.0001
Nodularity	1 (1.8)	2 (5.7)	0 (0)	0 (0)	0.185
Mosaicism	10 (18.2)	10 (28.6)	0 (0)	0 (0)	0.0001
Villous atrophy	11 (20.0)	7 (20.0)	4 (10.8)	1 (2.0)	0.012
Ulcers	3 (5.7)	2 (5.7)	5 (13.9)	6 (12.0)	0.471

In patients with VA (groups 1–3), those with more severe histological pattern on duodenal biopsies were more likely to have a positive SBCE (PVA: 21, 26%, SVA: 12, 60%, TVA: 13, 59%,  $p=0.001$ ). More extensive SB disease also corresponded to a more severe histological pattern (PVA 1%, SVA 15%, TVA 17%,  $p=0.001$ ).

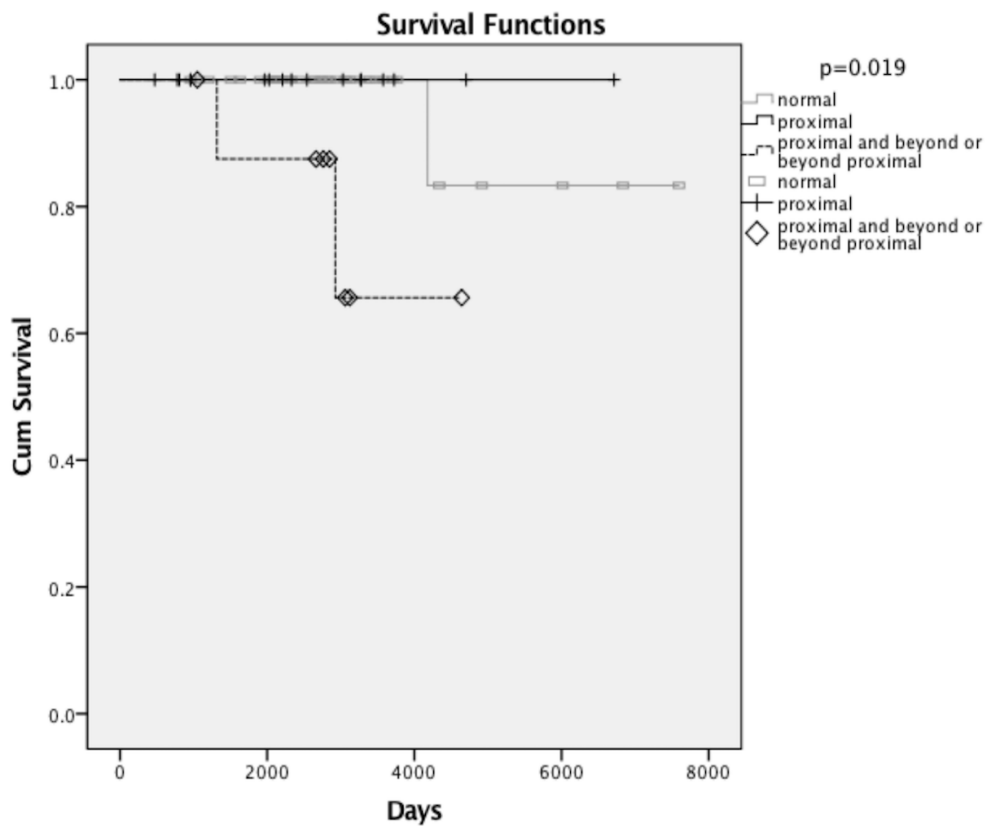
Eight (14.5%) patients within group 1 (SNVA-UO) had a positive second SBCE after a mean of 19 months (+/-SD 7.1). These patients had their immunosuppressive medications altered. A third SBCE was carried out in 3 patients in group 1 (SNVA-UO after a mean of 14 months (+/-0.1)). All of them had a positive SBCE. All patients (5, 14.3%) who had a repeat SBCE within group 2 (SNVA-CD) had persistently positive findings ( $p=0.643$ ). This resulted in further dietary review to ensure strict adherence to a GFD. Where this was confirmed and on reviewing histology a diagnosis of RCD was made prompting commencement of steroids and immunosuppressants.

Two patients in group 3 (SNVA-KNOWN CAUSE) (5.41%) had a repeat SBCE. In one patient the repeat SBCE was normal. In another patient florid ulceration was present. This patient was diagnosed and started treatment for Crohn's



disease. The first SBCE had also shown ulcers. Three patients (6.0%) in group 4 (raised IELs +/- crypt hyperplasia) had repeat SBCEs. One patient had distal SB ulcers and was treated for TB. This patient was not known to have TB prior to their investigations and she was of Asian ethnicity. Another patient had mosaic pattern of the mucosa proximally and had been on regular NSAIDs. Another patient had a normal SBCE.

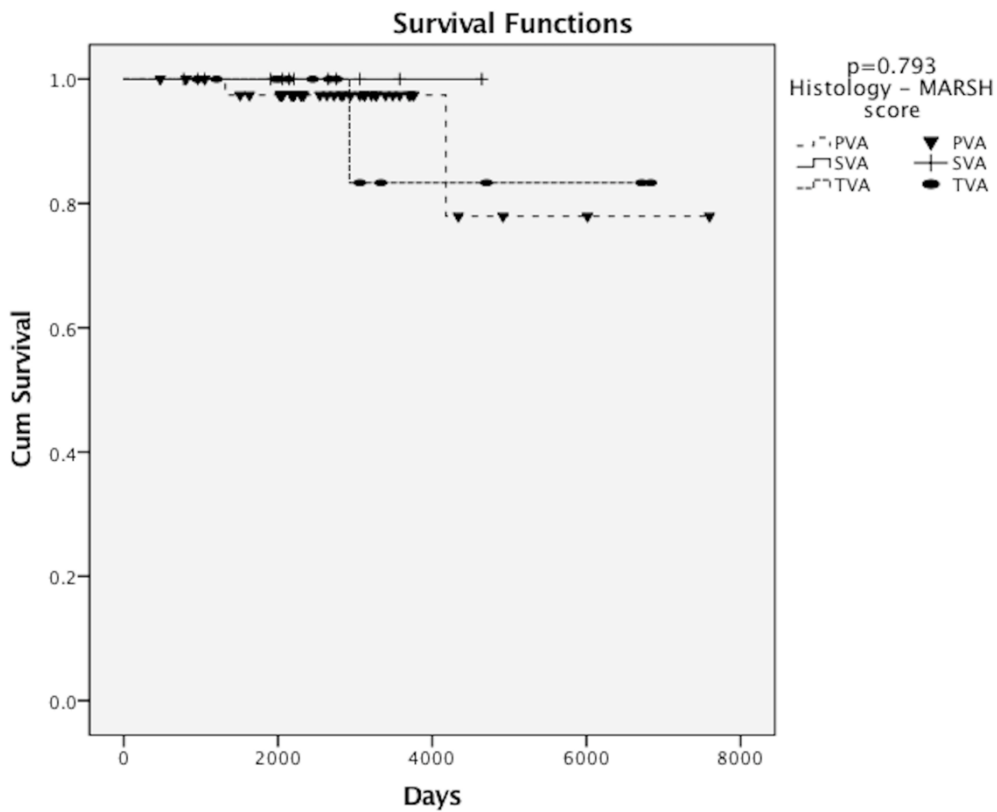
Overall, 11 patients (6.2%) passed away (all-cause mortality) by the end of the follow-up period (mean duration of follow-up  $8 \pm 6$  years). There was no statistical significant difference in mortality across groups (group 1: 3, 5.5%, group 2: 4, 11.4%, group 3: 3, 8.1%, group 4: 1, 2.0%  $p=0.327$ ). However, when only deaths related to SNVA were considered, mortality was highest in the SNVA-CD group (3; 8.6%) secondary to RCD complications. One patient (1.8%) with SNVA-UO passed away from lymphoma ( $p=0.048$ ). None of the patients in groups 3 and 4 passed away from CD-related causes. On constructing, survival curves for patients with SNVA-UO and SNVA-CD (CD-related mortality), patients with extensive SB involvement had worse survival than those with normal or proximal involvement on SBCE ( $p=0.019$ ) (Figure 21). There was no correlation between survival and severity of duodenal histology (mean duration of follow-up  $8 \pm 6$  years) ( $p=0.793$ ) (Figure 22).



**Figure 21:** Mortality in group 1 (SNVA-UO) and 2 (SNVA-CD) from CD-related causes

(Normal: no features of SNVA on SBCE; proximal: features of SNVA in the proximal third of the small bowel; proximal and beyond or beyond proximal: features of SNVA that extend beyond the proximal small bowel or involve mid and distal small bowel;

SNVA-UO: SNVA of an unknown cause, SNVA-CD: SNVA secondary to coeliac disease)



**Figure 22:** Mortality in group 1 (SNVA-UO) and 2 (SNVA-CD) patients from CD-related causes according to severity of duodenal histology

(PVA: partial villous atrophy, SVA: subtotal villous atrophy, TVA: total villous atrophy, SNVA-UO: SNVA of an unknown cause, SNVA-CD: SNVA secondary to coeliac disease;)

## 7.5 Discussion

This study describes the findings on SBCE in subgroups of patients with different causes for SNVA in the SB and in this aspect it is the first of its kind. It highlights how SBCE at the time of diagnosis of SNVA can be important in the prediction of disease course and in the identification of features such as SB ulcers that need follow up and could be consistent with other diagnoses such as Crohn's disease. There are only 2 studies on the use of SBCE in patients with SNVA. In a study by Kurien et al, patients with equivocal CD were compared to patients with non-responsive CD. Patients with equivocal CD were further subdivided into 32 patients with SNVA and 30 with Marsh grade 1 or 2 histology. In those patients with SNVA, 28% had a positive SBCE that showed features of CD or Crohn's disease. This is slightly lower than the overall DY reported in this study (group 1–3: 39.4%). In patients with Marsh 1 and 2, 1 patient was diagnosed with CD and another with SB Crohn's disease (Kurien et al, 2013). This is much lower than the DY reported in this study for a similar group of patients (14%). In another study by Lujan-Sanchis et al, 19 patients with SNVA-CD had a DY of 73.7% (Lujan-Sanchis et al, 2017). This is higher than the DY for group 2 (SNVA-CD 51.4%) in this study. One explanation for the difference in DY is the stricter diagnostic criteria that was used to diagnose SNVA-CD in this study: histological response to a GFD.

The utility of SBCE in subgroups of patients with SNVA was further assessed in this study. Patients with SNVA-UO and SNVA-CD were most likely to have positive SBCEs and they were likely to have the most extensive SB involvement unlike patients with an identifiable cause for SNVA and those with raised IELs +/- crypt hyperplasia. Therefore, patients with SNVA who also have positive findings on SBCE are more likely to fall within one of these 2 groups of underlying etiology. The cause of SNVA / Marsh 1 and 2 histology is not always established at the time of initial investigations. Patients with a negative SBCE are more likely to have an underlying cause to explain the histological changes. It is important that this is ruled out by means of a thorough history and secondary investigations such as further duodenal biopsies for TB. In groups 3 and 4, SBCE was also helpful as it identified patients with SB ulcers. Patients with a diagnosis of

tuberculosis, were not known to have the condition prior to investigations for SNVA, Marsh 1 and 2 histology. Those with changes secondary to NSAIDs use only admitted to their intake on further questioning. It has been suggested that patients with SB ulcers will benefit from a repeat SBCE after at least 6 to 8 months to ensure healing of the SB mucosa (Chetcuti Zammit et al, 2019b).

In this study, a correlation between extent of SB disease and survival in patients with SNVA-UO and SNVA-CD was established. However, a similar relationship with duodenal histology was not confirmed. These findings establish an additional role for SBCE in predicting disease outcome. In patients with SNVA-UO, a positive SBCE was associated with persistent positive histology at follow up. This association highlights the fact that patients with macroscopic SB changes need to be targeted early with immunosuppressive therapy (DeGaetani et al, 2013) due to the risk of persistent disease that in turn can be associated with risks of malabsorption and the development of lymphoproliferative disorders. Patients with SNVA-CD can develop complications such as RCD, ulcerative jejunoileitis, lymphoma and adenocarcinoma similar to patients with seropositive CD (Barret et al, 2012; Tomba et al, 2016). All patients who eventually developed complications in the SNVA-CD group had a positive SBCE and they also had more extensive disease than patients with uncomplicated SNVA-CD. These findings underline the important role SBCE can play in patients with SNVA-CD where the main treatment is a GFD. Patients with SNVA-CD with a positive SBCE can be monitored more closely due to the higher risk of developing complications.

Mortality in patients with SNVA has been compared to that in seropositive CD patients in 2 studies (English and Italian studies), both confirming the higher mortality in the former group. In one study the mortality in SNVA-CD, SNVA-non-CD, seropositive CD patients was 11.2%, 8.7% and 3.2% respectively (Aziz et al, 2017). In another study, mortality was 6 deaths /100 person years in patients with SNVA, whereas only 0.2 deaths /100 person years were reported in seropositive CD patients (Schiepatti et al, 2017). These findings tie in with other differences that distinguish SNVA-CD and seropositive CD. The former tend to be older and have a higher risk of complications (Salmi et al, 2006). In this study, CD-related mortality was highest in the SNVA-CD group. This is secondary to

RCD-related complications. Survival in patients with SNVA-UO and SNVA-CD correlated inversely with extent of mucosal involvement on SBCE. This confirms the importance of regularly screening patients with SNVA-CD for complications and managing those with extensive disease aggressively.

A limitation of the study is the small cohort of patients included. However, other studies on patients with SNVA undergoing SBCEs have included an even smaller number of patients (up to 32 with SNVA, 30 Marsh I, II) (Kurien et al, 2013; Lujan-Sanchis et al, 2017). Other limitations include the single center nature of this study and the broad time interval for data collection. Expert capsule reviewers were also not blinded to the clinical findings, serology and duodenal histology results. This might have resulted in over or under reporting of features of SNVA on SBCE. Additionally, a few patients did not have HLA assays and some of them did not have a second duodenal biopsy. Not all patients with SNVA, raised IELs+/- crypt hyperplasia during the study period had a SBCE. In addition, only a few patients had a repeat SBCE and repeat duodenal histology as decided by the caring physician which resulted in very small numbers of patients with repeat investigations. A repeat SBCE is useful to re-assess disease extent, assess response to therapy and in some cases (raised IELs+/- crypt hyperplasia) it can help to clarify the diagnosis. This made it difficult for us to draw any conclusions from features on repeat SBCEs.”

## 7.6 Conclusion

SBCE can be useful in patients diagnosed with SNVA or Marsh 1 and 2 histology as it can identify features of CD or other conditions such as distal inflammation that can be associated with SB Crohn's disease. Unlike duodenal histology, SBCE can play an additional role in predicting disease outcome. In patients with SNVA-UO, positive findings on SBCE and more extensive disease can predict those with persistent SNVA who will require treatment with immunosuppressants. In SNVA-CD the same pattern is true for patients who eventually develop CD-related complications. In both SNVA-CD and SNVA-UO, more extensive disease on SBCE is indicative of a poorer prognosis. These patients need to be monitored more closely and alternative therapy such as steroids and immunosuppressants considered if complications develop. Although the number

of patients with repeat SBCE in this study is small, re-evaluation of disease extent using SBCE can result in modification of therapy in patients with persistent or progressive changes.

## **Chapter 8 – Small bowel capsule endoscopy in patients with refractory coeliac disease**

### 8.1 Abstract

#### 8.1.1 Background

There is no literature on the role of repeat small bowel capsule endoscopy (SBCE) in patients with refractory coeliac disease (RCD) following treatment with steroids +/- immunosuppressants. The aims of this study were to assess whether SBCE can provide additional information on RCD at the time of diagnosis and to assess the role of follow-up SBCE after treatment with steroids +/- immunosuppressants.

#### 8.1.2 Materials and methods

The findings on SBCEs from a group of patients with histologically proven RCD were compared to the findings from patients with uncomplicated coeliac disease (CD). All patients had concurrent duodenal histology and serology taken at the time of SBCE.

#### 8.1.3 Results

A group of patients with RCD (n=23, 32.4%) were compared to a group of patients with uncomplicated CD (n=48, 67.6%). Patients with RCD had a greater extent of mucosal involvement on SBCE than patients with uncomplicated CD (42.4±34.1% vs 9.7±21.7%, p=0.0001).

Following treatment with steroids and / or immunosuppressants, patients with RCD had an improvement in the extent of affected small bowel (SB) mucosa (42.4±34.1% vs 26.4±28.9% p=0.012). There was no statistical difference in histology and serology taken at the time of the first and second SBCE in patients with RCD.

#### 8.1.4 Conclusions

This study suggests that SBCE is valuable in documenting the extent of mucosal involvement in patients with RCD. This is the first study that delineates the value



of a second look SBCE to assess improvement in extent of disease in the SB following treatment.

## 8.2 Introduction

CD has a prevalence of about 1% in the general population (Green & Cellier, 2007; Rostom et al, 2006). About 0.31 to 10% of patients with CD go on to develop RCD (Illus et al, 2014; Liu et al, 2010; Rowinski & Christensen, 2016; Wahab et al, 2002; West, 2009). Such a varied prevalence of RCD reflects the difficulties encountered when diagnosing RCD on histology (Liu et al, 2010). Persistent symptoms, absence of gluten ingestion for at least 6 to 12 months and persistence of histological changes on duodenal biopsies define RCD (Biagi & Corazza, 2001).

The absence of (Type I) or presence (Type II) of abnormal intraepithelial lymphocytes on duodenal histology can distinguish between the 2 subtypes of RCD (Nijeboer et al, 2013). PCR gene amplification on cells can differentiate between polyclonal (Type I) T cell receptors and monoclonal T cell receptors (Type II) (Cellier et al, 2000; Daum et al, 2001).

RCD type I has the same histological appearance as uncomplicated CD with normal surface CD3 and CD8 expression and intracellular CD3 in intraepithelial lymphocytes that is similar in patients with a persistent ingestion of gluten (Liu et al, 2010). It is therefore crucial to rule out gluten contamination when RCD is suspected as otherwise an inappropriate diagnosis of RCD I is made. Histological diagnosis of RCD II is also not full proof. An anomalous population of lymphocytes and a monoclonal T-cell receptor arrangement can also be found in the initial stages of CD diagnosis and in CD patients with persistent exposure to gluten (Liu et al, 2010; Prisco et al, 1997; Ubiali et al, 2007). Immunostaining can lead to a very inaccurate estimation of CD3+, CD8- cells (Liu et al, 2010). It also does not distinguish between surface and intracellular CD3 (Patey-Mariaud De Serre et al, 2000). Fresh biopsies are needed for flow cytometry which can also be affected by variable cell yields and the lack of localization of the cells isolated (Verbeek et al, 2008).

Repeat duodenal histology is currently recommended following 3 months of treatment in RCD I. If response to treatment is observed, duodenal biopsies are repeated annually with quantification of aberrant intraepithelial lymphocytes. Repeat histology is also recommended in RCD II following initial treatment with steroids (Woodward, 2016).

Despite duodenal histology currently being the gold standard for diagnosing RCD, the previously mentioned factors and the non-uniform pattern of CD in the SB (Ravelli et al, 2010), necessitate additional modalities for a confirmative diagnosis of RCD and for monitoring of its progression.

Endoscopic evaluation of the SB by SBCE is currently recommended whenever RCD is diagnosed (Pennazio et al, 2015). This is to ensure no complications related to RCD have developed. These commonly occur in the distal SB and include enteropathy associated small bowel lymphoma (EATL), B cell lymphoma, adenocarcinoma and ulcerative jejunoileitis (Daum et al, 2007).

In addition to being a useful modality in diagnosing complications, SBCE has the potential to provide information on the extent of disease (Daum et al, 2007). Although there has been some interest in SBCE providing information on the extent of diseased mucosa in the SB, this has only been assessed in patients with uncomplicated CD (Lidums et al, 2011b; Murray et al, 2008). No studies have looked at the extent of mucosal involvement at diagnosis of RCD and on second look SBCE to assess improvement in the extent of affected mucosa following treatment.

The aim of this study was to assess whether SBCE can provide additional information on RCD at the time of diagnosis apart from ruling out complications. The role of a follow up SBCE after treatment with steroids +/- immunosuppressants was also assessed.

## 8.3 Methodology

### 8.3.1 Study design and patients

Data on 23 consecutive patients with histologically confirmed RCD who underwent a SBCE was prospectively compared to data from 48 age and gender matched patients with uncomplicated CD with persistent symptoms requiring SBCE in whom RCD had been excluded histologically. The study was carried out at Sheffield Teaching Hospitals which is the national centre for the investigation and management of CD in the United Kingdom. They all underwent a gastroduodenoscopy with duodenal biopsies and a SBCE within 3 months of obtaining duodenal biopsies.

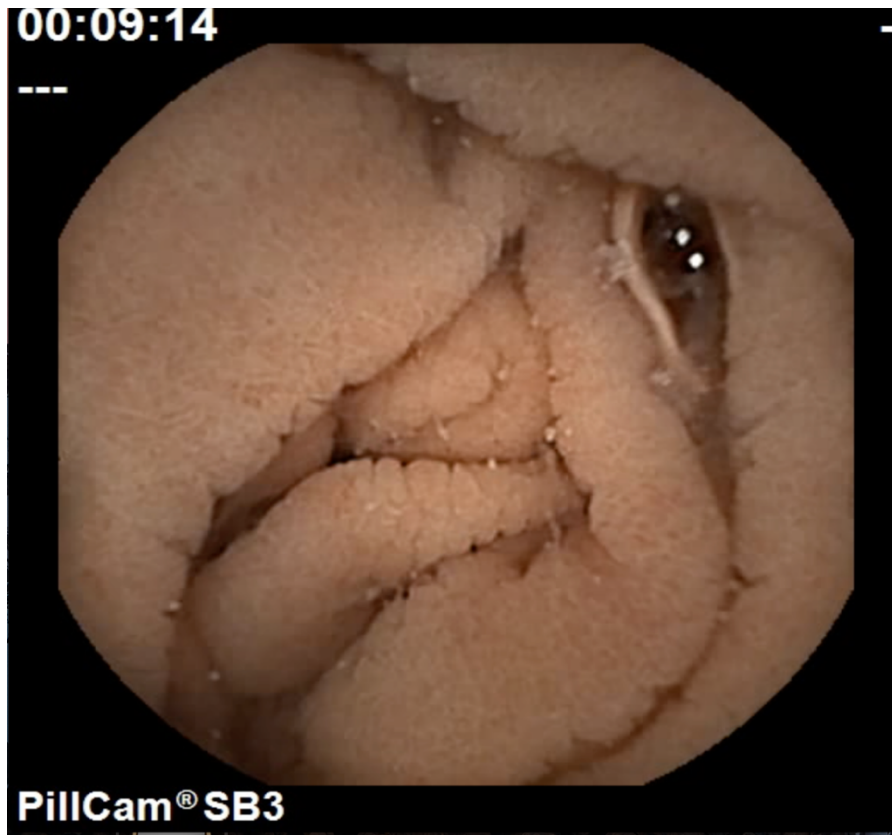
### 8.3.2 Duodenal histology

Details of histology that was obtained at the time of SBCE were collected. This was classified according to the modified Marsh Classification (Oberhuber et al, 1999). At least two samples from the duodenal bulb and four samples from the second part of the duodenum were taken during gastroduodenoscopy. The most severe histological grade for duodenal histology was considered as the overall histological grade for each patient. Initial reporting of duodenal histology was undertaken by one of three gastrointestinal histopathologists. All cases were then reviewed by a single gastrointestinal histopathologist with expertise in CD. Immunohistochemistry was performed on all samples for T-helper and T cytotoxic suppressor cells. Whenever a null clone was identified, T-cell receptor gene rearrangement studies were carried out to exclude the presence of lymphoma.

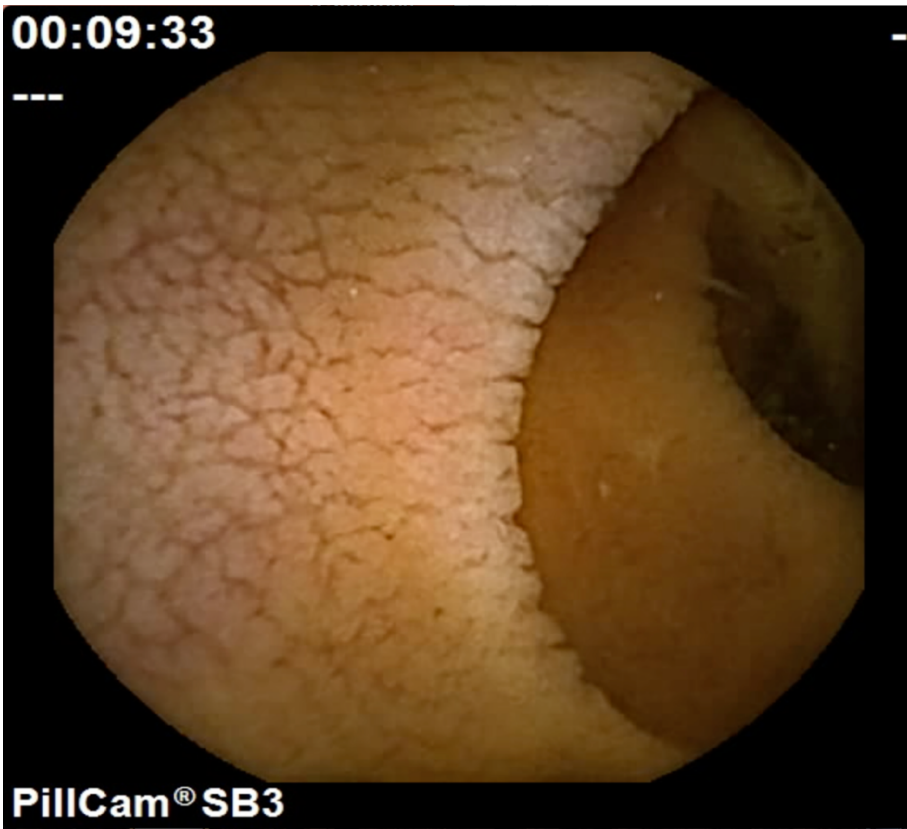### 8.3.3 Small bowel capsule endoscopy

Patients were asked to drink 2 litres of Klean-Prep® prior to undergoing SBCE. All patients underwent SBCE using the Pillcam SB3 (Medtronic, Minneapolis, USA) (Zwinger et al, 2018). Details on gastric and SB passage time, extent of abnormal SB and macroscopic features of CD on SBCE were carefully examined. Macroscopic features of CD included villous atrophy, nodularity and mosaic pattern of mucosa, fissuring, scalloping of folds and ulcers (Figure 23, Figure 24, Figure 25). The SBCEs were read by two expert reviewers including myself (more than 300 SBCEs per year) blinded to both indication for SBCE and to

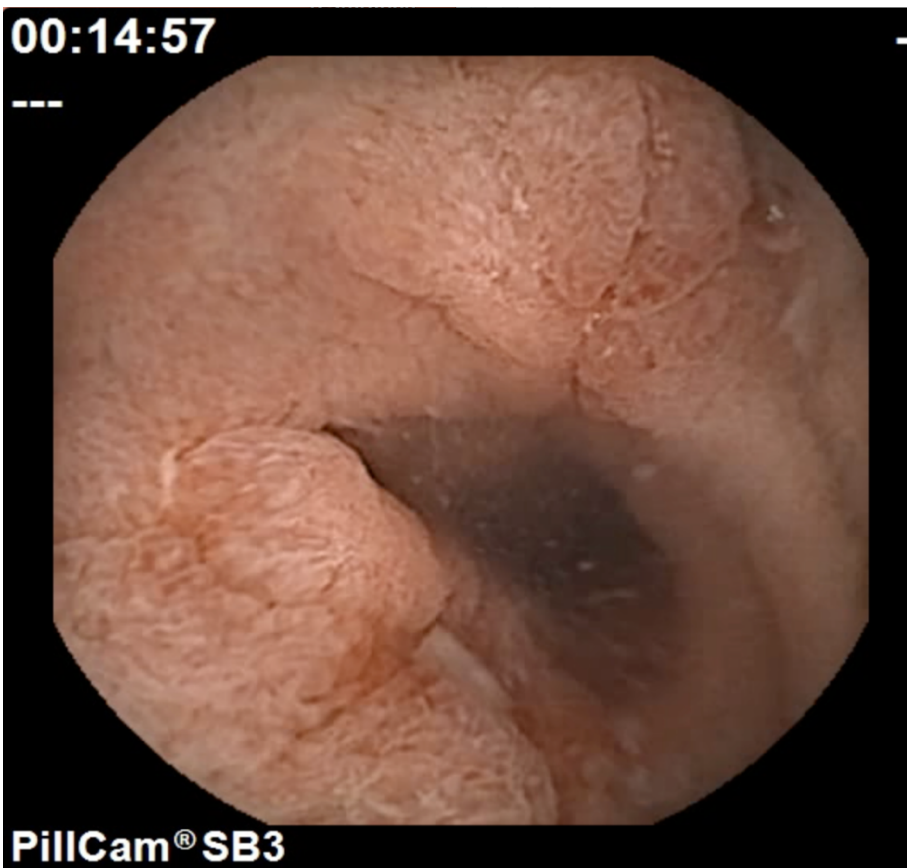
results of duodenal histology. In the case of disagreement about findings, a third expert reviewer was involved in the adjudication process.



**Figure 23:** Scalloping of mucosa in a patient with uncomplicated coeliac disease.



**Figure 24:** Fissuring and scalloping of mucosa in a patient with type I refractory coeliac disease.



**Figure 25:** Mucosal ulceration in a patient with refractory coeliac disease type II.

#### 8.3.4 Statistical analysis

Statistical analysis was carried out using SPSS version 23 (IBM Corp. Released 2015. IBM SPSS Statistics for Mac, Version 23.0. Armonk, NY: IBM Corp.). Descriptive data was measured in the form of frequencies and percentages in the case of categorical variables and using mean and standard deviations if variables were continuous. Non-parametric statistical tests were used in view of the small cohort of patients in this study. Fisher's Exact Test was used to compare categorical variables. The Mann-Whitney U test compared independent, continuous variables such as for example extent of disease on SBCE in both groups of patients. The Wilcoxon Signed Ranks Test was used to assess the statistical difference between 2 related variables for example the extent of disease on the first and second SBCE in patients with RCD. Results were considered to be statistically significant if the p value was less than 0.05.

#### 8.3.5 Ethical considerations

The study was approved by the local research and development department of Sheffield Teaching Hospital NHS Foundation Trust under the registration number STH19998.

### 8.4 Results

A total of 71 patients (51 females; 71.8%) with CD were included in this study. RCD was present in 23 patients (32.4%) and uncomplicated CD was present in 48 patients (67.6%). The mean age of patients at the first SBCE was 52.5 (SD±15.5) years and the mean duration of disease before undergoing the first SBCE was 84 (SD±105.4) months. There was no statistical difference in the mean age at first SCBE ( $p=0.176$ ), duration of disease ( $p=0.395$ ) and gender (0.171) between the 2 groups.

#### 8.4.1 Comparison of patients with refractory coeliac disease and uncomplicated coeliac disease

Patients with RCD had a more severe Marsh classification of disease on duodenal histology than patients with uncomplicated CD at the time of the first SBCE ( $p=0.034$ ) (Table 36).

Table 36: Marsh classification of histology in both groups of patients

Marsh classification	Coeliac disease	Refractory coeliac disease
0	6	1
	13.0%	4.3%
1	8	0
	17.4%	0.0%
2	5	0
	10.9%	0.0%
3a	8	4
	17.4%	17.4%
3b	10	8
	21.7%	34.8%
3c	9	10
	19.6%	43.5%

There was no statistical significant difference in the positivity of EMA ( $p=0.345$ ), levels of anti-TTG ( $p=0.691$ ), anti-gliadin antibody IgG ( $p=0.801$ ) and anti-gliadin antibody IgA ( $p=0.798$ ) between patients with uncomplicated CD and RCD.

Patients with RCD ( $n=9$ ; 39.1%) were more likely to have involvement beyond the proximal SB than patients with uncomplicated CD ( $n=4$ ; 8.3%) ( $p=0.003$ ). The length of abnormal mucosa and the percentage of abnormal SB mucosa were significantly longer in patients with RCD than in patients with uncomplicated CD ( $p=0.0001$ ). Patients with RCD had significantly more scalloping ( $p=0.001$ ), villous atrophy ( $p=0.017$ ) and ulcers ( $p=0.004$ ) in the SB than patients with uncomplicated CD (

Table 37). On applying the Bonferroni correction, the length of abnormal mucosa ( $p=0.001$ ), the percentage of abnormal SB mucosa ( $p=0.001$ ), the presence of scalloping (0.01) and ulcers ( $p=0.04$ ) in the SB retained statistical significance.



**Table 37:** Differences on capsule endoscopy in both groups

	Refractory coeliac disease (RCD) / uncomplicated coeliac disease (CD)	Mean	Std. Deviation	p value
Gastric passage time (minutes)	CD	27.1	26.4	0.606
	RCD	41.8	51.1	
Small bowel passage time (minutes)	CD	287.8	147.6	0.471
	RCD	296.5	102.1	
Time mucosa abnormal (minutes)	CD	30.5	72.1	0.0001
	RCD	137.0	121.5	
% abnormal mucosa	CD	9.7	21.7	0.0001
	RCD	42.4	34.1	
Villous atrophy	CD	8 (16.7%)		0.017
	RCD	10 (45.5%)		
Scalloping	CD	14 (29.2%)		0.001
	RCD	16 (72.7%)		
Mosaic pattern	CD	14 (29.2%)		0.287
	RCD	10 (43.5%)		
Ulcers	CD	1 (2.1%)		0.004
	RCD	6 (26.1%)		
Fissuring	CD	10 (20.8%)		0.389
	RCD	7 (30.4%)		
Nodularity	CD	1 (2.1%)		0.403
	RCD	1 (7.1%)		

#### 8.4.2 Patients with refractory coeliac disease

Most patients with RCD (16, 69.6%) had type I disease. Patients received the following between SBCEs: 6 patients (26.1%) received immunosuppressants (azathioprine, mycophenolate, 6-mercaptopurine), 10 patients (43.5%) were given budesonide or prednisolone, 5 patients (21.7%) received a combination of both immunosuppressants and steroids and 2 failed immunosuppressant therapy and were treated with interleukin 15 monoclonal antibody in addition to steroids. A SBCE was repeated after a mean of 17.0 months ( $SD\pm 12.1$ ) (Table 38).

**Table 38:** Characteristics of patients with refractory coeliac disease

Patient	Gender	Age at first SBCE	Marsh duodenal histology at first SBCE	Marsh duodenal histology at second SBCE	% extent small bowel mucosa on first SBCE	% extent small bowel mucosa on second SBCE	Treatment
1	male	55	3b	3c	49.8%	69.4%	mycophenolate
2	male	68	3c	1	15.6%	18.1%	budesonide
3	female	46	3c	3a	0.5%	5.9%	azathioprine
4	female	54	3b	3a	15.7%	15.7%	budesonide
5	male	67	3c	3b	74.8%	97.8%	budesonide
6	male	67	3c	3c	27.6%	34.2%	azathioprine
7	male	28	3c	3b	19.2%	4.4%	azathioprine
8	male	41	3c	3b	51.3%	21.6%	prednisolone
9	female	71	3a	0	100.0%	4.3%	prednisolone
10	female	51	3b	3b	3.4%	3.2%	budesonide, azathioprine
11	female	53	3c	3a	20.6%	15.2%	budesonide, mycophenolate
12	female	68	3b	3c	80.3%	29.7%	budesonide
13	female	51	3b	3a	77.9%	37.1%	azathioprine
14	female	74	3c	3a	98.2%	65.4%	budesonide
15	male	65	3c	3c	100.0%	85.5%	budesonide
16	female	69	3a	0	28.3%	15.8%	prednisolone, azathioprine
17	female	55	3a	3b	18.3%	0.0%	6-mercaptopurine, budesonide
18	female	56	3c	3b	22.6%	0.0%	budesonide
19	female	71	3b	3a	66.5%	11.0%	budesonide
20	female	25	0	0	0.0%	0.0%	6-mercaptopurine
21	male	49	3b	3a	54.1%	41.6%	budesonide, interleukin 15 monoclonal antibody
22	male	62	3b	3b	incomplete	incomplete	budesonide, interleukin 15 monoclonal antibody
23	female	38	3a	3b	8.0%	4.4%	budesonide, azathioprine

There was no statistical significant difference in the positivity of EMA ( $p=0.298$ ), levels of anti-TTG ( $p=0.328$ ) and anti-gliadin antibody IgG ( $p=0.345$ ) between the first and second SBCE in patients with RCD. Anti-gliadin IgA improved at the time of repeat SBCE (5.86 vs 3.87 U/ml) ( $p=0.003$ ).

There was no statistical difference in histology taken at the time of the first and second SBCE in patients with RCD ( $p=0.136$ ). However, there was an improvement in the length of abnormal SB mucosa ( $p=0.015$ ) and the percentage of affected SB mucosa ( $p=0.012$ ) when SBCE was repeated following treatment (Table 39).

**Table 39:** Comparison of features on first and repeat SCBE in patients with refractory coeliac disease

	Mean	Std. Deviation	p value
1st SCBE: Gastric passage time (minutes)	43.6	51.7	0.601
2nd SCBE: Gastric passage time (minutes)	31.1	28.1	
1st SCBE: Small bowel passage time (minutes)	296.5	102.1	0.765
2nd SCBE: Small bowel passage time (minutes)	307.5	144.5	
1st SCBE: Time mucosa abnormal (minutes)	137.0	121.5	0.015
2nd SCBE: Time mucosa abnormal capsule (minutes)	73.6	88.6	
1st SCBE: % abnormal mucosa	42.4%	34.1%	0.012
2nd SCBE: % abnormal mucosa	26.4%	28.9%	

Although the number of patients with RCD II was small, patients with RCD type II had a greater extent of SB mucosal involvement than those with RCD type I on both the first (76.7%  $\pm$ 21.2 vs 31.0%  $\pm$ 29.2,  $p=0.005$ ) and repeat SBCE (54.7%  $\pm$ 21.9 vs 15.7%  $\pm$ 23.8,  $p=0.001$ ).

## 8.5 Discussion

This is the first study that assesses the role of a second look SBCE in patients with RCD. An important finding is the decrease in the percentage of affected mucosa on repeating a SBCE in patients with RCD (from 42.4% to 26.4%).

The definition of RCD includes symptoms of malabsorption, persistent histological changes of villous atrophy (VA) and a thorough history confirming that a patient is following a strict gluten free diet (GFD) (Abdulkarim et al, 2002;

Biagi & Corazza, 2001; Leffler et al, 2007). Otherwise histological changes can be attributed to persistent gluten exposure (Ludvigsson et al, 2013). Even though serology is largely negative in patients with RCD, positive serology has been reported in between 13% and 49% of these patients (Malamut et al, 2009; Rubio-Tapia et al, 2009). My study has shown no difference in serological markers between patients with RCD and those with uncomplicated CD and no difference on repeating serological markers in patients with RCD. A diagnosis of RCD should be independent of serological antibody levels as current literature suggests that there is a low sensitivity for coeliac serology in detecting persistent VA in patients with CD (Silvester et al, 2017).

Distinguishing patients with RCD from those with uncomplicated CD is pertinent due to the risk of transformation from RCD I to II and the high mortality associated with RCD due to complications that can develop such as adenocarcinoma, EATL, B cell lymphoma and jejunoileitis (Biagi et al, 2014; Eigner et al, 2017; Elli et al, 2017; Malamut et al, 2013; Tomba et al, 2016). RCD I has a good prognosis with a 5 year survival of 96% (Al-Toma et al, 2007). Five year survival in patients with RCD II can vary between 53 to 58% but can be as low as 8% if EATL develops. Survival after 5 years from diagnosis is usually better (90 – 96%) in patients with RCD I (Al-Toma et al, 2007). Although a histological diagnosis is so far considered the gold standard for diagnosing RCD, the existence of some pitfalls in achieving a histological diagnosis of RCD means that this cannot be completely relied upon. This study provides an additional role for SBCE that can support a histological diagnosis of RCD by demonstrating more extensive SB disease in those with RCD.

Two studies exist on the use of SBCE to follow up patients with CD managed with a GFD. Murray et al, demonstrated improvement in the extent of intestinal involvement 6 months after GFD in 79% of patients (Murray et al, 2008). Lidums et al, demonstrated an improvement in VA macroscopically in 12 adult patients with CD on repeat SBCE after 12 months of GFD. However there was persistent villous abnormality on duodenal histology in 42% of patients (Lidums et al, 2011b). The main focus in this study was a special group of patients with RCD that require additional treatment to GFD. To date there is no study on the role of

a second look SBCE in the follow up of patients with RCD receiving steroids and / or immunosuppressants.

Management with a combination of steroids and / or immunosuppressants or ciclosporin is recommended when RCD I is diagnosed (Costantino et al, 2008; Gillett et al, 2002; Nasr et al, 2015; Schmidt et al, 2009; Wahab et al, 2000). RCD II is treated more aggressively with Cladribine or stem cell transplantation in view of the potential complications that can arise (Al-Toma et al, 2006; Al-toma et al, 2007; Tack et al, 2011a). Other treatment such as Interleukin 15 monoclonal antibody have been trialed in patients with RCD II (Cellier et al, 2018). RCD also responds less well to immunosuppressants and steroids (Goerres et al, 2003). The risk of enteropathy associated T cell lymphoma (EATL) can be potentially enhanced when Azathioprine is administered to patients with RCD II (Woodward, 2016). In a more recent study by Murray et al, patients with RCD I and II responded clinically and histologically to open capsule budesonide (Mukewar et al, 2017).

By using SBCE, an improvement in the extent of mucosal involvement following initiation of immunosuppressants +/- steroids has been confirmed. CD most commonly affects the proximal SB and the length of SB affected beyond the duodenum varies. Repeating duodenal histology following several months of treatment with immunosuppressants and / or steroids might not be representative of disease improvement or stability as this is only representative of the disease in the duodenum. In fact, histological improvement following treatment with steroids and / or immunosuppressants in patients with RCD has not always been demonstrated. In a study by Brar et al, clinical improvement but not histological improvement of disease was demonstrated following treatment (Brar et al, 2007). Histological improvement in RCD patients following treatment was also absent in my study. Patients with an improvement in disease extent but the same histological grade on duodenal biopsies can be classified as partial or slow responders to treatment. It might only be a matter of time before disease grade in the duodenum improves further. Patients with the same extent of disease on the second SBCE need to be targeted more aggressively with the addition of steroids or immunosuppressants or a complete change in treatment. Also, a

diagnosis of RCD II in these patients needs to be excluded by for example deep enteroscopy for histology.

In my study, more patients with RCD had type I disease similar to 2 other studies from the US (Rubio-Tapia et al, 2009) and Germany (Daum et al, 2009). However, other studies have reported a higher frequency of RCD II than RCD I (Al-Toma et al, 2007; Malamut et al, 2009). Distinction between RCD I and II can be made histologically by analyzing the population of intraepithelial lymphocytes and by recognizing differences in CD3 and CD8 patterns (Catassi C et al, 2001). Although the distinction on SBCE between RCD I and II has to be interpreted with caution due to the small number of patients especially in the RCD II group, mucosal changes can be more extensive in RCD II than RCD I. Limited literature also exists on this aspect (Barret et al, 2012).

One limitation of this study is the small cohort of patients with RCD. This has prevented us from making certain sub-group analysis for example on different treatment given in patients with RCD. However RCD is an uncommon disorder with very limited literature in relation to SBCE. Other studies on RCD have also included a small number of patients despite some having a multicentre design and spanning a number of years (Cellier et al, 2018; Goerres et al, 2003). A longer follow up period is also required to assess the true significance of the reduction of mucosal abnormality seen on SBCE in RCD and the longer term prognosis.

Conclusions: This study has demonstrated that the extent of disease on SBCE in patients with RCD can be greater than in patients with uncomplicated CD. This can be used as further evidence of RCD in patients where a diagnosis of RCD is still uncertain. In addition, SBCE can detect an improvement in length of macroscopic disease following treatment and hence serves as a useful adjunct in the follow up of patients with RCD. This is the first study to report that a second look SBCE can play a key role in the follow up of patients with RCD receiving immunosuppressant and steroid therapy.

## 8.6 Conclusions



The extent of disease on SBCE in patients with RCD is greater compared to that of uncomplicated CD. This can be used as further evidence of RCD in patients where a diagnosis of RCD is still uncertain. In addition, SBCE can detect an improvement in length of macroscopic disease following treatment and hence serves as a useful adjunct in the follow up of patients with RCD. This is the first study to report that a second look SBCE can play a key role in the follow up of patients with RCD receiving immunosuppressant and steroid therapy.

## **Chapter 9: Summary of key findings, recommendations for future research and conclusions**

This body of work has explored the role small bowel capsule endoscopy (SBCE) in people with coeliac disease (CD). SBCE can give additional information to duodenal histology in patients with CD in view of its better magnification than a standard gastroscope and because of its wider angle of view. It can help the delineation of macroscopic features of CD and detect complications. It is also very advantageous for both clinicians and patients in view of its non-invasive nature.

Macroscopic features of CD have been studied before on small numbers of patients. The validity of these macroscopic features to delineate active CD in the SB was assessed. The overall interobserver agreement for features of CD and extent of disease between expert capsule reviewers was high, confirming the validity of these features as markers of active disease. In this study, patients with SNVA were also included, thus confirming the validity of these features in patients with similar features to patients with CD but alternative causes or patients with CD but negative serology. Unfortunately, the reporting of features of CD on SBCE is still very subjective. Expert reviewers very often comment on the extent of disease (proximal, mid, distal) and on the severity of disease (mild, moderate, severe). Through the correlation of presence of macroscopic features, extent of disease and overall severity of disease as determined by the expert reviewers, I formulated a score of severity of disease. Validation of the severity score on a different cohort of CD and SNVA patients is an area of future research. Once validated, it will provide an objective score of severity of disease and therefore enables comparison of severity to be made in the same patient and between patients.

The sensitivity of SBCE in delineating CD-related changes is reported to vary between 71-93% (El-Matary et al, 2009; Hopper et al, 2007; Lujan-Sanchis et al, 2017; Murray et al, 2008; Petroniene et al, 2005; Rokkas & Niv, 2012; Rondonotti et al, 2007). Virtual chromoendoscopy, has been studied in the delineation of ulcers and angioectasias but not in the setting of CD. Therefore, the role of Flexible Spectra Imaging Colour Enhancement (FICE) and blue light (forms of

virtual chromoendoscopy) in the delineation of CD-related changes on SBCE was assessed. FICE and blue light were not superior to conventional white light in the detection of macroscopic CD changes on SBCE. This has been shown by a low kappa agreement between expert capsule reviewers for the best modality to delineate CD changes. A lower sensitivity and specificity of FICE and blue light compared to conventional white light in the delineation of changes related to CD has also been confirmed.

The study of features of CD on SBCE in patients with newly diagnosed CD, eliminates the role of confounding factors such as duration of CD and duration of a gluten free diet (GFD). As in other studies, the lack of association between signs and symptoms at presentation and extent of disease in this cohort of patients has been confirmed. This is true except for in case of red flag signs such as weight loss and iron deficiency anaemia where patients with these signs had more extensive SB disease on SBCE. Patients with these red flag signs and those with low albumin were also significantly older at diagnosis. None of the patients studied with newly diagnosed CD had premalignant and malignant conditions on SBCE. I have therefore been unable to show a correlation between age at diagnosis, extent of CD on SBCE and the presence of premalignant or malignant conditions. This could be assessed at in future studies. However, it is known from existent literature that complications, most importantly lymphoma are more likely to occur in elderly patients especially those patients who are diagnosed with CD later on in life (Casella et al, 2012; Cooper et al, 1982). A delayed diagnosis of CD exposes patients to a longer duration of gluten in their diet and therefore can explain the higher likelihood of complications. Elderly patients and those with red flag signs at presentation should be monitored more closely and consideration should be given to carrying out a SBCE at diagnosis in view of more extensive SB disease and a potentially higher rate of complications.

Patients with established CD can present with recurrent or persistent symptoms of malabsorption that can be due to ongoing disease or due to other causes such as (Roncoroni et al, 2018; Testa et al, 2018), microscopic colitis (Vigren et al, 2013), lactose intolerance (O'Grady et al, 1984; Peña et al, 1972; PLOTKIN & ISSELBACHER, 1964) and inflammatory bowel disease (Leeds et al, 2007). There is evidence from recently published literature of the poor correlation

between symptoms and CD serology and ongoing VA on duodenal histology (Silvester et al, 2017). The patchy nature of CD (Bonamico et al, 2004; Hopper et al, 2008) can make a histological diagnosis of ongoing disease inaccurate. SBCE can give clinicians crucial information about ongoing active disease and complications in these patients. The high sensitivity (87.2%) and specificity (89.0%) of SBCE in delineating ongoing disease (Marsh 3a or higher) was confirmed. On studying a number of factors including serology, symptoms and duodenal histology, it was confirmed that patients with low albumin, vitamin B12 and folic acid which are markers of malabsorption, have more extensive disease in the SB on SBCE. It can therefore be concluded that these are the patients who are most likely to benefit from a SBCE.

In the same study, the SBT between patients with CD and controls without CD was compared. Small bowel transit (SBT) was prolonged in those with CD. Interestingly, on subgroup analysis within the group of patients with established CD, patients with normal SBCE and therefore no macroscopic evidence of active disease, had a more prolonged SBT than controls but a faster transit than those with active disease. SBT can have clinical implications in patients with CD. Medications for related neurological (Campagna et al, 2017) or autoimmune conditions (Ferrari et al, 2019) require medications. A delayed SBT can impact on absorption of medications.

Patients with villous atrophy (VA) on duodenal histology and negative CD serology and those with raised intraepithelial lymphocytes (IELs) undergo rigorous investigations to determine the cause of the changes on duodenal histology. These changes can occur secondary to CD or other conditions such as Crohn's disease, medications that patients might be on or infective pathologies. SBCE is part of the secondary investigations these patients undergo. It can be useful to detect / rule out changes of CD or Crohn's disease. In one of my studies, the use of SBCE in patients with SNVA or raised IELs was assessed. Patients with seronegative villous atrophy (SNVA) were further subdivided into those with an established cause for SNVA, those with presumed CD (SNVA-CD) that responded to a GFD and those patients with an unknown cause for their VA (SNVA-UO). SBCE was likely to be positive and changes were most extensive in patients with SNVA-CD and SNVA-UO. In patients with an

established cause for their SNVA, SBCE was still useful to rule out other pathologies such as Crohn's disease. The use of SBCE was also studied to determine if this had any impact on prognosis. Those with an unknown cause for VA and positive SBCE at diagnosis, were likely to have ongoing disease on repeat biopsies. Also, patients with SNVA-CD were more likely to develop refractory coeliac disease (RCD) if they had extensive macroscopic changes on SBCE at the time of diagnosis. More extensive SB disease on SBCE correlated with a higher SNVA-related mortality in patients with SNVA-UO and SNVA-CD. It can therefore be concluded that patients with a positive SBCE at diagnosis, need to be monitored more closely and alternative therapy considered early on in the disease course.

Some patients with CD become refractory to management with a GFD. These patients require additional treatment with immunosuppressants and have a high risk of malignant transformation and therefore require exclusion of malignant complications at diagnosis and continuous surveillance. Traditionally surveillance in these patients has been carried out by repeat duodenal histology. The use of SBCE as a means of follow up of these patients in addition to repeating a gastroduodenoscopy for histology was explored. It was confirmed that the extent of CD related changes on SBCE in patients with RCD is greater compared to that of patients with uncomplicated CD. I have also shown that the extent of affected SB mucosa on repeat SBCE in patients with RCD following treatment improves. This is the first study that demonstrates the benefit of a second look SBCE in patients with RCD showing that mucosal healing can be assessed in a non-invasive manner using SBCE. This study establishes a role for SBCE in the follow up of patients with RCD. As previously explained, SBCE can give information on extent of disease unlike duodenal histology. In patients with a poor response to immunosuppressants, treatment can be intensified further or altered, thus helping improve the prognosis of these patients. The use of SBCE for follow up and monitoring of disease extent in RCD patients in other tertiary centres is an important consideration for future research.

The studies in this thesis have been carried out at Sheffield Teaching hospitals which is a tertiary centre for the management of CD and a national centre for the management of patients with RCD. It is also a centre that performs a significant

number of SBCEs and device assisted enteroscopy per year. Although the high workload and the highly specialized care that is provided in this centre is reflected in the number of patients recruited and in the quality of these studies, it also means that the recruitment process could have been an important source of bias for example patients were more likely to be offered a SBCE as part of their routine care and RCD patients were more likely to undergo SBCE than dedicated SB imaging.

In this thesis, I have managed to add knowledge to the existent body of evidence on the role of SBCE in CD and to the most recent published guidelines on the management of patients with CD. I have also tried to overcome some of the challenges faced by expert reviewers whilst reporting on CD-related features by formulating a score of severity of disease, a crucial step required in the standardisation of features of CD. Development of a score of severity of disease, although very much required, has been challenging and limited by several factors including the development of a score based on the interobserver agreement between two expert reviewers from the same high volume centre. An external validation of the study on separate groups of patients from other centres will enable the interobserver agreement between reviewers with different experience from different centres to be compared.

This is only the start of a journey where machine-learning methods are being developed and deep neural networks are being tested to automatically detect and quantify changes in the SB in these patients (Ding et al, 2019; Zhou et al, 2017). This will make it easier for the human reviewer to delineate changes of CD as it eliminates fatigability (Beg S et al, 2018) and reading time required (Ding et al, 2019). It will also make SBCE reporting more accurate and eliminate the potential implication of low pre-reading experience in affecting the diagnostic yield of SBCE (Pezzoli et al, 2011). Once validated, the score of severity of disease can also be trialled in a study that utilises deep networks for reviewing of SBCEs. The score can also be compared to the score of human reviewers reviewing SBCEs.

Table 40 summarises the highlights in this thesis and future studies that can be considered.

Table 40: Summary of studies, important points and future studies to be considered.

Cohort of patients / study	Important points that could change clinical practice	Future Studies
Score of severity, interobserver agreement study	<ol style="list-style-type: none"> <li>1. Features of CD including mosaic pattern, fissuring of folds, nodularity, scalloping of folds, villous atrophy, ulcers are valid as features of CD in the SB.</li> <li>2. Determination of severity of disease by means of an objective score is important as it will enable us to compare disease severity more accurately in patients who require more than one SBCE.</li> </ol>	<ol style="list-style-type: none"> <li>1. Study where the validity of the score of severity of CD is determined in a separate cohort of patients. Intra-observer agreement for each reviewer can also be determined.</li> <li>2. A deep network study where the utility of a severity score can be determined.</li> </ol>
Flexible spectral imaging colour enhancement (FICE) study	<ol style="list-style-type: none"> <li>1. FICE / virtual chromoendoscopy does not help in the delineation of CD on SBCE</li> </ol>	
Newly diagnosed CD	<ol style="list-style-type: none"> <li>1. Duodenal histology remains the gold standard in diagnosing CD in patients with positive CD antibodies.</li> <li>2. SBCE is useful in elderly patients, those presenting with weight loss &amp; iron deficiency anaemia. It is known from the literature that elderly patients are more prone to malignant complications.</li> </ol>	Longitudinal study to determine the relationship between extent of disease at diagnosis & potential complications

Established CD	<ol style="list-style-type: none"> <li>1. SBCE is useful as a non-invasive investigation in patients with established CD who have signs of malabsorption eg low folate, B12, albumin.</li> <li>2. Patients with established CD have a longer SBT than patients without significant co-morbidities. Altered pharmacokinetics should be kept in mind when treating associated autoimmune conditions. SBCEs with longer battery life should be considered in patients with CD.</li> <li>3. There is no association between symptoms, CD antibodies &amp; diagnostic yield &amp; symptoms.</li> <li>4. Marsh grade of histology from the duodenal bulb correlates with diagnostic yield &amp; extent of disease in the SB on SBCE emphasizing the importance of obtaining duodenal bulb histology on repeat gastroduodenoscopies.</li> </ol>	
SNVA, raised IELs	<ol style="list-style-type: none"> <li>1. SBCE should be incorporated in the initial work up of patients with SNVA as it can give important information on disease course &amp; mortality.</li> <li>2. Patients with a worse prognosis can be targeted early with more aggressive therapy.</li> <li>3. In patients with raised IELs, SBCE can be useful in ruling out alternative pathology where the suspicion of significant pathology remains high.</li> </ol>	



<p>Refractory coeliac disease</p>	<ol style="list-style-type: none"> <li>1. Patients with RCD have more extensive disease in the SB than those with uncomplicated CD reflecting the severity of disease.</li> <li>2. Patients with the same or more extensive disease on repeat SBCE should be considered for change or escalation of therapy.</li> </ol>	<ol style="list-style-type: none"> <li>1. Multicentre studies to show the importance of SBCE in determining extent of disease in the follow up of patients with RCD.</li> <li>2. Study to determine the association between gluten immunogenic peptides &amp; features of CD on SBCE in patients with RCD.</li> </ol>
-----------------------------------	---	---

## 9.1 Outputs from this thesis:

Presentations at national and international conferences:

Bardhan meeting (March 2018) –

- Repeat capsule endoscopy in patients with coeliac disease.

British Society of Gastroenterology Annual Meeting (June 2018) –

- What is the role of capsule endoscopy in evaluating patients with refractory coeliac disease?

United European Gastroenterology week (October 2018) –

- Do clinical symptoms or serology correlate with capsule endoscopy findings in coeliac disease?
- What is the role of capsule endoscopy in evaluating patients with refractory coeliac disease?

Coeliac UK (March 2019) –

- Coeliac disease - Older patients have the most extensive small bowel involvement on capsule endoscopy.
- Capsule Endoscopy in Established Coeliac Disease: Clinical symptoms, extent of disease and small bowel transit.
- Capsule endoscopy in coeliac disease: The role of Flexible Spectral Imaging Colour Enhancement.

British Society of Gastroenterology Annual Meeting (June 2019) –

- Coeliac disease - Older patients have the most extensive small bowel involvement on capsule endoscopy.
- Capsule Endoscopy in Established Coeliac Disease: Clinical symptoms, extent of disease and small bowel transit.
- Capsule endoscopy in coeliac disease: The role of Flexible Spectral Imaging Colour Enhancement.

United European Gastroenterology week (October 2019) –

- Capsule Endoscopy in Established Coeliac Disease: Clinical symptoms, extent of disease and small bowel transit.
- Coeliac disease - Older patients have the most extensive small bowel involvement on capsule endoscopy.
- Is there a correlation between duodenal histology and disease severity on capsule endoscopy in patients with villous atrophy? (**recognized as poster of excellence**)
- Use of capsule endoscopy in seronegative villous atrophy: Does it clarify or cloud the picture?

## Chapter 10 Supplementary material

10.1 Permission to reuse figure 1 (Introduction)

### BMJ PUBLISHING GROUP LTD. LICENSE TERMS AND CONDITIONS

Feb 15, 2020

---

---

This Agreement between Stefania Chetcuti Zammit ("You") and BMJ Publishing Group Ltd. ("BMJ Publishing Group Ltd.") consists of your license details and the terms and conditions provided by BMJ Publishing Group Ltd. and Copyright Clearance Center.

License Number	4770400264074
License date	Feb 15, 2020
Licensed Content Publisher	BMJ Publishing Group Ltd.
Licensed Content Publication	Gut
Licensed Content Title	Recent advances in coeliac disease
Licensed Content Author	D A van Heel, J West
Licensed Content Date	Jul 1, 2006
Licensed Content Volume	55
Licensed Content Issue	7
Type of Use	Dissertation/Thesis
Requestor type	Individual
Format	Print and electronic
Portion	Figure/table/extract

Number of figure/table/extracts	1
Description of figure/table/extracts	Figure 3
Will you be translating?	No
Circulation/distribution	6
Title	The use of small bowel capsule endoscopy in patients with coeliac disease and serology negative villous atrophy
Institution name	Sheffield Teaching Hospitals
Expected presentation date	Jun 2020
Portions	Figure 3
	Stefania Chetcuti Zammit Royal Hallamshire Hospital
Requestor Location	Mosta, Malta S10 2JF United Kingdom Attn: Stefania Chetcuti Zammit
Publisher Tax ID	GB674738491
Total	0.00 GBP

#### Terms and Conditions

##### **BMJ Group Terms and Conditions for Permissions**

When you submit your order you are subject to the terms and conditions set out below. You will also have agreed to the Copyright Clearance Center's ("CCC") terms and conditions regarding billing and payment <https://s100.copyright.com/App/PaymentTermsAndConditions.jsp>.

CCC are acting as the BMJ Publishing Group Limited's ("BMJ Group's") agent.

Subject to the terms set out herein, the BMJ Group hereby grants to you (the Licensee) a non-exclusive, non-transferable licence to re-use material as detailed in your request for this/those purpose(s) only and in accordance with the following conditions:

1) **Scope of Licence:** Use of the Licensed Material(s) is restricted to the ways specified by you during the order process and any additional use(s) outside of those specified in that request, require a further grant of permission.

2) **Acknowledgement:** In all cases, due acknowledgement to the original publication with permission from the BMJ Group should be stated adjacent to the reproduced Licensed Material. The format of such acknowledgement should read as follows:

"Reproduced from [publication title, author(s), volume number, page numbers, copyright notice year] with permission from BMJ Publishing Group Ltd."

3) **Third Party Material:** BMJ Group acknowledges to the best of its knowledge, it has the rights to licence your reuse of the Licensed Material, subject always to the caveat that images/diagrams, tables and other illustrative material included within, which have a separate copyright notice, are presumed as excluded from the licence. Therefore, you should ensure that the Licensed Material you are requesting is original to BMJ Group and does not carry the copyright of another entity (as credited in the published version). If the credit line on any part of the material you have requested in any way indicates that it was reprinted or adapted by BMJ Group with permission from another source, then you should seek permission from that source directly to re-use the Licensed Material, as this is outside of the licence granted herein.

4) **Altering/Modifying Material:** The text of any material for which a licence is granted may not be altered in any way without the prior express permission of the BMJ Group. Subject to Clause 3 above however, single figure adaptations do not require BMJ Group's approval; however, the adaptation should be credited as follows:

"Adapted by permission from BMJ Publishing Group Limited. [publication title, author, volume number, page numbers, copyright notice year]"

5) **Reservation of Rights:** The BMJ Group reserves all rights not specifically granted in the combination of (i) the licence details provided by you and

accepted in the course of this licensing transaction, (ii) these terms and conditions and (iii) CCC's Billing and Payment Terms and Conditions.

6) **Timing of Use:** First use of the Licensed Material must take place within 12 months of the grant of permission.

7). **Creation of Contract and Termination:** Once you have submitted an order via Rights link and this is received by CCC, and subject to you completing accurate details of your proposed use, this is when a binding contract is in effect and our acceptance occurs. As you are ordering rights from a periodical, to the fullest extent permitted by law, you will have no right to cancel the contract from this point other than for BMJ Group's material breach or fraudulent misrepresentation or as otherwise permitted under a statutory right. Payment must be made in accordance with CCC's Billing and Payment Terms and conditions. In the event that you breach any material condition of these terms and condition or any of CCC's Billing and Payment Terms and Conditions, the license is automatically terminated upon written notice from the BMJ Group or CCC or as otherwise provided for in CCC's Billing and Payment Terms and Conditions, where these apply.. Continued use of materials where a licence has been terminated, as well as any use of the Licensed Materials beyond the scope of an unrevoked licence, may constitute intellectual property rights infringement and BMJ Group reserves the right to take any and all action to protect its intellectual property rights in the Licensed Materials.

8. **Warranties:** BMJ Group makes no express or implied representations or warranties with respect to the Licensed Material and to the fullest extent permitted by law this is provided on an "as is" basis. For the avoidance of doubt BMJ Group does not warrant that the Licensed Material is accurate or fit for any particular purpose.

9. **Limitation of Liability:** To the fullest extent permitted by law, the BMJ Group disclaims all liability for any indirect, consequential or incidental damages (including without limitation, damages for loss of profits, information or interruption) arising out of the use or inability to use the Licensed Material or the inability to obtain additional rights to use the Licensed Material. To the fullest extent permitted by law, the maximum aggregate liability of the BMJ Group for any claims, costs, proceedings and demands for direct losses caused by BMJ Group's breaches of its obligations herein shall be limited to twice the amount paid by you to CCC for the licence granted herein.

**10. Indemnity:** You hereby indemnify and hold harmless the BMJ Group and their respective officers, directors, employees and agents, from and against any and all claims, costs, proceeding or demands arising out of your unauthorised use of the Licensed Material.

**11. No Transfer of License:** This licence is personal to you, and may not be assigned or transferred by you without prior written consent from the BMJ Group or its authorised agent(s). BMJ Group may assign or transfer any of its rights and obligations under this Agreement, upon written notice to you.

**12. No Amendment Except in Writing:** This licence may not be amended except in a writing signed by both parties (or, in the case of BMJ Group, by CCC on the BMJ Group's behalf).

**13. Objection to Contrary terms:** BMJ Group hereby objects to any terms contained in any purchase order, acknowledgment, check endorsement or other writing prepared by you, which terms are inconsistent with these terms and conditions or CCC's Billing and Payment Terms and Conditions. These terms and conditions, together with CCC's Billing and Payment Terms and Conditions (which to the extent they are consistent are incorporated herein), comprise the entire agreement between you and BMJ Group (and CCC) and the Licensee concerning this licensing transaction. In the event of any conflict between your obligations established by these terms and conditions and those established by CCC's Billing and Payment Terms and Conditions, these terms and conditions shall control.

**14. Revocation:** BMJ Group or CCC may, within 30 days of issuance of this licence, deny the permissions described in this licence at their sole discretion, for any reason or no reason, with a full refund payable to you should you have not been able to exercise your rights in full. Notice of such denial will be made using the contact information provided by you. Failure to receive such notice from BMJ Group or CCC will not, to the fullest extent permitted by law alter or invalidate the denial. For the fullest extent permitted by law in no event will BMJ Group or CCC be responsible or liable for any costs, expenses or damage incurred by you as a result of a denial of your permission request, other than a refund of the amount(s) paid by you to BMJ Group and/or CCC for denied permissions.



**15. Restrictions to the license:**

**15.1 Promotion:** BMJ Group will not give permission to reproduce in full or in part any Licensed Material for use in the promotion of the following:

a) non-medical products that are harmful or potentially harmful to health: alcohol, baby milks and/or, sunbeds

b) medical products that do not have a product license granted by the Medicines and Healthcare products Regulatory Agency (MHRA) or its international equivalents. Marketing of the product may start only after data sheets have been released to members of the medical profession and must conform to the marketing authorization contained in the product license.

**16. Translation:** This permission is granted for non-exclusive world English language rights only unless explicitly stated in your licence. If translation rights are granted, a professional translator should be employed and the content should be reproduced word for word preserving the integrity of the content.

**17. General:** Neither party shall be liable for failure, default or delay in performing its obligations under this Licence, caused by a Force Majeure event which shall include any act of God, war, or threatened war, act or threatened act of terrorism, riot, strike, lockout, individual action, fire, flood, drought, tempest or other event beyond the reasonable control of either party.

17.1 In the event that any provision of this Agreement is held to be invalid, the remainder of the provisions shall continue in full force and effect.

17.2 There shall be no right whatsoever for any third party to enforce the terms and conditions of this Agreement. The Parties hereby expressly wish to exclude the operation of the Contracts (Rights of Third Parties) Act 1999 and any other legislation which has this effect and is binding on this agreement.

17.3 To the fullest extent permitted by law, this Licence will be governed by the laws of England and shall be governed and construed in accordance with the laws of England. Any action arising out of or relating to this agreement shall be brought in courts situated in England save where it is necessary for BMJ Group for enforcement to bring proceedings to bring an action in an alternative jurisdiction.

**Questions? [customer care@copyright.com](mailto:customer care@copyright.com) or +1-855-239-3415 (toll free in the US) or +1-978-646-2777.**

\_\_\_\_\_  
\_\_\_\_\_


## 10.2 Permission to reuse articles from co-authors

To whom it may concern,

I was a co-author with Dr Stefania Chetcuti Zammit of the publication '**Chetcuti Zammit S, Sanders D S, Sidhu R. A comprehensive review on the utility of capsule endoscopy in coeliac disease: From computational analysis to the bedside. Comput Biol Med. 2018; 1;102:300-314.**' I confirm permission for the article to be reproduced in his thesis and that Dr Stefania Chetcuti Zammit was the primary contributor in writing this paper.

Yours faithfully,

Name: 

Signature: 

Date: 2/1/2020

To whom it may concern,

I was a co-author with Dr Stefania Chetcuti Zammit of the publication '**Chetcuti Zammit S, Sanders D S, Sidhu R. A comprehensive review on the utility of capsule endoscopy in coeliac disease: From computational analysis to the bedside. Comput Biol Med. 2018; 1;102:300-314.**' I confirm permission for the article to be reproduced in his thesis and that Dr Stefania Chetcuti Zammit was the primary contributor in writing this paper.

Yours faithfully,

Name: *PROF DAVID SAMOEFAS*

Signature:



Date:

*2/1/20*

To whom it may concern,

I was a co-author with Dr Stefania Chetcuti Zammit of the publication '**Chetcuti Zammit S, Sanders D S, Sidhu R. Capsule Endoscopy for patients with coeliac disease. Exp Rev Gastroenterol Hepatol. 2018;12(8):779-790.**' I confirm permission for the article to be reproduced in his thesis and that Dr Stefania Chetcuti Zammit was the primary contributor in writing this paper.

Yours faithfully,

Name: *Ramon*

Signature:



Date:

*2/1/2020*

To whom it may concern,

I was a co-author with Dr Stefania Chetcuti Zammit of the publication '**Chetcuti Zammit S, Sanders D S, Sidhu R. Capsule Endoscopy for patients with coeliac disease. Exp Rev Gastroenterol Hepatol. 2018;12(8):779-790.**' I confirm permission for the article to be reproduced in his thesis and that Dr Stefania Chetcuti Zammit was the primary contributor in writing this paper.

Yours faithfully,

Name: PROF DAVID SANDOZ

Signature:



Date:

2/1/20

To whom it may concern,

I was a co-author with Dr Stefania Chetcuti Zammit of the publication '**Chetcuti Zammit S, Sanders D S, Sidhu R. Refractory coeliac disease - What should we be doing different? Curr Opin Gastroenterol.**'

I confirm permission for the article to be reproduced in his thesis and that Dr Stefania Chetcuti Zammit was the primary contributor in writing this paper.

Yours faithfully,

Name:



Signature:



Date:

2/1/2020

To whom it may concern,

I was a co-author with Dr Stefania Chetcuti Zammit of the publication 'Chetcuti Zammit S, Sanders D S, Sidhu R. Refractory coeliac disease - What should we be doing different? Curr Opin Gastroenterol.'

I confirm permission for the article to be reproduced in his thesis and that Dr Stefania Chetcuti Zammit was the primary contributor in writing this paper.

Yours faithfully,

Name:

PROF DAVID SANDERS

Signature:



Date:

2/1/20

To whom it may concern,

I was a co-author with Dr Stefania Chetcuti Zammit of the publication '**Chetcuti Zammit S, Sanders D S, Sidhu R. Coeliac disease: older patients have the most extensive small bowel involvement on capsule endoscopy. Eur J Gastroenterol Hepatol. 2019 Dec;31(12):1496-1501.**'

I confirm permission for the article to be reproduced in his thesis and that Dr Stefania Chetcuti Zammit was the primary contributor in writing this paper.

Yours faithfully,

Name: *Rendon*

Signature: *Rendon*

Date: *2/1/20*



To whom it may concern,

I was a co-author with Dr Stefania Chetcuti Zammit of the publication '**Chetcuti Zammit S, Sanders D S, Sidhu R. Coeliac disease: older patients have the most extensive small bowel involvement on capsule endoscopy. Eur J Gastroenterol Hepatol. 2019 Dec;31(12):1496-1501.**'

I confirm permission for the article to be reproduced in his thesis and that Dr Stefania Chetcuti Zammit was the primary contributor in writing this paper.

Yours faithfully,

Name: *Prof David Jandem*

Signature: 

Date: *2/1/20*

To whom it may concern,

I was a co-author with Dr Stefania Chetcuti Zammit of the publication '**Chetcuti Zammit S, Kurien M, Sanders D S, Sidhu R. What is the role of small bowel capsule endoscopy in established coeliac disease?. Clin Res Hepatol Gastroenterol. 2019.**'

I confirm permission for the article to be reproduced in his thesis and that Dr Stefania Chetcuti Zammit was the primary contributor in writing this paper.

Yours faithfully,

Name: 

Signature: 

Date: 2/1/2020

To whom it may concern,

I was a co-author with Dr Stefania Chetcuti Zammit of the publication '**Chetcuti Zammit S, Kurien M, Sanders D S, Sidhu R. What is the role of small bowel capsule endoscopy in established coeliac disease?. Clin Res Hepatol Gastroenterol. 2019.**'

I confirm permission for the article to be reproduced in his thesis and that Dr Stefania Chetcuti Zammit was the primary contributor in writing this paper.

Yours faithfully,

Name: 

Signature: 

Date: 2/1/20

To whom it may concern,

I was a co-author with Dr Stefania Chetcuti Zammit of the publication '**Chetcuti Zammit S, Kurien M, Sanders D S, Sidhu R. What is the role of small bowel capsule endoscopy in established coeliac disease?. Clin Res Hepatol Gastroenterol. 2019.**'

I confirm permission for the article to be reproduced in his thesis and that Dr Stefania Chetcuti Zammit was the primary contributor in writing this paper.

Yours faithfully,

Name: Dr Matthew Kurien

Signature:



Date: 05/01/20

To whom it may concern,

I was a co-author with Dr Stefania Chetcuti Zammit of the publication **'Chetcuti Zammit S, Schiepatti A, Aziz I, Kurien M, Sanders D S, Sidhu R. The use of small bowel capsule endoscopy in cases of equivocal celiac disease: Does it clarify or cloud the picture? Gastrointestinal Endoscopy. 2019.**

I confirm permission for the article to be reproduced in her thesis and that Dr Stefania Chetcuti Zammit was the primary contributor in writing this paper.

Yours faithfully,

Name: ANNALISA SCHIEPATTI

Signature: 

Date: PAVIA, 05/01/2020

To whom it may concern,


I was a co-author with Dr Stefania Chetcuti Zammit of the publication '**Chetcuti Zammit S, Schiepatti A, Aziz I, Kurien M, Sanders D S, Sidhu R. The use of small bowel capsule endoscopy in cases of equivocal celiac disease: Does it clarify or cloud the picture? Gastrointestinal Endoscopy. 2019.**

I confirm permission for the article to be reproduced in her thesis and that Dr Stefania Chetcuti Zammit was the primary contributor in writing this paper.

Yours faithfully,

Name: Imran Aziz

Signature:

A rectangular box containing a handwritten signature in black ink. The signature reads "Imran Aziz" on the top line and "I. Aziz" on the bottom line.

Date: 2/1/20

To whom it may concern,

I was a co-author with Dr Stefania Chetcuti Zammit of the publication **'Chetcuti Zammit S, Schiepatti A, Aziz I, Kurien M, Sanders D S, Sidhu R. The use of small bowel capsule endoscopy in cases of equivocal celiac disease: Does it clarify or cloud the picture? Gastrointestinal Endoscopy. 2019.**

I confirm permission for the article to be reproduced in her thesis and that Dr Stefania Chetcuti Zammit was the primary contributor in writing this paper.

Yours faithfully,

Name: Dr Matthew Kurien

Signature: 

Date: 05/01/20

To whom it may concern,

I was a co-author with Dr Stefania Chetcuti Zammit of the publication '**Chetcuti Zammit S, Schiepatti A, Aziz I, Kurien M, Sanders D S, Sidhu R. The use of small bowel capsule endoscopy in cases of equivocal celiac disease: Does it clarify or cloud the picture? Gastrointestinal Endoscopy. 2019.**

I confirm permission for the article to be reproduced in her thesis and that Dr Stefania Chetcuti Zammit was the primary contributor in writing this paper.

Yours faithfully,

Name: *PROF DAVID SAMIEM*

Signature:



Date:

*2/1/20*

To whom it may concern,

I was a co-author with Dr Stefania Chetcuti Zammit of the publication '**Chetcuti Zammit S, Schiepatti A, Aziz I, Kurien M, Sanders D S, Sidhu R. The use of small bowel capsule endoscopy in cases of equivocal celiac disease: Does it clarify or cloud the picture? Gastrointestinal Endoscopy. 2019.**

I confirm permission for the article to be reproduced in her thesis and that Dr Stefania Chetcuti Zammit was the primary contributor in writing this paper.

Yours faithfully,

Name:



Signature:



Date:





To whom it may concern,

I was a co-author with Dr Stefania Chetcuti Zammit of the publication '**Stefania Chetcuti Zammit, David S Sanders, Simon S Cross, Reena Sidhu. Capsule endoscopy in the management of refractory coeliac disease (Journal of Gastrointestinal and Liver Diseases, 2019)**'. I confirm permission for the article to be reproduced in his thesis and that Dr Stefania Chetcuti Zammit was the primary contributor in writing this paper.

Yours faithfully,

Name: *PROF. DAVID SANDERS*

Signature:



Date:

*2/2/20*

To whom it may concern,

I was a co-author with Dr Stefania Chetcuti Zammit of the publication '**Stefania Chetcuti Zammit, David S Sanders, Simon S Cross, Reena Sidhu. Capsule endoscopy in the management of refractory coeliac disease (Journal of Gastrointestinal and Liver Diseases, 2019)**'. I confirm permission for the article to be reproduced in his thesis and that Dr Stefania Chetcuti Zammit was the primary contributor in writing this paper.

Yours faithfully,

Name: Prof. Simon Cross

Signature: 


Date: 10<sup>th</sup> February 2020

To whom it may concern,

I was a co-author with Dr Stefania Chetcuti Zammit of the publication '**Stefania Chetcuti Zammit, David S Sanders, Simon S Cross, Reena Sidhu. Capsule endoscopy in the management of refractory coeliac disease (Journal of Gastrointestinal and Liver Diseases, 2019)**'. I confirm permission for the article to be reproduced in his thesis and that Dr Stefania Chetcuti Zammit was the primary contributor in writing this paper.

Yours faithfully,

Name: 

Signature: 

Date: 

To whom it may concern,

I was a co-author with Dr Stefania Chetcuti Zammit of the publication '**Chetcuti Zammit S, McAlindon ME, Ellul P, Rondonotti E, Carretero C, Sanders DS, Sidhu R. Improving diagnostic yield of capsule endoscopy in coeliac disease. – Can Flexible Spectral Imaging Colour Enhancement play a role? Digestion. 2019 Aug 13:1-8. doi: 10.1159/000500906. [Epub ahead of print]**'. I confirm permission for the article to be reproduced in her thesis and that Dr Stefania Chetcuti Zammit was the primary contributor in writing this paper.

Yours faithfully,

Name:

OSPEDALE VALDUCE - COMO  
U.O. GASTROENTEROLOGIA  
*Dr. Rondonotti Emanuele*  
C.F. RND MNL 74P27 A794T  
Tel. 031-324145

Signature:



Date:

6.02.2020

To whom it may concern,

I was a co-author with Dr Stefania Chetcuti Zammit of the publication '**Chetcuti Zammit S, McAlindon ME, Ellul P, Rondonotti E, Carretero C, Sanders DS, Sidhu R. Improving diagnostic yield of capsule endoscopy in coeliac disease. – Can Flexible Spectral Imaging Colour Enhancement play a role? Digestion. 2019 Aug 13:1-8. doi: 10.1159/000500906. [Epub ahead of print]**'. I confirm permission for the article to be reproduced in her thesis and that Dr Stefania Chetcuti Zammit was the primary contributor in writing this paper.

Yours faithfully,

Name: M McALINDON

Signature: M McAlindon

Date: 2/1/20

To whom it may concern,

I was a co-author with Dr Stefania Chetcuti Zammit of the publication '**Improving diagnostic yield of capsule endoscopy in coeliac disease. – Can Flexible Spectral Imaging Colour Enhancement play a role?**' I confirm permission for the article to be reproduced in her thesis and that Dr Stefania Chetcuti Zammit was the primary contributor in writing this paper.

Yours faithfully,

Name:

Signature:



Date:

4/1/19

Dr Pierre Ellul  
FRCP MSc  
Gastroenterologist  
R.N.O. 2840  
St. Paul's Hospital


To whom it may concern,

I was a co-author with Dr Stefania Chetcuti Zammit of the publication '**Chetcuti Zammit S, McAlindon ME, Ellul P, Rondonotti E, Carretero C, Sanders DS, Sidhu R. Improving diagnostic yield of capsule endoscopy in coeliac disease. – Can Flexible Spectral Imaging Colour Enhancement play a role? Digestion. 2019 Aug 13:1-8. doi: 10.1159/000500906. [Epub ahead of print]**'. I confirm permission for the article to be reproduced in her thesis and that Dr Stefania Chetcuti Zammit was the primary contributor in writing this paper.

Yours faithfully,

Name: Cristina Carretero

Signature:



Date:

20/02/2020

To whom it may concern,

I was a co-author with Dr Stefania Chetcuti Zammit of the publication '**Chetcuti Zammit S, Kurien M, Sanders D S, Sidhu R. What is the role of small bowel capsule endoscopy in established coeliac disease?. Clin Res Hepatol Gastroenterol. 2019.**'

I confirm permission for the article to be reproduced in his thesis and that Dr Stefania Chetcuti Zammit was the primary contributor in writing this paper.

Yours faithfully,

Name:

PROF DR. D SANDERS

Signature:



Date:

2/1/20

To whom it may concern,

I was a co-author with Dr Stefania Chetcuti Zammit of the publication '**Chetcuti Zammit S, McAlindon ME, Ellul P, Rondonotti E, Carretero C, Sanders DS, Sidhu R. Improving diagnostic yield of capsule endoscopy in coeliac disease. – Can Flexible Spectral Imaging Colour Enhancement play a role? Digestion. 2019 Aug 13:1-8. doi: 10.1159/000500906. [Epub ahead of print]**'. I confirm permission for the article to be reproduced in her thesis and that Dr Stefania Chetcuti Zammit was the primary contributor in writing this paper.

Yours faithfully,

Name:



Signature:



Date:

2/1/2022



## 10.3 Permission to reuse published articles from journals

On Thursday, January 2, 2020, 04:34:15 AM PST, authorqueries@tandf.co.uk <authorqueries@tandf.co.uk> wrote:



Dear Stefania,

Thank you for your email and I hope you are well.

As an author of the original article you have the right to include the Accepted Manuscript in a thesis or dissertation that is not to be published commercially, provided that publication is acknowledged using the following text:

This is an Accepted Manuscript of an article published by Taylor & Francis in *Journal of XXX* on DATE, available online: <http://www.tandfonline.com/DOI>

Please see this guide for further information:  
<http://authorservices.taylorandfrancis.com/sharing-your-work/>

Best wishes,

Jacob Lombos  
On behalf of the Taylor & Francis Journals Helpdesk

Subject: Submission Query  
Sent by: stf\_che@yahoo.com  
Sent on: 02/01/2020

Customer Type: Author  
Institution Name: Sheffield Teaching Hospital  
Full Name: Stefania Chetcuti Zammit  
Journal Title:  
ISSN:  
Additional Comments: Dear editorial team,

I would like to seek permission to reuse the article entitled " Capsule Endoscopy for patients with coeliac disease" that has been accepted for publication in Expert Review Gastroenterology and Hepatology as a chapter in my thesis (MD, University of Sheffield).

I look forward to your reply.

**From:** Rommel Jallorina

**Date:** 27/11/2018 03.33 PM

I am currently doing an MD with the university of Sheffield. I would like to seek permission to reuse my article published in computers in biology and medicine in my thesis. My article is entitled: A comprehensive review on the utility of capsule endoscopy in coeliac disease: From computational analysis to the bedside.

This communication is confidential and may be privileged. Any unauthorised use or dissemination of this message in whole or in part is strictly prohibited and may be unlawful. If you receive this message by mistake, please notify the sender by return email and delete this message from your system. Elsevier B.V. (including its group companies) shall not be liable for any improper or incomplete transmission of the information contained in this communication or delay in its receipt. Any price quotes contained in this communication are merely indicative and may not be relied upon by the individual or entity receiving it. Any proposed transactions or quotes contained in this communication will not result in any legally binding or enforceable obligation or give rise to any obligation for reimbursement of any fees, expenses, costs or damages, unless an express agreement to that effect has been agreed upon, delivered and executed by the parties.

©2018, Elsevier BV. All rights reserved.

[---001:002281:39420---]

- 
- **Permissions Helpdesk** <permissionshelpdesk@elsevier.com>

---

**To:**stf\_che@yahoo.com

Nov 28 at 10:01 AM

Dear Dr. Zammit,

As an Elsevier journal author, you retain the right to Include the article in a thesis or dissertation (provided that this is not to be published commercially) whether in full or in part, subject to proper acknowledgment; see <https://www.elsevier.com/about/our-business/policies/copyright/personal-use> for more information. As this is a retained right, no written permission from Elsevier is necessary.

If I may be of further assistance, please let me know.

Best of luck with your thesis and best regards,

Laura

**Laura Stingelin**

Permissions Helpdesk Associate

**ELSEVIER** | Global E-Operations Books

+1 215-239-3867 office

[l.stingelin@elsevier.com](mailto:l.stingelin@elsevier.com)

Contact the Permissions Helpdesk

+1 800-523-4069 x3808 | [permissionshelpdesk@elsevier.com](mailto:permissionshelpdesk@elsevier.com)

The screenshot shows a web browser window with the URL [s100.copyright.com/AppDispatchServlet](https://s100.copyright.com/AppDispatchServlet). The page header includes the Copyright Clearance Center logo and the RightsLink logo. Navigation links for Home, Help, Email Support, Sign in, and Create Account are visible. The main content area displays a copyright notice for the article "Refractory coeliac disease: what should we be doing different?" by Stefania Chetcuti Zammit, David Sanders, and Reena Sidhu, published in Current Opinion in Gastroenterology by Wolters Kluwer Health, Inc. on Feb 18, 2020. A "License Not Required" section states that the final peer-reviewed manuscript can be reused in a thesis. At the bottom, there are "BACK" and "CLOSE WINDOW" buttons, and a footer with copyright information and contact details for the Copyright Clearance Center.



**Coeliac disease: older patients have the most extensive small bowel involvement on capsule endoscopy**

**Author:** Stefania Chetcuti Zammit, David Sanders, and Reena Sidhu

**Publication:** European Journal of Gastroenterology and Hepatology

**Publisher:** Wolters Kluwer Health, Inc.

**Date:** Dec 1, 2019

*Copyright © 2019, Copyright © 2019 Wolters Kluwer Health, Inc. All rights reserved.*

**License Not Required**

Wolters Kluwer policy permits only the final peer-reviewed manuscript of the article to be reused in a thesis. You are free to use the final peer-reviewed manuscript in your print thesis at this time, and in your electronic thesis 12 months after the article's publication date. The manuscript may only appear in your electronic thesis if it will be password protected. Please see our Author Guidelines here: <https://cdn-tp2.mozu.com/16833-m1/cms/files/Author-Documents.pdf?mzts=636410951730000000>.

BACK

CLOSE WINDOW

Re: permissions to reuse article

---

From: JGLD (editorjgld@gmail.com)

To: stf\_che@yahoo.com

Date: Saturday, January 11, 2020, 07:02 PM GMT

---

Dear Stefania Chetcuti Zammit

We agree that you use the paper published in our journal in your thesis

Best regards

Lidia Ciobanu

Assoc. Editor JGLD

On Thu, Jan 2, 2020 at 10:22 AM stef chet <[stf\\_che@yahoo.com](mailto:stf_che@yahoo.com)> wrote:

Dear editorial team,

I would like to seek permission to reuse the article entitled " Capsule endoscopy in the management of refractory coeliac disease." that has been published in the Journal of Gastrointestinal and Liver Diseases as a chapter in my thesis (MD, University of Sheffield).

I look forward to your reply.

Kind Regards

Stefania Chetcuti Zammit

**RE: Permission to reuse article in thesis**

---

From: GIE (gie@asge.org)

To: stf\_che@yahoo.com

Date: Thursday, January 2, 2020, 03:55 PM GMT

---

Dear Dr. Chet,

Authors can use their papers in theses or dissertations without permission. For more information regarding Elsevier permissions policies, please see the link below. Please let me know if you have further questions.

<https://www.elsevier.com/about/policies/copyright/permissions>

Kind Regards,

Stephanie Kinnan

Assistant Managing Editor of Clinical Publications

American Society for Gastrointestinal Endoscopy

Phone: 630-570-5640

---

**From:** stef chet <stf\_che@yahoo.com>  
**Sent:** Thursday, January 2, 2020 2:50 AM  
**To:** GIE <gie@asge.org>  
**Subject:** Permission to reuse article in thesis

Dear editorial team,

I would like to seek permission to reuse the article entitled "The use of small bowel capsule endoscopy in cases of equivocal celiac disease: Does it clarify or cloud the picture?" that has been accepted for publication in GIE as a chapter in my thesis (MD, University of Sheffield).

I look forward to your reply.

Kind Regards

## Permission

---

From: Rights and Permissions (permission@karger.com)

To: stf\_che@yahoo.com

Date: Thursday, January 2, 2020, 01:47 PM GMT

---

Dear Dr. Chetcuti Zammit,

Thank you for your email. As to your request, I am pleased to inform you that permission is granted hereby to reprint your article

**Chetcuti Zammit S, McAlindon M, E, Ellul P, Rondonotti E, Carretero C, Sanders D, S, Sidhu R: Improving Diagnostic Yield of Capsule Endoscopy in Coeliac Disease: Can Flexible Spectral Imaging Colour Enhancement Play a Role? Digestion 2019. doi: 10.1159/000500906**

as a chapter in the printed and electronic version of your **thesis/doctoral dissertation**, provided that proper credit will be given to the original source and that S. Karger AG, Basel will be mentioned.

Please note that this is a non-exclusive permission, hence any further use, edition, translation or distribution, either in print or electronically, requires written permission again as this permission is valid for the above mentioned purpose only.

This permission applies only to copyrighted content that S. Karger AG owns, and not to copyrighted content from other sources. If any material in our work appears with credit to another source, you must also obtain permission from the original source cited in our work. All content reproduced from copyrighted material owned by S. Karger AG remains the sole and exclusive property of S. Karger AG. The right to grant permission to a third party is reserved solely by S. Karger AG.

Thank you for your understanding and cooperation.

Hopefully, I have been of assistance to you with the above.

Kind regards,

Erika Brunner

ePartner Manager  
Rights & Permissions Manager

+41 61 306 12 48

[e.brunner@karger.com](mailto:e.brunner@karger.com)

---

## 10.4 Coeliac disease proforma

Patient details:

Reviewer:

Areas of small bowel involved:

Findings in proximal (0 – 33%) / Mid (34 – 66%) / Distal (67 – 100%)

	Proximal		Mid		Distal	
	continuos	patchy	continuouss	patchy	continuos	patchy
Mosaic pattern						
Fissuring of mucosa						
Scalloping of mucosa						
Villous atrophy						
Nodularity of mucosa						
Ulcers present						
Hypotrophic (intermediate)						

Overall descriptive severity: Mild / moderate / severe

Time with abnormality\_\_\_\_\_

Time without villi\_\_\_\_\_

Total small bowel transit\_\_\_\_\_

% length of abnormal small bowel\_\_\_\_\_



% Time without villi\_\_\_\_\_

Metoclopramide yes / no

## 10.5 Flexible spectral imaging colour enhancement study proforma

07/11/2018

The use of flexible spectral imaging colour enhancement and blue light in coeliac disease.

### **The use of flexible spectral imaging colour enhancement and blue light in coeliac disease.**

The following questions concern different flexible spectral imaging colour enhancement (FICE) settings and blue light to improve the detection of features of coeliac disease on small bowel capsule endoscopy. There is only 1 correct answer for questions in sections 1 to 5.

#### **Moderate features of coeliac disease:**

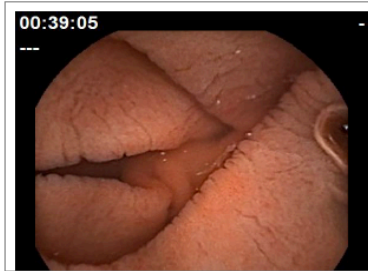
[https://docs.google.com/forms/d/1w1KX-nqYv6iUejWv-Vt3Mww6mleBiSahDxt\\_3jA5IFOU/edit](https://docs.google.com/forms/d/1w1KX-nqYv6iUejWv-Vt3Mww6mleBiSahDxt_3jA5IFOU/edit)

1/22

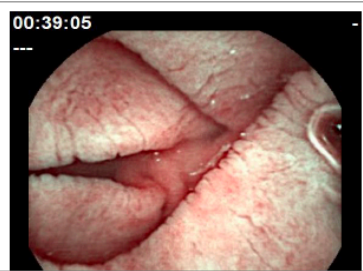
07/11/2018

The use of flexible spectral imaging colour enhancement and blue light in coeliac disease.

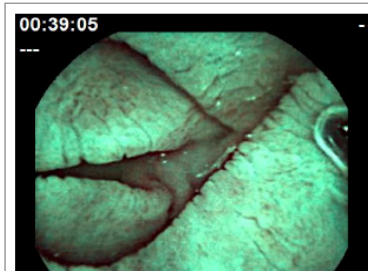
1. 1. Which capsule endoscopy image shows fissuring of mucosa best?  
Mark only one oval.



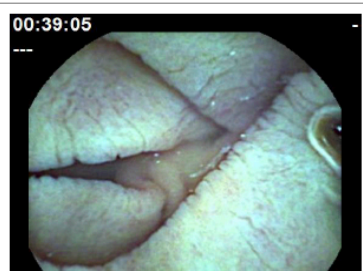
Option 1



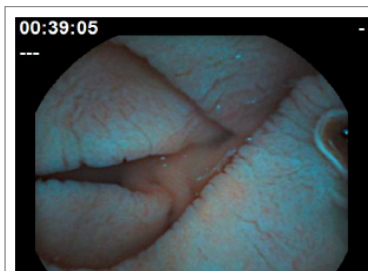
Option 2



Option 3

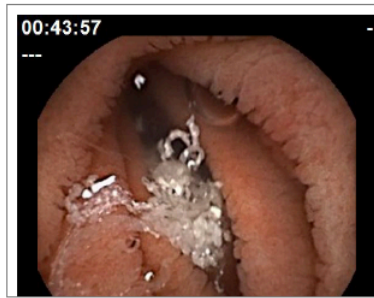

Option 4

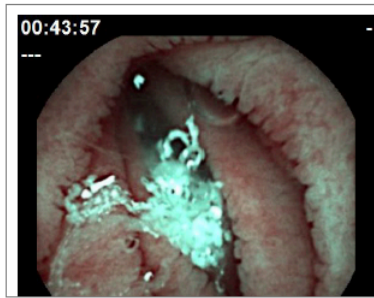

Option 5

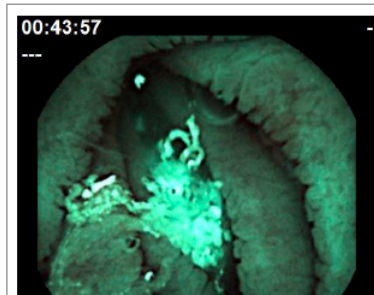
2. Which capsule endoscopy image shows scalloping of mucosa best?  
Mark only one oval.



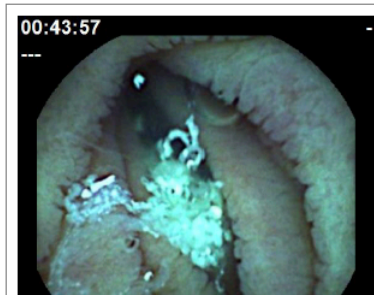Option 1



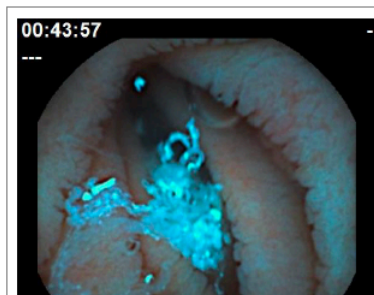
Option 2



Option 3

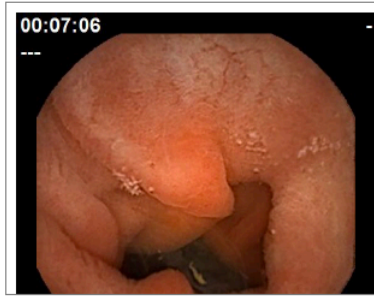


Option 4

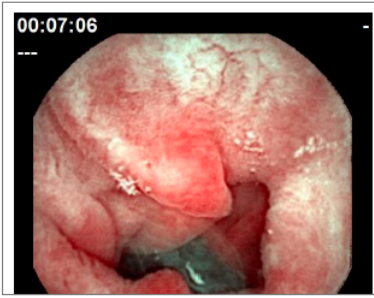


Option 5

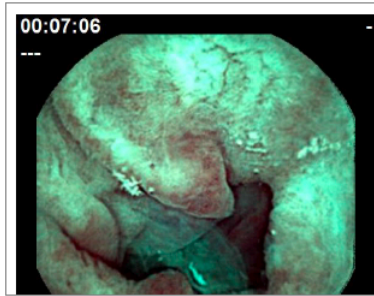3. 3. Which capsule endoscopy image shows villous atrophy best?  
Mark only one oval.



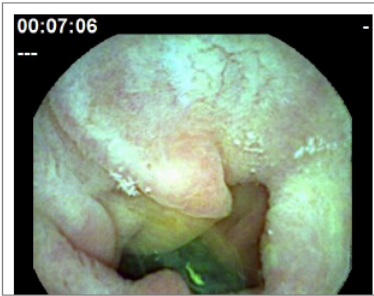
Option 1



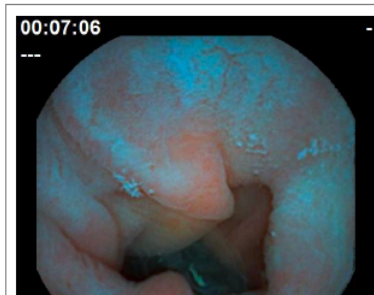Option 2



Option 3

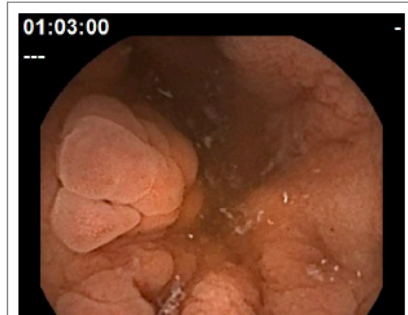

Option 4

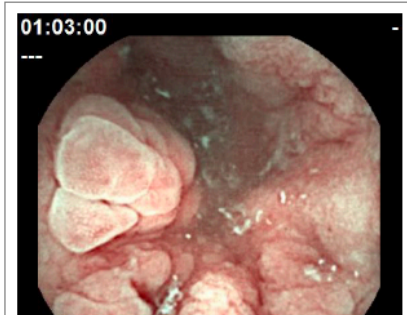

Option 5

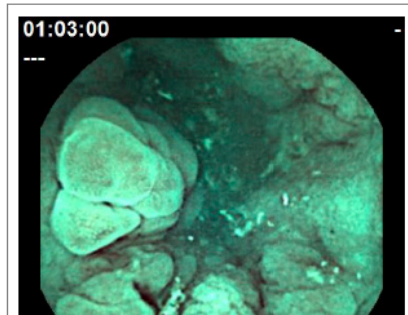
4. 4. Which capsule endoscopy image shows nodularity of mucosa best?  
Mark only one oval.



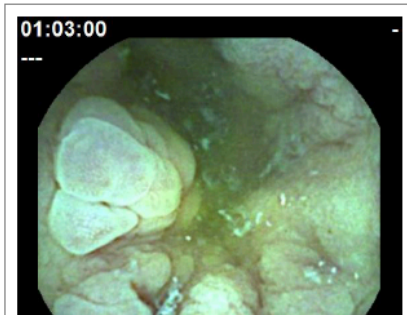
Option 1



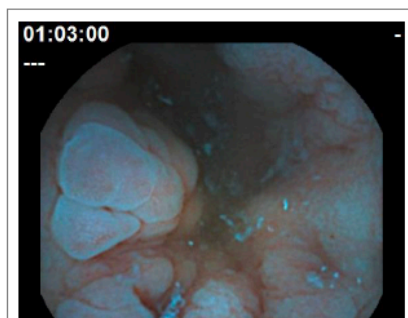
Option 2



Option 3

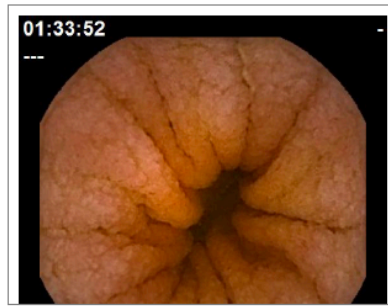

Option 4

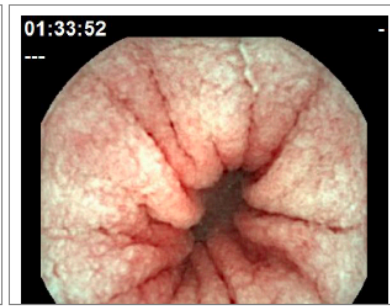


Option 5

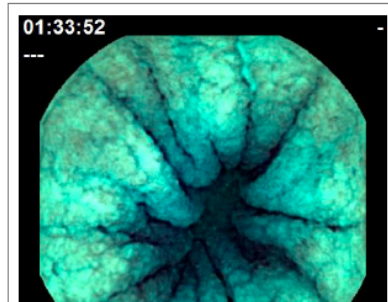
5. 5. Which capsule endoscopy image shows mosaic pattern of mucosa best?  
Mark only one oval.



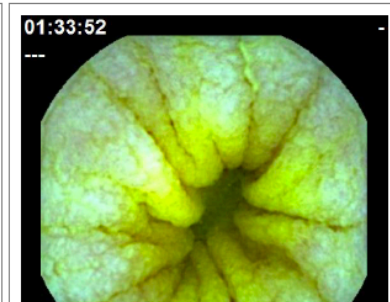
Option 1



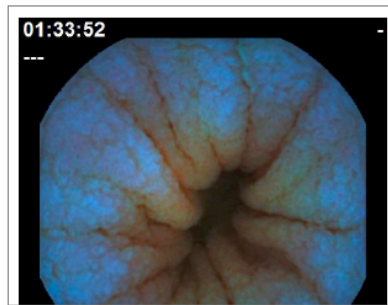
Option 2



Option 3



Option 4



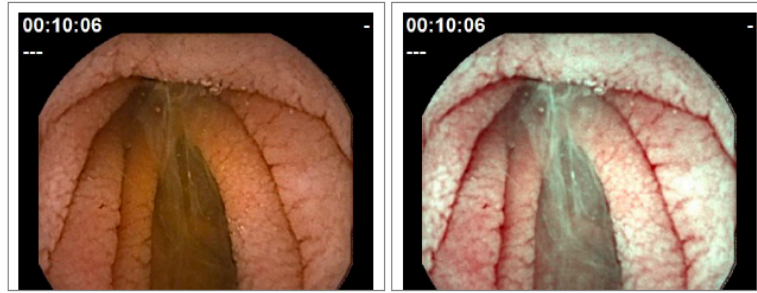
Option 5

**Severe features of coeliac disease:**



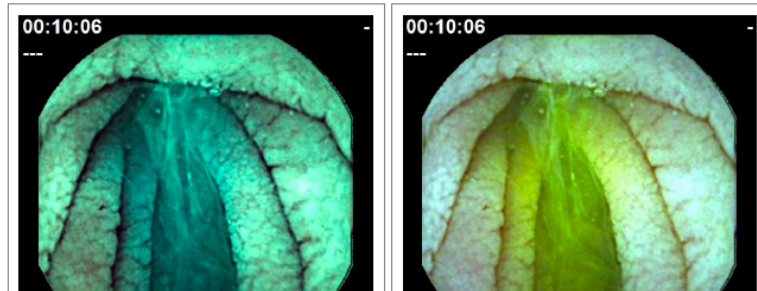
6. 1. Which capsule endoscopy image shows fissuring of mucosa best?

Mark only one oval.



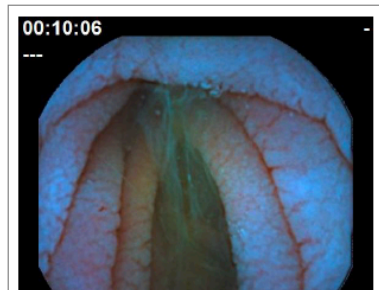
Option 1

Option 2



Option 3

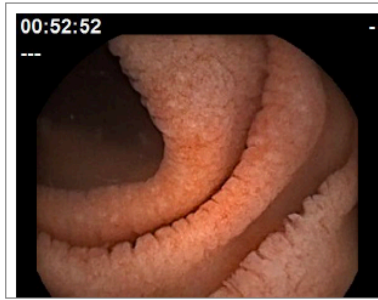Option 4



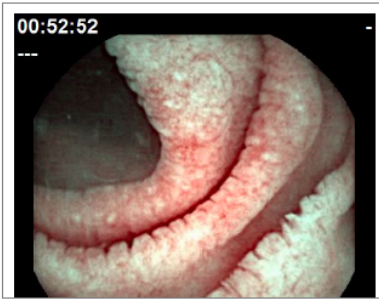Option 5



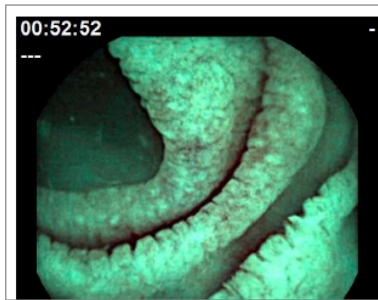
7. 2. Which capsule endoscopy image shows scalloping of mucosa best?  
Mark only one oval.



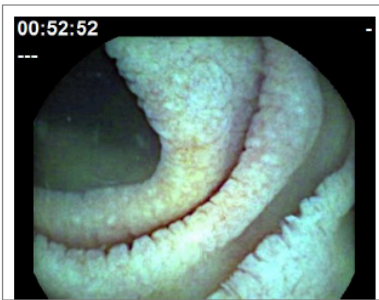Option 1



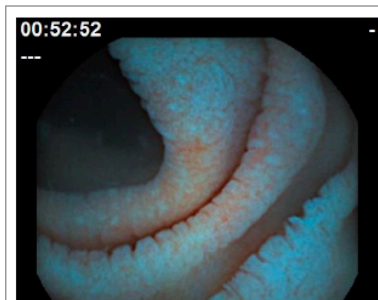
Option 2



Option 3

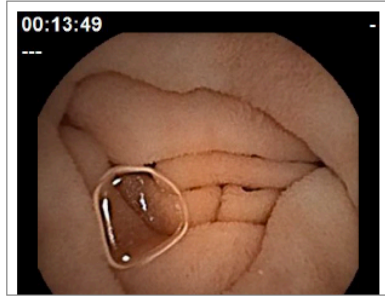


Option 4

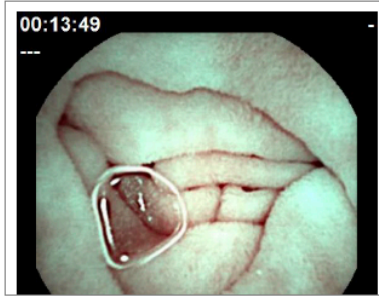


Option 5

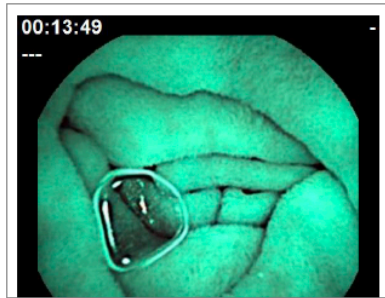
8. 3. Which capsule endoscopy image shows villous atrophy best?  
Mark only one oval.



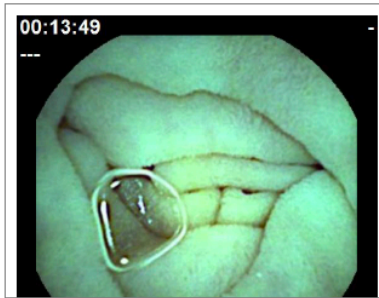
Option 1



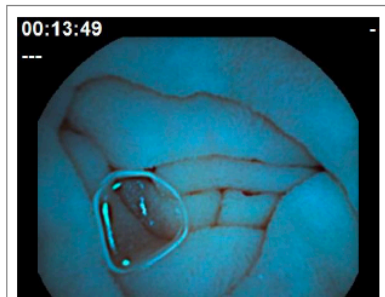
Option 2



Option 3

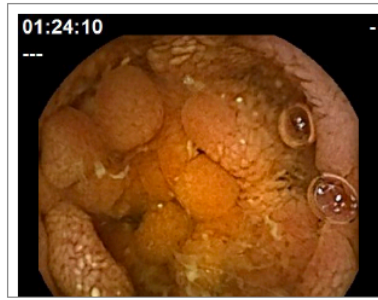

Option 4

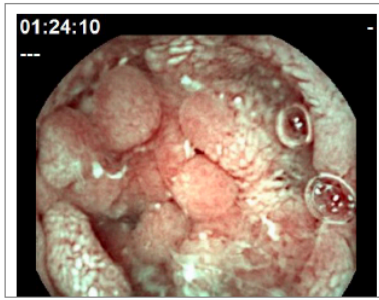


Option 5

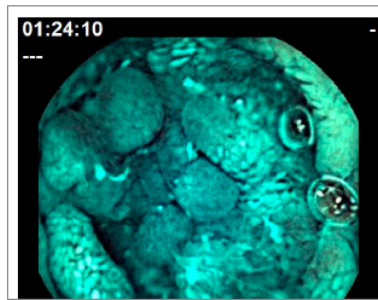
9. 4. Which capsule endoscopy image shows nodularity of mucosa best?  
Mark only one oval.



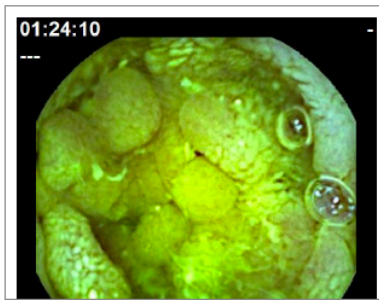
Option 1



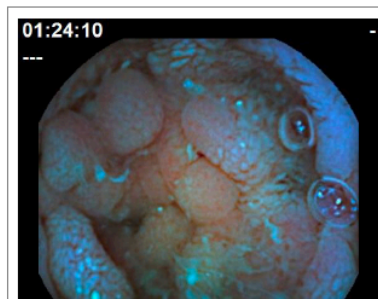
Option 2



Option 3

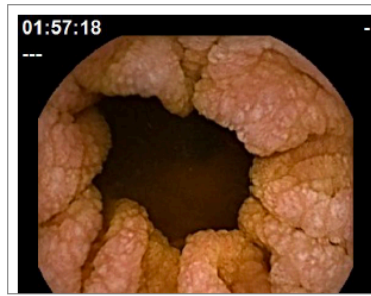

Option 4

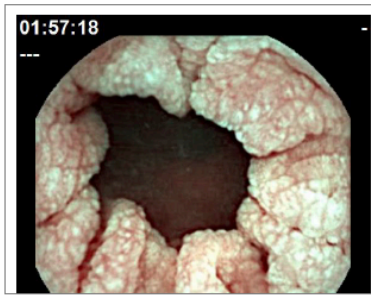

Option 5

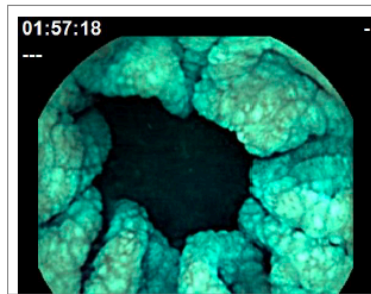
10. 5. Which capsule endoscopy image shows mosaic pattern of mucosa best?  
Mark only one oval.



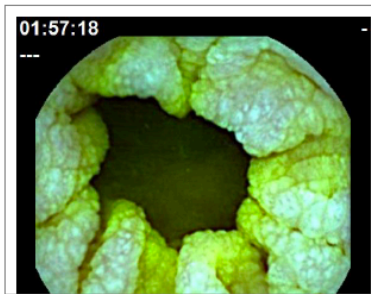
Option 1



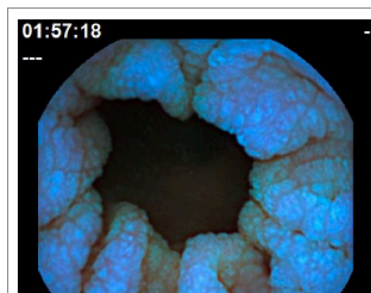
Option 2



Option 3



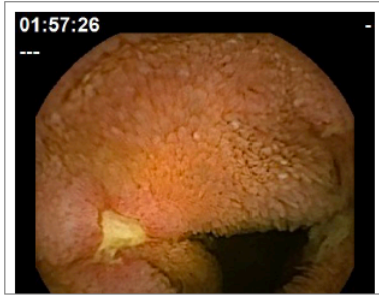
Option 4



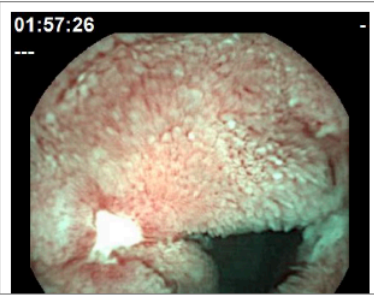
Option 5

**Ulcers in patients with coeliac disease**

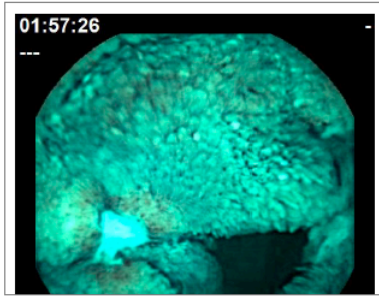
11. Which image shows ulceration of mucosa best?  
Tick all that apply.



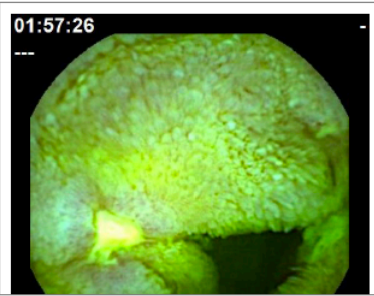
Option 1



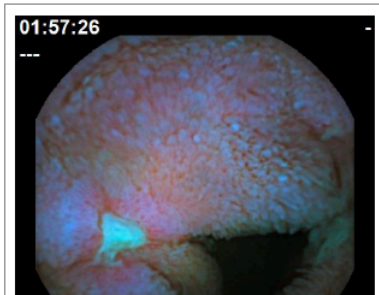
Option 2



Option 3



Option 4



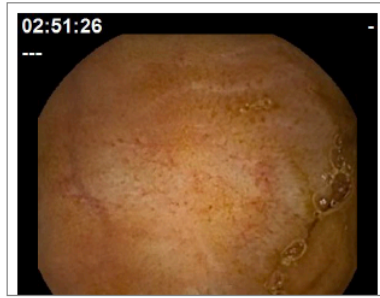
Option 5

Each question in this section shows images from different sections of the small bowel of a patient with coeliac disease. 5 out of 10 are abnormal in each question.

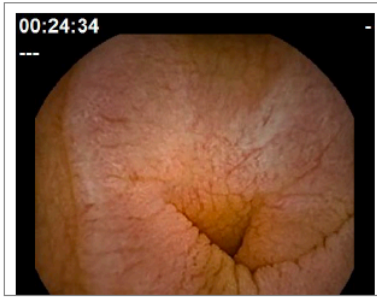


12. 1. Which images show features of coeliac disease (5/10)?

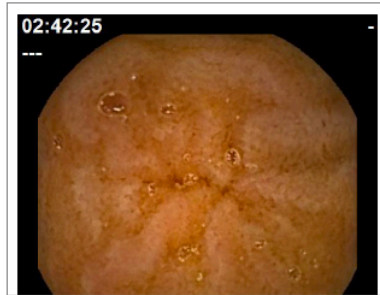Tick all that apply.



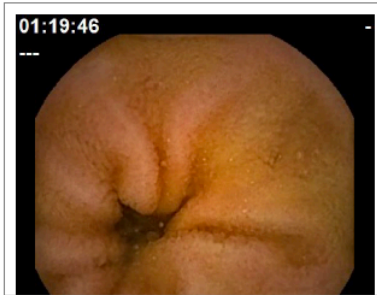Option 1



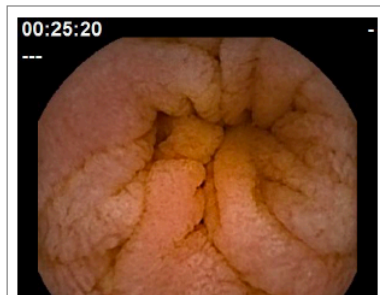
Option 2



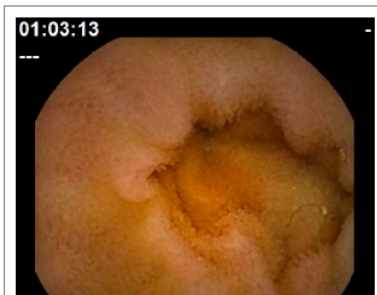
Option 3



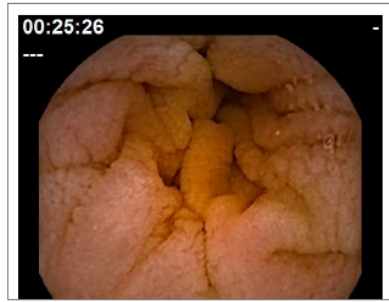Option 4



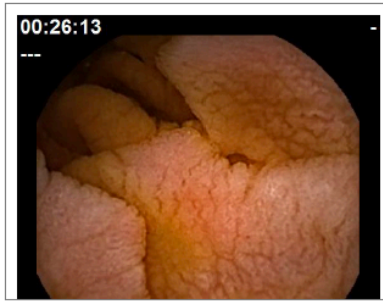
Option 5



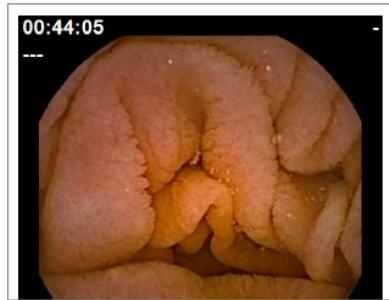
Option 6



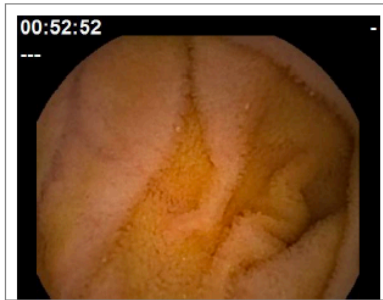
Option 7



Option 8



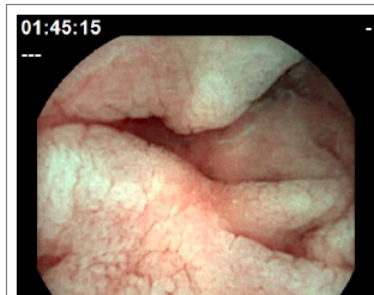Option 9



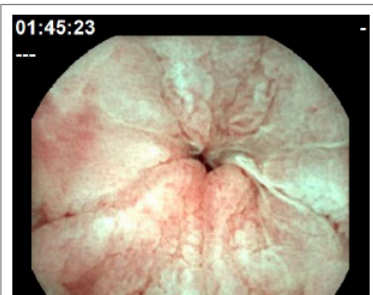
Option 10

13. 2. Which images show features of coeliac disease (5/10)?

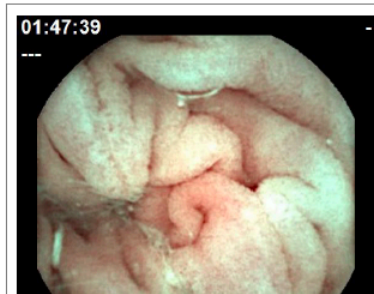Tick all that apply.



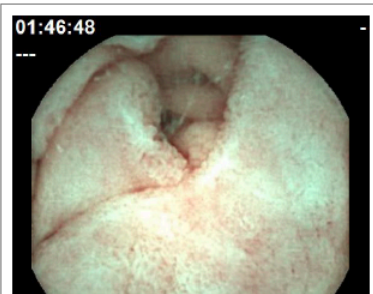
Option 1



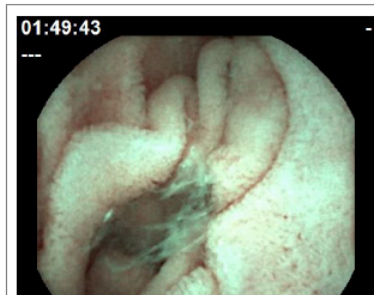
Option 2



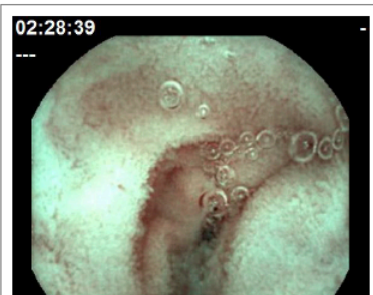Option 3



Option 4

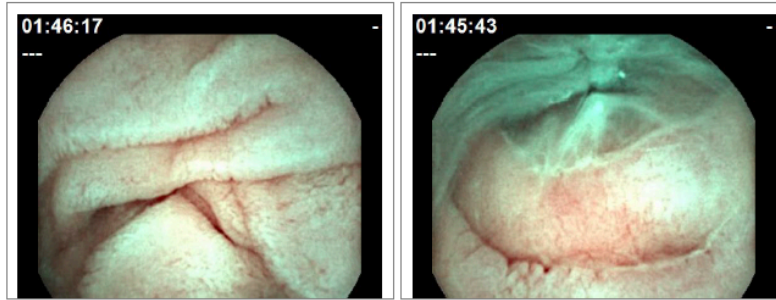


Option 5



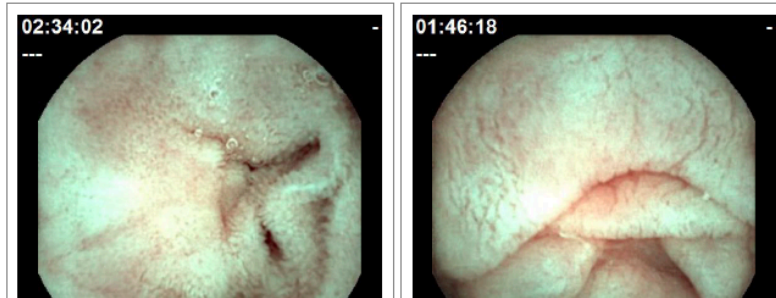
Option 6





Option 7

Option 8



Option 9

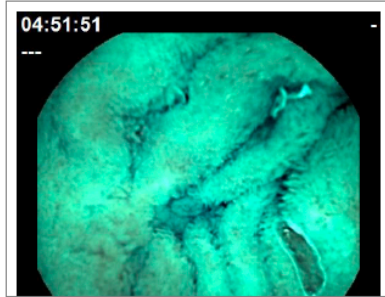
Option 10

07/11/2018

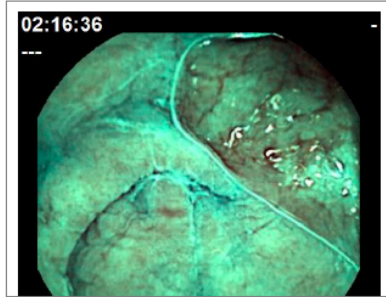
The use of flexible spectral imaging colour enhancement and blue light in coeliac disease.

14. 3. Which images show features of coeliac disease (5/10)?

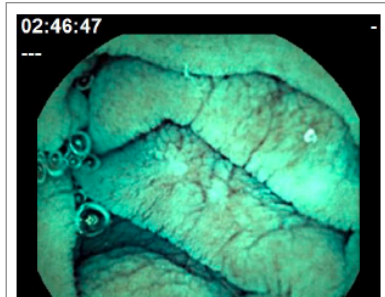
Tick all that apply.



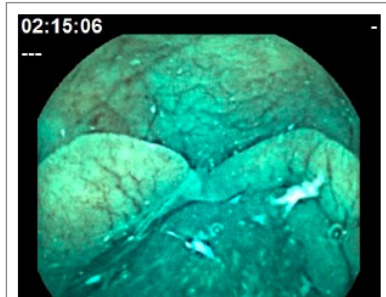
Option 1



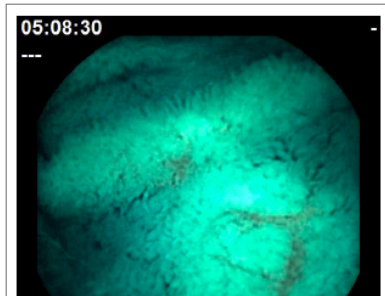
Option 2



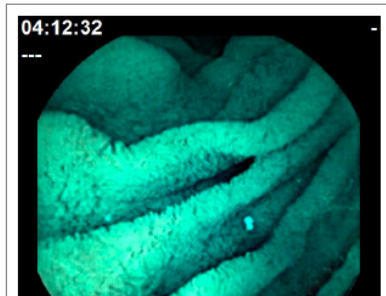Option 3



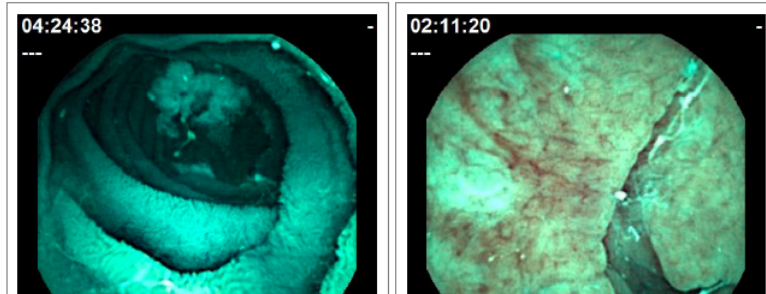
Option 4



Option 5

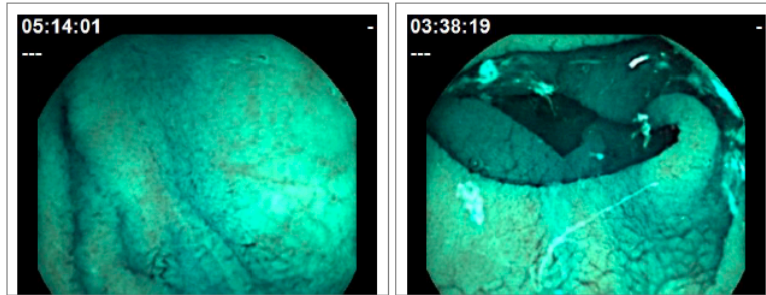


Option 6



Option 7

Option 8



Option 9

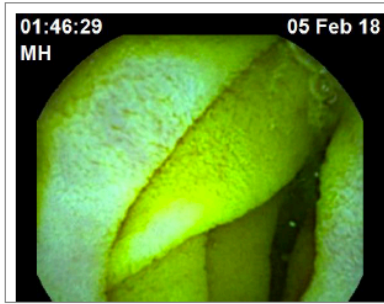
Option 10

07/11/2018

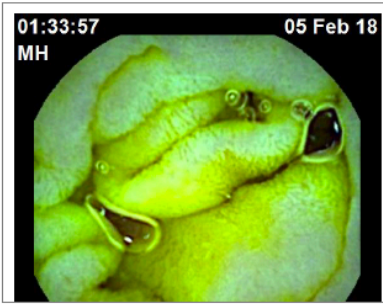
The use of flexible spectral imaging colour enhancement and blue light in coeliac disease.

15. 4. Which images show features of coeliac disease (5/10)?

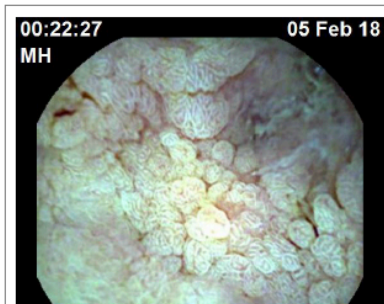
Tick all that apply.



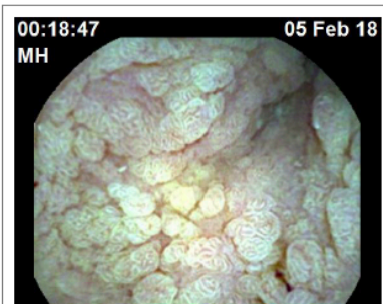
Option 1



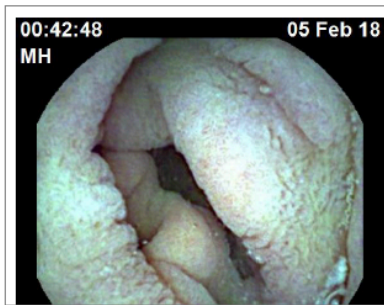
Option 2



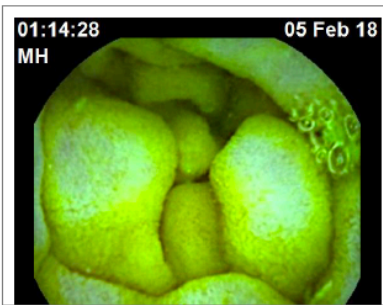
Option 3



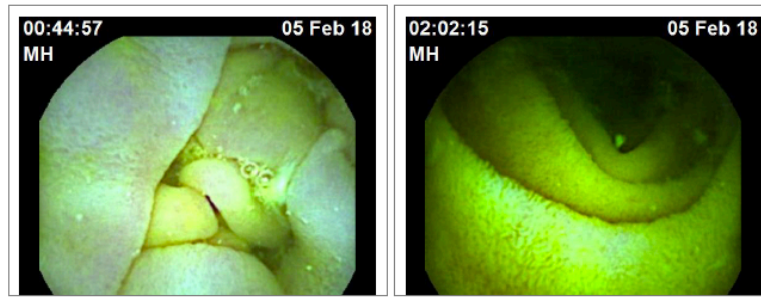
Option 4



Option 5

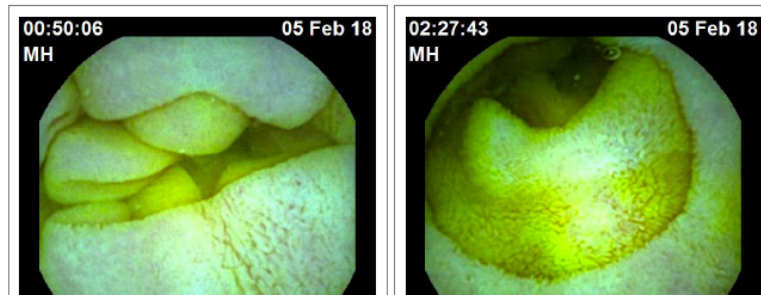


Option 6



Option 7

Option 8



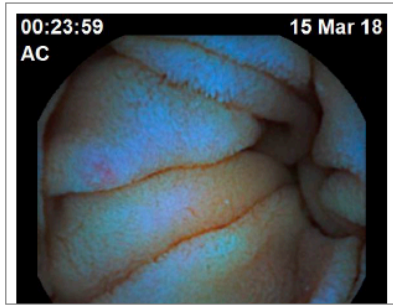
Option 9

Option 10

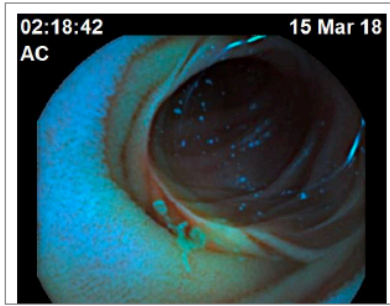


16. 5. Which images show features of coeliac disease (5/10)?

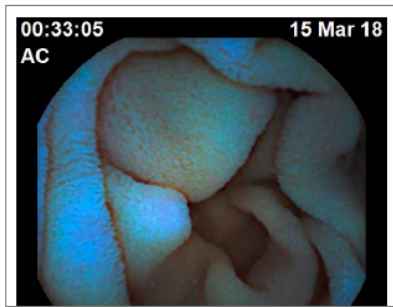
Tick all that apply.



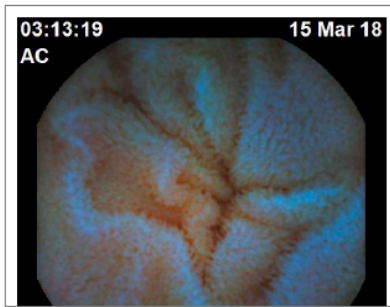
Option 1



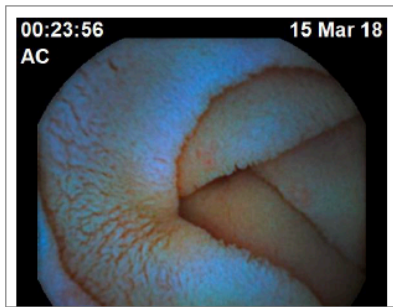
Option 2



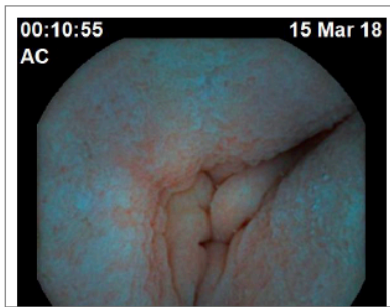
Option 3



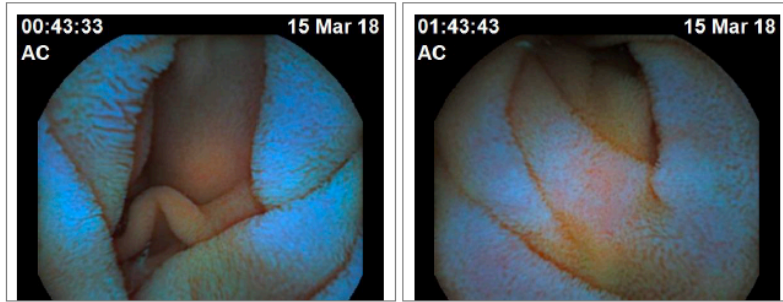
Option 4



Option 5

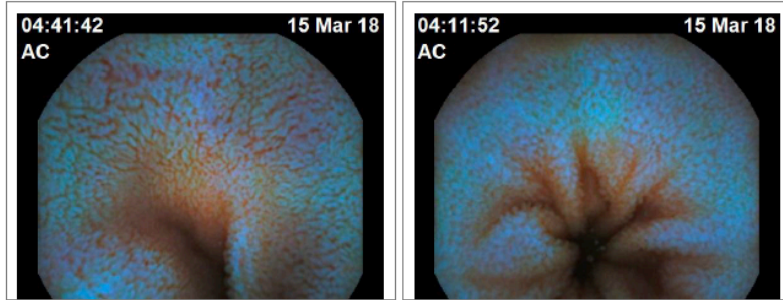


Option 6



Option 7

Option 8



Option 9

Option 10

---

Powered by  
 Google Forms

10.6 Ethics – approval letter

Downloaded: 07/11/2018

Approved: 04/05/2018

Stefania Chetcuti Zammit

Registration number: 170269362

Cardiovascular Science

Programme: MD

Dear Stefania

**PROJECT TITLE:** Small bowel capsule endoscopy in patients with coeliac disease.

**APPLICATION:** Reference Number 018590

On behalf of the University ethics reviewers who reviewed your project, I am pleased to inform you that on 04/05/2018 the above-named project was **approved** on ethics grounds, on the basis that you will adhere to the following documentation that you submitted for ethics review:

University research ethics application form 018590 (dated 19/04/2018).

If during the course of the project you need to deviate significantly from the above-approved documentation please inform me since written approval will be required.

Yours sincerely



Jean Lazenby

Ethics Administrator

Medical School

## Chapter 11 Bibliography

Abdulkarim, A. S., Burgart, L. J., See, J. & Murray, J. A. (2002) Etiology of nonresponsive celiac disease: results of a systematic approach. *Am J Gastroenterol*, 97(8), 2016-21.

Abrams, J. A., Diamond, B., Rotterdam, H. & Green, P. H. (2004) Seronegative celiac disease: increased prevalence with lesser degrees of villous atrophy. *Dig Dis Sci*, 49(4), 546-50.

Adler, S. N. & Bjarnason, I. (2012) What we have learned and what to expect from capsule endoscopy. *World journal of gastrointestinal endoscopy*, 4(10), 448-452.

Akarsu, C., Sahbaz, N. A., Dural, A. C., Kones, O., Binboga, S., Kabuli, H. A., Gumusoglu, A. Y. & Alis, H. (2017) FICE in Predicting Colorectal Flat Lesion Histology. *JSLs*, 21(4).

Al-Toma, A., Goerres, M. S., Meijer, J. W., von Blomberg, B. M., Wahab, P. J., Kerckhaert, J. A. & Mulder, C. J. (2006) Cladribine therapy in refractory celiac disease with aberrant T cells. *Clin Gastroenterol Hepatol*, 4(11), 1322-7; quiz 1300.

Al-Toma, A., Verbeek, W. H., Hadithi, M., von Blomberg, B. M. & Mulder, C. J. (2007) Survival in refractory coeliac disease and enteropathy-associated T-cell lymphoma: retrospective evaluation of single-centre experience. *Gut*, 56(10), 1373-8.

Al-toma, A., Visser, O. J., van Roessel, H. M., von Blomberg, B. M., Verbeek, W. H., Scholten, P. E., Ossenkoppele, G. J., Huijgens, P. C. & Mulder, C. J. (2007) Autologous hematopoietic stem cell transplantation in refractory celiac disease with aberrant T cells. *Blood*, 109(5), 2243-9.

Al-Toma, A., Volta, U., Auricchio, R., Castillejo, G., Sanders, D. S., Cellier, C., Mulder, C. J. & Lundin, K. E. A. (2019) European Society for the Study of Coeliac Disease (ESsCD) guideline for coeliac disease and other gluten-related disorders. *United European Gastroenterol J*, 7(5), 583-613.

Alessio, M. G., Tonutti, E., Brusca, I., Radice, A., Licini, L., Sonzogni, A., Florena, A., Schiaffino, E., Marus, W., Sulfaro, S. & Villalta, D. (2012) Correlation between IgA tissue transglutaminase antibody ratio and histological finding in celiac disease. *J Pediatr Gastroenterol Nutr*, 55(1), 44-9.

Anderson, R. P. (2008) Coeliac disease: current approach and future prospects. *Internal Medicine Journal*, 38(10), 790-799.

Atlas, D. S., Rubio-Tapia, A., Van Dyke, C. T., Lahr, B. D. & Murray, J. A. (2011) Capsule endoscopy in nonresponsive celiac disease. *Gastrointestinal endoscopy*, 74(6), 1315-1322.

Aziz, I., Evans, K. E., Hopper, A. D., Smillie, D. M. & Sanders, D. S. (2010) A prospective study into the aetiology of lymphocytic duodenosis. *Aliment Pharmacol Ther*, 32(11-12), 1392-7.

Aziz, I., Key, T., Goodwin, J. G. & Sanders, D. S. (2015) Predictors for Celiac Disease in Adult Cases of Duodenal Intraepithelial Lymphocytosis. *J Clin Gastroenterol*, 49(6), 477-82.

Aziz, I., Peerally, M. F., Barnes, J. H., Kandasamy, V., Whiteley, J. C., Partridge, D., Vergani, P., Cross, S. S., Green, P. H. & Sanders, D. S. (2017) The clinical and phenotypical assessment of seronegative villous atrophy; a prospective UK centre experience evaluating 200 adult cases over a 15-year period (2000-2015). *Gut*, 66(9), 1563-1572.

Bahram, S., S, B., B, C. R., S, F., D, G., T, G., L, H., R, H., H, I., M, J., C, J., A, M., S, M., J, N. M., A, O., S, Q., G, R., J, R., L, R., T, S., T, S., G, T., H, T., H, T., Q, V., L, W. & M, Y. (1999) Complete sequence and gene map of a human major histocompatibility complex. The MHC sequencing consortium. *Nature*, 401(6756), 921-3.

Balaban, D. V., Popp, A., Vasilescu, F., Haidautu, D., Purcarea, R. M. & Jinga, M. (2015) Diagnostic yield of endoscopic markers for celiac disease. *Journal of medicine and life*, 8(4), 452-457.

Bardella, M. T., Minoli, G., Radaelli, F., Quatrini, M., Bianchi, P. A. & Conte, D. (2000) Reevaluation of duodenal endoscopic markers in the diagnosis of celiac disease. *Gastrointestinal endoscopy*, 51(6), 714-716.

Barret, M., Malamut, G., Rahmi, G., Samaha, E., Edery, J., Verkarre, V., Macintyre, E., Lenain, E., Chatellier, G., Cerf-Bensussan, N. & Cellier, C. (2012) Diagnostic yield of capsule endoscopy in refractory celiac disease. *The American Journal of Gastroenterology*, 107(10), 1546-1553.

Bassotti, G., Castellucci, G., Betti, C., Fusaro, C., Cavalletti, M. L., Bertotto, A., Spinozzi, F., Morelli, A. & Pelli, M. A. (1994) Abnormal gastrointestinal motility in patients with celiac sprue. *Dig Dis Sci*, 39(9), 1947-54.

Basturk, A., Artan, R. & Yilmaz, A. (2017) The incidence of HLA-DQ2/DQ8 in Turkish children with celiac disease and a comparison of the geographical distribution of HLA-DQ. *Prz Gastroenterol*, 12(4), 256-261.

Beg S , Card T , Sidhu R, Wronska E & K, R. (2018) ADWE-07 How many capsule endoscopy cases can be read before accuracy is affected? *Gut*, 67(A164).

Benini, F., Mora, A., Turini, D., Bertolazzi, S., Lanzarotto, F., Ricci, C., Villanacci, V., Barbara, G., Stanghellini, V. & Lanzini, A. (2012) Slow gallbladder emptying reverts to normal but small intestinal transit of a physiological meal remains slow in celiac patients during gluten-free diet. *Neurogastroenterology and motility : the official journal of the European Gastrointestinal Motility Society*, 24(2), 100-7, e79-80.

Bhattacharya, M., Lomash, A., Sakhuja, P., Dubey, A. P. & Kapoor, S. (2014) Clinical and histopathological correlation of duodenal biopsy with IgA anti-tissue transglutaminase titers in children with celiac disease. *Indian J Gastroenterol*, 33(4), 350-4.

Biagi, F. & Corazza, G. R. (2001) Defining gluten refractory enteropathy. *Eur J Gastroenterol Hepatol*, 13(5), 561-5.

Biagi, F., Gobbi, P., Marchese, A., Borsotti, E., Zingone, F., Ciacci, C., Volta, U., Caio, G., Carroccio, A., Ambrosiano, G., Mansueto, P. & Corazza, G. R. (2014) Low incidence but poor prognosis of complicated coeliac disease: a retrospective multicentre study. *Dig Liver Dis*, 46(3), 227-30.

Biagi, F., Rondonotti, E., Campanella, J., Villa, F., Bianchi, P. I., Klersy, C., De Franchis, R. & Corazza, G. R. (2006) Video capsule endoscopy and histology for small-bowel mucosa evaluation: a comparison performed by blinded observers. *Clinical gastroenterology and hepatology : the official clinical practice journal of the American Gastroenterological Association*, 4(8), 998-1003.

Bjarnason, I., Marsh, M. N., Price, A., Levi, A. J. & Peters, T. J. (1985) Intestinal permeability in patients with coeliac disease and dermatitis herpetiformis. *Gut*, 26(11), 1214-9.

Boal Carvalho, P., Magalhães, J., Dias de Castro, F., Gonçalves, T. C., Rosa, B., Moreira, M. J. & Cotter, J. (2016) Virtual chromoendoscopy improves the diagnostic yield of small bowel capsule endoscopy in obscure gastrointestinal bleeding. *Dig Liver Dis*, 48(2), 172-5.

Bonamico, M., Mariani, P., Thanasi, E., Ferri, M., Nenna, R., Tiberti, C., Mora, B., Mazzilli, M. C. & Magliocca, F. M. (2004) Patchy villous atrophy of the duodenum in childhood celiac disease. *Journal of pediatric gastroenterology and nutrition*, 38(2), 204-207.

Brar, P., Kwon, G. Y., Egbuna, II, Holleran, S., Ramakrishnan, R., Bhagat, G. & Green, P. H. (2007) Lack of correlation of degree of villous atrophy with severity of clinical presentation of coeliac disease. *Dig Liver Dis*, 39(1), 26-9.

Brocchi, E., Corazza, G. R., Caletti, G., Treggiari, E. A., Barbara, L. & Gasbarrini, G. (1988) Endoscopic demonstration of loss of duodenal folds in the diagnosis of celiac disease. *The New England journal of medicine*, 319(12), 741-744.

Brocchi, E., Tomassetti, P., Misitano, B., Epifanio, G., Corinaldesi, R., Bonvicini, F., Gasbarrini, G. & Corazza, G. (2002) Endoscopic markers in adult coeliac disease. *Digestive and liver disease : official journal of the Italian Society of Gastroenterology and the Italian Association for the Study of the Liver*, 34(3), 177-182.

Cammarota, G., Martino, A., Pirozzi, G. A., Cianci, R., Cremonini, F., Zuccala, G., Cuoco, L., Ojetti, V., Montalto, M., Vecchio, F. M., Gasbarrini, A. & Gasbarrini, G. (2004) Direct visualization of intestinal villi by high-resolution magnifying upper endoscopy: a validation study. *Gastrointestinal endoscopy*, 60(5), 732-738.

Campagna, G., Pesce, M., Tatangelo, R., Rizzuto, A., La Fratta, I. & Grilli, A. (2017) The progression of coeliac disease: its neurological and psychiatric implications. *Nutr Res Rev*, 30(1), 25-35.

Camus, M., Coriat, R., Leblanc, S., Brezault, C., Terris, B., Pommaret, E., Gaudric, M., Chrystostalis, A., Prat, F. & Chaussade, S. (2012) Helpfulness of the combination of acetic acid and FICE in the detection of Barrett's epithelium and Barrett's associated neoplasias. *World J Gastroenterol*, 18(16), 1921-5.

Casella, S., Zanini, B., Lanzarotto, F., Villanacci, V., Ricci, C. & Lanzini, A. (2012) Celiac disease in elderly adults: clinical, serological, and histological characteristics and the effect of a gluten-free diet. *J Am Geriatr Soc*, 60(6), 1064-9.

Cataldo, F., Marino, V., Ventura, A., Bottaro, G. & Corazza, G. R. (1998) Prevalence and clinical features of selective immunoglobulin A deficiency in coeliac disease: an Italian multicentre study. Italian Society of Paediatric Gastroenterology and Hepatology (SIGEP) and "Club del Tenue" Working Groups on Coeliac Disease. *Gut*, 42(3), 362-5.

Catassi C, A., Cellier C and Cerf-Bensussan N, Paris, Ciclitira PJ, L., Collin P, T., Corazza, GR, P., Dickey W, L., Fasano A, B., Holmes GKT, D., Klinecicz P, P., Mearin ML, L., Mulder CJJ, A., Murray JA, Rochester, Pena AS, A., Schuppan D, E., Sollid LM, O., Uil JJ, W., Wahab PJ, Arnhem, Walker-Smith JA, L. & Watson P, B. U. E. G. (2001) When is a coeliac a coeliac? Report of a working group of the United European Gastroenterology Week in Amsterdam, 2001. *Eur J Gastroenterol Hepatol*, 13(9), 1123-8.

Cellier, C., Bouma, G., van Gils, T., Khater, S., Malamut, G., Crespo, L., Green, P. H., Crowe, S. E., Collin, P., Tsuji, W. H., Leon, F. & Mulder, C. J. (2018) 616 - AMG 714 (Anti-IL-15 MAB) Halts the Progression of Aberrant Intraepithelial Lymphocytes in Refractory Celiac Disease type II (RCD-II): A Phase 2A, Randomized, Double-Blind, Placebo-Controlled Study Evaluating AMG 714 in Adult Patients with RCD-II/Pre-EATL, 154. *Gastroenterology*.

Cellier, C., Delabesse, E., Helmer, C., Patey, N., Matuchansky, C., Jabri, B., Macintyre, E., Cerf-Bensussan, N. & Brousse, N. (2000) Refractory sprue, coeliac disease, and enteropathy-associated T-cell lymphoma. French Coeliac Disease Study Group. *Lancet*, 356(9225), 203-8.

Chetcuti Zammit, S., Sanders, D. S., Cross, S. S. & Sidhu, R. (2019a) Capsule endoscopy in the management of refractory coeliac disease. *J Gastrointest Liver Dis*, 28(1), 15-22.

Chetcuti Zammit, S., Sanders, D. S., McAlindon, M. E. & Sidhu, R. (2019b) Optimising the use of small bowel endoscopy: a practical guide. *Frontline Gastroenterol*, 10(2), 171-176.

Chiarioni, G., Bassotti, G., Germani, U., Battaglia, E., Brentegani, M. T., Morelli, A. & Vantini, I. (1997) Gluten-free diet normalizes mouth-to-cecum transit of a caloric meal in adult patients with celiac disease. *Digestive diseases and sciences*, 42(10), 2100-2105.

Ciaccio, E. J., Tennyson, C. A., Bhagat, G., Lewis, S. K. & Green, P. H. (2012) Quantitative estimates of motility from videocapsule endoscopy are useful to discern celiac patients from controls. *Digestive diseases and sciences*, 57(11), 2936-2943.

Ciccocioppo, R., Di Sabatino, A., Bauer, M., Della Riccia, D. N., Bizzini, F., Biagi, F., Cifone, M. G., Corazza, G. R. & Schuppan, D. (2005) Matrix metalloproteinase pattern in celiac duodenal mucosa. *Lab Invest*, 85(3), 397-407.

Ciclitira, P. J., King, A. L. & Fraser, J. S. (2001) AGA technical review on Celiac Sprue. American Gastroenterological Association. *Gastroenterology*, 120(6), 1526-1540.

Collin, P., Kaukinen, K., Vogelsang, H., Korponay-Szabo, I., Sommer, R., Schreier, E., Volta, U., Granito, A., Veronesi, L., Mascart, F., Ocmant, A., Ivarsson, A., Lagerqvist, C., Burgin-Wolff, A., Hadziselimovic, F., Furlano, R. I., Sidler, M. A., Mulder, C. J., Goerres, M. S., Mearin, M. L., Ninaber, M. K., Gudmand-Hoyer, E., Fabiani, E., Catassi, C., Tidlund, H., Alaintalo, L. & Maki, M. (2005) Antiendomysial and antihuman recombinant tissue transglutaminase antibodies in the diagnosis of coeliac disease: a biopsy-proven European multicentre study. *Eur J Gastroenterol Hepatol*, 17(1), 85-91.

Collin, P., Rondonotti, E., Lundin, K. E., Spada, C., Keuchel, M., Kaukinen, K., DE Franchis, R., Jacobs, M. A., Villa, F. & Mulder, C. J. (2012) Video capsule endoscopy in celiac disease: current clinical practice. *J Dig Dis*, 13(2), 94-9.

Connolly, L. & Chang, L. (2011) Combined orocecal scintigraphy and lactulose hydrogen breath testing demonstrate that breath testing detects orocecal transit, not small intestinal bacterial overgrowth in patients with irritable bowel syndrome. *Gastroenterology*, 141(3), 1118-21.

Cooper, B. T., Holmes, G. K. & Cooke, W. T. (1982) Lymphoma risk in coeliac disease of later life. *Digestion*, 23(2), 89-92.

Corazza, G. R. & Gasbarrini, G. (1995) Coeliac disease in adults. *Bailliere's Clinical Gastroenterology*, 9(2), 329-350.

Costantino, G., della Torre, A., Lo Presti, M. A., Caruso, R., Mazzon, E. & Fries, W. (2008) Treatment of life-threatening type I refractory coeliac disease with long-term infliximab. *Dig Liver Dis*, 40(1), 74-7.

Cotter, J., Dias de Castro, F., Magalhães, J., Moreira, M. J. & Rosa, B. (2015) Validation of the Lewis score for the evaluation of small-bowel Crohn's disease activity. *Endoscopy*, 47(4), 330-5.

Cotter, J., Magalhaes, J., de Castro, F. D., Barbosa, M., Carvalho, P. B., Leite, S., Moreira, M. J. & Rosa, B. (2014) Virtual chromoendoscopy in small bowel capsule endoscopy: New light or a cast of shadow? *World J Gastrointest Endosc*, 6(8), 359-65.

Culliford, A., Daly, J., Diamond, B., Rubin, M. & Green, P. H. (2005) The value of wireless capsule endoscopy in patients with complicated celiac disease. *Gastrointest Endosc*, 62(1), 55-61.

Dahlbom, I., Korponay-Szabo, I. R., Kovacs, J. B., Szalai, Z., Maki, M. & Hansson, T. (2010) Prediction of clinical and mucosal severity of coeliac disease and dermatitis herpetiformis by quantification of IgA/IgG serum antibodies to tissue transglutaminase. *J Pediatr Gastroenterol Nutr*, 50(2), 140-6.

Daum, S., Bauer, U., Foss, H. D., Schuppan, D., Stein, H., Riecken, E. O. & Ullrich, R. (1999) Increased expression of mRNA for matrix metalloproteinases-1 and -3 and tissue inhibitor of metalloproteinases-1 in intestinal biopsy specimens from patients with coeliac disease. *Gut*, 44(1), 17-25.

Daum, S., Ipczynski, R., Schumann, M., Wahnschaffe, U., Zeitz, M. & Ullrich, R. (2009) High rates of complications and substantial mortality in both types of refractory sprue. *Eur J Gastroenterol Hepatol*, 21(1), 66-70.

Daum, S., Wahnschaffe, U., Glasenapp, R., Borchert, M., Ullrich, R., Zeitz, M. & Faiss, S. (2007) Capsule endoscopy in refractory celiac disease. *Endoscopy*, 39(5), 455-458.

Daum, S., Weiss, D., Hummel, M., Ullrich, R., Heise, W., Stein, H., Riecken, E. O., Foss, H. D. & Group, I. L. S. (2001) Frequency of clonal intraepithelial T lymphocyte proliferations in enteropathy-type intestinal T cell lymphoma, coeliac disease, and refractory sprue. *Gut*, 49(6), 804-12.

DeGaetani, M., Tennyson, C. A., Lebwohl, B., Lewis, S. K., Abu Daya, H., Arguelles-Grande, C., Bhagat, G. & Green, P. H. (2013) Villous atrophy and negative celiac serology: a diagnostic and therapeutic dilemma. *Am J Gastroenterol*, 108(5), 647-53.

Di Sabatino, A., Biagi, F., Gobbi, P. G. & Corazza, G. R. (2012) How I treat enteropathy-associated T-cell lymphoma. *Blood*, 119(11), 2458-68.

Dias de Castro, F., Magalhães, J., Boal Carvalho, P., Cúrdia Gonçalves, T., Rosa, B., Moreira, M. J. & Cotter, J. (2015) Improving diagnostic yield in obscure gastrointestinal bleeding--how virtual chromoendoscopy may be the answer. *Eur J Gastroenterol Hepatol*, 27(6), 735-40.

Dickey, W. & Hughes, D. (1999) Prevalence of celiac disease and its endoscopic markers among patients having routine upper gastrointestinal endoscopy. *The American Journal of Gastroenterology*, 94(8), 2182-2186.

Dickey, W. & Hughes, D. (2001) Disappointing sensitivity of endoscopic markers for villous atrophy in a high-risk population: implications for celiac disease diagnosis during routine endoscopy. *The American Journal of Gastroenterology*, 96(7), 2126-2128.

Digenis, G. A., Sandefer, E.P., Parr, A.F., Beihn, R., McClain, C., Scheinthal, B.M., Ghebre-Sellassie, I., Iyer, U., Nesbitt, R.U. and Randinitis, E. (1990) Gastrointestinal Behavior of Orally Administered Radiolabeled Erythromycin Pellets in Man as Determined by Gamma Scintigraphy. *The Journal of Clinical Pharmacology*, 30, 621-631.

Ding, Z., Shi, H., Zhang, H., Meng, L., Fan, M., Han, C., Zhang, K., Ming, F., Xie, X., Liu, H., Liu, J., Lin, R. & Hou, X. (2019) Gastroenterologist-Level Identification of Small-Bowel Diseases and Normal Variants by Capsule Endoscopy Using a Deep-Learning Model. *Gastroenterology*, 157(4), 1044-1054.e5.

Downey, L., Houten, R., Murch, S., Longson, D. & Group, G. D. (2015) Recognition, assessment, and management of coeliac disease: summary of updated NICE guidance. *BMJ*, 351, h4513.

Duque, G., Almeida, N., Figueiredo, P., Monsanto, P., Lopes, S., Freire, P., Ferreira, M., Carvalho, R., Gouveia, H. & Sofia, C. (2012) Virtual chromoendoscopy can be a useful software tool in capsule endoscopy. *Rev Esp Enferm Dig*, 104(5), 231-6.

Efthymakis, K., Milano, A., Laterza, F., Serio, M. & Neri, M. (2017) Iron deficiency anemia despite effective gluten-free diet in celiac disease: Diagnostic role of small bowel capsule endoscopy. *Dig Liver Dis*, 49(4), 412-416.

Eigner, W., Bashir, K., Primas, C., Kazemi-Shirazi, L., Wrba, F., Trauner, M. & Vogelsang, H. (2017) Dynamics of occurrence of refractory coeliac disease and associated complications over 25 years. *Aliment Pharmacol Ther*, 45(2), 364-372.

El-Matary, W., Huynh, H. & Vandermeer, B. (2009) Diagnostic characteristics of given video capsule endoscopy in diagnosis of celiac disease: a meta-analysis. *Journal of laparoendoscopic & advanced surgical techniques.Part A*, 19(6), 815-820.

Elli, L., Casazza, G., Locatelli, M., Branchi, F., Ferretti, F., Conte, D. & Fraquelli, M. (2017) Use of enteroscopy for the detection of malignant and premalignant lesions of the small bowel in complicated celiac disease: a meta-analysis. *Gastrointest Endosc*, 86(2), 264-273.e1.

Ellis, A. (1981) Coeliac Disease: Previous Family Studies., *The Genetics of Coeliac Disease* Springer, Dordrecht, 197-200.

Fedeli, P., Gasbarrini, A. & Cammarota, G. (2011) Spectral endoscopic imaging: the multiband system for enhancing the endoscopic surface visualization. *J Clin Gastroenterol*, 45(1), 6-15.

Ferrari, S. M., Fallahi, P., Ruffilli, I., Elia, G., Ragusa, F., Benvenga, S. & Antonelli, A. (2019) The association of other autoimmune diseases in patients with Graves' disease (with or without ophthalmopathy): Review of the literature and report of a large series. *Autoimmun Rev*.

Freeman, H. J. (1994) Clinical Spectrum of Biopsy-Defined Celiac Disease in the Elderly. Canadian Journal of Gastroenterology: Hindawi Publishing Corporation.

Gibbons, C. H. & Freeman, R. (2005) Autonomic neuropathy and coeliac disease. *J Neurol Neurosurg Psychiatry*, 76(4), 579-81.

Gillett, H. R., Arnott, I. D., McIntyre, M., Campbell, S., Dahele, A., Priest, M., Jackson, R. & Ghosh, S. (2002) Successful infliximab treatment for steroid-refractory celiac disease: a case report. *Gastroenterology*, 122(3), 800-5.

Gkolfakis, P., Tziatzios, G., Dimitriadis, G. D. & Triantafyllou, K. (2018) Meta-analysis of randomized controlled trials challenging the usefulness of purgative preparation before small-bowel video capsule endoscopy. *Endoscopy*, 50(7), 671-683.

Goerres, M. S., Meijer, J. W., Wahab, P. J., Kerckhaert, J. A., Groenen, P. J., Van Krieken, J. H. & Mulder, C. J. (2003) Azathioprine and prednisone combination therapy in refractory coeliac disease. *Aliment Pharmacol Ther*, 18(5), 487-94.

Goldstein, J. L., Eisen, G. M., Lewis, B., Gralnek, I. M., Zlotnick, S., Fort, J. G. & Investigators (2005) Video capsule endoscopy to prospectively assess small bowel injury with celecoxib, naproxen plus omeprazole, and placebo. *Clin Gastroenterol Hepatol*, 3(2), 133-41.

Goldstein, N. S. (2004) Proximal small-bowel mucosal villous intraepithelial lymphocytes. *Histopathology*, 44(3), 199-205.



Goldstein, N. S. & Underhill, J. (2001) Morphologic features suggestive of gluten sensitivity in architecturally normal duodenal biopsy specimens. *Am J Clin Pathol*, 116(1), 63-71.

Gralnek, I. M., Defranchis, R., Seidman, E., Leighton, J. A., Legnani, P. & Lewis, B. S. (2008) Development of a capsule endoscopy scoring index for small bowel mucosal inflammatory change. *Aliment Pharmacol Ther*, 27(2), 146-54.

Green, P. H. (2008) Celiac disease: how many biopsies for diagnosis? *Gastrointestinal endoscopy*, 67(7), 1088-1090.

Green, P. H. & Cellier, C. (2007) Celiac disease. *N Engl J Med*, 357(17), 1731-43.

Halstensen, T. S., Scott, H., Fausa, O. & Brandtzaeg, P. (1993) Gluten stimulation of coeliac mucosa in vitro induces activation (CD25) of lamina propria CD4+ T cells and macrophages but no crypt-cell hyperplasia. *Scand J Immunol*, 38(6), 581-90.

Hankey GL & GKT, H. (1994) Coeliac disease in the elderly. *Gut*.

Hedsund, C., Gregersen, T., Joensson, I. M., Olesen, H. V. & Krogh, K. (2012) Gastrointestinal transit times and motility in patients with cystic fibrosis. *Scand J Gastroenterol*, 47(8-9), 920-6.

Hogberg, L., Falth-Magnusson, K., Grodzinsky, E. & Stenhammar, L. (2003) Familial prevalence of coeliac disease: a twenty-year follow-up study. *Scand J Gastroenterol*, 38(1), 61-5.

Hopman, W. P., Rosenbusch, G., Hectors, M. P. & Jansen, J. B. (1995) Effect of predigested fat on intestinal stimulation of plasma cholecystokinin and gall bladder motility in coeliac disease. *Gut*, 36(1), 17-21.

Hopper, A. D., Cross, S. S. & Sanders, D. S. (2008) Patchy villous atrophy in adult patients with suspected gluten-sensitive enteropathy: is a multiple duodenal biopsy strategy appropriate? *Endoscopy*, 40(3), 219-224.

Hopper, A. D., Sidhu, R., Hurlstone, D. P., McAlindon, M. E. & Sanders, D. S. (2007) Capsule endoscopy: an alternative to duodenal biopsy for the recognition of villous atrophy in coeliac disease? *Digestive and liver disease : official journal of the Italian Society of Gastroenterology and the Italian Association for the Study of the Liver*, 39(2), 140-145.

Howdle, P. & Losowsky, M. (1992) *Coeliac disease in adults.* , 49-80. In Marsh MN ed. *Coeliac Disease.*: Oxford: Blackwell Science.

Högberg, L., Grodzinsky, E. & Stenhammar, L. (2003) Better dietary compliance in patients with coeliac disease diagnosed in early childhood. *Scand J Gastroenterol*, 38(7), 751-4.

Ianiro, G., Gasbarrini, A. & Cammarota, G. (2013) Endoscopic tools for the diagnosis and evaluation of celiac disease. *World journal of gastroenterology*, 19(46), 8562-8570.

Iddan, G., Meron, G., Glukhovskiy, A. & Swain, P. (2000) Wireless capsule endoscopy. *Nature*, 405(6785), 35013140.

Ierardi, E., Amoruso, A., Giorgio, F., Principi, M., Losurdo, G., Piscitelli, D., Buffelli, F., Fiore, M. G., Mongelli, A., Castellaneta, N. M., Giangaspero, A., De Francesco, V., Montenegro, L. & Di Leo, A. (2015) Mucosal molecular pattern of tissue transglutaminase and interferon gamma in suspected seronegative celiac disease at marsh 1 and 0 stages. *Saudi J Gastroenterol*, 21(6), 379-85.

Ilus, T., Kaukinen, K., Virta, L. J., Huhtala, H., Mäki, M., Kurppa, K., Heikkinen, M., Heikura, M., Hirsi, E., Jantunen, K., Moilanen, V., Nielsen, C., Puhto, M., Pölkki, H., Vihriälä, I. & Collin, P. (2014) Refractory coeliac disease in a country with a high prevalence of clinically-diagnosed coeliac disease. *Aliment Pharmacol Ther*, 39(4), 418-25.

Imagawa, H., Oka, S., Tanaka, S., Noda, I., Higashiyama, M., Sanomura, Y., Shishido, T., Yoshida, S. & Chayama, K. (2011) Improved detectability of small-bowel lesions via capsule endoscopy with computed virtual chromoendoscopy: a pilot study. *Scand J Gastroenterol*, 46(9), 1133-7.

Iovino, P., Ciacci, C., Sabbatini, F., Acioli, D. M., D'Argenio, G. & Mazzacca, G. (1998) Esophageal impairment in adult celiac disease with steatorrhea. *Am J Gastroenterol*, 93(8), 1243-9.

Jabri, B. & Sollid, L. M. (2009) Tissue-mediated control of immunopathology in coeliac disease. *Nat Rev Immunol*, 9(12), 858-70.

Johnston, A. J., Kurien, M., Avgerinos, A., Mooney, P. D. & Sanders, D. S. *Is there a role for chromoendoscopy in the diagnosis of coeliac disease?* *J Gastrointest Liver Dis*. 2014 Mar;23(1):103-4.

Kalhan, S., Joseph, P., Sharma, S., Dubey, S., Dudani, S. & Dixit, M. (2011) Comparative study of histopathological Marsh grading with clinical and serological parameters in celiac iceberg of north India. *Indian J Pathol Microbiol*, 54(2), 279-83.

Karell, K., Louka, A. S., Moodie, S. J., Ascher, H., Clot, F., Greco, L., Ciclitira, P. J., Sollid, L. M. & Partanen, J. (2003) HLA types in celiac disease patients not carrying the DQA1\*05-DQB1\*02 (DQ2) heterodimer: results from the European Genetics Cluster on Celiac Disease. *Hum Immunol*, 64(4), 469-77.

Kastin, D. A., Buchman, A. L., Barrett, T., Halverson, A. & Wallin, A. (2004) Strictures from Crohn's disease diagnosed by video capsule endoscopy. *Journal of clinical gastroenterology*, 38(4), 346-349.

Kaur, J., Rana, S. V., Gupta, R., Gupta, V., Sharma, S. K. & Dhawan, D. K. (2014) Prolonged orocecal transit time enhances serum bile acids through bacterial overgrowth, contributing factor to gallstone disease. *J Clin Gastroenterol*, 48(4), 365-9.

Kobayashi, Y., Watabe, H., Yamada, A., Hirata, Y., Yamaji, Y., Yoshida, H. & Koike, K. (2012) Efficacy of flexible spectral imaging color enhancement on the detection of small intestinal diseases by capsule endoscopy. *J Dig Dis*, 13(12), 614-20.

Konishi, M., Shibuya, T., Mori, H., Kurashita, E., Takeda, T., Nomura, O., Fukuo, Y., Matsumoto, K., Sakamoto, N., Osada, T., Nagahara, A., Ogihara, T. & Watanabe, S. (2014) Usefulness of flexible spectral imaging color enhancement for the detection and

diagnosis of small intestinal lesions found by capsule endoscopy. *Scand J Gastroenterol*, 49(4), 501-5.

Kurien, M., Evans, K. E., Aziz, I., Sidhu, R., Drew, K., Rogers, T. L., McAlindon, M. E. & Sanders, D. S. (2013) Capsule endoscopy in adult celiac disease: a potential role in equivocal cases of celiac disease? *Gastrointestinal endoscopy*, 77(2), 227-232.

Lami, G., Galli, A., Macrì, G., Dabizzi, E., Biagini, M. R., Tarocchi, M., Messerini, L., Valanzano, R., Milani, S. & Polvani, S. (2017) Gastric and duodenal polyps in familial adenomatous polyposis patients: Conventional endoscopy. *World J Clin Oncol*, 8(2), 168-177.

Landis, J. R. & Koch, G. G. (1977) The measurement of observer agreement for categorical data. *Biometrics*, 33(1), 159-74.

Leeds, J. S., Höroldt, B. S., Sidhu, R., Hopper, A. D., Robinson, K., Toulson, B., Dixon, L., Lobo, A. J., McAlindon, M. E., Hurlstone, D. P. & Sanders, D. S. (2007) Is there an association between coeliac disease and inflammatory bowel diseases? A study of relative prevalence in comparison with population controls. *Scand J Gastroenterol*, 42(10), 1214-20.

Leffler, D. A., Dennis, M., Hyett, B., Kelly, E., Schuppan, D. & Kelly, C. P. (2007) Etiologies and predictors of diagnosis in nonresponsive celiac disease. *Clin Gastroenterol Hepatol*, 5(4), 445-50.

Leon, F. (2011) Flow cytometry of intestinal intraepithelial lymphocytes in celiac disease. *J Immunol Methods*, 363(2), 177-86.

Leonard, M. M., Weir, D. C., DeGroote, M., Mitchell, P. D., Singh, P., Silvester, J. A., Leichtner, A. M. & Fasano, A. (2017) Value of IgA tTG in Predicting Mucosal Recovery in Children With Celiac Disease on a Gluten-Free Diet. *J Pediatr Gastroenterol Nutr*, 64(2), 286-291.

Lidums, I., Cummins, A. G. & Teo, E. (2011a) The role of capsule endoscopy in suspected celiac disease patients with positive celiac serology. *Digestive diseases and sciences*, 56(2), 499-505.

Lidums, I., Teo, E., Field, J. & Cummins, A. G. (2011b) Capsule endoscopy: a valuable tool in the follow-up of people with celiac disease on a gluten-free diet. *Clinical and translational gastroenterology*, 2, e4.

Lionetti, P., Breese, E., Braegger, C. P., Murch, S. H., Taylor, J. & MacDonald, T. T. (1993) T-cell activation can induce either mucosal destruction or adaptation in cultured human fetal small intestine. *Gastroenterology*, 105(2), 373-81.

Liu, H., Brais, R., Lavergne-Slove, A., Jeng, Q., Payne, K., Ye, H., Liu, Z., Carreras, J., Huang, Y., Bacon, C. M., Hamoudi, R. A., Save, V., Venkatraman, L., Isaacson, P. G., Woodward, J. & Du, M. Q. (2010) Continual monitoring of intraepithelial lymphocyte immunophenotype and clonality is more important than snapshot analysis in the surveillance of refractory coeliac disease. *Gut*, 59(4), 452-60.

Lohi, S., Mustalahti, K., Kaukinen, K., Laurila, K., Collin, P., Rissanen, H., Lohi, O., Bravi, E., Gasparin, M., Reunanen, A. & Mäki, M. (2007) Increasing prevalence of coeliac disease over time. *Aliment Pharmacol Ther*, 26(9), 1217-25.

Losurdo, G., Marra, A., Shahini, E., Girardi, B., Giorgio, F., Amoruso, A., Pisani, A., Piscitelli, D., Barone, M., Principi, M., Di Leo, A. & Ierardi, E. (2017) Small intestinal bacterial overgrowth and celiac disease: A systematic review with pooled-data analysis. *Neurogastroenterol Motil*, 29(6).

Ludvigsson, J. F., Bai, J. C., Biagi, F., Card, T. R., Ciacci, C., Ciclitira, P. J., Green, P. H., Hadjivassiliou, M., Holdoway, A., van Heel, D. A., Kaukinen, K., Leffler, D. A., Leonard, J. N., Lundin, K. E., McGough, N., Davidson, M., Murray, J. A., Swift, G. L., Walker, M. M., Zingone, F., Sanders, D. S., Group, B. C. D. G. D. & Gastroenterology, B. S. o. (2014) Diagnosis and management of adult coeliac disease: guidelines from the British Society of Gastroenterology. *Gut*, 63(8), 1210-28.

Ludvigsson, J. F., Leffler, D. A., Bai, J. C., Biagi, F., Fasano, A., Green, P. H., Hadjivassiliou, M., Kaukinen, K., Kelly, C. P., Leonard, J. N., Lundin, K. E., Murray, J. A., Sanders, D. S., Walker, M. M., Zingone, F. & Ciacci, C. (2013) The Oslo definitions for coeliac disease and related terms. *Gut*, 62(1), 43-52.

Lujan-Sanchis, M., Perez-Cuadrado-Robles, E., Garcia-Lledo, J., Juanmartinena Fernandez, J. F., Elli, L., Jimenez-Garcia, V. A., Egea-Valenzuela, J., Valle-Munoz, J., Carretero-Ribon, C., Fernandez-Urien-Sainz, I., Lopez-Higueras, A., Alonso-Lazaro, N., Sanjuan-Acosta, M., Sanchez-Ceballos, F., Rosa, B., Gonzalez-Vazquez, S., Branchi, F., Ruano-Diaz, L., Prieto-de-Frias, C., Pons-Beltran, V., Borque-Barrera, P., Gonzalez-Suarez, B., Xavier, S., Arguelles-Arias, F., Herrerias-Gutierrez, J. M., Perez-Cuadrado-Martinez, E. & Sempere-Garcia-Arguelles, J. (2017) Role of capsule endoscopy in suspected celiac disease: A European multi-centre study. *World journal of gastroenterology*, 23(4), 703-711.

Lundin, K. E., Scott, H., Fausa, O., Thorsby, E. & Sollid, L. M. (1994) T cells from the small intestinal mucosa of a DR4, DQ7/DR4, DQ8 celiac disease patient preferentially recognize gliadin when presented by DQ8. *Hum Immunol*, 41(4), 285-91.

Lundin, K. E., Scott, H., Hansen, T., Paulsen, G., Halstensen, T. S., Fausa, O., Thorsby, E. & Sollid, L. M. (1993) Gliadin-specific, HLA-DQ(alpha 1\*0501,beta 1\*0201) restricted T cells isolated from the small intestinal mucosa of celiac disease patients. *J Exp Med*, 178(1), 187-96.

Maiden, L., Elliott, T., McLaughlin, S. D. & Ciclitira, P. (2009) A blinded pilot comparison of capsule endoscopy and small bowel histology in unresponsive celiac disease. *Digestive diseases and sciences*, 54(6), 1280-1283.

Majsiak, E., Cichoz-Lach, H., Gubska, O. & Cukrowska, B. (2018) [Celiac disease - disease of children and adults: symptoms, disease complications, risk groups and comorbidities]. *Pol Merkur Lekarski*, 44(259), 31-35.

Malamut, G., Afchain, P., Verkarre, V., Lecomte, T., Amiot, A., Damotte, D., Bouhnik, Y., Colombel, J. F., Delchier, J. C., Allez, M., Cosnes, J., Lavergne-Slove, A., Meresse, B., Trinquart, L., Macintyre, E., Radford-Weiss, I., Hermine, O., Brousse, N., Cerf-

Bensussan, N. & Cellier, C. (2009) Presentation and long-term follow-up of refractory celiac disease: comparison of type I with type II. *Gastroenterology*, 136(1), 81-90.

Malamut, G., Chandesris, O., Verkarre, V., Meresse, B., Callens, C., Macintyre, E., Bouhnik, Y., Gornet, J. M., Allez, M., Jian, R., Berger, A., Châtellier, G., Brousse, N., Hermine, O., Cerf-Bensussan, N. & Cellier, C. (2013) Enteropathy associated T cell lymphoma in celiac disease: a large retrospective study. *Dig Liver Dis*, 45(5), 377-84.

Marsh, M. N. & Crowe, P. T. (1995) Morphology of the mucosal lesion in gluten sensitivity. *Bailliere's Clinical Gastroenterology*, 9(2), 273-293.

Maurino, E., Capizzano, H., Niveloni, S., Kogan, Z., Valero, J., Boerr, L. & Bai, J. C. (1993) Value of endoscopic markers in celiac disease. *Digestive diseases and sciences*, 38(11), 2028-2033.

Maurino, E., Niveloni, S., Chernavsky, A., Pedreira, S., Mazure, R., Vazquez, H., Reyes, H., Fiorini, A., Smecuol, E., Cabanne, A., Capucchio, M., Kogan, Z. & Bai, J. C. (2002) Azathioprine in refractory sprue: results from a prospective, open-label study. *The American Journal of Gastroenterology*, 97(10), 2595-2602.

McIntyre, A. S., Ng, D. P., Smith, J. A., Amoah, J. & Long, R. G. (1992) The endoscopic appearance of duodenal folds is predictive of untreated adult celiac disease. *Gastrointestinal endoscopy*, 38(2), 148-151.

McNeish, A. S. & Sweet, E. M. (1968) Lactose intolerance in childhood coeliac disease. Assessment of its incidence and importance. *Arch Dis Child*, 43(230), 433-7.

Mearin, M. L., Biemond, I., Pena, A. S., Polanco, I., Vazquez, C., Schreuder, G. T., de Vries, R. R. & van Rood, J. J. (1983) HLA-DR phenotypes in Spanish coeliac children: their contribution to the understanding of the genetics of the disease. *Gut*, 24(6), 532-7.

Medtronic, M., USA (2018) *PillCam™ SB 3 System* | Medtronic, 2018. Available online: <http://www.medtronic.com/covidien/en-us/products/capsule-endoscopy/pillcam-sb-3-system.html> [Accessed].

Minami-Kobayashi, Y., Yamada, A., Watabe, H., Suzuki, H., Hirata, Y., Yamaji, Y., Yoshida, H. & Koike, K. (2016) Efficacy of repeat review with flexible spectral imaging color enhancement in patients with no findings by capsule endoscopy. *Saudi J Gastroenterol*, 22(5), 385-390.

Molberg, O., McAdam, S. N., Korner, R., Quarsten, H., Kristiansen, C., Madsen, L., Fugger, L., Scott, H., Noren, O., Roepstorff, P., Lundin, K. E., Sjostrom, H. & Sollid, L. M. (1998) Tissue transglutaminase selectively modifies gliadin peptides that are recognized by gut-derived T cells in celiac disease. *Nat Med*, 4(6), 713-7.

Monteiro, S., Barbosa, M., Cúrdia Gonçalves, T., Boal Carvalho, P., Moreira, M. J., Rosa, B. & Cotter, J. (2018) Fecal Calprotectin as a Selection Tool for Small Bowel Capsule Endoscopy in Suspected Crohn's Disease. *Inflamm Bowel Dis*.

Mooney, P. D., Evans, K. E., Singh, S. & Sanders, D. S. (2012) Treatment failure in coeliac disease: a practical guide to investigation and treatment of non-responsive and

refractory coeliac disease. *Journal of gastrointestinal and liver diseases : JGLD*, 21(2), 197-203.

Mooney, P. D., Kurien, M., Evans, K. E., Rosario, E., Cross, S. S., Vergani, P., Hadjivassiliou, M., Murray, J. A. & Sanders, D. S. (2016) Clinical and Immunologic Features of Ultra-Short Celiac Disease. *Gastroenterology*, 150(5), 1125-1134.

Muhammad, A. & Pitchumoni, C. S. (2008) Newly detected celiac disease by wireless capsule endoscopy in older adults with iron deficiency anemia. *J Clin Gastroenterol*, 42(9), 980-3.

Mukewar, S. S., Sharma, A., Rubio-Tapia, A., Wu, T. T., Jabri, B. & Murray, J. A. (2017) Open-Capsule Budesonide for Refractory Celiac Disease. *The American Journal of Gastroenterology*, 112(6), 959-967.

Murray, J. A., Rubio-Tapia, A., Van Dyke, C. T., Brogan, D. L., Knipschild, M. A., Lahr, B., Rumalla, A., Zinsmeister, A. R. & Gostout, C. J. (2008) Mucosal atrophy in celiac disease: extent of involvement, correlation with clinical presentation, and response to treatment. *Clin Gastroenterol Hepatol*, 6(2), 186-93; quiz 125.

Nakamura, M., Ohmiya, N., Miyahara, R., Ando, T., Watanabe, O., Kawashima, H., Itoh, A., Hirooka, Y. & Goto, H. (2012) Usefulness of flexible spectral imaging color enhancement (FICE) for the detection of angiodysplasia in the preview of capsule endoscopy. *Hepatology*, 59(117), 1474-7.

Nasr, I., Beyers, C., Chang, F., Donnelly, S. & Ciclitira, P. J. (2015) Recognising and Managing Refractory Coeliac Disease: A Tertiary Centre Experience. *Nutrients*, 7(12), 9896-907.

Nasr, I., Campling, H. & Ciclitira, P. J. (1000) Approach to patients with refractory coeliac disease. *F1000Res*, 20(5).

Nijeboer, P., van Wanrooij, R. L., Tack, G. J., Mulder, C. J. & Bouma, G. (2013) Update on the diagnosis and management of refractory coeliac disease. *Gastroenterol Res Pract*, 2013, 518483.

Niveloni, S., Fiorini, A., Dezi, R., Pedreira, S., Smecuol, E., Vazquez, H., Cabanne, A., Boerr, L. A., Valero, J., Kogan, Z., Maurino, E. & Bai, J. C. (1998) Usefulness of videoduodenoscopy and vital dye staining as indicators of mucosal atrophy of celiac disease: assessment of interobserver agreement. *Gastrointestinal endoscopy*, 47(3), 223-229.

Nogales Rincón, O., Merino Rodríguez, B., González Asanza, C. & Fernández-Pacheco, P. M. (2013) [Utility of capsule endoscopy with flexible spectral imaging color enhancement in the diagnosis of small bowel lesions]. *Gastroenterol Hepatol*, 36(2), 63-8.

O'Grady, J. G., Stevens, F. M., Keane, R., Cryan, E. M., Egan-Mitchell, B., McNicholl, B., McCarthy, C. F. & Fottrell, P. F. (1984) Intestinal lactase, sucrase, and alkaline phosphatase in 373 patients with coeliac disease. *J Clin Pathol*, 37(3), 298-301.

O'Mahony, S., Howdle, P. D. & Losowsky, M. S. (1996) Review article: management of patients with non-responsive coeliac disease. *Aliment Pharmacol Ther*, 10(5), 671-80.

- Oberhuber, G., Granditsch, G. & Vogelsang, H. (1999) The histopathology of coeliac disease: time for a standardized report scheme for pathologists. *Eur J Gastroenterol Hepatol*, 11(10), 1185-94.
- Olds, G., McLoughlin, R., O'Morian, C. & Sivak, M. V., Jr. (2002) Celiac disease for the endoscopist. *Gastrointestinal endoscopy*, 56(3), 407-415.
- Ou, G., Shahidi, N., Galorport, C., Takach, O., Lee, T. & Enns, R. (2015) Effect of longer battery life on small bowel capsule endoscopy. *World J Gastroenterol*, 21(9), 2677-82.
- Oxentenko, A. S., Grisolano, S. W., Murray, J. A., Burgart, L. J., Dierkhising, R. A. & Alexander, J. A. (2002) The insensitivity of endoscopic markers in celiac disease. *The American Journal of Gastroenterology*, 97(4), 933-938.
- Pais, W. P., Duerksen, D. R., Pettigrew, N. M. & Bernstein, C. N. (2008) How many duodenal biopsy specimens are required to make a diagnosis of celiac disease? *Gastrointestinal endoscopy*, 67(7), 1082-1087.
- Pallav, K., Leffler, D. A., Tariq, S., Kabbani, T., Hansen, J., Peer, A., Bhansali, A., Najarian, R. & Kelly, C. P. (2012) Noncoeliac enteropathy: the differential diagnosis of villous atrophy in contemporary clinical practice. *Aliment Pharmacol Ther*, 35(3), 380-90.
- Parihar, V., Stack, R., Alakkari, A., Breslin, N., Ryan, B. M., Crowther, S. & McNamara, D. (2017) Clinical Outcome of Patients with Raised Intraepithelial Lymphocytes with Normal Villous Architecture on Duodenal Biopsy. *Digestion*, 95(4), 288-292.
- Patey-Mariaud De Serre, N., Cellier, C., Jabri, B., Delabesse, E., Verkarre, V., Roche, B., Lavergne, A., Briere, J., Mauvieux, L., Leborgne, M., Barbier, J. P., Modigliani, R., Matuchansky, C., MacIntyre, E., Cerf-Bensussan, N. & Brousse, N. (2000) Distinction between coeliac disease and refractory sprue: a simple immunohistochemical method. *Histopathology*, 37(1), 70-7.
- Pender, S. L., Tickle, S. P., Docherty, A. J., Howie, D., Wathen, N. C. & MacDonald, T. T. (1997) A major role for matrix metalloproteinases in T cell injury in the gut. *J Immunol*, 158(4), 1582-90.
- Pennazio, M., Spada, C., Eliakim, R., Keuchel, M., May, A., Mulder, C. J., Rondonotti, E., Adler, S. N., Albert, J., Baltés, P., Barbaro, F., Cellier, C., Charton, J. P., Delvaux, M., Despott, E. J., Domagk, D., Klein, A., McAlindon, M., Rosa, B., Rowse, G., Sanders, D. S., Saurin, J. C., Sidhu, R., Dumonceau, J. M., Hassan, C. & Gralnek, I. M. (2015) Small-bowel capsule endoscopy and device-assisted enteroscopy for diagnosis and treatment of small-bowel disorders: European Society of Gastrointestinal Endoscopy (ESGE) Clinical Guideline. *Endoscopy*, 47(4), 352-376.
- Perez-Cuadrado-Robles, E., Lujan-Sanchis, M., Elli, L., Juanmartinena-Fernandez, J. F., Garcia-Lledo, J., Ruano-Diaz, L., Egea-Valenzuela, J., Jimenez-Garcia, V. A., Arguelles-Arias, F., Juan-Acosta, M. S., Carretero-Ribon, C., Alonso-Lazaro, N., Rosa, B., Sanchez-Ceballos, F., Lopez-Higueras, A., Fernandez-Urien-Sainz, I., Branchi, F., Valle-Muñoz, J., Borque-Barrera, P., Gonzalez-Vazquez, S., Pons-Beltran, V., Xavier, S., Gonzalez-Suarez, B., Herrerias-Gutierrez, J. M., Perez-Cuadrado-Martinez, E., Sempere-

Garcia-Arguelles, J. & (SEED), E. a. C. E. S. S. G. o. t. S. S. o. D. E. (2018) Role of capsule endoscopy in alarm features and non-responsive celiac disease: A European multicenter study. *Dig Endosc*, 30(4), 461-466.

Petroniene, R., Dubcenco, E., Baker, J. P., Ottaway, C. A., Tang, S. J., Zanati, S. A., Streutker, C. J., Gardiner, G. W., Warren, R. E. & Jeejeebhoy, K. N. (2005) Given capsule endoscopy in celiac disease: evaluation of diagnostic accuracy and interobserver agreement. *Am J Gastroenterol*, 100(3), 685-94.

Pezzoli, A., Cannizzaro, R., Pennazio, M., Rondonotti, E., Zancanella, L., Fusetti, N., Simoni, M., Cantoni, F., Melina, R., Alberani, A., Caravelli, G., Villa, F., Chilovi, F., Casetti, T., Iaquinto, G., D'imperio, N. & Gullini, S. (2011) Interobserver agreement in describing video capsule endoscopy findings: a multicentre prospective study. *Dig Liver Dis*, 43(2), 126-31.

Peña, A. S., Truelove, S. C. & Whitehead, R. (1972) Disaccharidase activity and jejunal morphology in coeliac disease. *Q J Med*, 41(164), 457-76.

Pietzak, M. M. (2005) Follow-up of patients with celiac disease: achieving compliance with treatment. *Gastroenterology*, 128(4 Suppl 1), S135-41.

PLOTKIN, G. R. & ISSELBACHER, K. J. (1964) SECONDARY DISACCHARIDASE DEFICIENCY IN ADULT CELIAC DISEASE (NONTROPICAL SPRUE) AND OTHER MALABSORPTION STATES. *N Engl J Med*, 271, 1033-7.

Pohl, J., Aschmoneit, I., Schuhmann, S. & Ell, C. (2010) Computed image modification for enhancement of small-bowel surface structures at video capsule endoscopy. *Endoscopy*, 42(6), 490-2.

Pohl, J., May, A., Rabenstein, T., Pech, O. & Ell, C. (2007) Computed virtual chromoendoscopy: a new tool for enhancing tissue surface structures. *Endoscopy*, 39(1), 80-3.

Prisco, A., Troncone, R., Mazzarella, G., Gianfrani, C., Auricchio, S., Even, J., Tiberio, C., Guardiola, J. & De Berardinis, P. (1997) Identical T-cell receptor beta chain rearrangements are present in T cells infiltrating the jejunal mucosa of untreated celiac patients. *Hum Immunol*, 55(1), 22-33.

Rahman, M., Akerman, S., DeVito, B., Miller, L., Akerman, M. & Sultan, K. (2015) Comparison of the diagnostic yield and outcomes between standard 8 h capsule endoscopy and the new 12 h capsule endoscopy for investigating small bowel pathology. *World J Gastroenterol*, 21(18), 5542-7.

Ravelli, A., Bolognini, S., Gambarotti, M. & Villanacci, V. (2005) Variability of histologic lesions in relation to biopsy site in gluten-sensitive enteropathy. *The American Journal of Gastroenterology*, 100(1), 177-185.

Ravelli, A., Villanacci, V., Monfredini, C., Martinazzi, S., Grassi, V. & Manenti, S. (2010) How patchy is patchy villous atrophy?: distribution pattern of histological lesions in the duodenum of children with celiac disease. *The American Journal of Gastroenterology*, 105(9), 2103-2110.



- Rimbaş, M., Negreanu, L., Ciobanu, L., Benguş, A., Spada, C., Băicuş, C. R. & Costamagna, G. (2015) Is virtual chromoendoscopy useful in the evaluation of subtle ulcerative small-bowel lesions detected by video capsule endoscopy? *Endosc Int Open*, 3(6), E615-20.
- Rocco, A., Sarnelli, G., Compare, D., de Colibus, P., Micheli, P., Somma, P., Marotti, B., Cuomo, R. & Nardone, G. (2008) Tissue ghrelin level and gastric emptying rate in adult patients with celiac disease. *Neurogastroenterology and motility : the official journal of the European Gastrointestinal Motility Society*, 20(8), 884-890.
- Rokkas, T. & Niv, Y. (2012) The role of video capsule endoscopy in the diagnosis of celiac disease: a meta-analysis. *European journal of gastroenterology & hepatology*, 24(3), 303-308.
- Roncoroni, L., Elli, L., Doneda, L., Bascuñán, K. A., Vecchi, M., Morreale, F., Scricciolo, A., Lombardo, V. & Pellegrini, N. (2018) A Retrospective Study on Dietary FODMAP Intake in Celiac Patients Following a Gluten-Free Diet. *Nutrients*, 10(11).
- Rondonotti, E., Spada, C., Adler, S., May, A., Despott, E. J., Koulaouzidis, A., Panter, S., Domagk, D., Fernandez-Urien, I., Rahmi, G., Riccioni, M. E., van Hooft, J. E., Hassan, C. & Pennazio, M. (2018) Small-bowel capsule endoscopy and device-assisted enteroscopy for diagnosis and treatment of small-bowel disorders: European Society of Gastrointestinal Endoscopy (ESGE) Technical Review. *Endoscopy*, 50(4), 423-446.
- Rondonotti, E., Spada, C., Cave, D., Pennazio, M., Riccioni, M. E., De Vitis, I., Schneider, D., Sprujevnik, T., Villa, F., Langelier, J., Arrigoni, A., Costamagna, G. & Franchis, R. (2007) Video capsule enteroscopy in the diagnosis of celiac disease: a multicenter study. *Am J Gastroenterol*, 102(8), 1624-31.
- Ropert, A., Cherbut, C., Rozé, C., Le Quellec, A., Holst, J. J., Fu-Cheng, X., Bruley des Varannes, S. & Galmiche, J. P. (1996) Colonic fermentation and proximal gastric tone in humans. *Gastroenterology*, 111(2), 289-96.
- Rosa, B., Moreira, M. J., Rebelo, A. & Cotter, J. (2012) Lewis Score: a useful clinical tool for patients with suspected Crohn's Disease submitted to capsule endoscopy. *J Crohns Colitis*, 6(6), 692-7.
- Rostom, A., Murray, J. A. & Kagnoff, M. F. (2006) American Gastroenterological Association (AGA) Institute technical review on the diagnosis and management of celiac disease. *Gastroenterology*, 131(6), 1981-2002.
- Rowinski, S. A. & Christensen, E. (2016) Epidemiologic and therapeutic aspects of refractory coeliac disease - a systematic review. *Danish medical journal*, 63(12), A5307.
- Rubio-Tapia, A., Hill, I. D., Kelly, C. P., Calderwood, A. H. & Murray, J. A. *American College of Gastroenterology Clinical Guideline: Diagnosis and Management of Celiac Disease* *Am J Gastroenterol*. 2013 May;108(5):656-77. Epub 2013 Apr 23 doi:10.1038/ajg.2013.79.
- Rubio-Tapia, A., Hill, I. D., Kelly, C. P., Calderwood, A. H., Murray, J. A. & American College of, G. (2013) ACG clinical guidelines: diagnosis and management of celiac disease. *The American Journal of Gastroenterology*, 108(5), 656-76; quiz 677.

- Rubio-Tapia, A., Kelly, D. G., Lahr, B. D., Dogan, A., Wu, T. T. & Murray, J. A. (2009) Clinical staging and survival in refractory celiac disease: a single center experience. *Gastroenterology*, 136(1), 99-107; quiz 352-3.
- Sadik, R., Abrahamsson, H., Kilander, A. & Stotzer, P. O. (2004) Gut transit in celiac disease: delay of small bowel transit and acceleration after dietary treatment. *The American Journal of Gastroenterology*, 99(12), 2429-2436.
- Sakai, E., Endo, H., Kato, S., Matsuura, T., Tomeno, W., Taniguchi, L., Uchiyama, T., Hata, Y., Yamada, E., Ohkubo, H., Higrashi, T., Hosono, K., Takahashi, H. & Nakajima, A. (2012) Capsule endoscopy with flexible spectral imaging color enhancement reduces the bile pigment effect and improves the detectability of small bowel lesions. *BMC Gastroenterol*, 12, 83.
- Salmi, T. T., Collin, P., Korponay-Szabó, I. R., Laurila, K., Partanen, J., Huhtala, H., Király, R., Lorand, L., Reunala, T., Mäki, M. & Kaukinen, K. (2006) Endomysial antibody-negative coeliac disease: clinical characteristics and intestinal autoantibody deposits. *Gut*, 55(12), 1746-53.
- Sasamura, H., Nakamoto, H., Ryuzaki, M., Kumagai, K., Abe, S., Suzuki, H., Hirakata, M., Tojo, T., Handa, M. & Yamamoto, M. (1991) Repeated intestinal ulcerations in a patient with systemic lupus erythematosus and high serum antiphospholipid antibody levels. *South Med J*, 84(4), 515-7.
- Sato, Y., Sagawa, T., Hirakawa, M., Ohnuma, H., Osuga, T., Okagawa, Y., Tamura, F., Horiguchi, H., Takada, K., Hayashi, T., Sato, T., Miyanishi, K., Takimoto, R., Kobune, M. & Kato, J. (2014) Clinical utility of capsule endoscopy with flexible spectral imaging color enhancement for diagnosis of small bowel lesions. *Endosc Int Open*, 2(2), E80-7.
- Scapa, E., Jacob, H., Lewkowicz, S., Migdal, M., Gat, D., Gluckhovski, A., Gutmann, N. & Fireman, Z. (2002) Initial experience of wireless-capsule endoscopy for evaluating occult gastrointestinal bleeding and suspected small bowel pathology. *Am J Gastroenterol*, 97(11), 2776-9.
- Schiepatti, A., Biagi, F., Fraternali, G., Vattiato, C., Balduzzi, D., Agazzi, S., Alpini, C., Klersy, C. & Corazza, G. R. (2017) Short article: Mortality and differential diagnoses of villous atrophy without coeliac antibodies. *Eur J Gastroenterol Hepatol*, 29(5), 572-576.
- Schmidt, C., Kasim, E., Schlake, W., Gerken, G., Giese, T. & Stallmach, A. (2009) TNF-alpha antibody treatment in refractory collagenous sprue: report of a case and review of the literature. *Z Gastroenterol*, 47(6), 575-8.
- Sekra, A., Schauer, C., Mills, L., Vandal, A. C., Rose, T., Lal, D. & Ogra, R. (2018) Chromoendoscopy versus standard colonoscopy for detection of nonpolypoid dysplasia in patients with inflammatory bowel disease. *N Z Med J*, 131(1478), 32-38.
- Selleski, N., Almeida, L. M., Almeida, F. C., Pratesi, C. B., Nobrega, Y. K. M. & Gandolfi, L. (2018) Prevalence of Celiac Disease Predisposing Genotypes, Including Hla-Dq2.2 Variant, in Brazilian Children. *Arq Gastroenterol*, 55(1), 82-85.

- Shmidt, E., Smyrk, T. C., Boswell, C. L., Enders, F. T. & Oxentenko, A. S. (2014) Increasing duodenal intraepithelial lymphocytosis found at upper endoscopy: time trends and associations. *Gastrointest Endosc*, 80(1), 105-11.
- Shmidt, E., Smyrk, T. C., Faubion, W. A. & Oxentenko, A. S. (2013) Duodenal intraepithelial lymphocytosis with normal villous architecture in pediatric patients: Mayo Clinic experience, 2000-2009. *J Pediatr Gastroenterol Nutr*, 56(1), 51-5.
- Silvester, J. A., Kurada, S., Szwajcer, A., Kelly, C. P., Leffler, D. A. & Duerksen, D. R. (2017) Tests for Serum Transglutaminase and Endomysial Antibodies Do Not Detect Most Patients With Celiac Disease and Persistent Villous Atrophy on Gluten-free Diets: a Meta-analysis. *Gastroenterology*, 153(3), 689-701.e1.
- Singh, P., Kurray, L., Agnihotri, A., Das, P., Verma, A. K., Sreenivas, V., Dattagupta, S. & Makharia, G. K. (2015) Titers of anti-tissue transglutaminase antibody correlate well with severity of villous abnormalities in celiac disease. *J Clin Gastroenterol*, 49(3), 212-7.
- Sjölund, K., Alumets, J., Berg, N. O., Håkanson, R. & Sundler, F. (1979) Duodenal endocrine cells in adult coeliac disease. *Gut*, 20(7), 547-52.
- Swinson, C. M., Slavin, G., Coles, E. C. & Booth, C. C. (1983) Coeliac disease and malignancy. *Lancet*, 1(8316), 111-5.
- Tack, G. J., Verbeek, W. H., Al-Toma, A., Kuik, D. J., Schreurs, M. W., Visser, O. & Mulder, C. J. (2011a) Evaluation of Cladribine treatment in refractory celiac disease type II. *World J Gastroenterol*, 17(4), 506-13.
- Tack, G. J., Wondergem, M. J., Al-Toma, A., Verbeek, W. H., Schmittl, A., Machado, M. V., Perri, F., Ossenkoppele, G. J., Huijgens, P. C., Schreurs, M. W., Mulder, C. J. & Visser, O. J. (2011b) Auto-SCT in refractory celiac disease type II patients unresponsive to cladribine therapy. *Bone Marrow Transplant*, 46(6), 840-6.
- Testa, A., Imperatore, N., Rispo, A., Rea, M., Tortora, R., Nardone, O. M., Lucci, L., Accarino, G., Caporaso, N. & Castiglione, F. (2018) Beyond Irritable Bowel Syndrome: The Efficacy of the Low Fodmap Diet for Improving Symptoms in Inflammatory Bowel Diseases and Celiac Disease. *Dig Dis*, 36(4), 271-280.
- Togashi, K., Osawa, H., Koinuma, K., Hayashi, Y., Miyata, T., Sunada, K., Nokubi, M., Horie, H. & Yamamoto, H. (2009) A comparison of conventional endoscopy, chromoendoscopy, and the optimal-band imaging system for the differentiation of neoplastic and non-neoplastic colonic polyps. *Gastrointest Endosc*, 69(3 Pt 2), 734-41.
- Tomba, C., Sidhu, R., Sanders, D. S., Mooney, P. D., Branchi, F., Locatelli, M., Roncoroni, L., Conte, D., Bardella, M. T. & Elli, L. (2016) Celiac Disease and Double-Balloon Enteroscopy: What Can We Achieve?: The Experience of 2 European Tertiary Referral Centers. *J Clin Gastroenterol*, 50(4), 313-7.
- Tortora, R., Capone, P., Imperatore, N., De Stefano, G., Gerbino, N., Leo, M., Caporaso, N. & Rispo, A. (2014) Predictive value of "Marsh 1" type histology in subjects with suspected cealic disease. *Scand J Gastroenterol*, 49(7), 801-6.

Tursi, A. (2004) Gastrointestinal motility disturbances in celiac disease. *Journal of clinical gastroenterology*, 38(8), 642-645.

Tursi, A., Brandimarte, G., Giorgetti, G. M. & Gigliobianco, A. (2002) Endoscopic features of celiac disease in adults and their correlation with age, histological damage, and clinical form of the disease. *Endoscopy*, 34(10), 787-792.

Ubiali, A., Villanacci, V., Facchetti, F., Lanzini, A., Lanzarotto, F., Rindi, G. & Bassotti, G. (2007) Is TCRgamma clonality assay useful to detect early celiac disease? *J Clin Gastroenterol*, 41(3), 275-9.

Urgesi, R., Cianci, R., Bizzotto, A., Costamagna, G. & Riccioni, M. E. (2013) Evaluation of gastric and small bowel transit times in coeliac disease with the small bowel PillCam(R): a single centre study in a non gluten-free diet adult Italian population with coeliac disease. *European review for medical and pharmacological sciences*, 17(9), 1167-1173.

Usai, P., Bassotti, G., Usai Satta, P., Cherchi, M., Plesa, A., Boy, F., Morelli, A. & Balestrieri, A. (1995) Oesophageal motility in adult coeliac disease. *Neurogastroenterology and motility : the official journal of the European Gastrointestinal Motility Society*, 7(4), 239-244.

Usai-Satta, P., Oppia, F., Scarpa, M., Giannetti, C. & Cabras, F. (2016) Delayed gastric emptying does not normalize after gluten withdrawal in adult celiac disease. *Scand J Gastroenterol*, 51(8), 923-6.

van de Wal, Y., Kooy, Y., van Veelen, P., Pena, S., Mearin, L., Papadopoulos, G. & Koning, F. (1998) Selective deamidation by tissue transglutaminase strongly enhances gliadin-specific T cell reactivity. *J Immunol*, 161(4), 1585-8.

van de Wal, Y., Kooy, Y. M., van Veelen, P., Vader, W., August, S. A., Drijfhout, J. W., Pena, S. A. & Koning, F. (1999) Glutenin is involved in the gluten-driven mucosal T cell response. *Eur J Immunol*, 29(10), 3133-9.

van Heel, D. A. & West, J. (2006) Recent advances in coeliac disease. *Gut*, 55(7), 1037-46.

Verbeek, W. H., Goerres, M. S., von Blomberg, B. M., Oudejans, J. J., Scholten, P. E., Hadithi, M., Al-Toma, A., Schreurs, M. W. & Mulder, C. J. (2008) Flow cytometric determination of aberrant intra-epithelial lymphocytes predicts T-cell lymphoma development more accurately than T-cell clonality analysis in Refractory Celiac Disease. *Clin Immunol*, 126(1), 48-56.

Verdu, E. F., Huang, X., Natividad, J., Lu, J., Blennerhassett, P. A., David, C. S., McKay, D. M. & Murray, J. A. (2008) Gliadin-dependent neuromuscular and epithelial secretory responses in gluten-sensitive HLA-DQ8 transgenic mice. *American journal of physiology. Gastrointestinal and liver physiology*, 294(1), G217-25.

Veress, B., Franzén, L., Bodin, L. & Borch, K. (2004) Duodenal intraepithelial lymphocyte-count revisited. *Scand J Gastroenterol*, 39(2), 138-44.

Vigren, L., Tysk, C., Ström, M., Kilander, A. F., Hjortswang, H., Bohr, J., Benoni, C., Larson, L. & Sjöberg, K. (2013) Celiac disease and other autoimmune diseases in patients with collagenous colitis. *Scand J Gastroenterol*, 48(8), 944-50.

Vilppula, A., Collin, P., Mäki, M., Valve, R., Luostarinen, M., Krekelä, I., Patrikainen, H., Kaukinen, K. & Luostarinen, L. (2008) Undetected coeliac disease in the elderly: a biopsy-proven population-based study. *Dig Liver Dis*, 40(10), 809-13.

Wahab, P. J., Crusius, J. B., Meijer, J. W., Uil, J. J. & Mulder, C. J. (2000) Cyclosporin in the treatment of adults with refractory coeliac disease--an open pilot study. *Aliment Pharmacol Ther*, 14(6), 767-74.

Wahab, P. J., Meijer, J. W. & Mulder, C. J. (2002) Histologic follow-up of people with celiac disease on a gluten-free diet: slow and incomplete recovery. *Am J Clin Pathol*, 118(3), 459-63.

West, J. (2009) Celiac disease and its complications: a time traveller's perspective. *Gastroenterology*, 136(1), 32-4.

Westerhof, J., Weersma, R. K. & Koornstra, J. J. (2009) Risk factors for incomplete small-bowel capsule endoscopy. *Gastrointestinal endoscopy*, 69(1), 74-80.

Woodward, J. (2016) Improving outcomes of refractory celiac disease - current and emerging treatment strategies. *Clin Exp Gastroenterol*, 9, 225-36.

Yung, D. E., Boal Carvalho, P., Giannakou, A., Kopylov, U., Rosa, B., Rondonotti, E., Toth, E., Plevris, J. N. & Koulaouzidis, A. (2017) Clinical validity of flexible spectral imaging color enhancement (FICE) in small-bowel capsule endoscopy: a systematic review and meta-analysis. *Endoscopy*, 49(3), 258-269.

Zhou, T., Han, G., Li, B. N., Lin, Z., Ciaccio, E. J., Green, P. H. & Qin, J. (2017) Quantitative analysis of patients with celiac disease by video capsule endoscopy: A deep learning method. *Comput Biol Med*, 85, 1-6.

Zwinger, L. L., Siegmund, B., Stroux, A., Adler, A., Veltzke-Schlieker, W., Wentrup, R., Jürgensen, C., Wiedenmann, B., Wiedbrauck, F., Hollerbach, S., Liceni, T. & Bojarski, C. (2018) CapsoCam SV-1 Versus PillCam SB 3 in the Detection of Obscure Gastrointestinal Bleeding: Results of a Prospective Randomized Comparative Multicenter Study. *J Clin Gastroenterol*.