

THE STRUCTURE AND BEHAVIOUR OF THE
CERCARIA OF SCHISTOSOMA MANSONI

VOLUME 2 (2 Vols.)

CHRISTOPHER JOHN NUTTMAN

Thesis submitted for the degree of DPhil

Biology Department
University of York

July 1975



IMAGING SERVICES NORTH

Boston Spa, Wetherby

West Yorkshire, LS23 7BQ

www.bl.uk

TEXT BOUND CLOSE TO THE SPINE IN THE ORIGINAL THESIS

TABLE OF CONTENTS

VOLUME 2

	<u>Page</u>
SECTION 1.3 BODY MUSCULATURE FIGURES	1
1.4 CAUDAL MUSCULATURE FIGURES	25
1.5 NERVOUS SYSTEM FIGURES	54

Fig. 1. Transverse section (TS) of the posterior body to show general layout of body wall and internal tissue. X4000

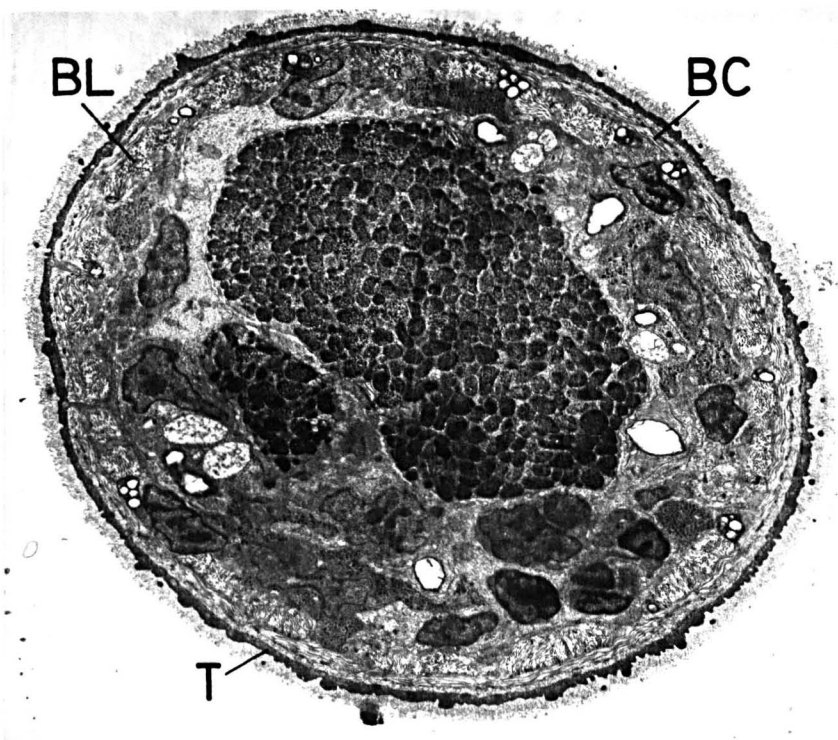


Fig. 2. A montage to show the section in Fig. 1 at higher magnification.

X12000

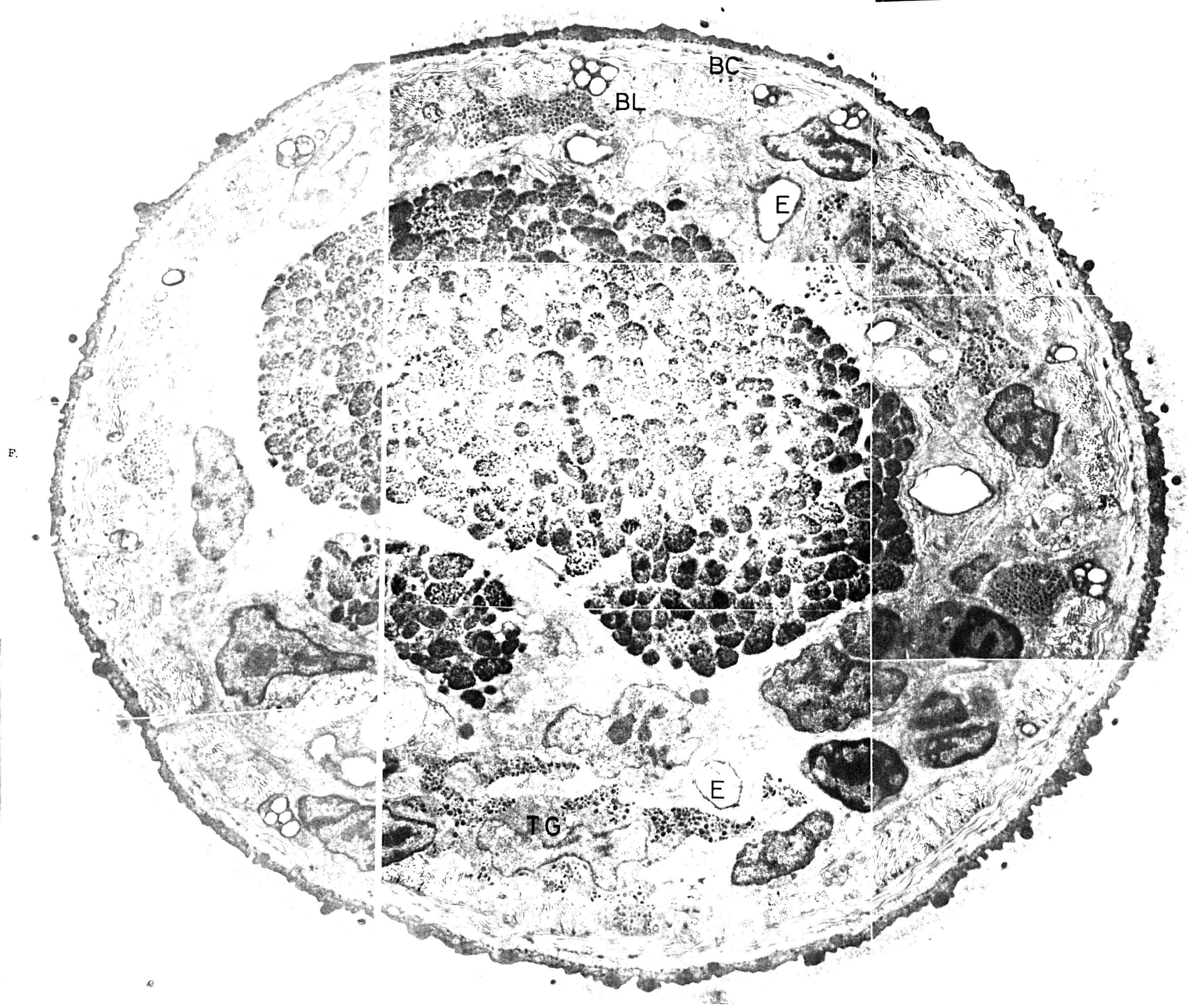


Fig. 3. TS body wall muscle. Cytoplasmic continuity shown between the circular contractile region and the underlying sarcoplasmic region. Note very sparse sarcoplasmic reticulum of circular fibre. X34000

Fig. 4. LS body wall muscle. Sarcoplasmic reticulum of circular fibres more readily observed. Desmosomes join sarcolemmas of adjacent myofibres. X25400.

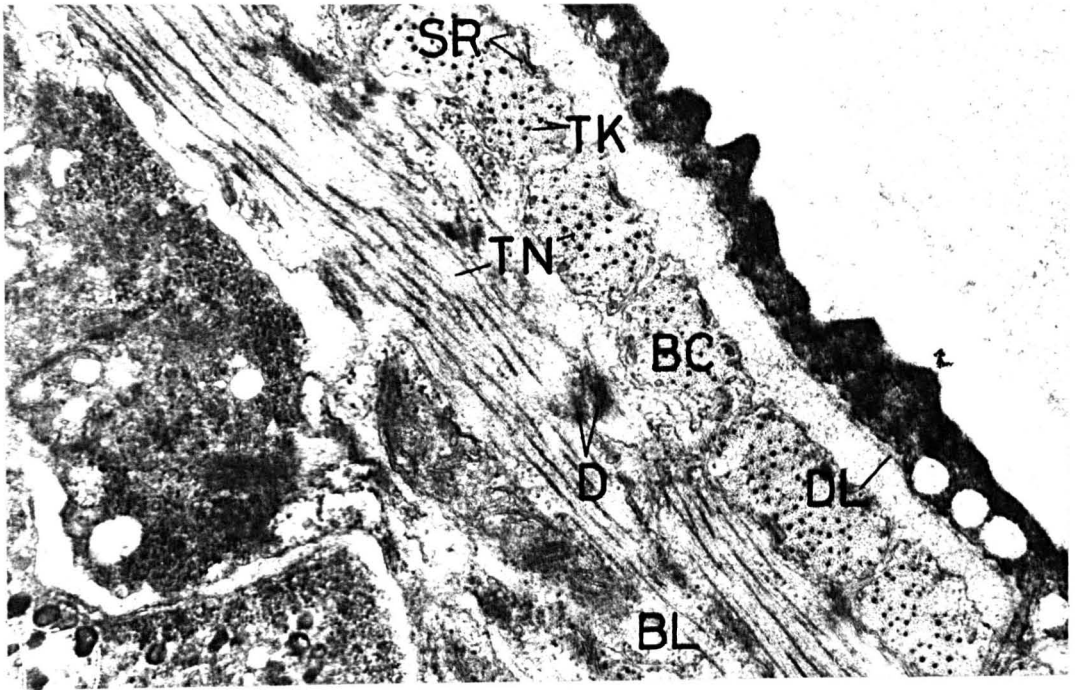
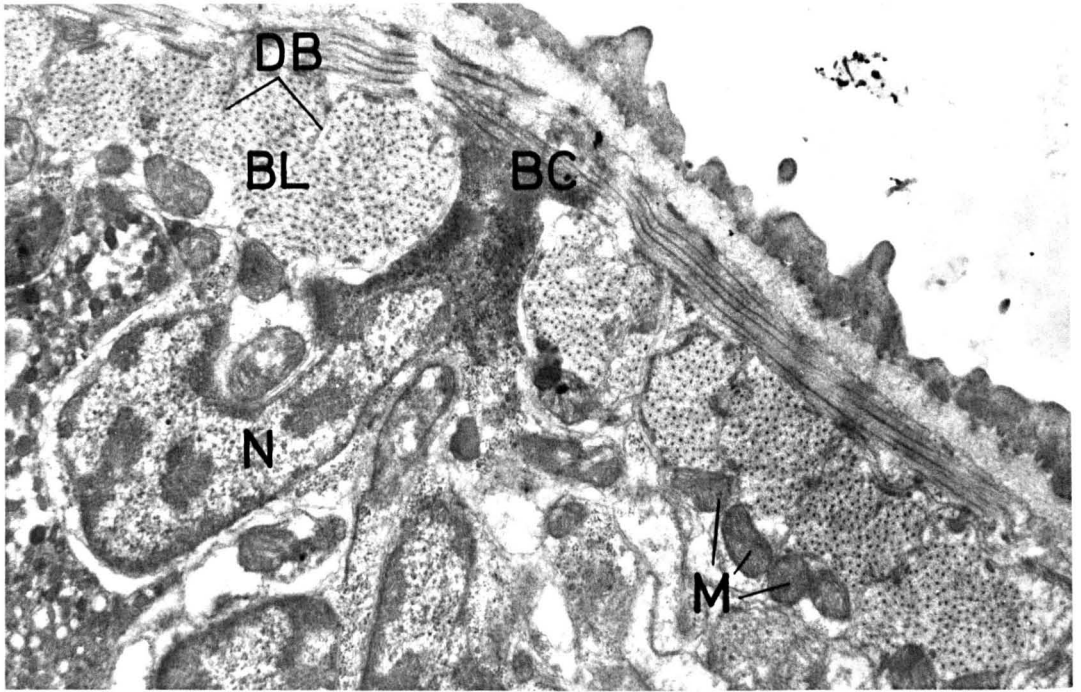


Fig. 5. TS body. Nucleus of longitudinal myofibre contains clumped distribution of chromatin and also groups of small, dense particles. Note cytoplasmic channel to circular fibre and dense line across filaments of longitudinal fibre. x32000

Fig.6. TS body. Nucleus of circular myofibre contains some dense particles. x38000.

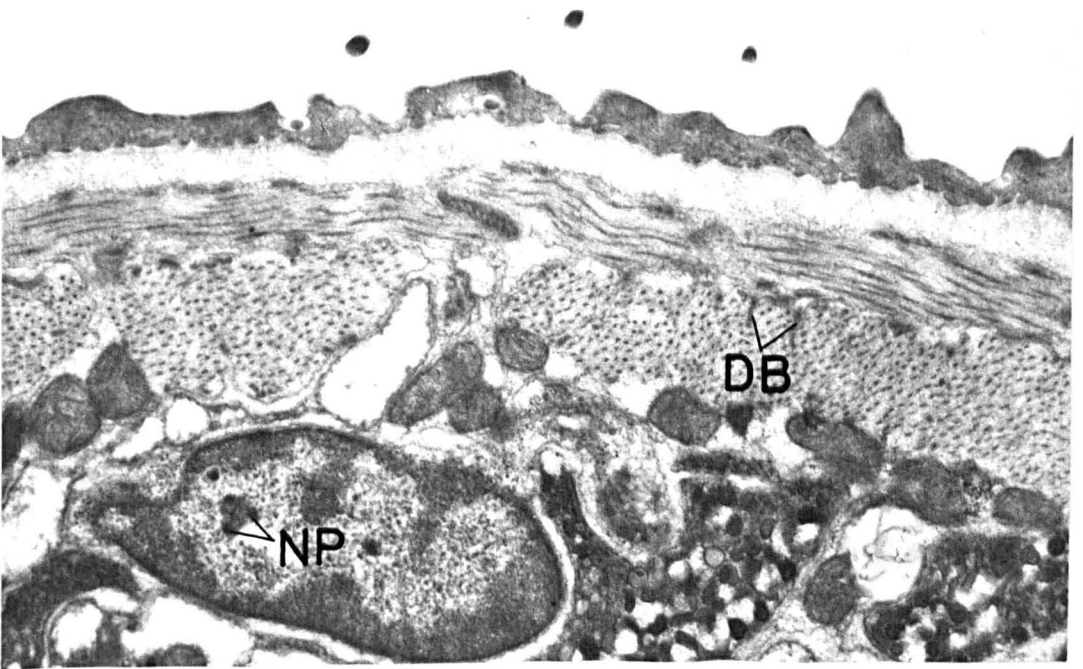
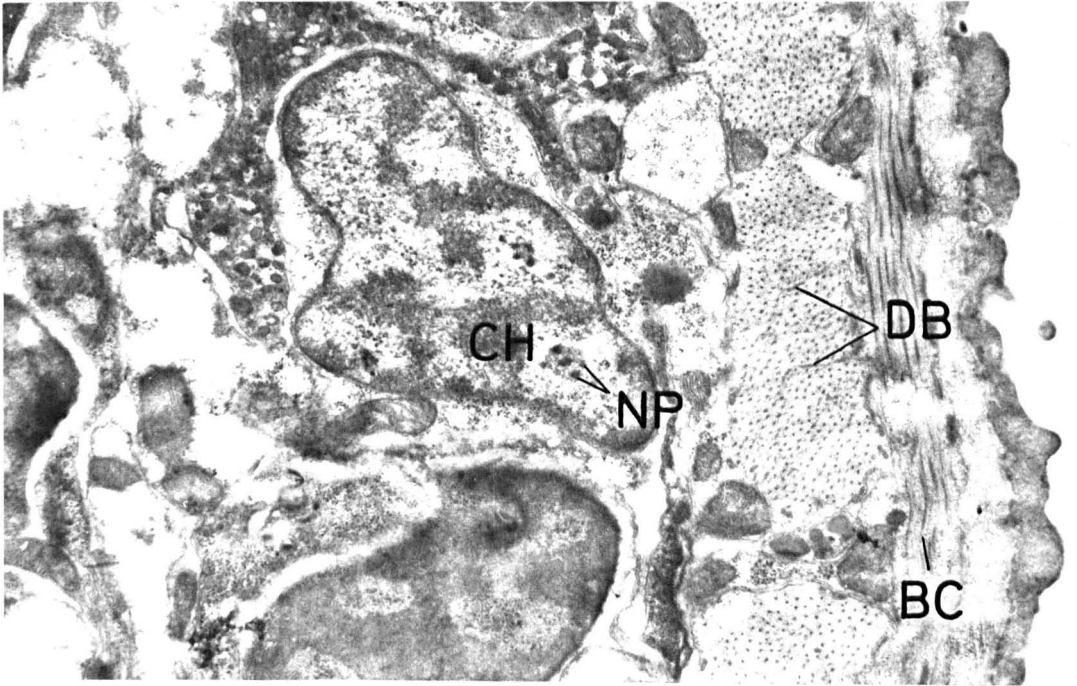


Fig. 7. LS posterior end of body. Circular myofibres are rounded and their enclosed thick myofilaments are only lightly stained. Underlying longitudinal fibre appears branched. X24000.

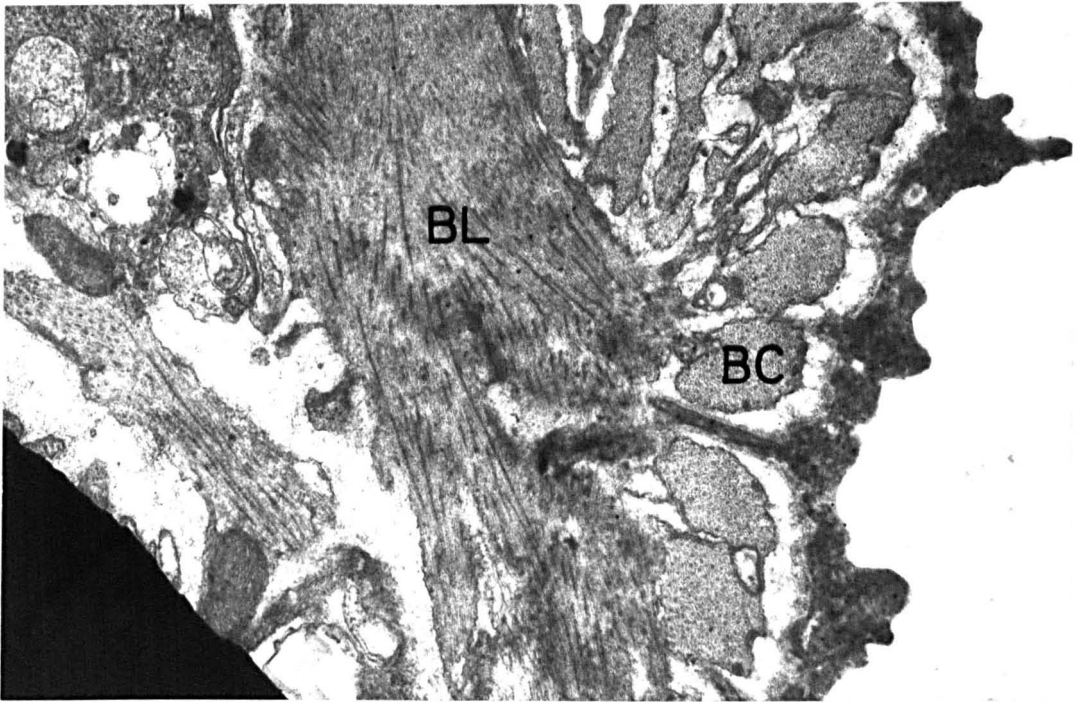


Fig. 8. LS central region of body. Circular fibres elongate in TS. Longitudinal fibres are not visible in this section which has presumably passed between adjacent longitudinal fibres. Note underlying cell with lobed nucleus, granular cytoplasm and numerous vesicles. Nerve tissue passing between myofibres to surface includes an axon and a multiciliated receptor. X23500.

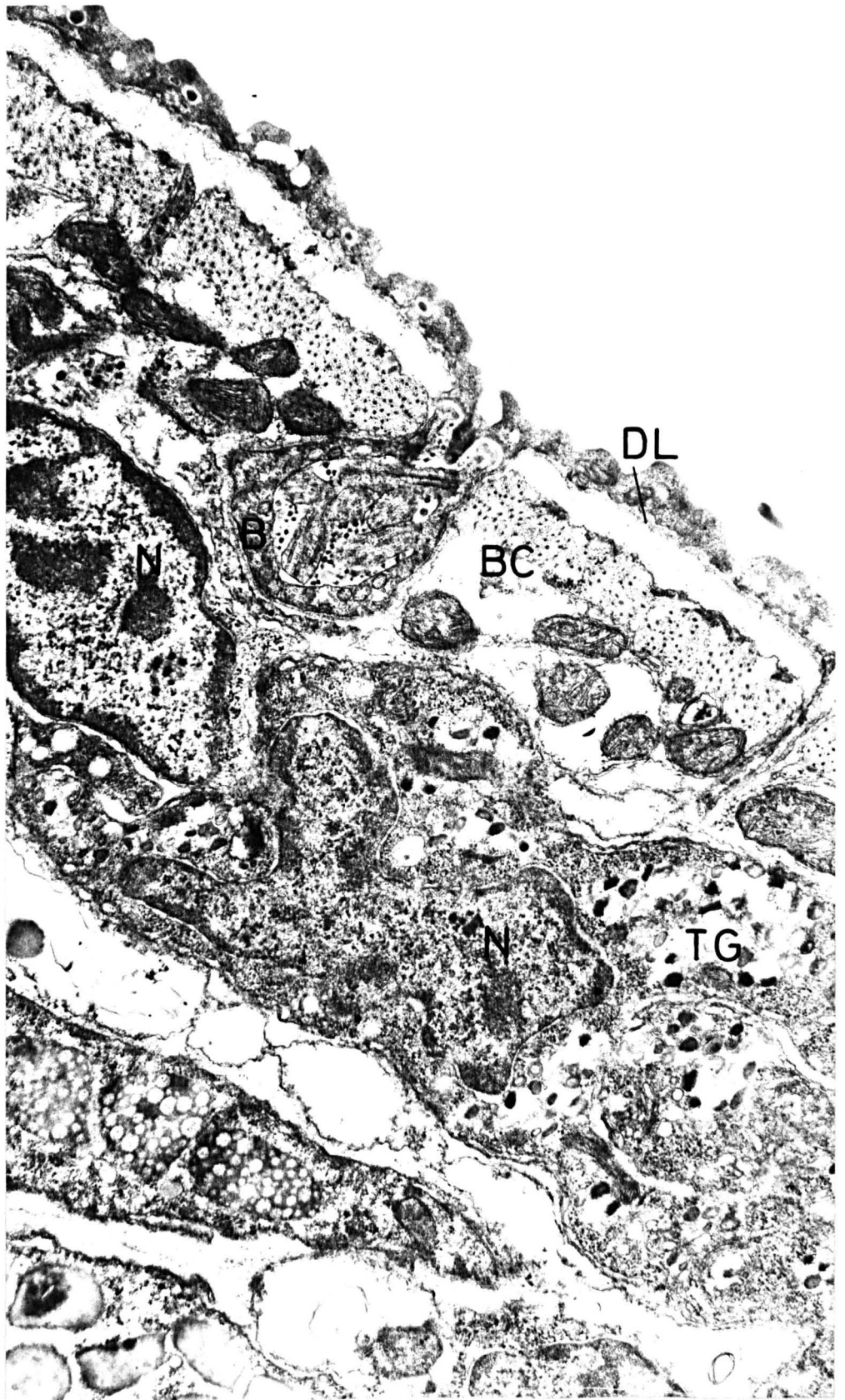


Fig. 9. LS body. Varying size of thick myofilaments as seen in circular fibre is reflected in tapered appearance of filament in longitudinal fibre. Nerve cord lies beneath longitudinal muscle. X24000.

Fig. 10. LS body, passing tangentially through circular muscle. Long, thick myofilaments seen. Fibrous layer beneath tegument attached to latter and to myofibres by desmosomes. X22400.

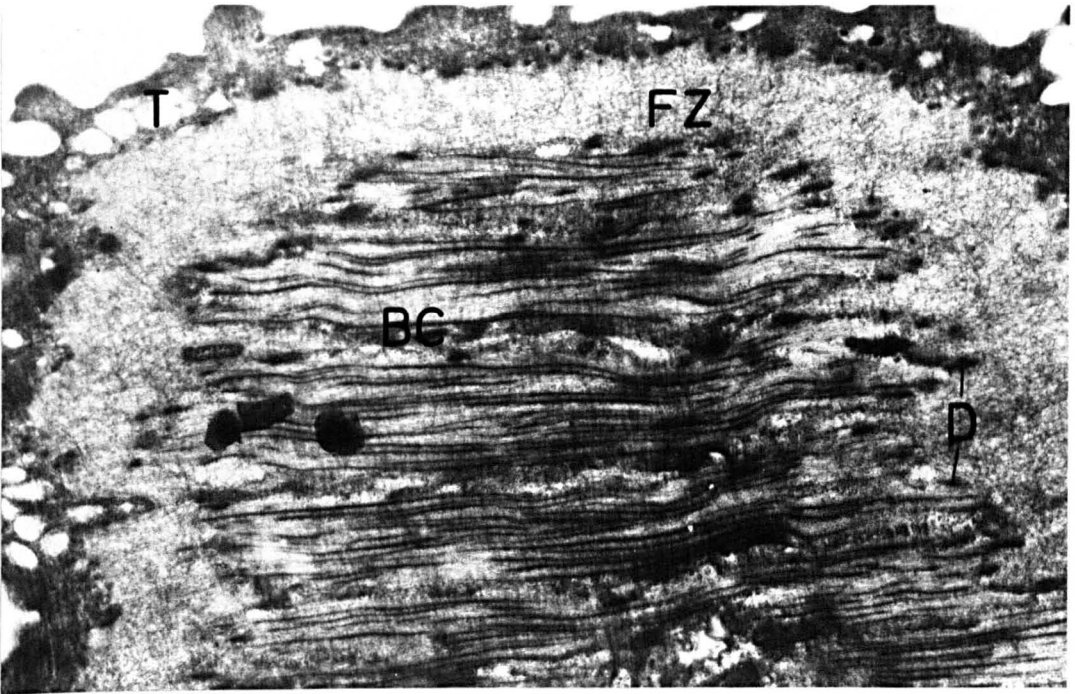
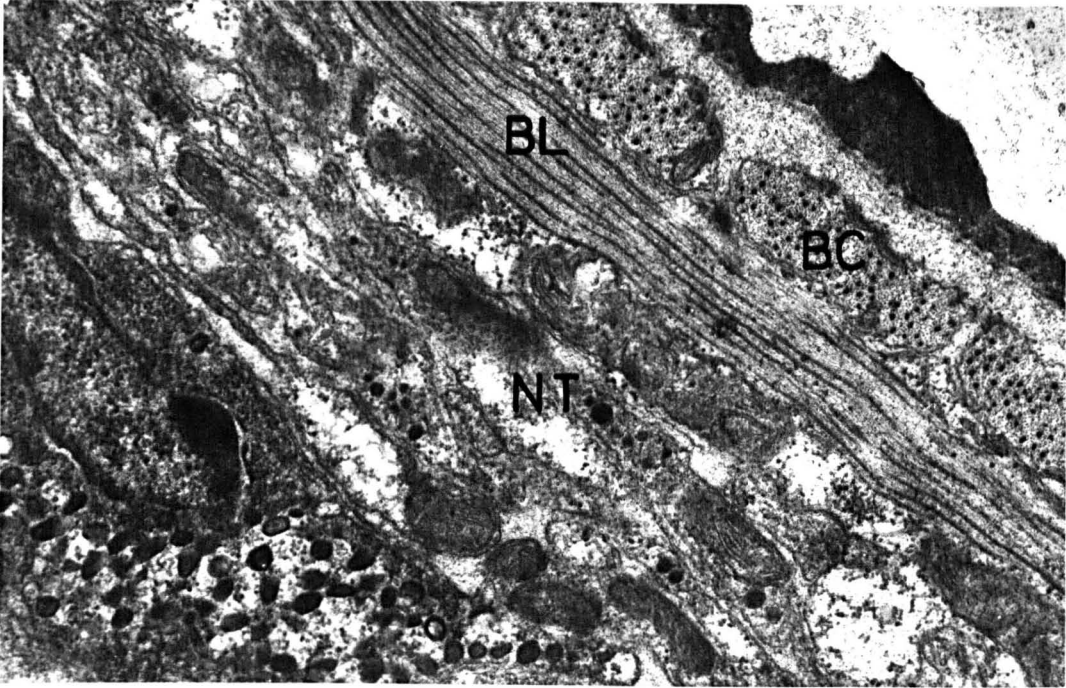


Fig. 11. LS body, passing tangentially through (mainly) subtegumentary fibrous zone. X38000.

Fig. 12. TS longitudinal myofibre at end of body, near to tail/body junction. X38000.

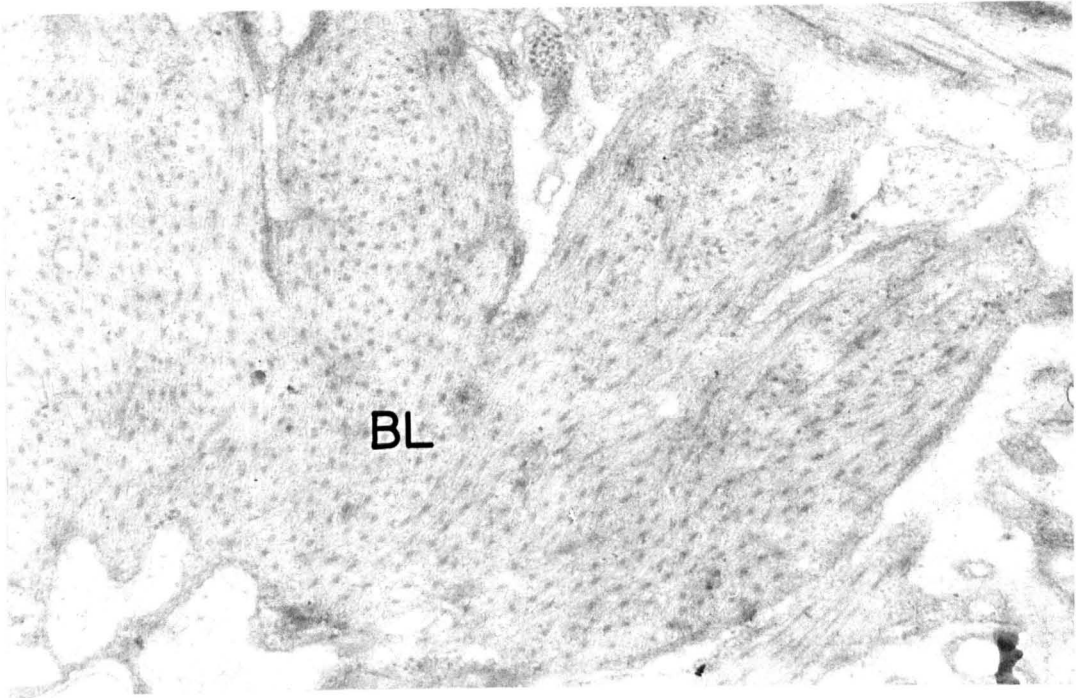
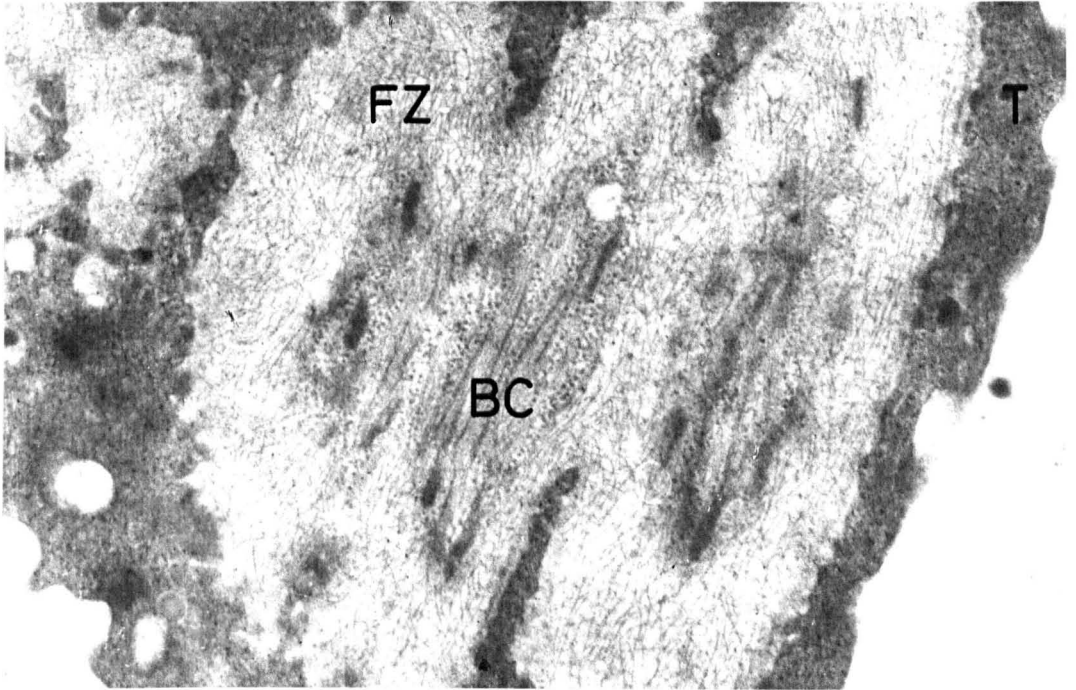


Fig. 13. TS posterior end of body, same region as in 12. Shows apparent continuity between adjacent fibres. X24000.

Fig. 14. TS central region of body. Extensive nervous tissue seen, with central axonal and peripheral nuclear regions. Gland cell ducts centrally placed prior to their lateral displacement and penetration of oral sucker capsule. Central gut also visible. The lack of tegumentary staining is an artifact. X5800.

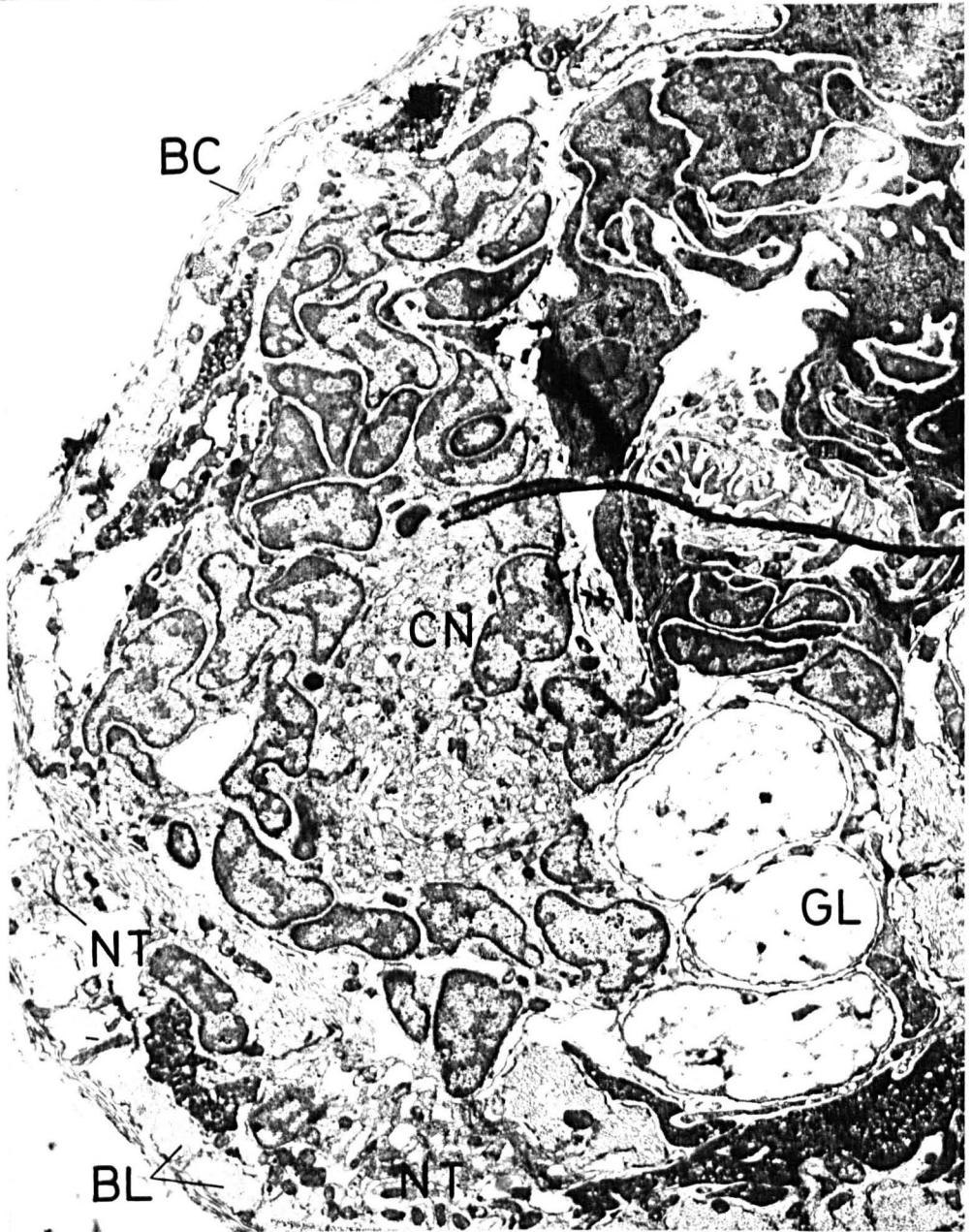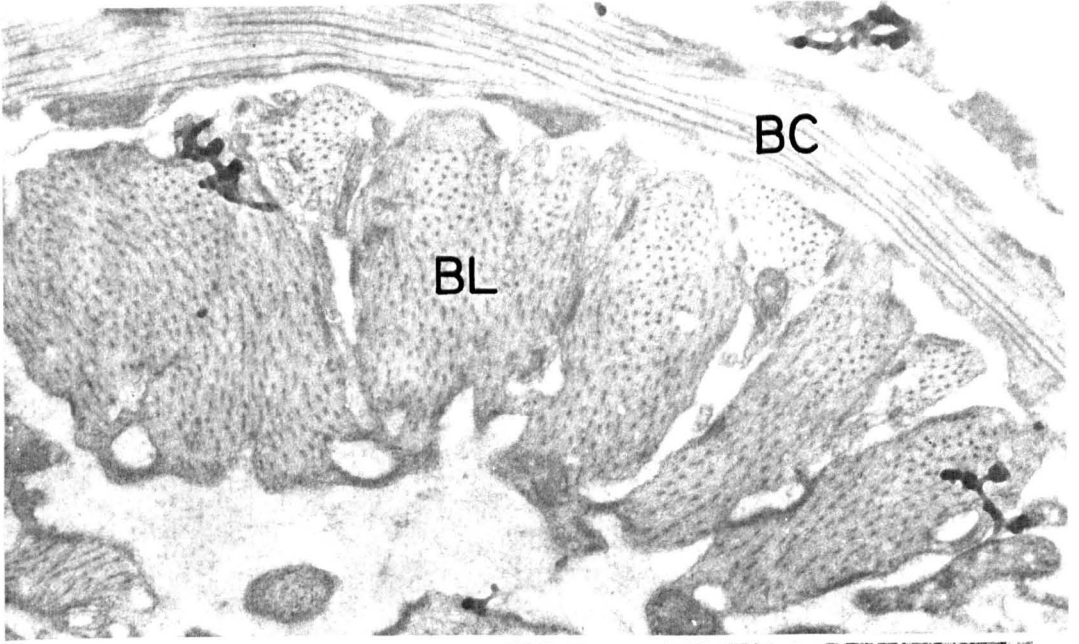


Fig. 15. Slightly oblique TS of posterior end of body, immediately anterior to the excretory bladder. The asterisks indicate the more posterior tissues. Note change in shape of longitudinal myofibres. X4000.

Fig. 16. As for 15 except section taken just posterior to that in 15. Two main excretory channels are seen, prior to their junction with the excretory bladder. The posterior body flange also visible on one side. X4000.

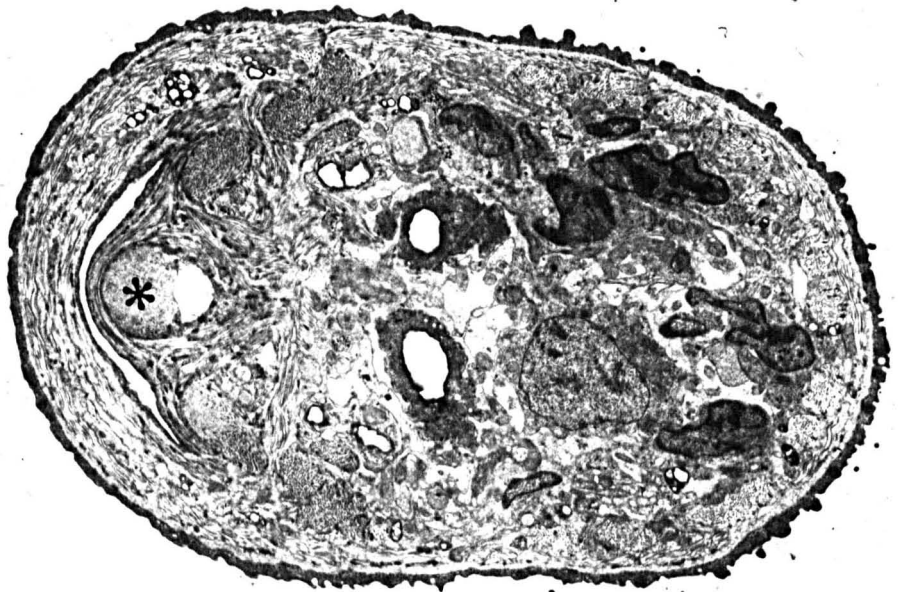
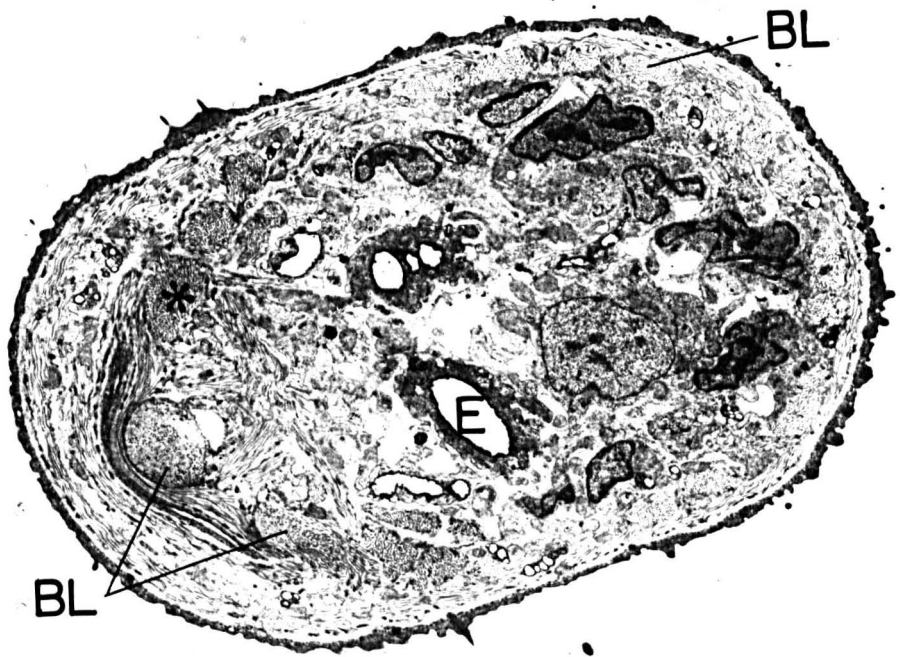


Fig. 17. As for 16. Higher magnification shows much of longitudinal myofibre contains only thin myofilaments. Other fibres, of varied orientation also seen. X12000.

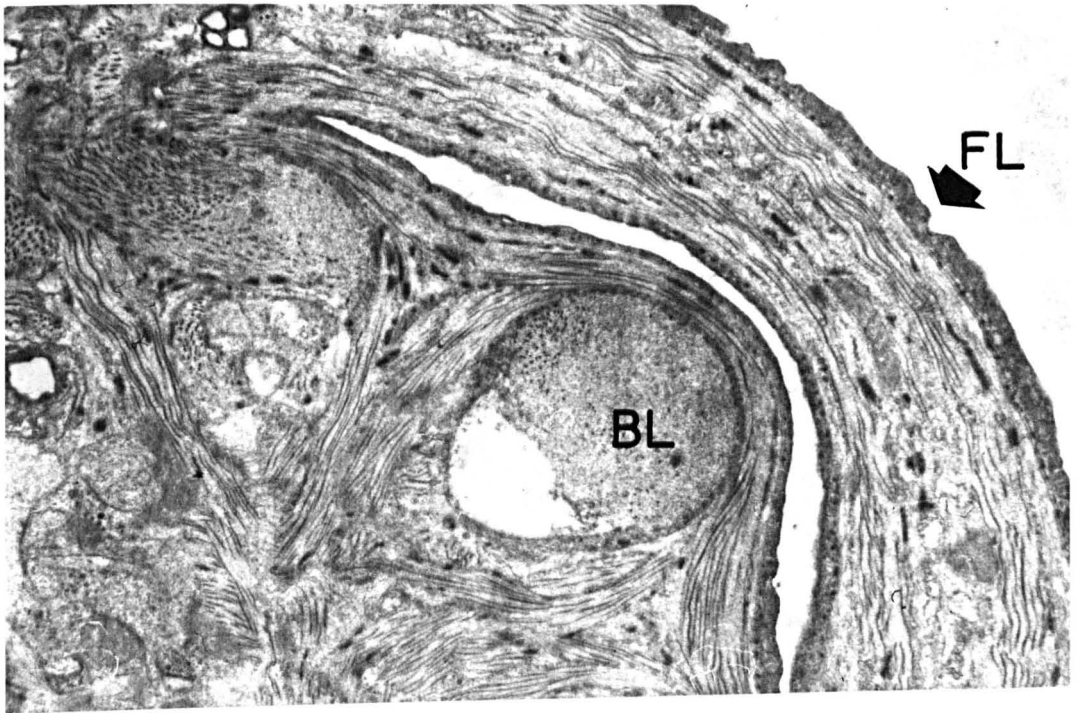


Fig. 18. IS tail/body junction. Contents of apparently branched body myofibres change from thick and thin filaments to thin only. Intimate association between body and tail longitudinal fibres. X38000.

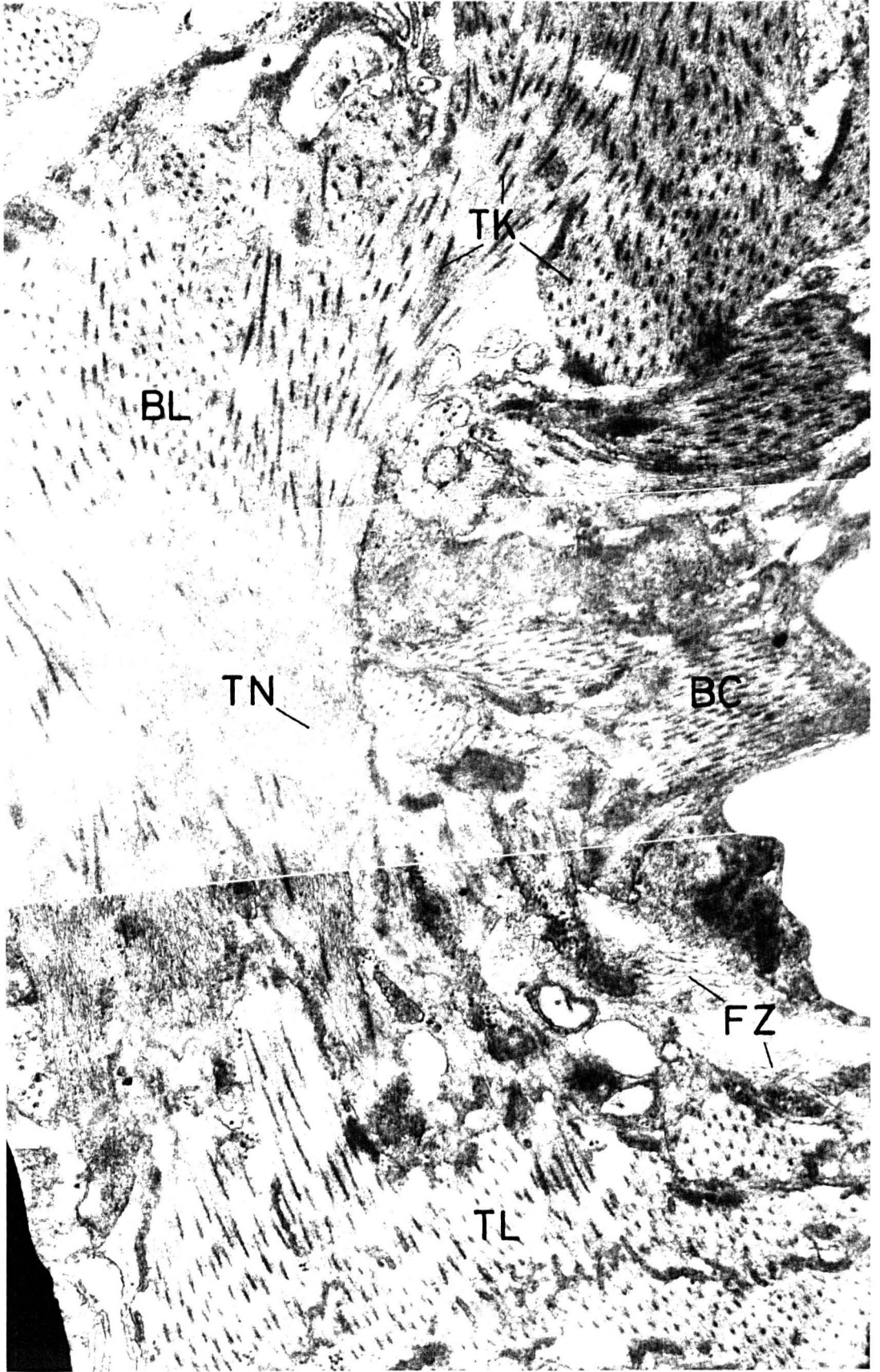


Fig. 19. LS thin myofilament region of body longitudinal muscle in tail/
body junction. X38000.

Fig. 20. LS tail/body junction to put Figs. 18, 19 into perspective.
Excretory bladder seen at one side. Minor flange, posterior
to main body flange also seen. X16000.

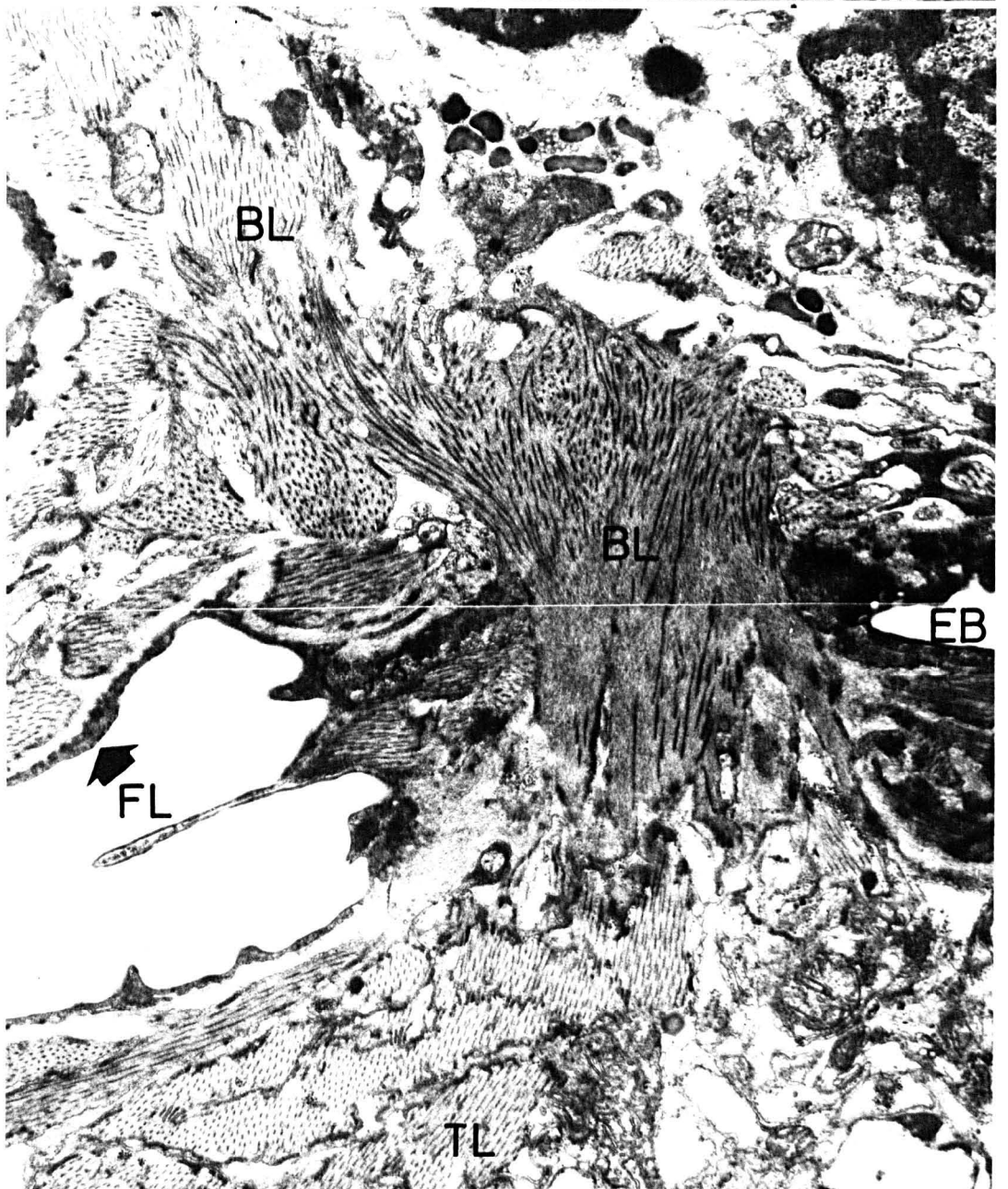
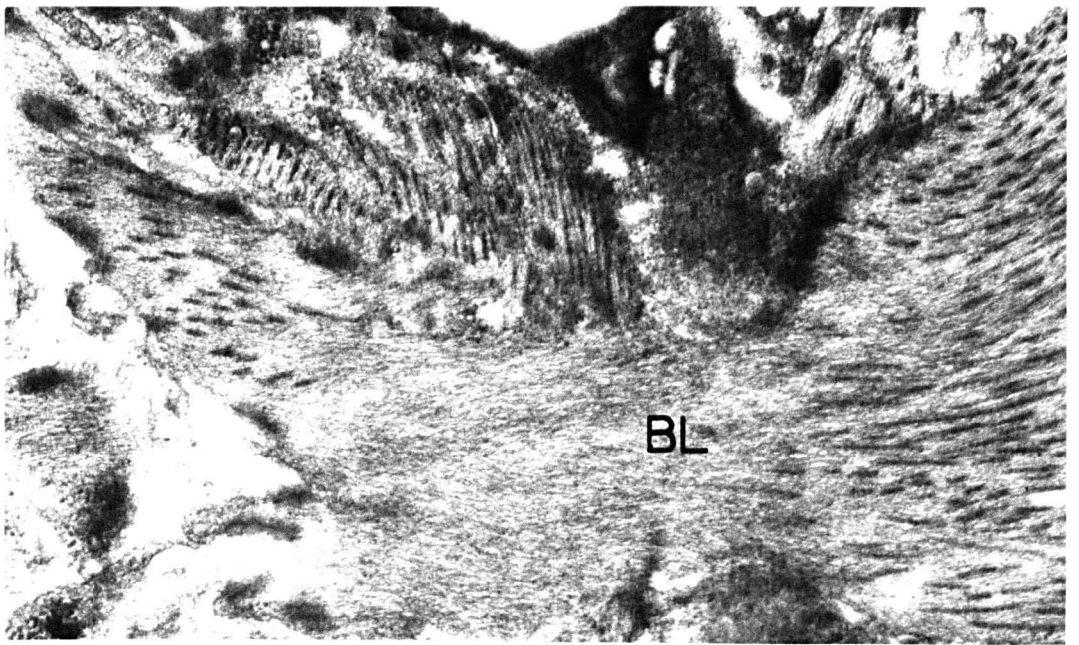


Fig. 21. Oblique LS body wall musculature. Note dense body attached to sarcolemma of (outer) circular fibre which appears to be continuous with thin myofilaments. Bar-like dense bodies in the (inner) fibre are also attached to the sarcolemma. Note also underlying nerve tissue and tubule linking tegument to inner tissues. X38000.

Fig. 22 TS ventral sucker. Cavity contains a nerve bulb, many inwardly-projecting spines and 'lips' of sucker protrude slightly. Six radial myofibres visible, separated by nuclei and mitochondria.

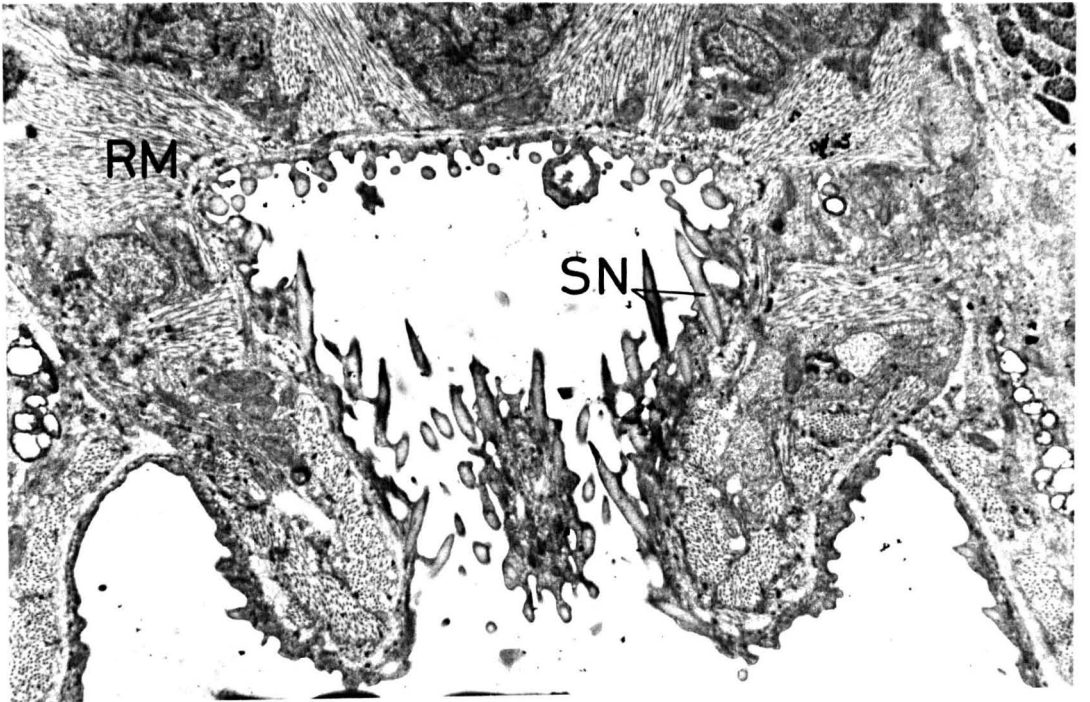
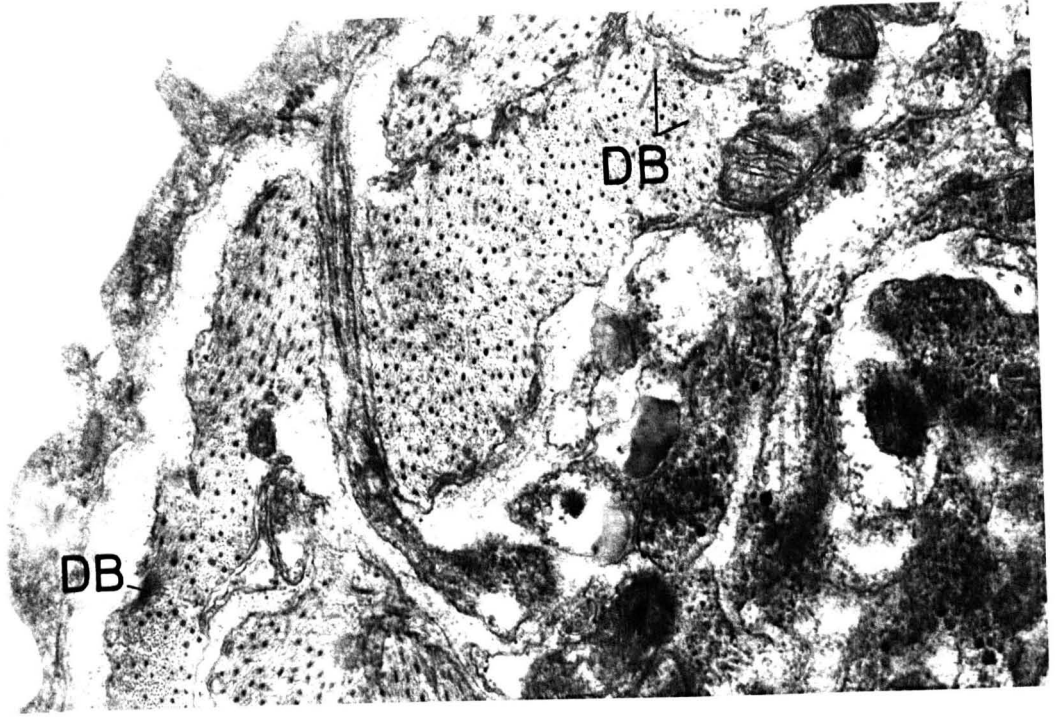


Fig. 23. LS ventral sucker. Radial and circular myofibres visible.
Note dense particles in nucleus. X8000.

Fig. 24. Horizontal LS ventral sucker (protruding). Main radial fibres
seen in TS. Nerve bulb present in cavity. X8000.

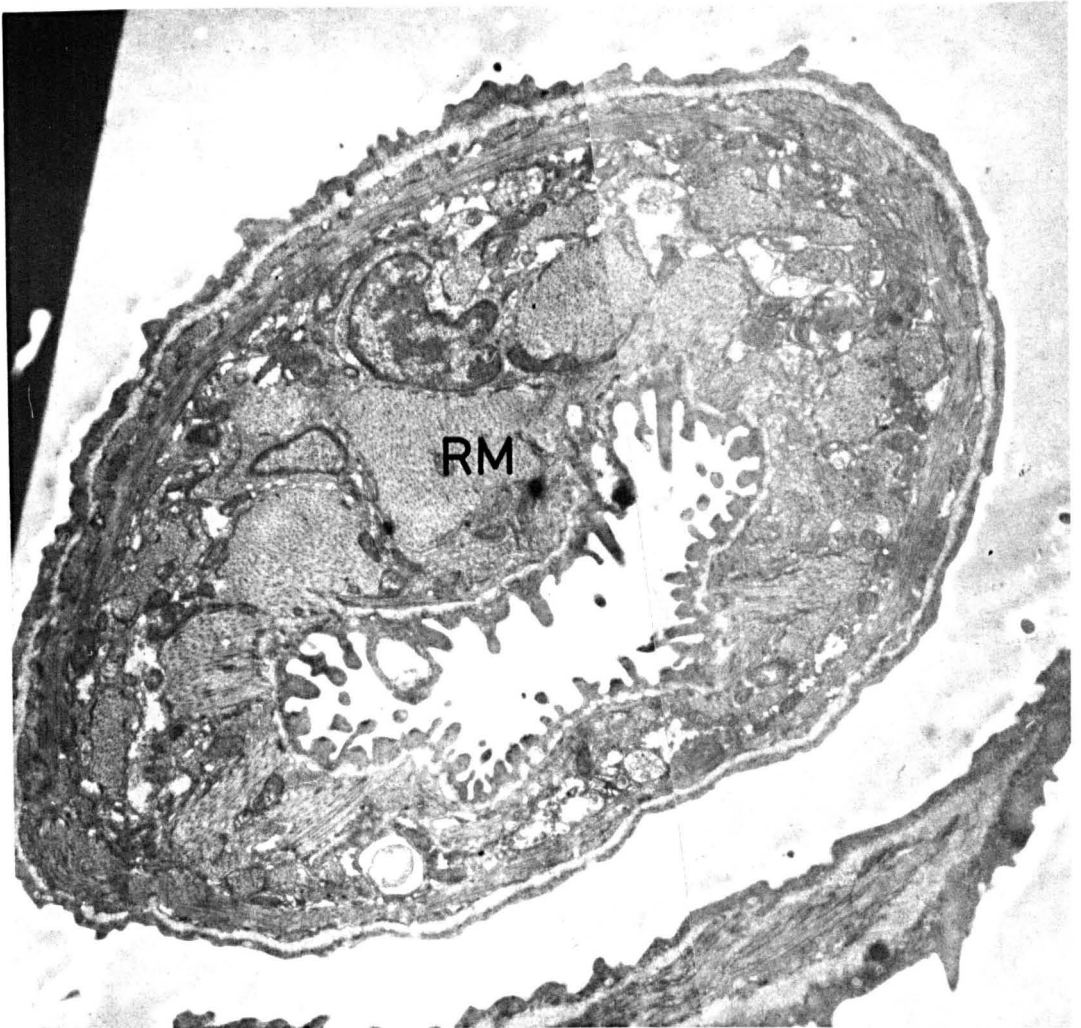
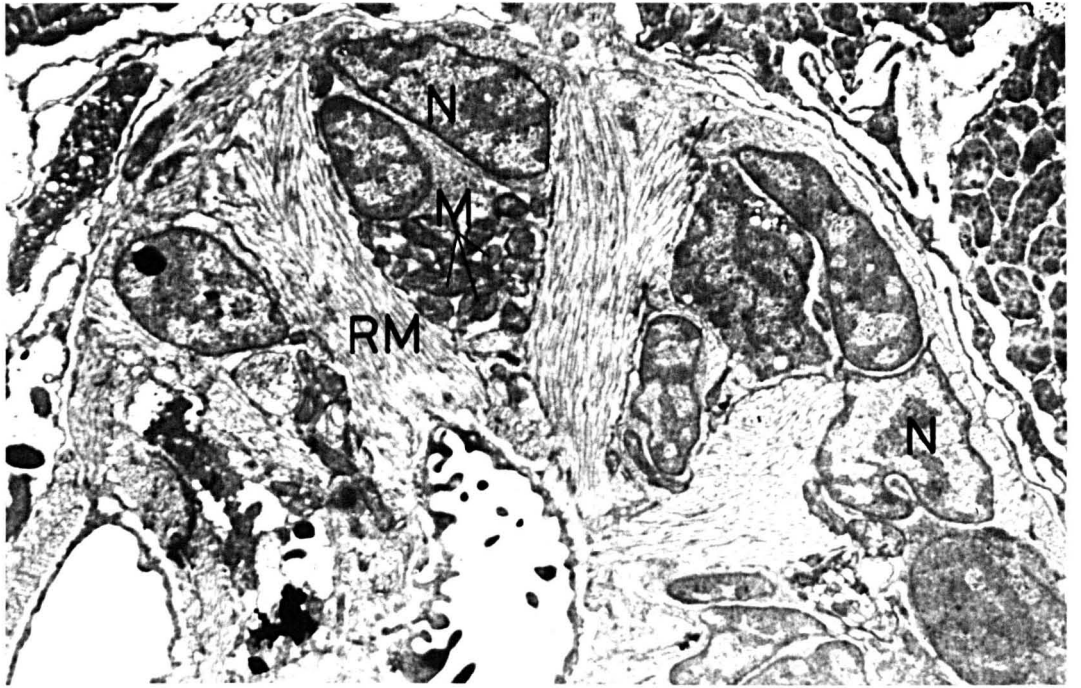

Fig. 25. Horizontal LS through centre of ventral sucker. Array of radial myofibres sectioned. X8000.

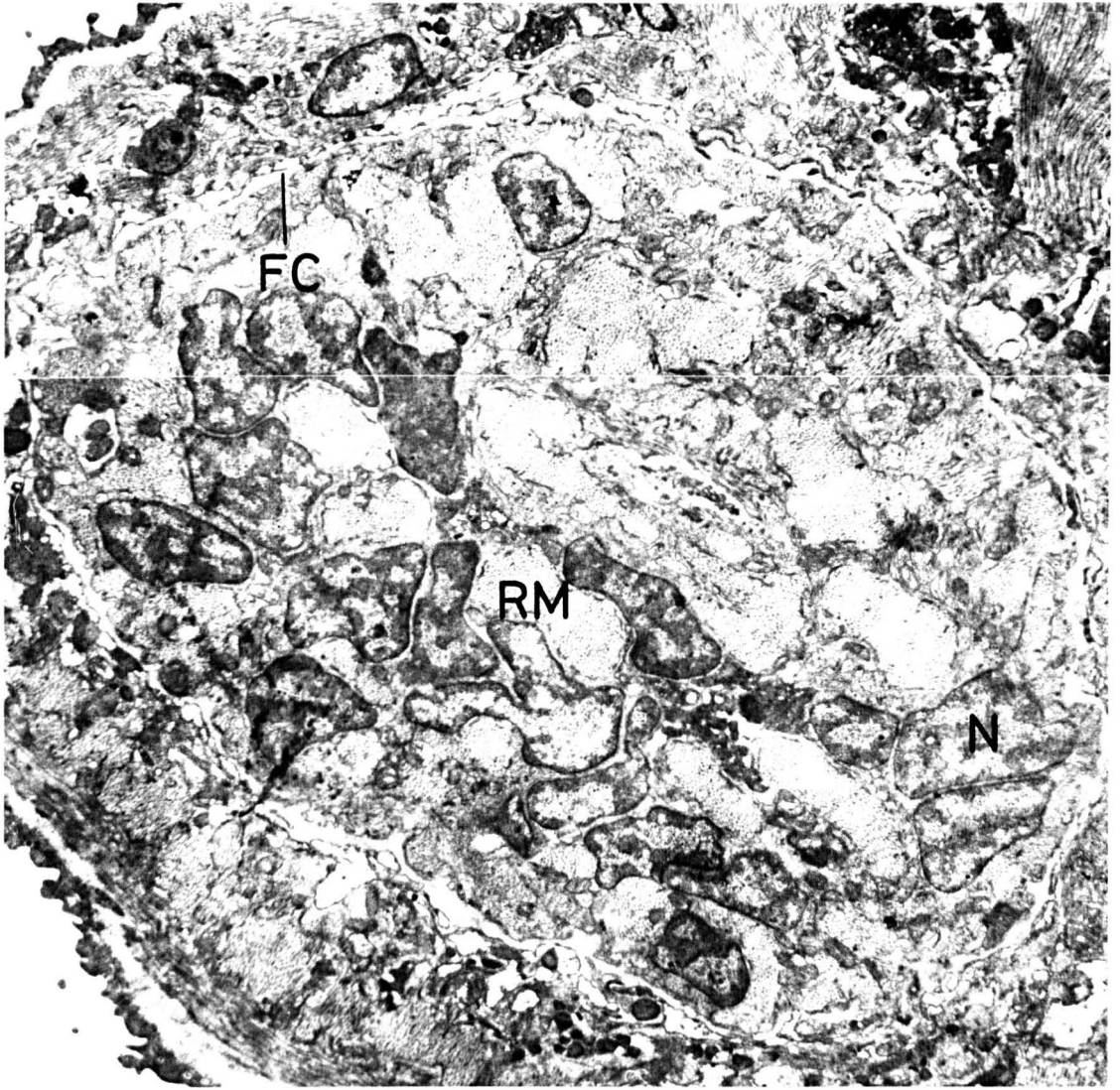


Fig. 26. TS body to show vertical fibres joining ventral sucker capsule to dorsal body wall. Note also, ventral and lateral nerve cords. X5800.

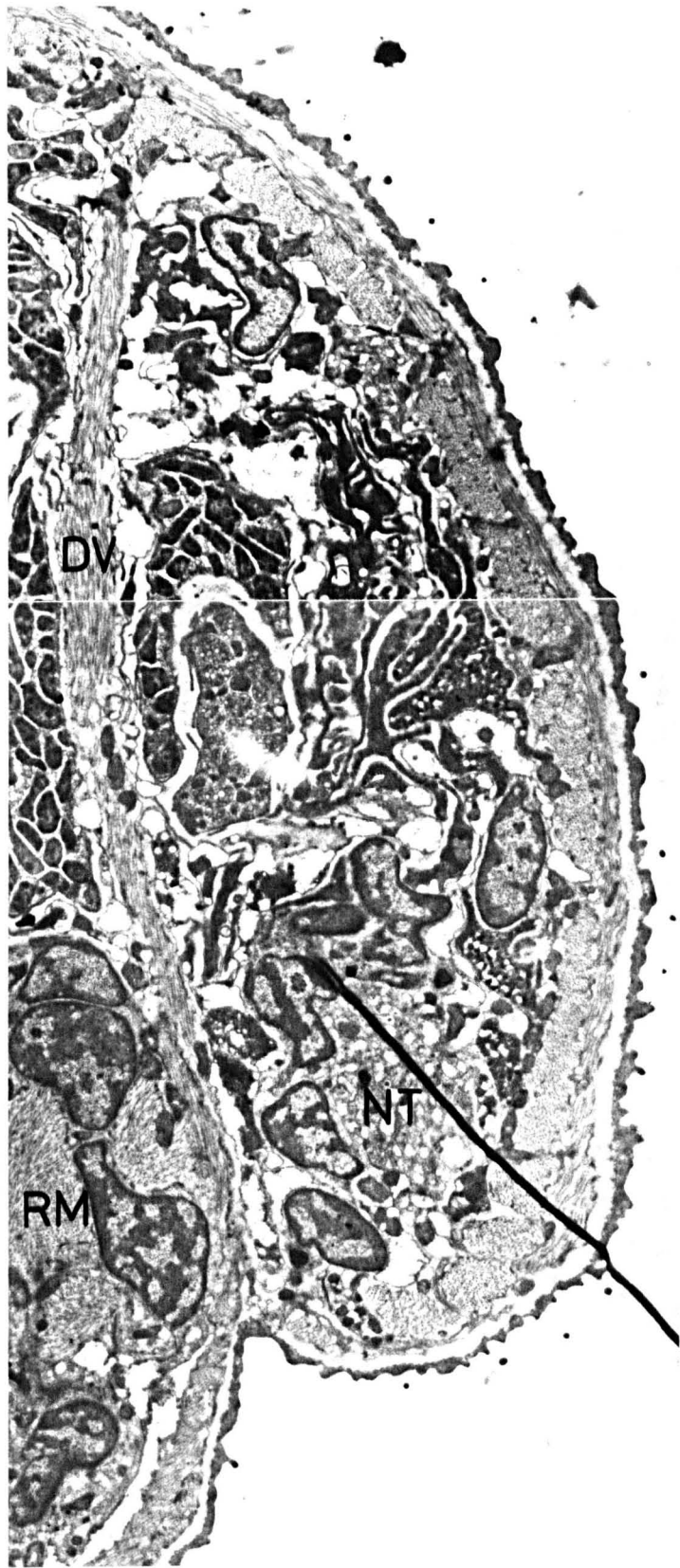

Fig. 27. TS body showing attachment of vertical muscle from sucker on the dorsal body wall. X20000.

Fig. 28. TS body. Montage to show distribution of tissues in the oral sucker region. One side of section passes through body wall, just posterior to the oral sucker capsule, so that both body wall and oral sucker musculature are visible. Sucker capsule is continuous with subtegumentary fibrous zone. X4000.

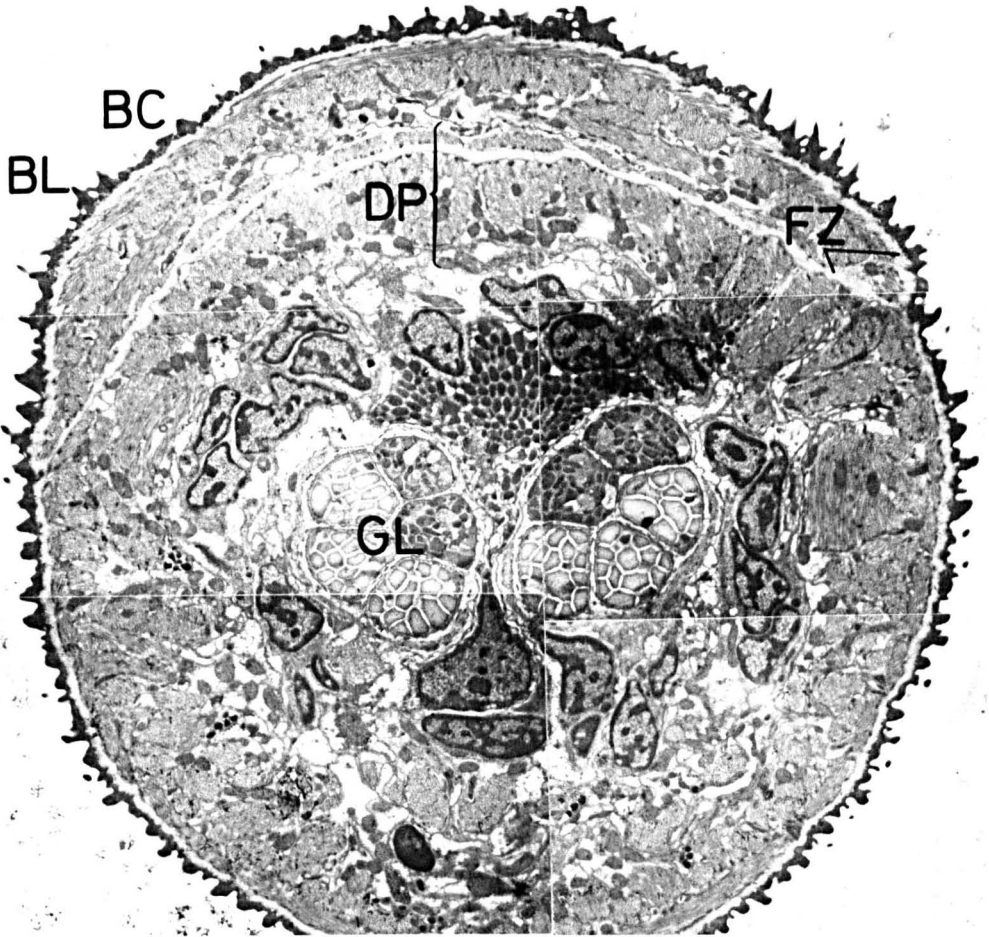
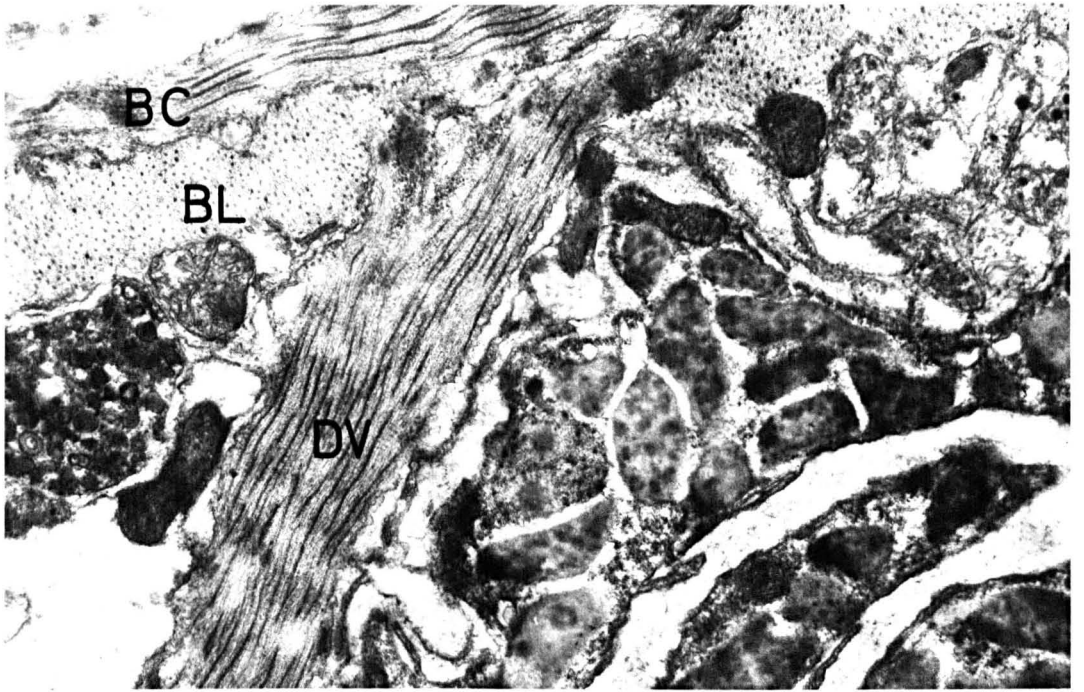


Fig. 29. TS body. Detail of oral sucker capsule. Longitudinal myofibres on both sides of capsule. Further myofibre between body wall and capsule. X16000.

Fig. 30. TS part of oral sucker capsule. Dense bodies are numerous in internal myofibre. Note large dense vesicles under body wall myofibres. X38000.

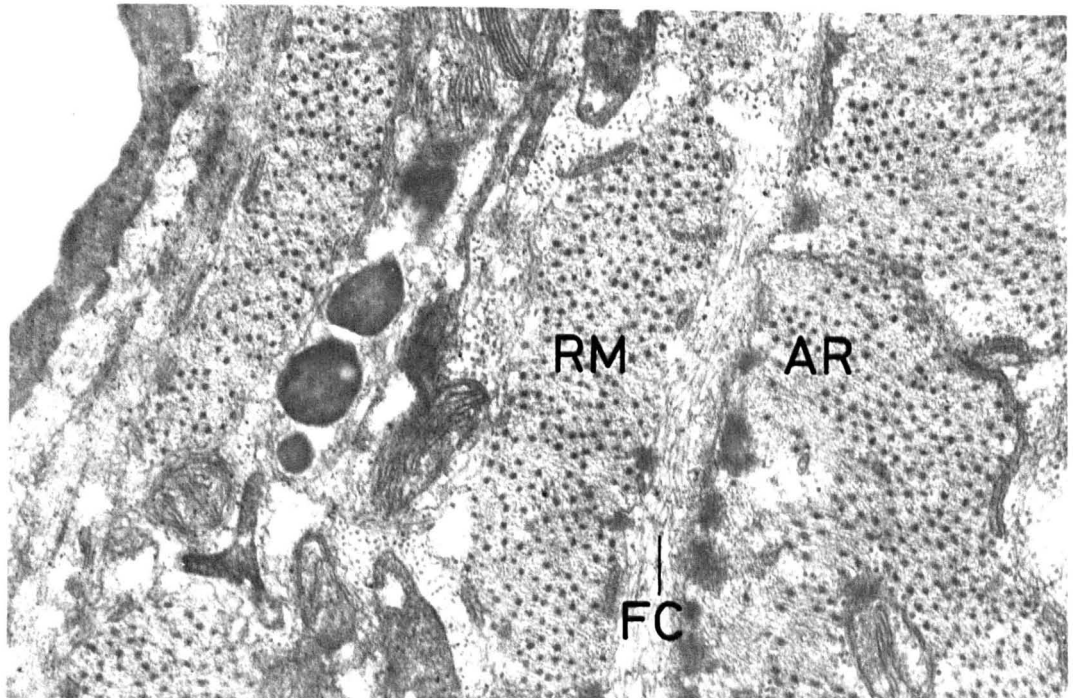
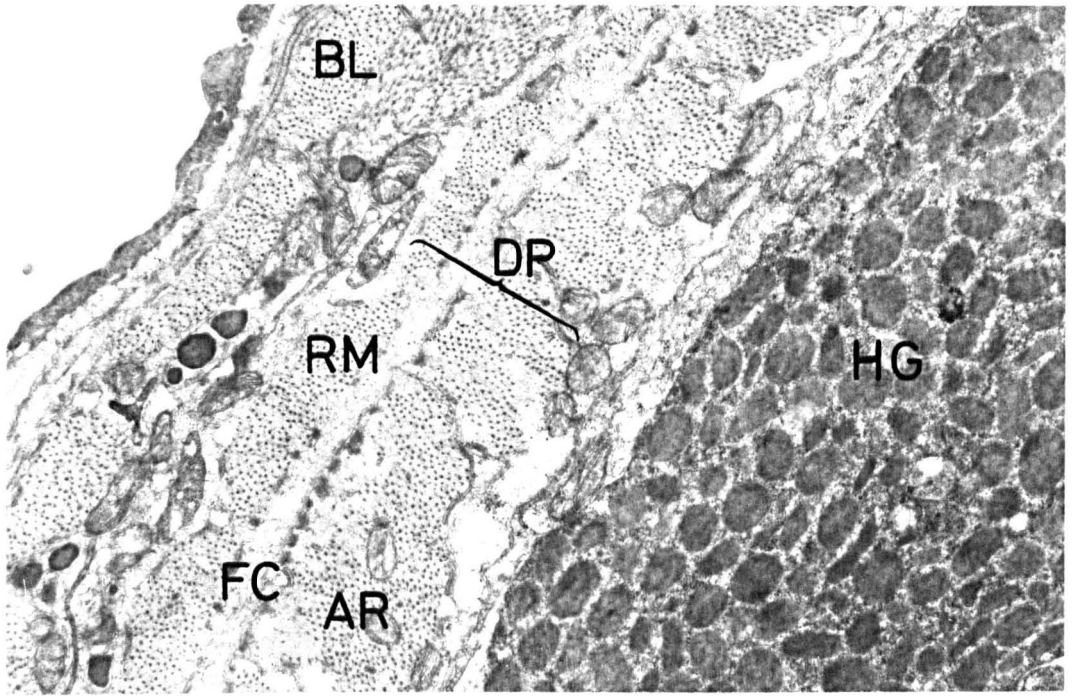


Fig. 31. TS oral sucker in region of periphery of diaphragm,
(see text). Note prominent longitudinal myofibres
inside capsule and also nerve tissue. x8000.

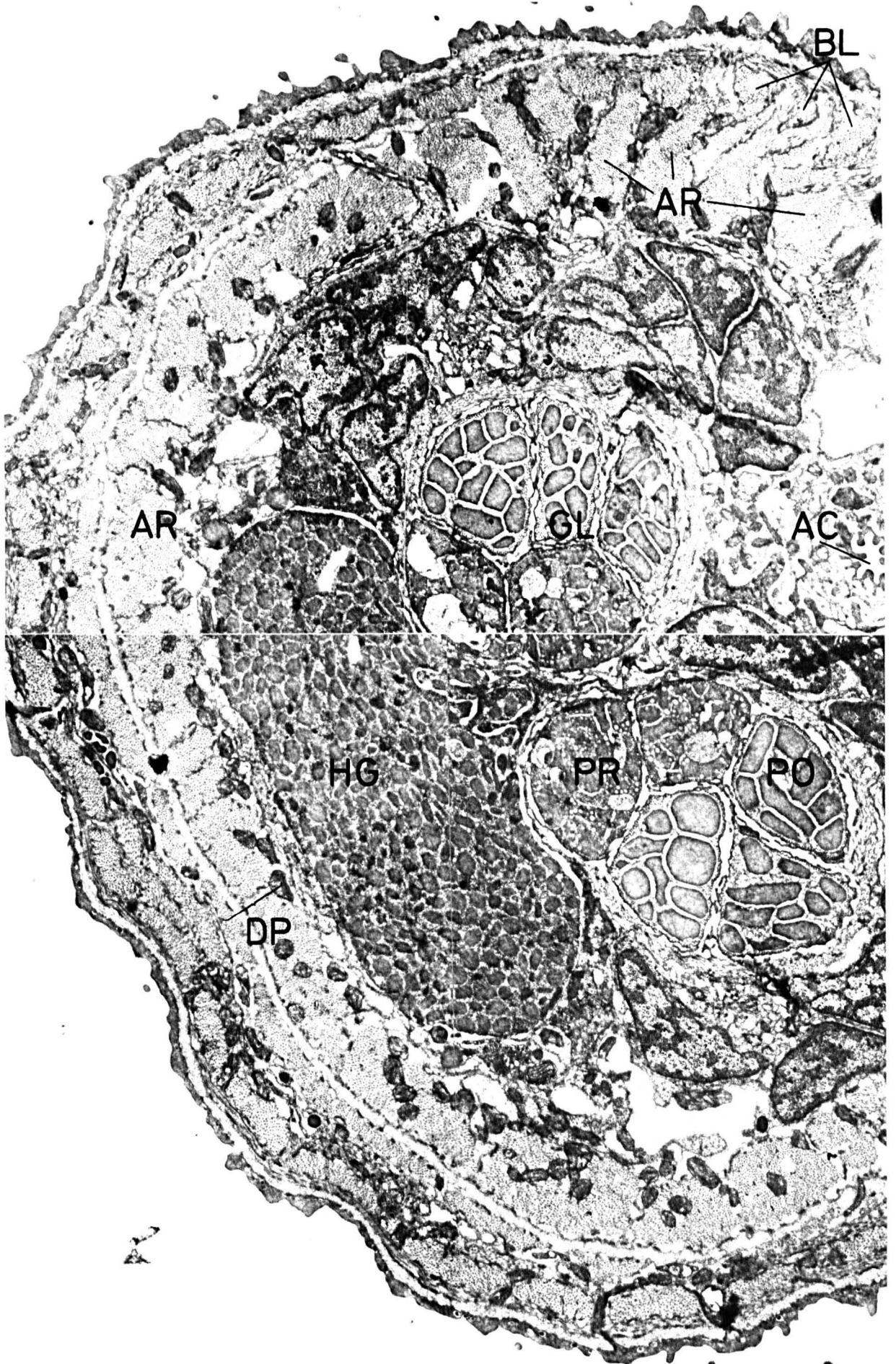

Fig. 32. TS oral sucker near centre of diaphragm. Longitudinal fibres outside capsule more prominent than in Fig.31 while fibres inside are obliquely circular. x8000.

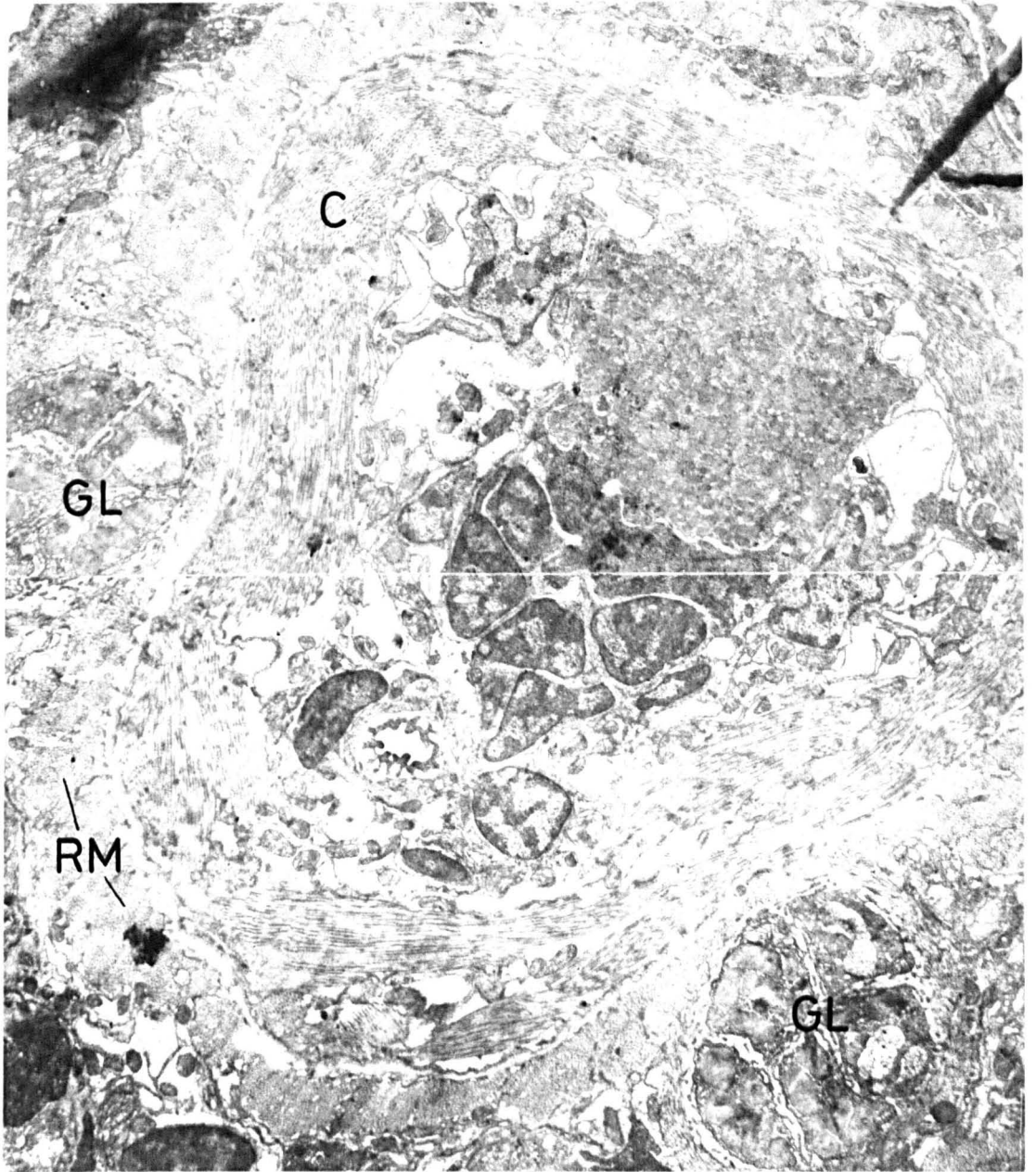


Fig. 33. TS part of oral sucker capsule, same region as Fig. 32. Gland cell duct sectioned just prior to its insertion through the diaphragm musculature. Ducts possess own circular muscle at this point. x12000.

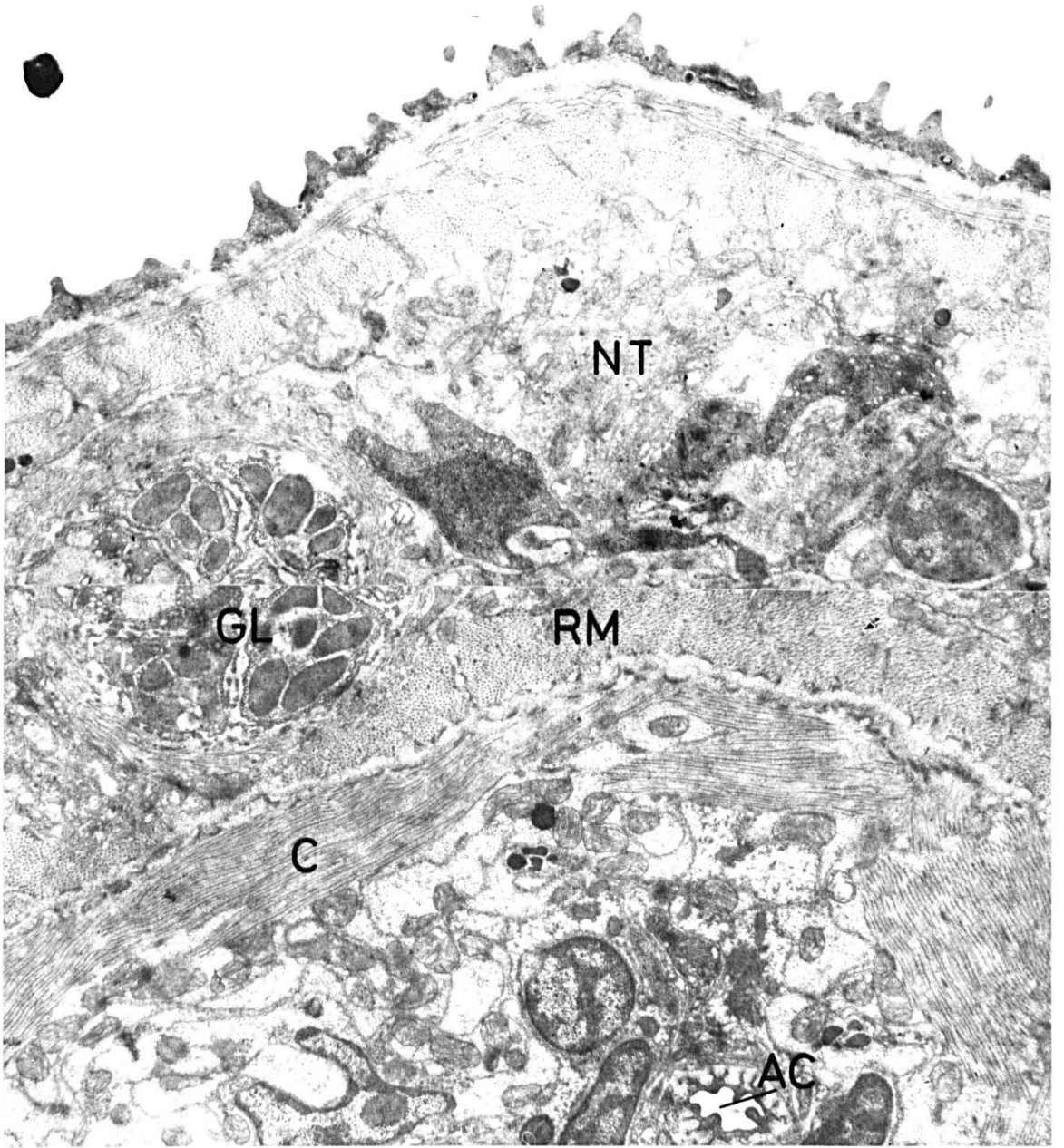


Fig. 34. LS anterior tip of body. Head gland has more than one exit to the tegument. Ancillary longitudinal myofibres present. Note apical nerve bulbs and main gland cell ducts. X8000.

Fig. 35. TS gland cell ducts within oral sucker region. Abundant, peripheral microtubules present. Note dense particles in nearby nucleus. X12000.

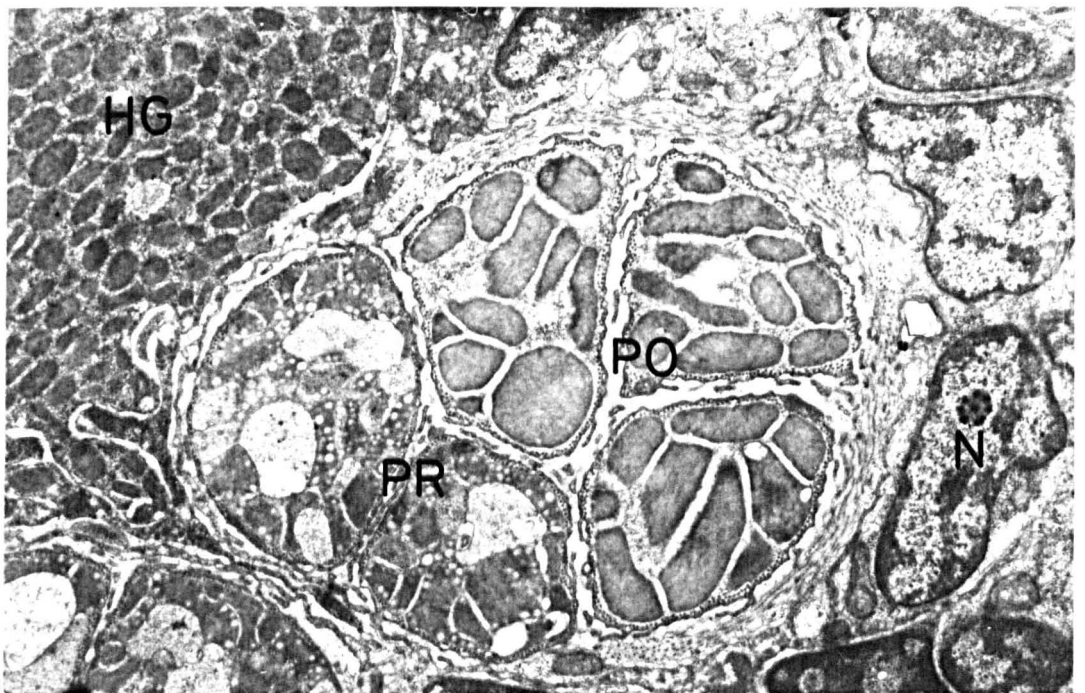
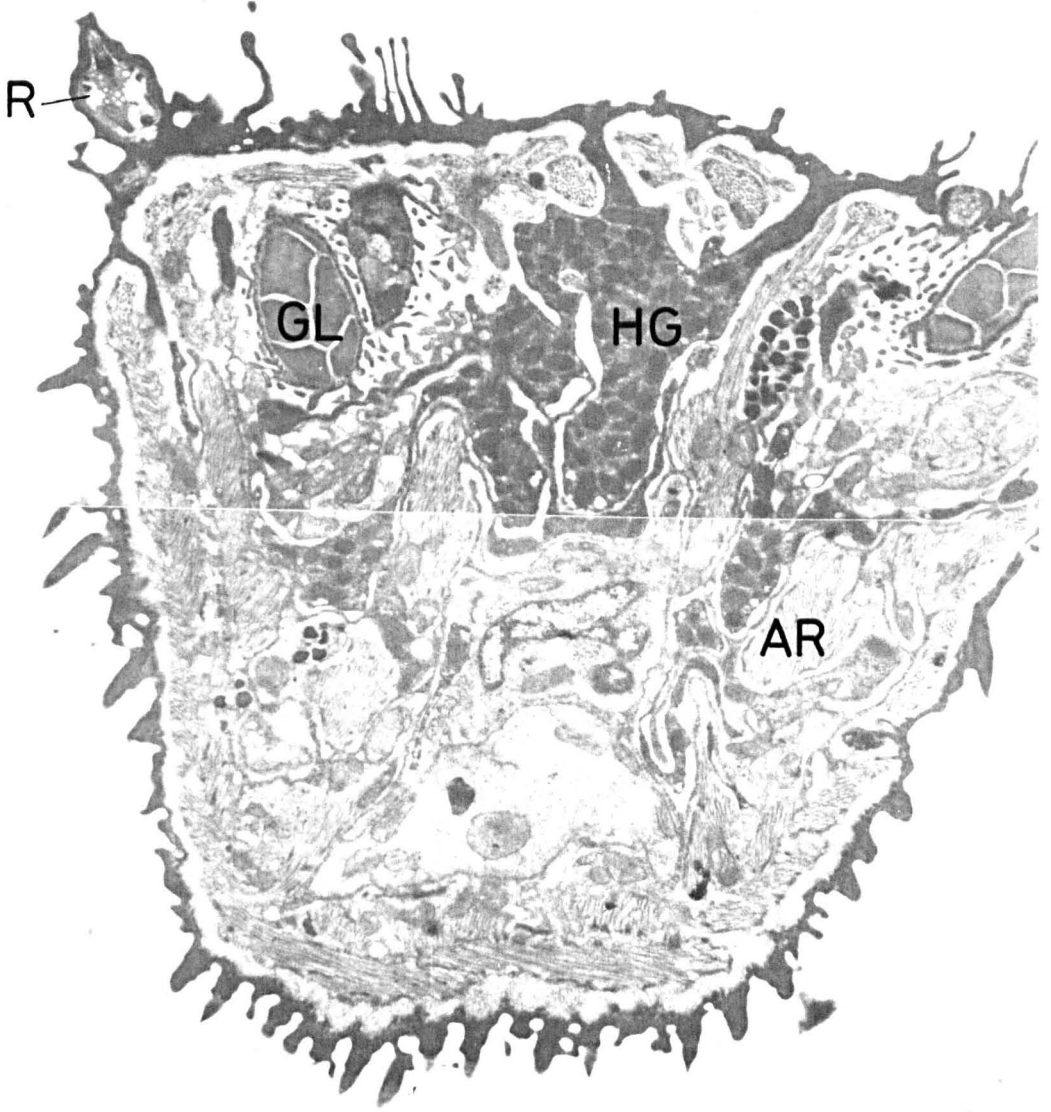


Fig. 36. TS alimentary canal within oral sucker region. Circular and longitudinal myofibres visible. X34000.

Fig. 37. TS gland cells shows peripheral microtubules in TS. X38000.

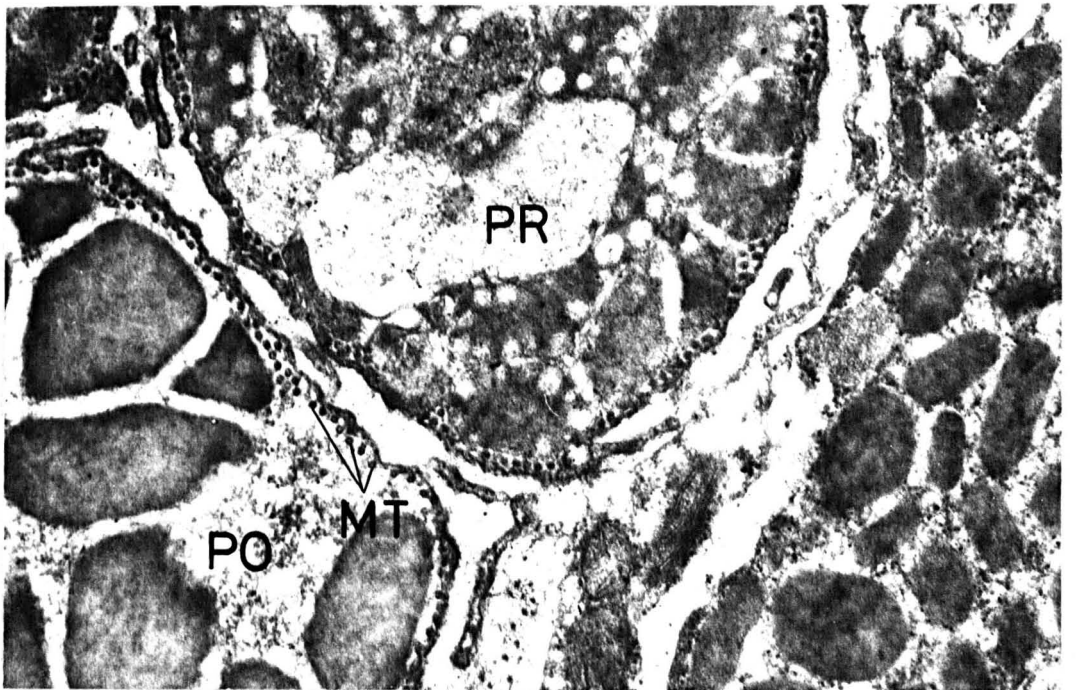
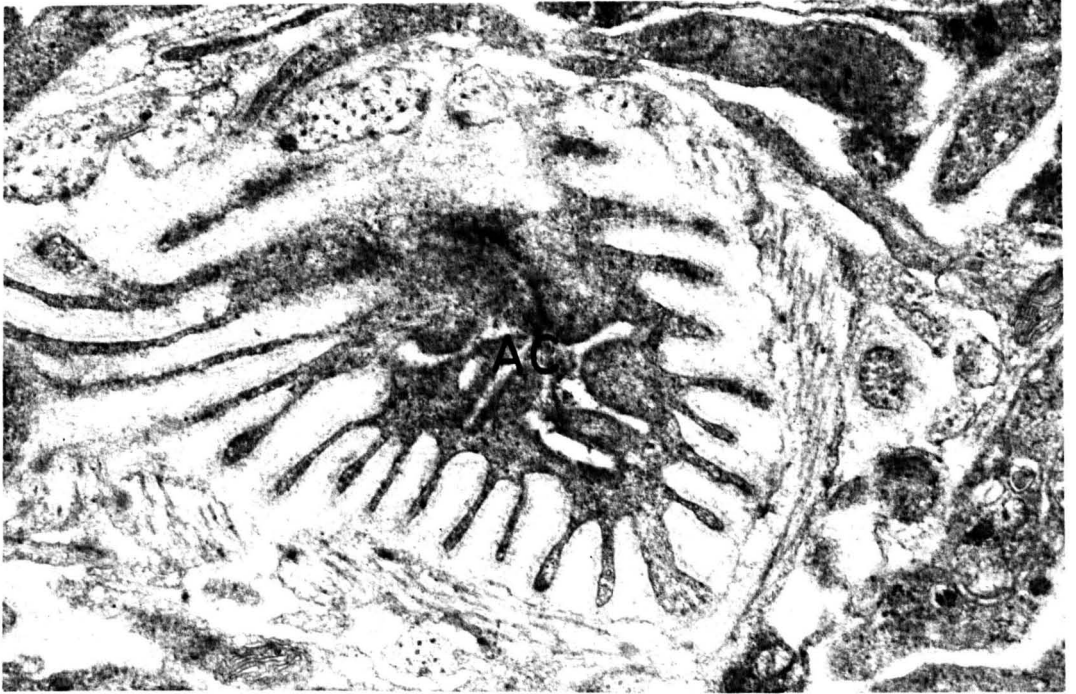



Fig. 38. LS musculature associated with excretory bladder. X12000.

Fig. 39. LS base of tail. Note relatively small circular myofibres, many nuclei associated with longitudinal fibres and large 'clear' spaces centrally. X8000.



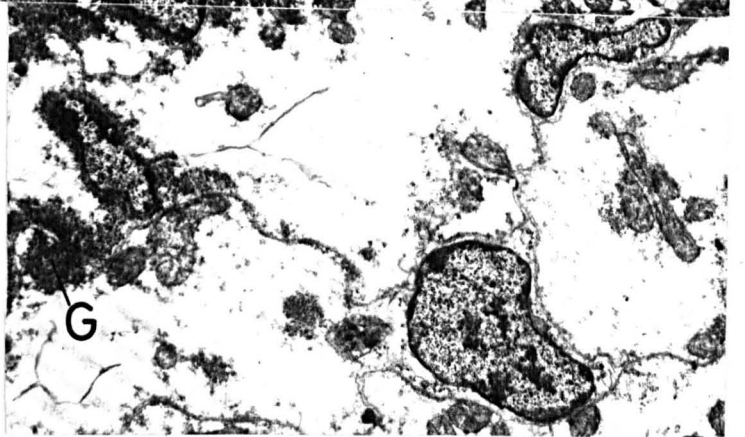
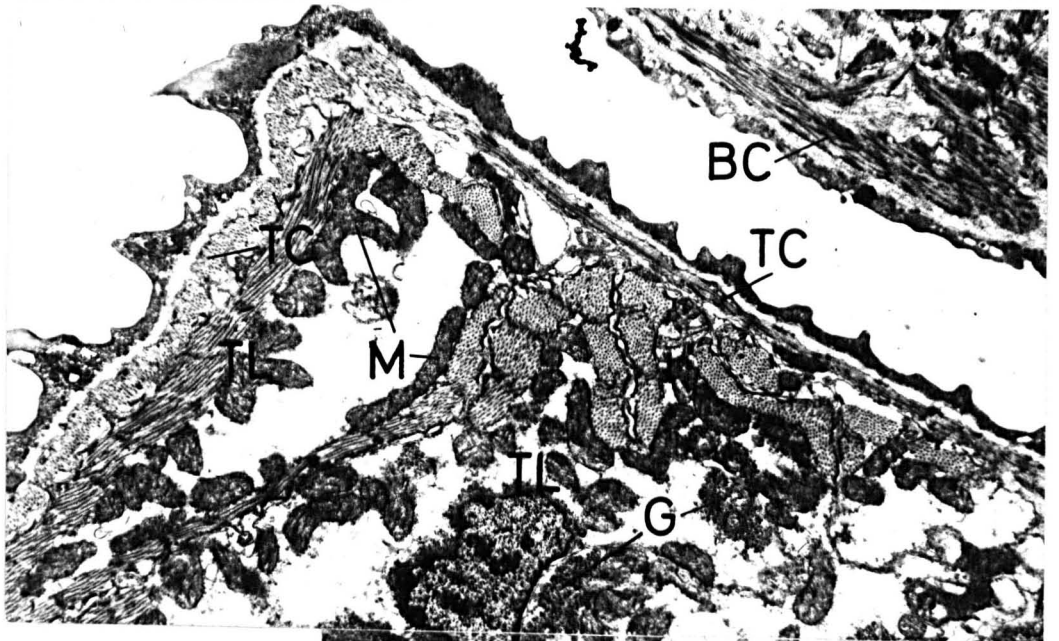
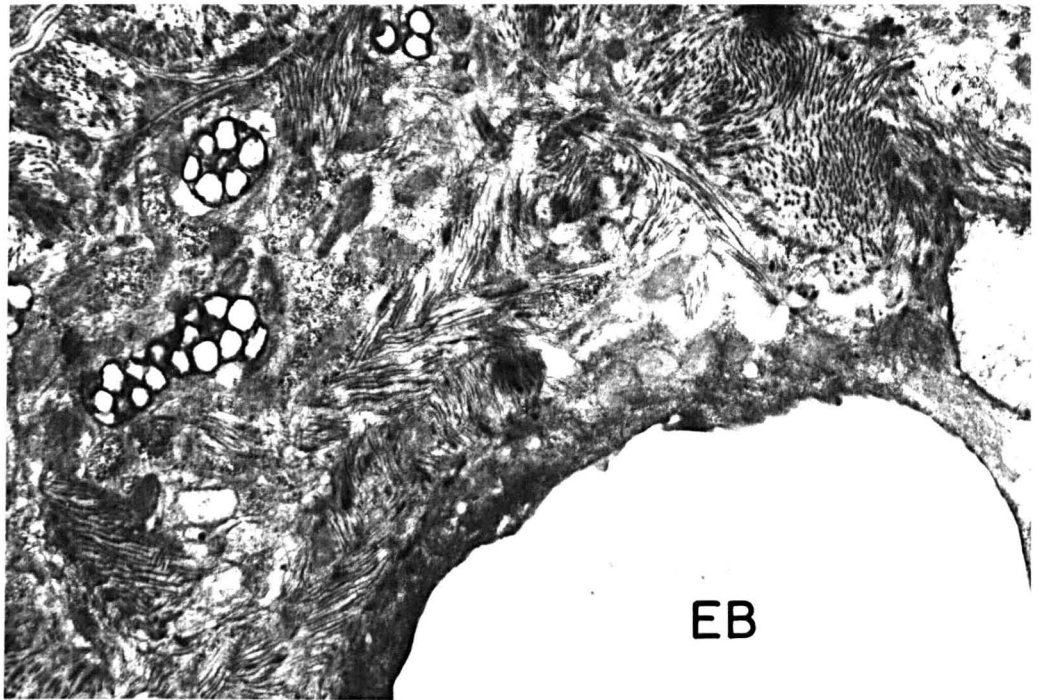


Fig. 40. LS base of tail. Desmosomes lie on both sides of subtegumentary fibrous zone. Longitudinal fibre is non-striated.
X8000.

Fig. 41. LS base of tail - close to section in Fig. 42. Note dense nuclear particles and great variation in size of mitochondria.
X8000.

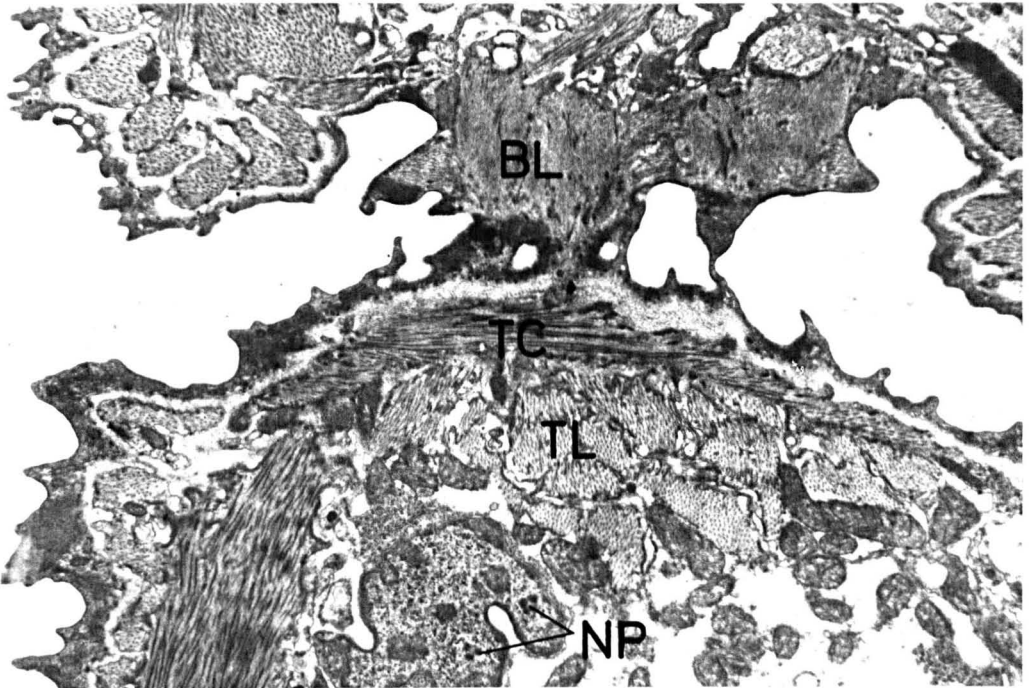
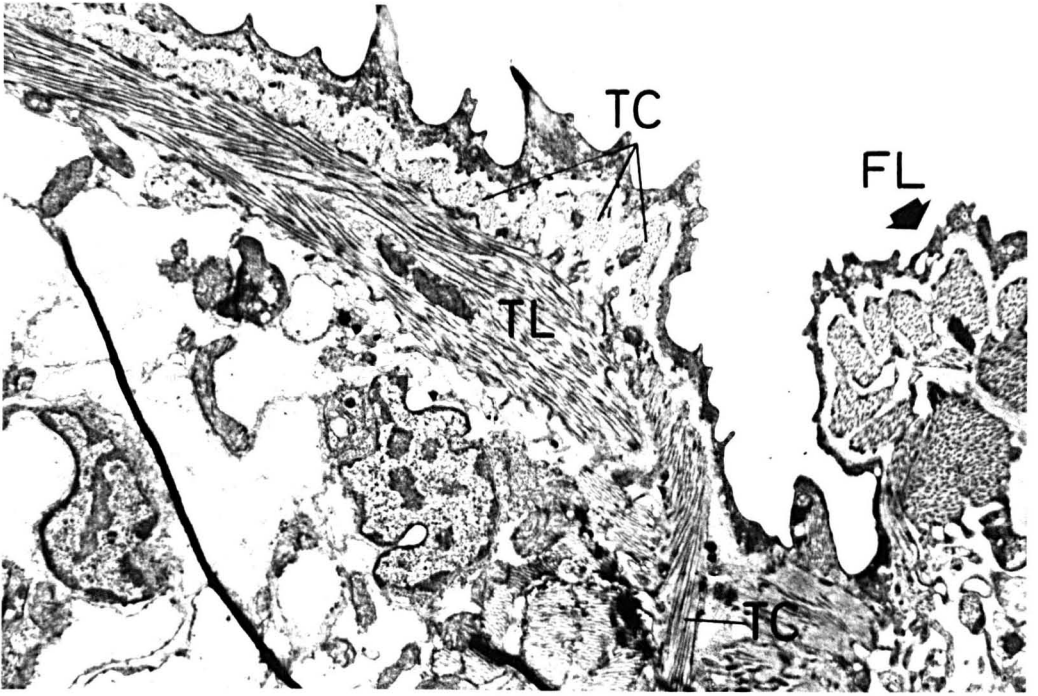


Fig. 42. TS tail showing sarcoplasmic region of a circular fibre. Dense nuclear particles present. X12000.

Fig. 43. LS part of 'thin filament cylinder' of longitudinal body musculature. X38000.

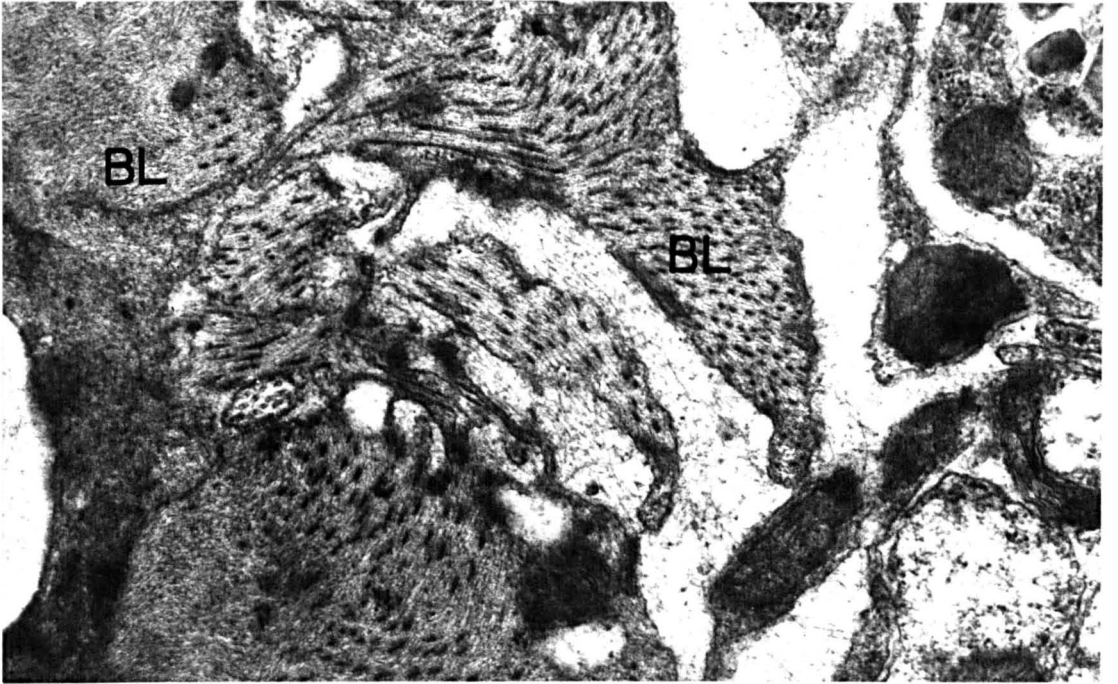
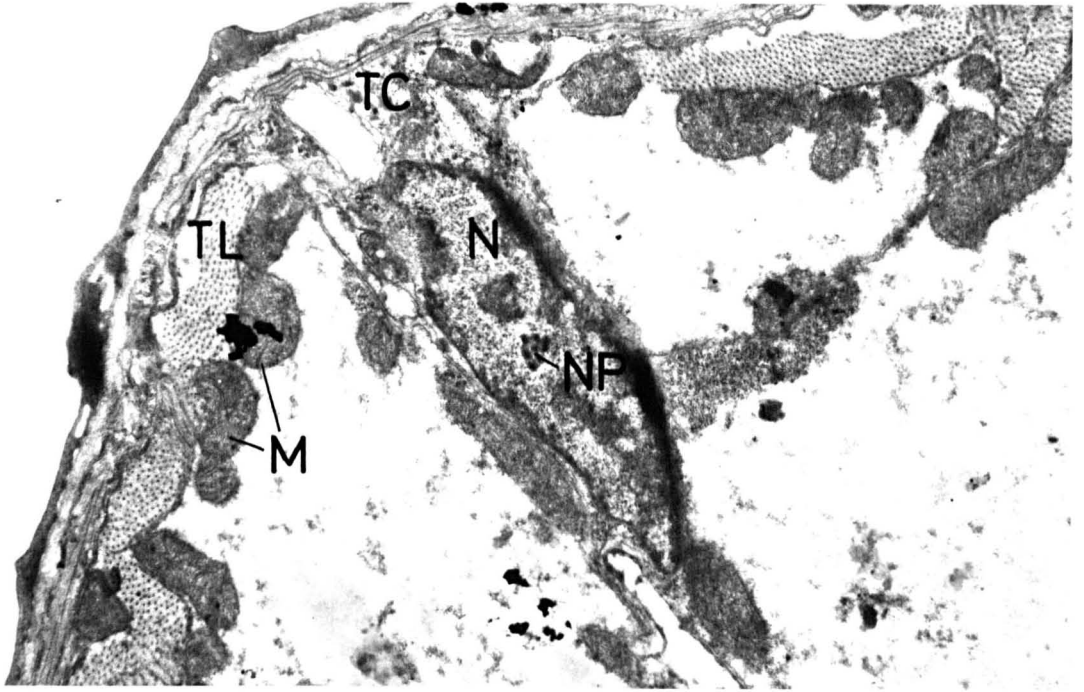


Fig.44. LS tail/body junction showing relationship between excretory bladder and 'thin filament cylinder'. X12000

Fig. 45. LS tail/body junction. Excretory bladder in contracted state. Filament complement of body longitudinal myofibres changes at level of bladder. X8000.

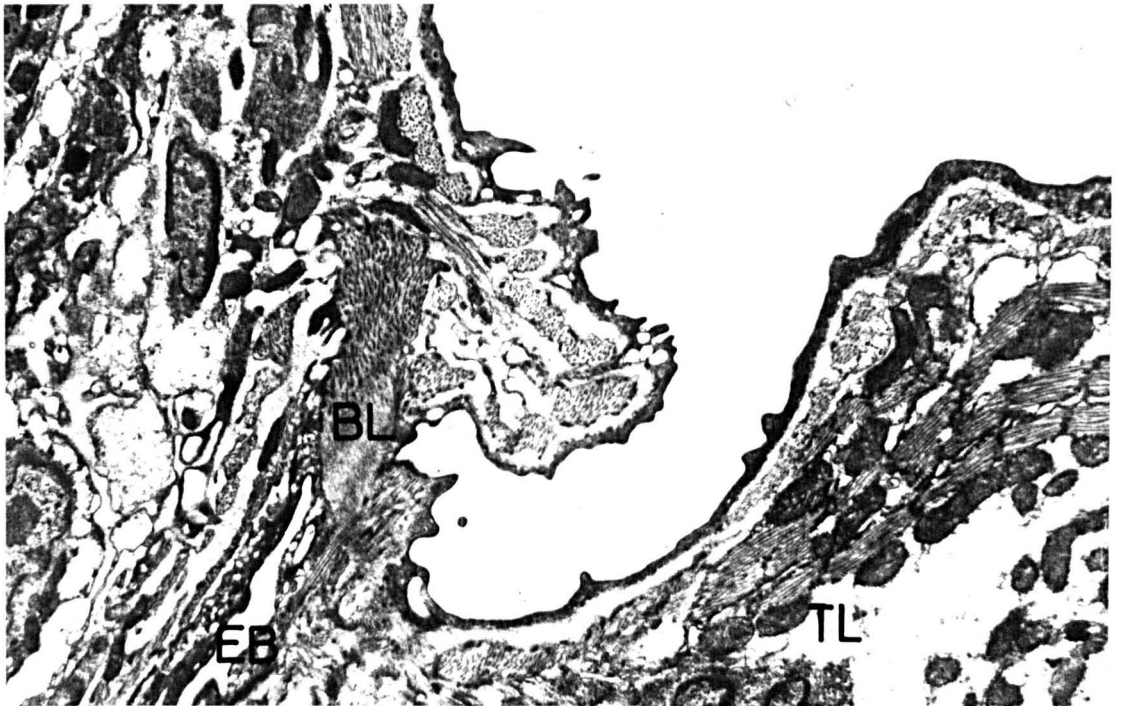
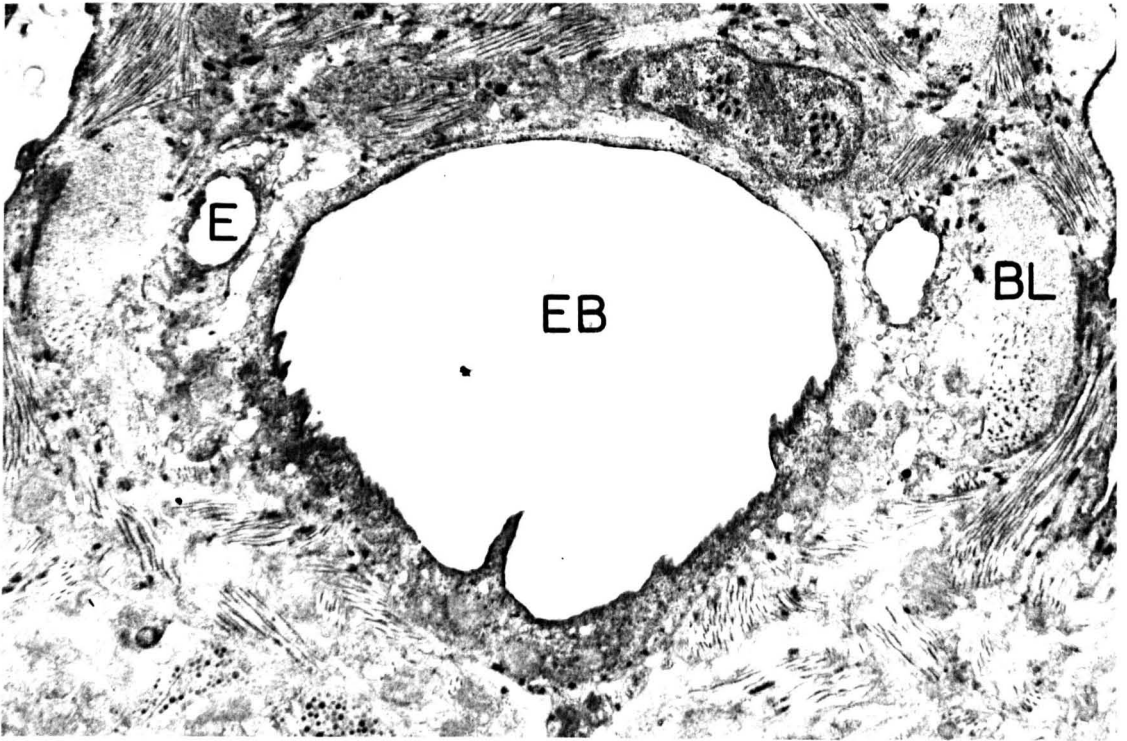
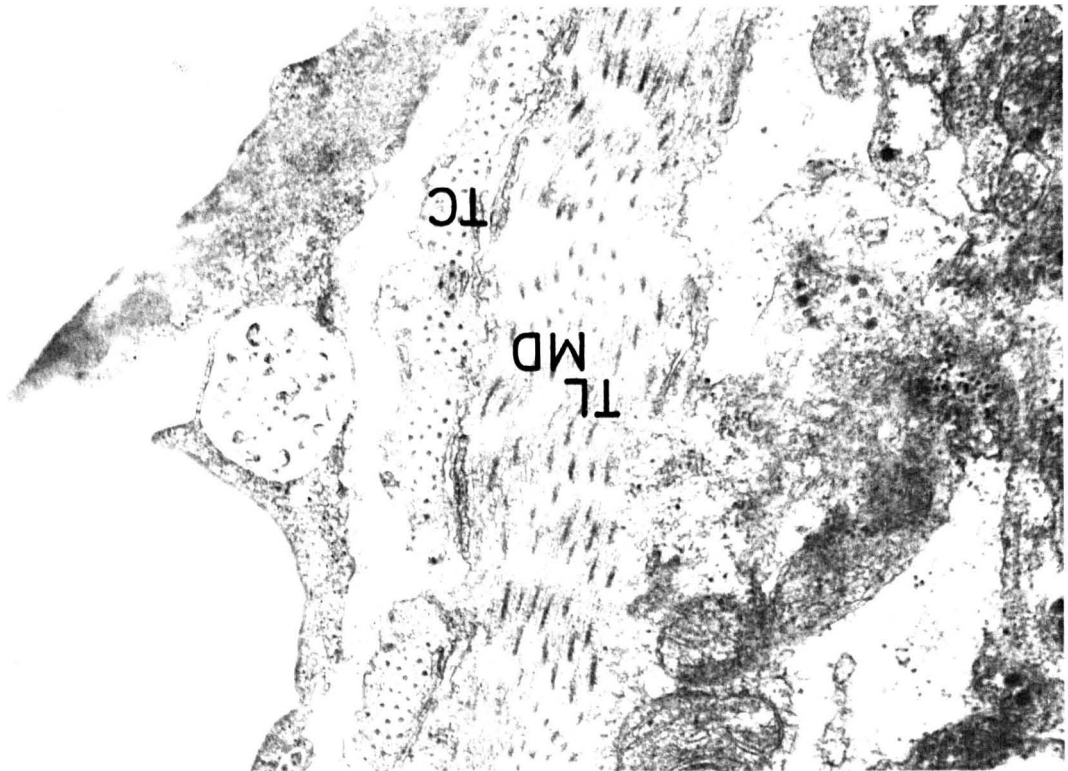
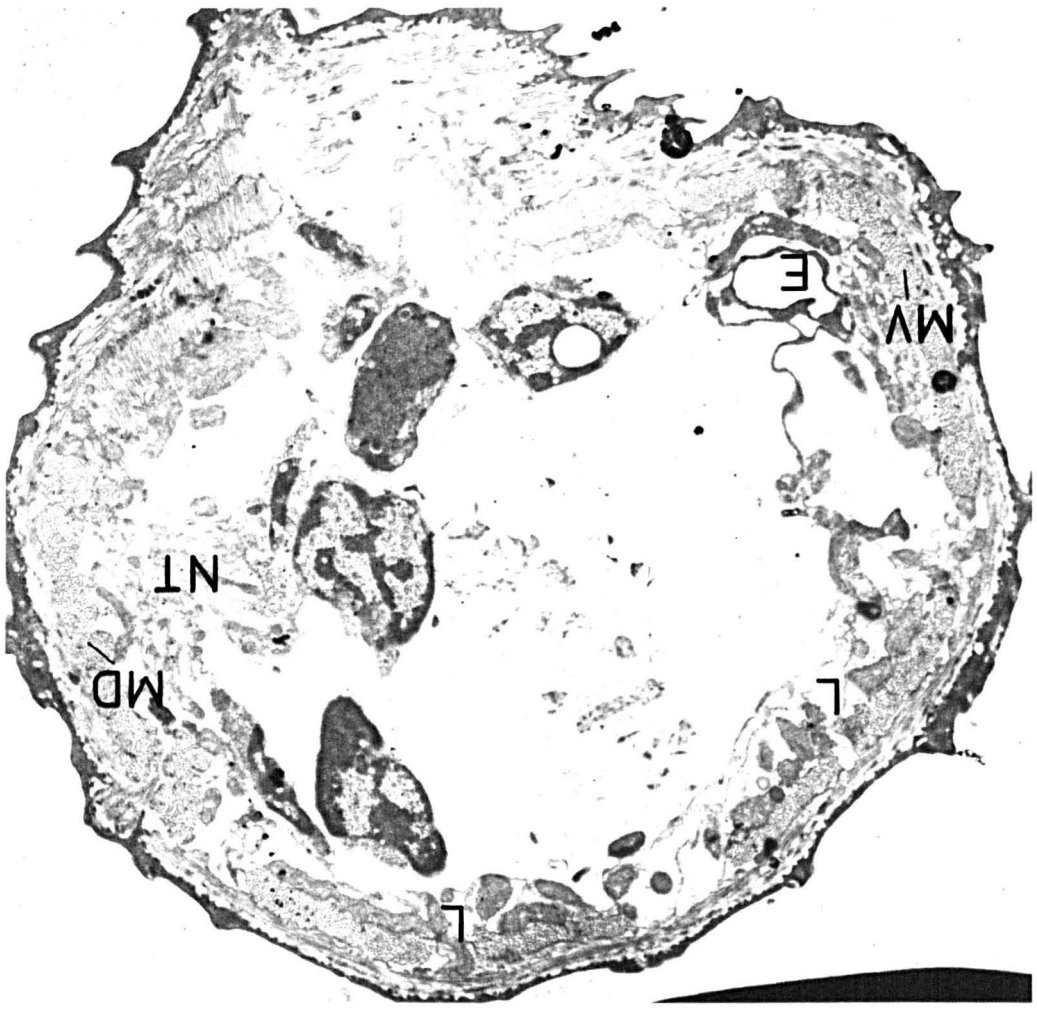


Fig. 46. TS central tail region. Mid-dorsal nerve cord lies beneath dorsal muscle block. Two types of vesicle present in nerves. X23200.

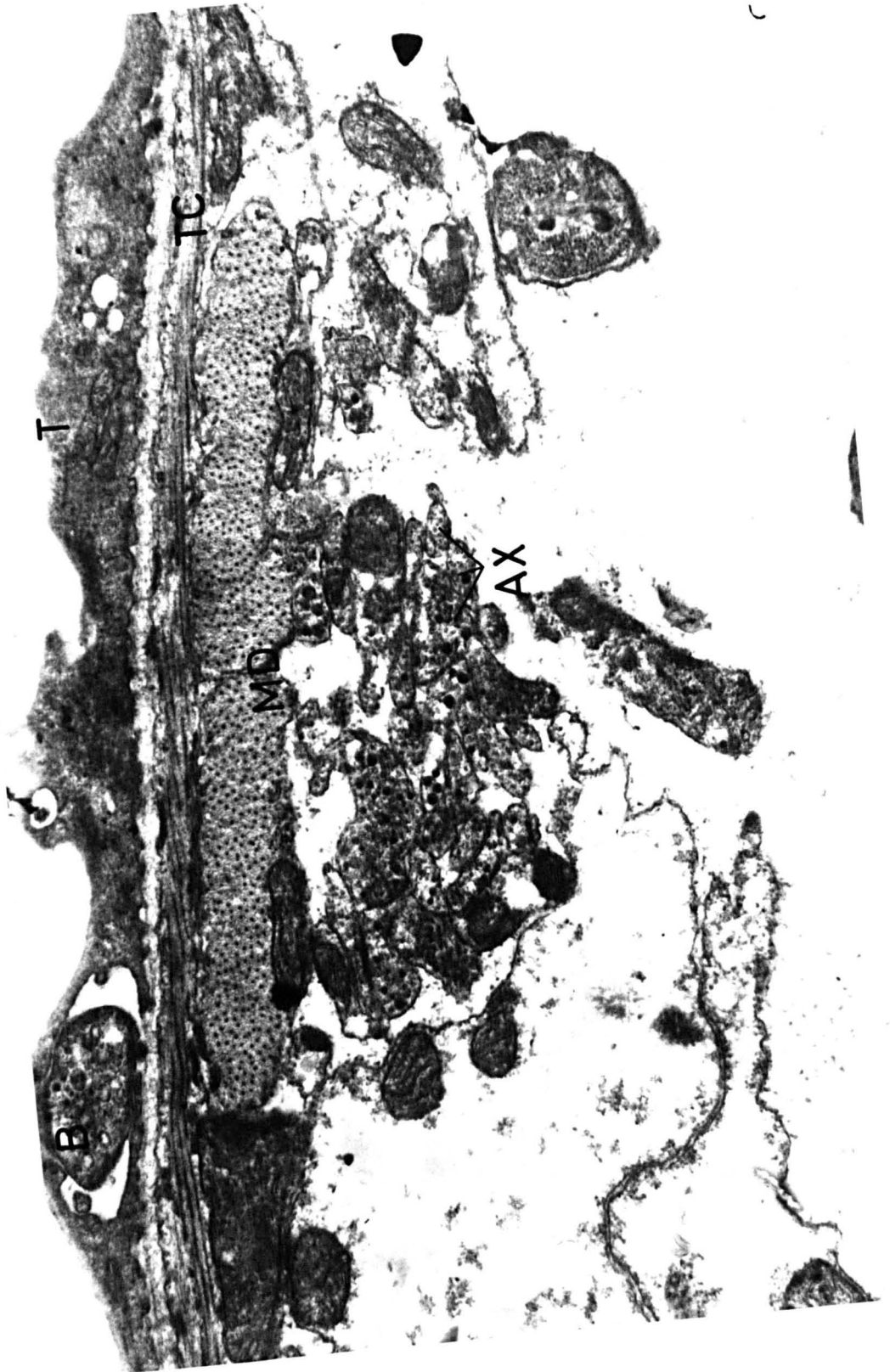

Fig. 47. LS median muscle in tail. No evidence of striation. X38000.

Fig. 48. TS distal tail. Median muscle blocks and nerve cords present, but only two myofibres in each lateral block. X5500.



Figs. 49-50. TS distal tail in region of bifurcation of excretory duct.

Nerve and muscle organization similar to that in Fig. 50.

X5500.

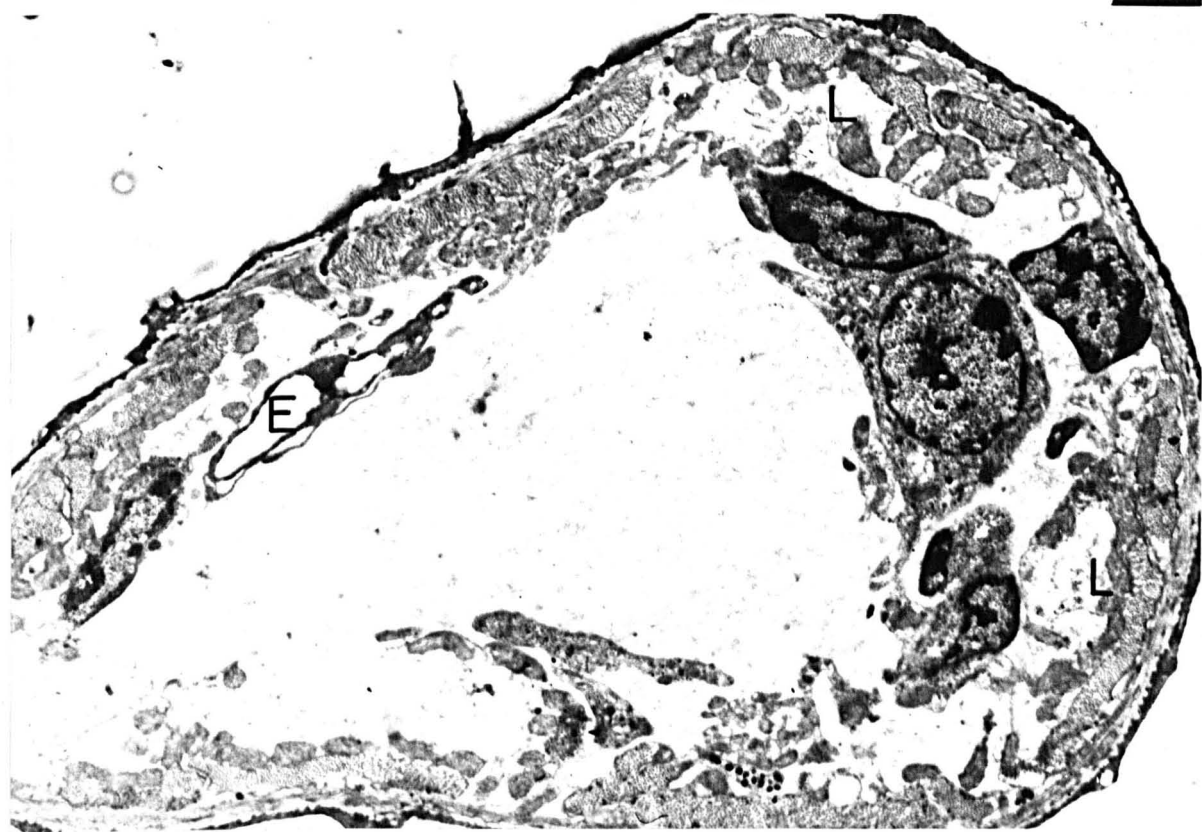
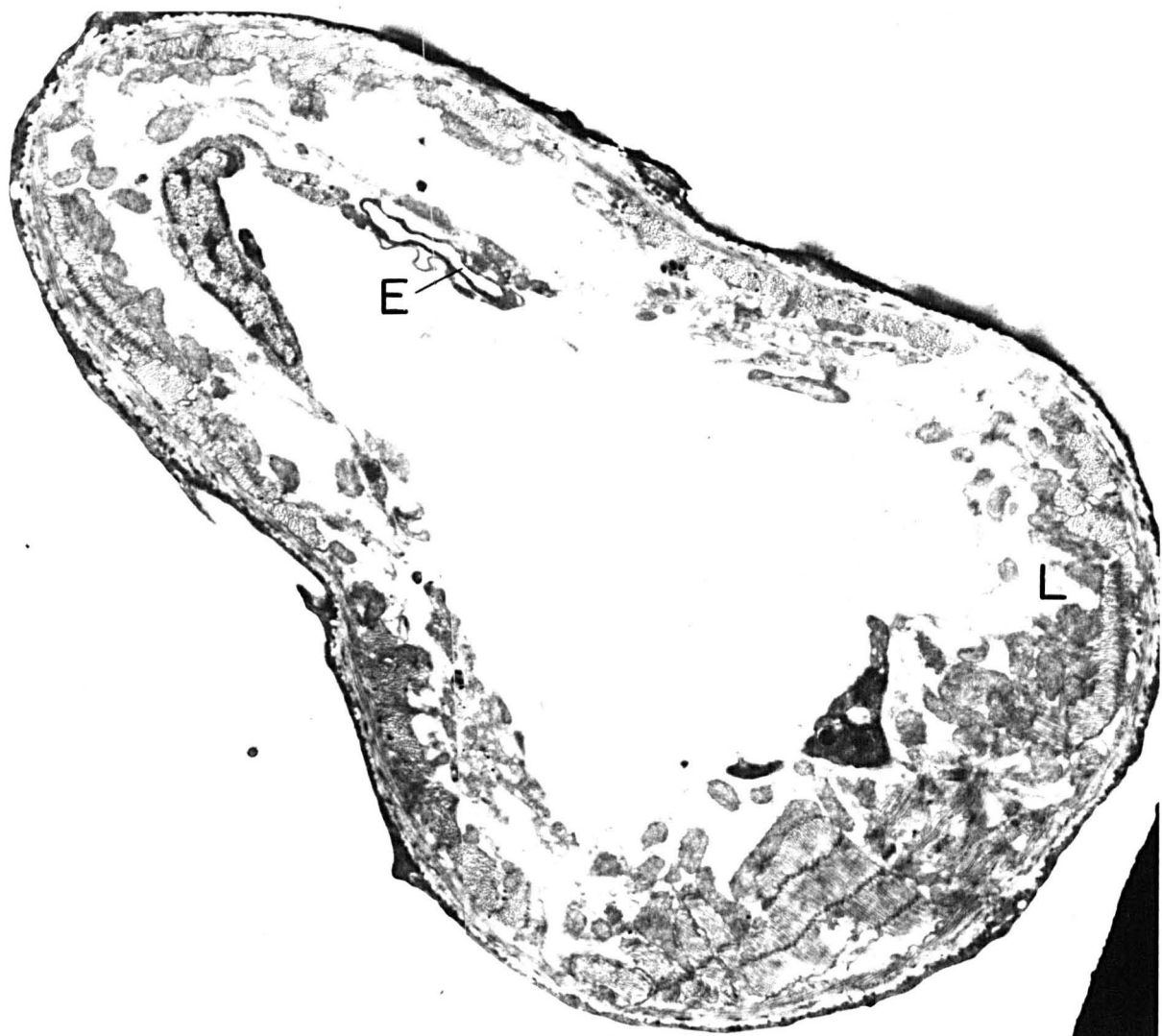
Fig. 51. TS distal tail, posterior to bifurcation of excretory duct. Nerve cord has also divided laterally. Prominent lateral muscle blocks absent. Oblique myofibres dorsally and ventrally. X10600.

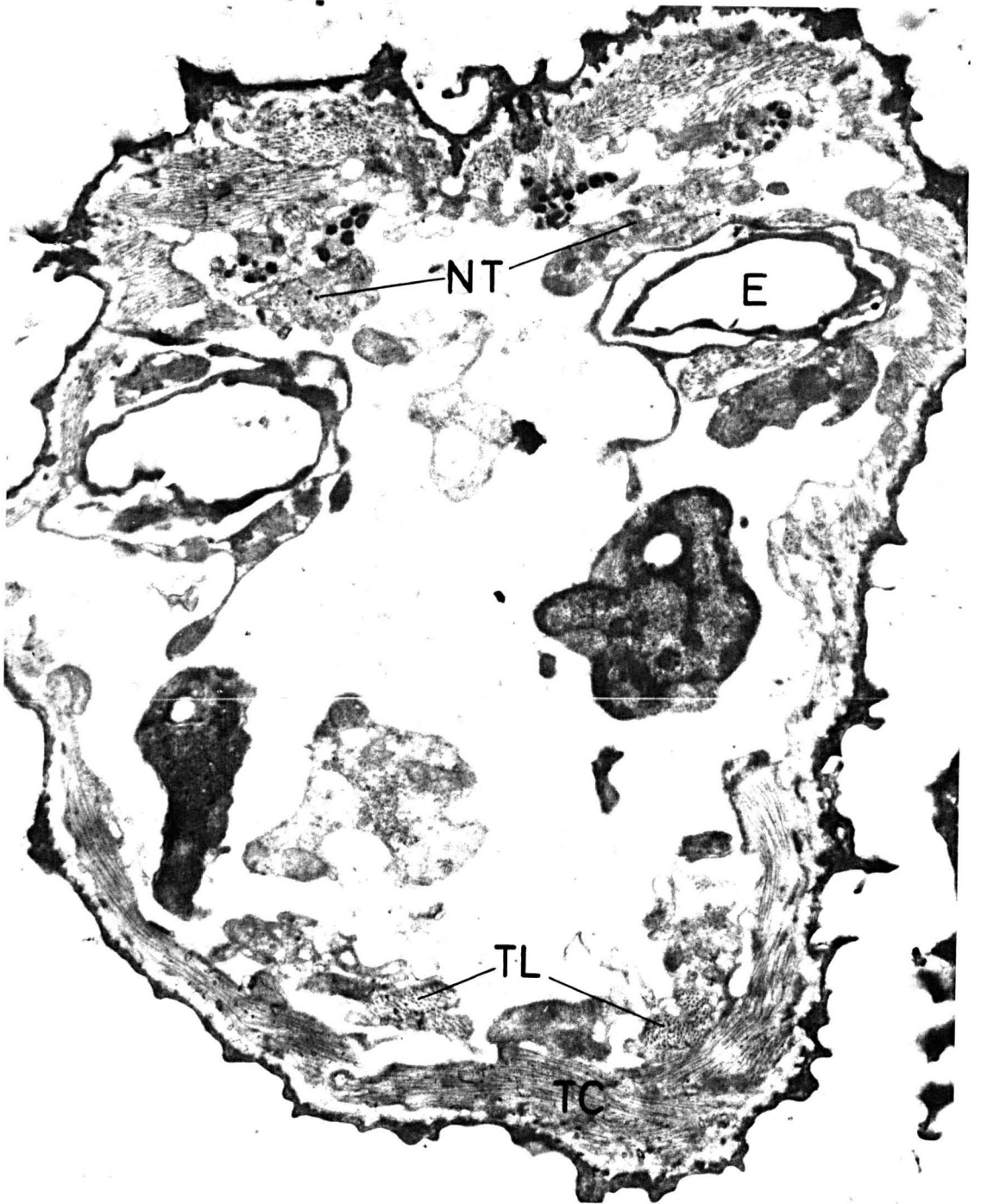


Fig. 52. TS distal tail, similar region to Fig. 53. Oblique myofibres above excretory ducts. X7000.

Fig. 53. TS median musculature of distal tail. Longitudinal myofibres lie above the two nerve cords. Obliquely orientated fibres also present. X16000.

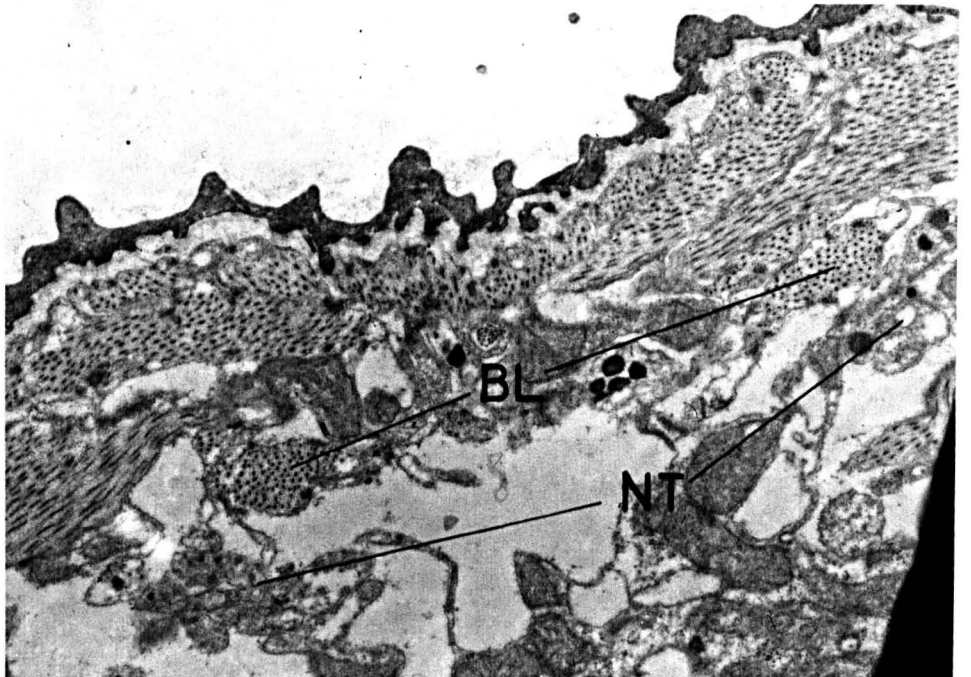
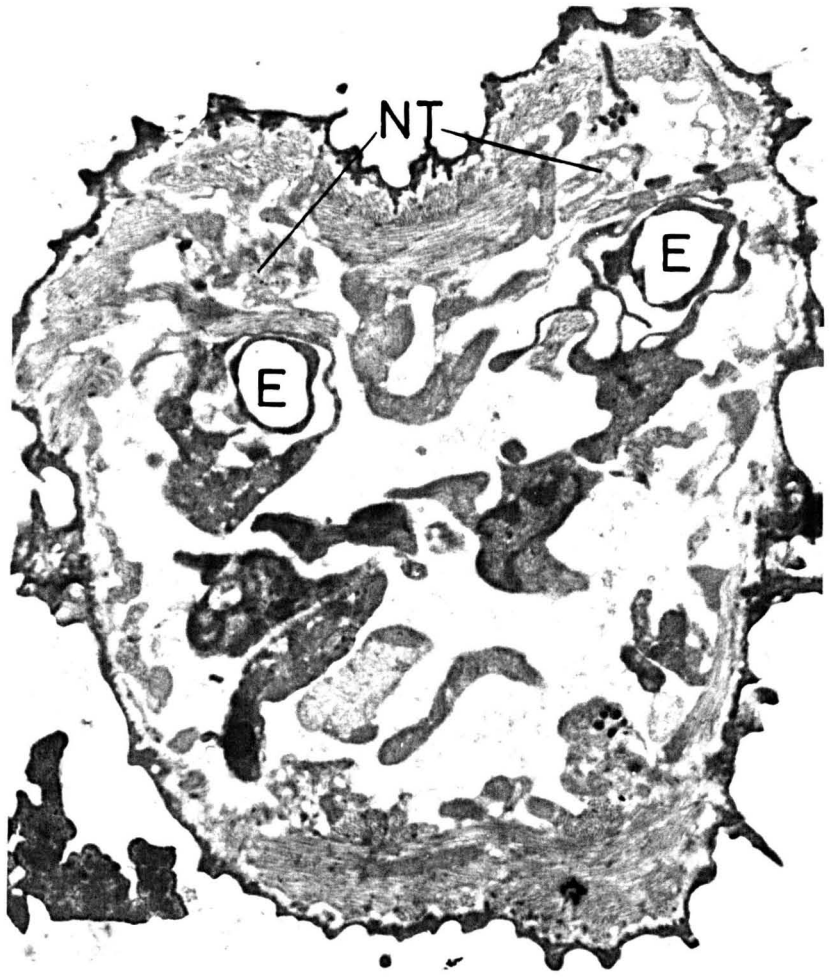


Fig. 54. Oblique TS central region of tail. A median and a lateral muscle block are shown, consisting of two and five myofibres respectively. X8000.

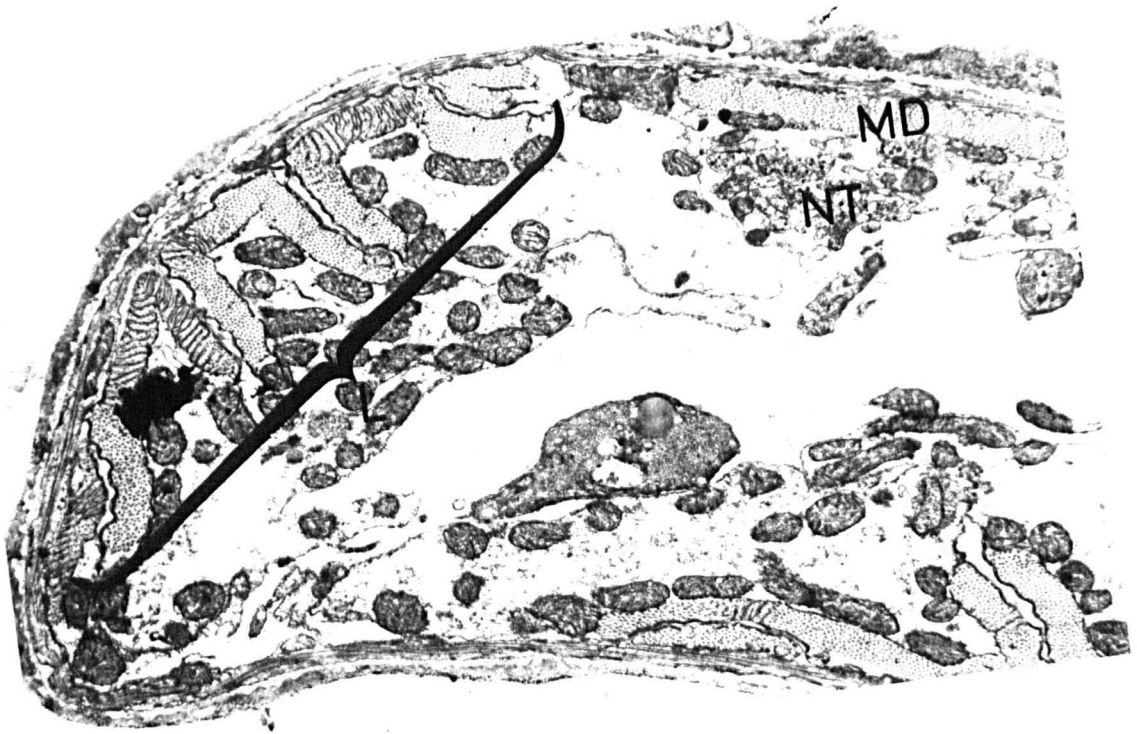


Fig. 55. TS part of one lateral muscle block. A transverse membrane system visible within each fibre. X23200.

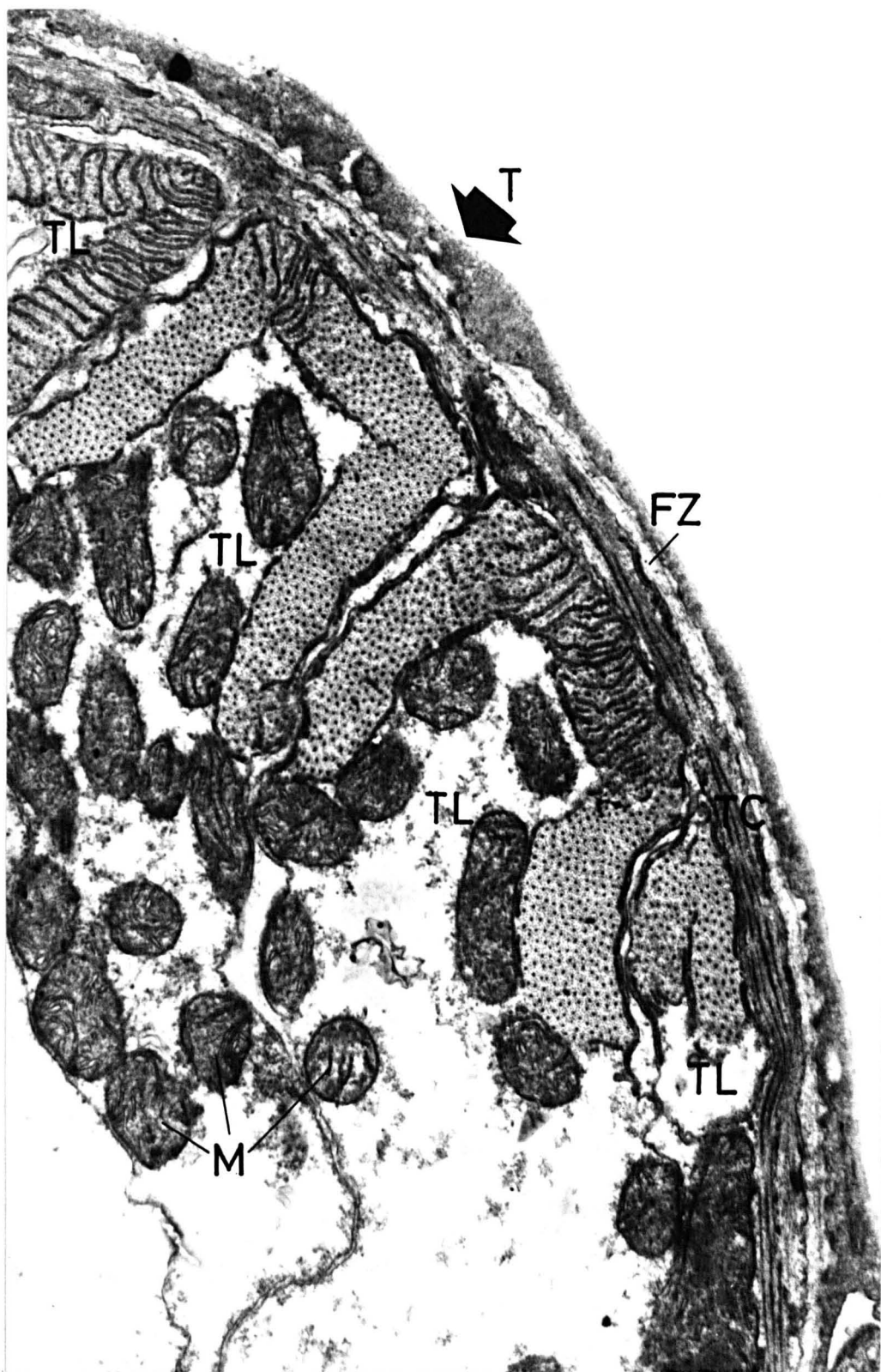


Fig. 56. TS lateral muscle block. Membrane system appears concentrically arranged at one side of fibre. Longitudinal tubules also visible. X24000.

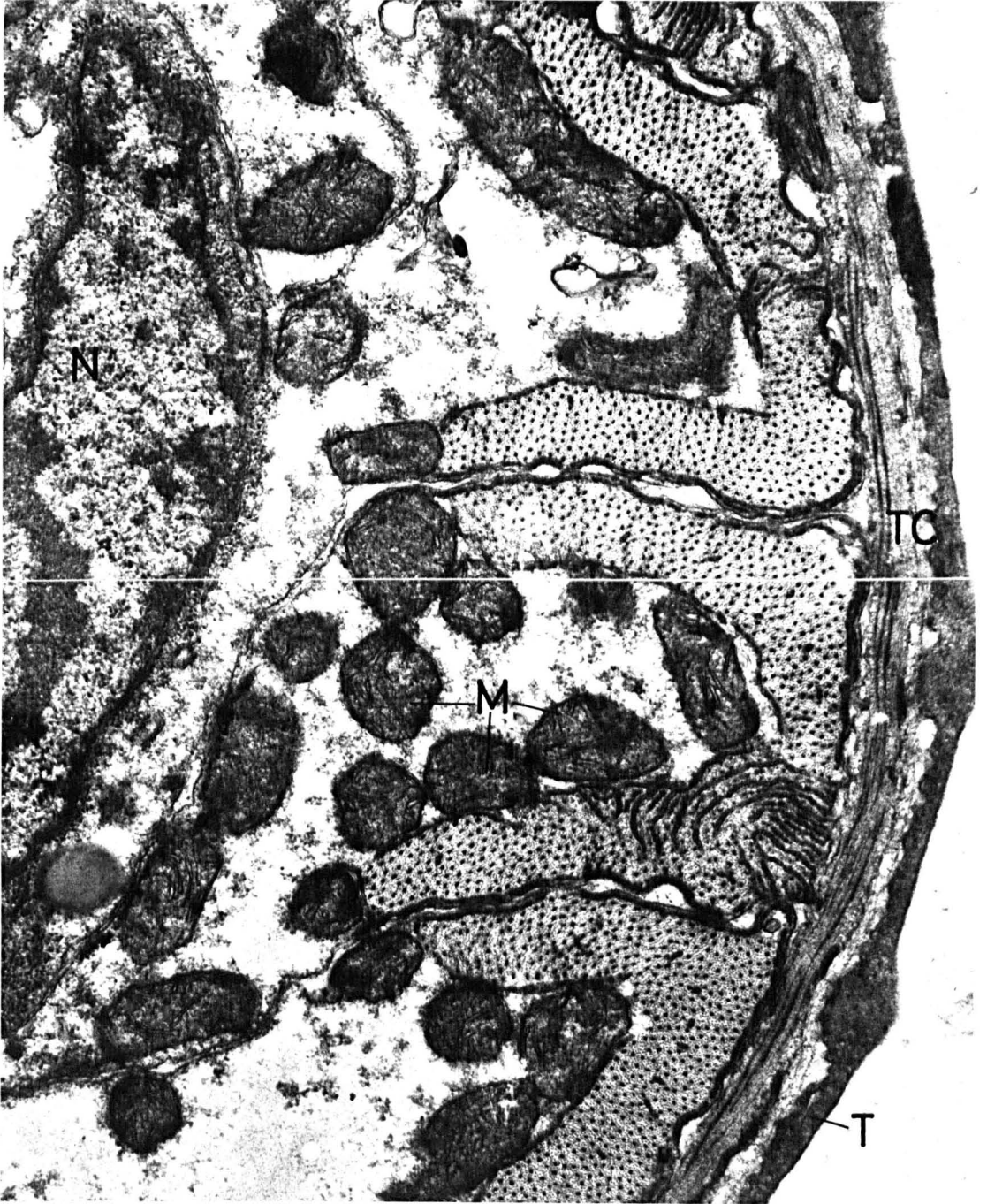


Fig. 57. TS lateral muscle block. Adjacent tubules are continuous at edge of filamentous region. X38000.

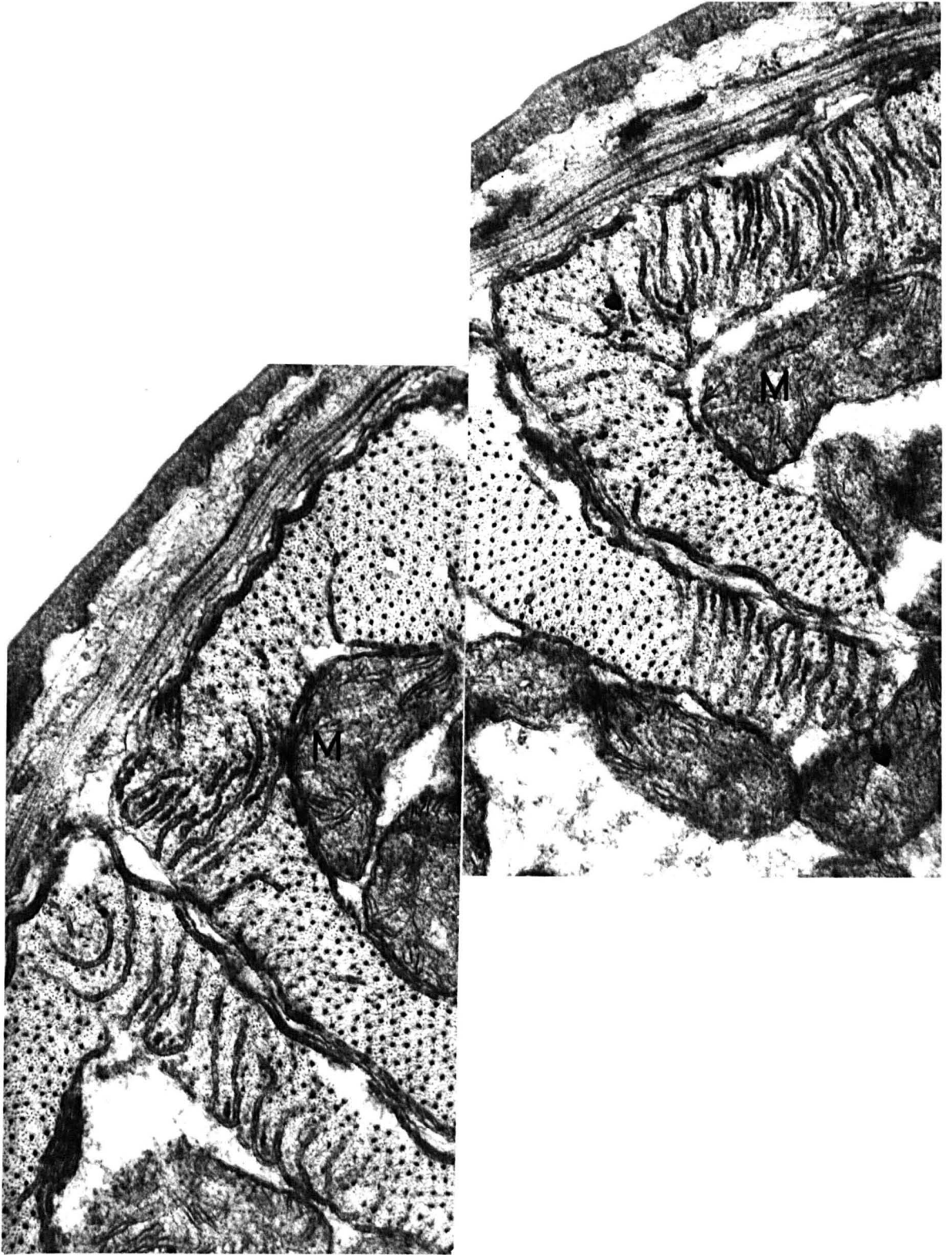


Fig. 58. Light micrograph of whole mount. Oblique striation visible.

Fig. 59. Light micrograph of whole mount. Striation at right angles to that in Fig. 60.

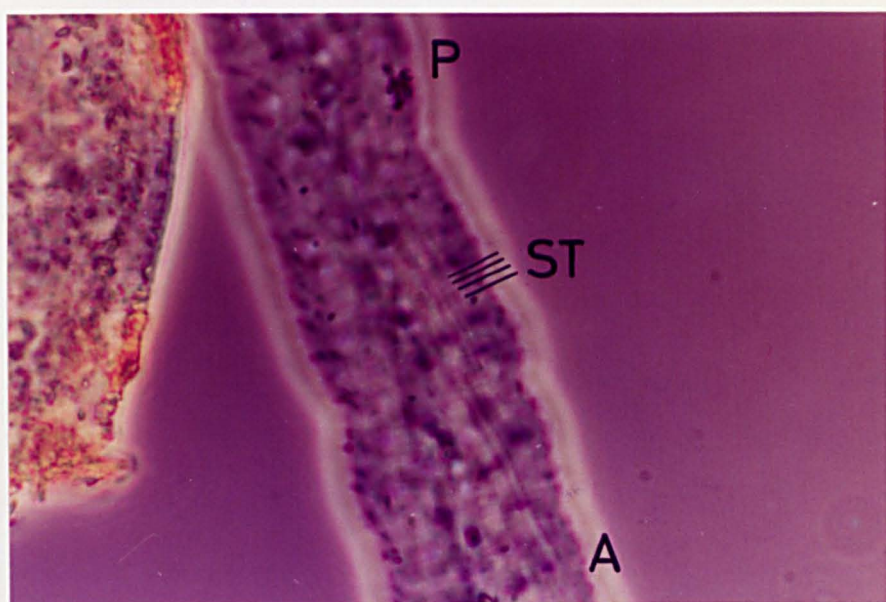
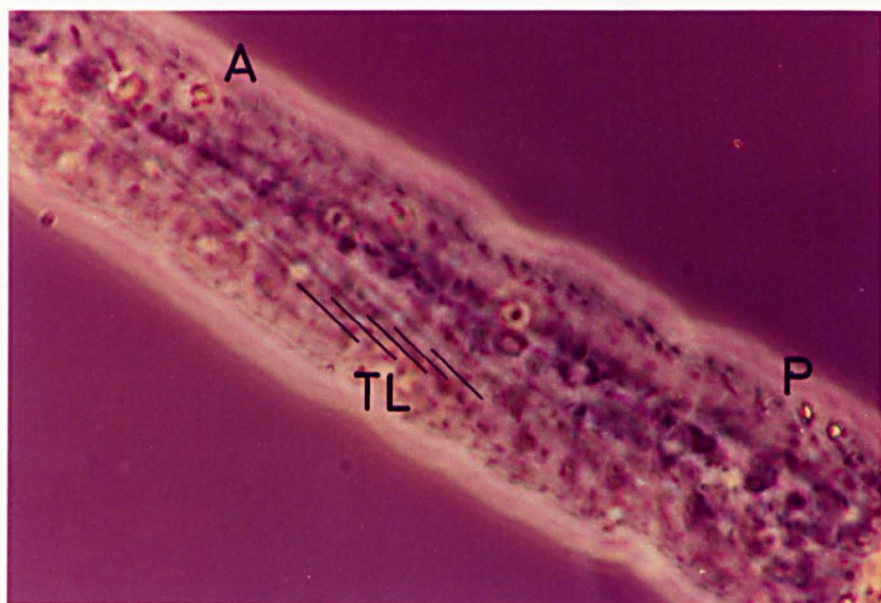


Fig. 60. Light micrograph of LS of base of tail. Expanded excretory bladder and caudal flame cell seen. Striations of longitudinal musculature can be discerned.

Fig. 61. Light micrograph of LS of base of tail. Transverse striations seen.

Fig. 62. LS lateral muscle block. Adjacent sarcolemmas interdigitate. Mitochondria numerous and associated with contractile regions. X8000.

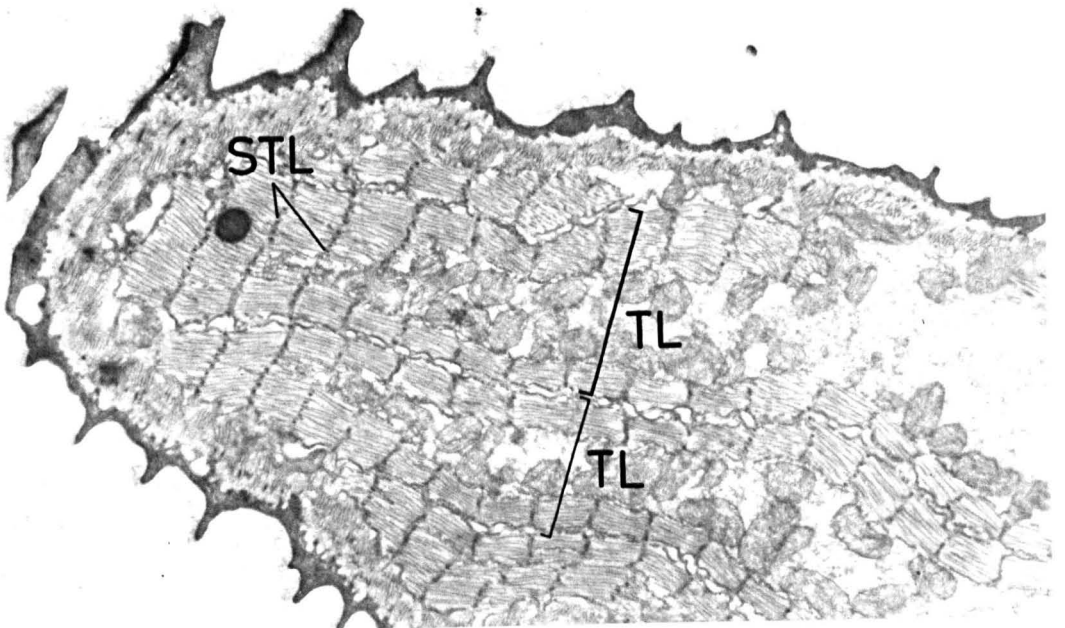
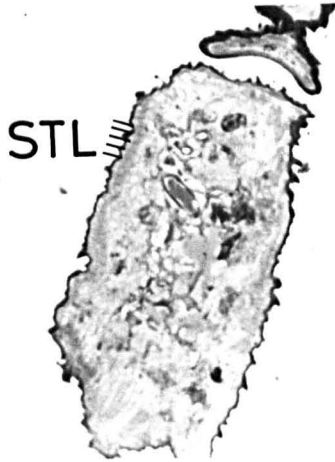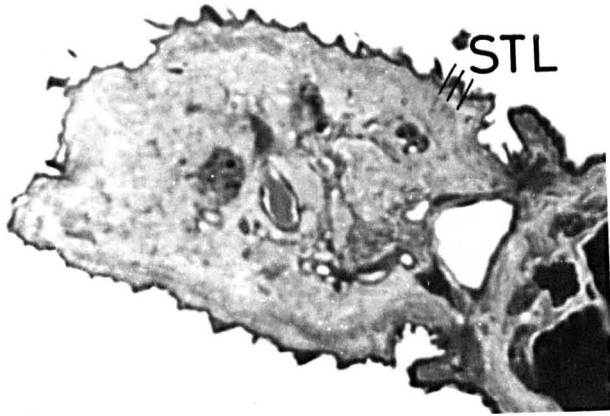


Fig. 63. LS lateral muscle block. Note the frequent, but not invariable alignment of striations in adjacent myofibres. X14400.

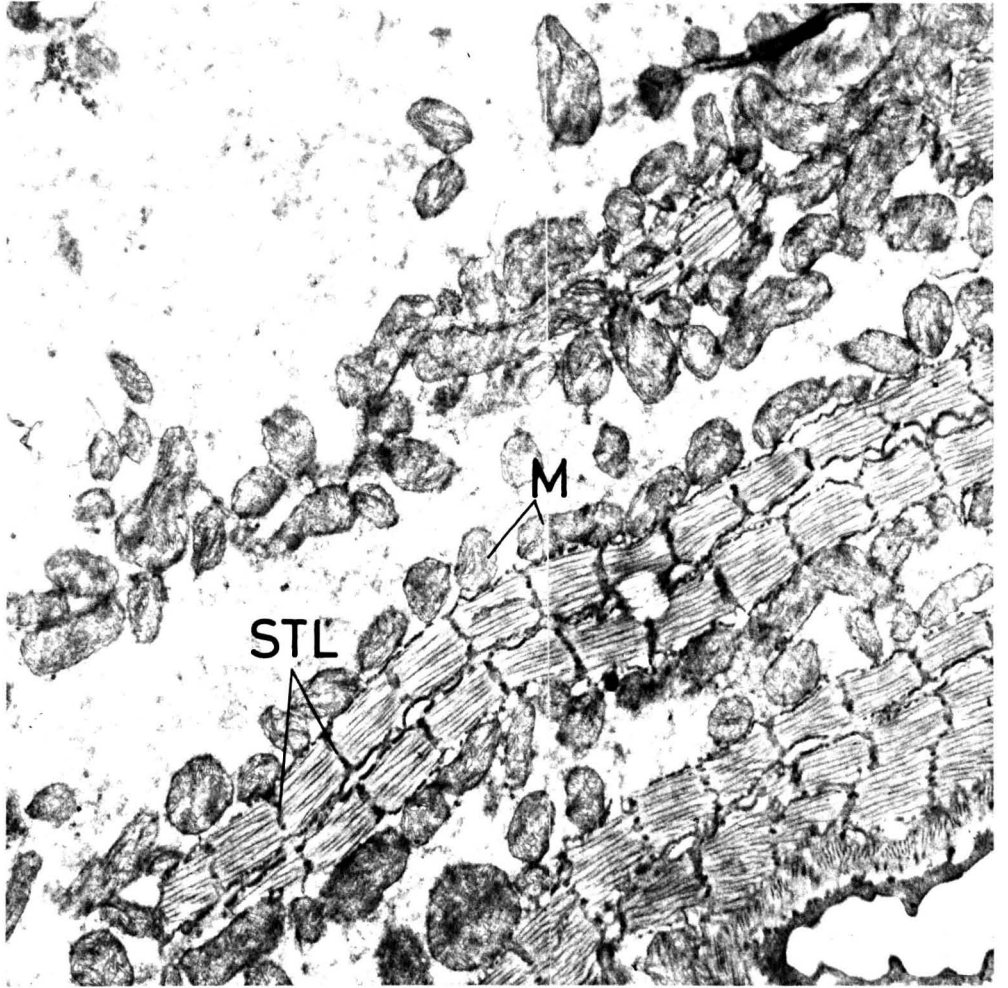


Fig. 64. LS lateral myofibre. Striation composed of alternating dense and membranous elements. X50000.

Fig. 65. LS striation in lateral myofibre. X133000.

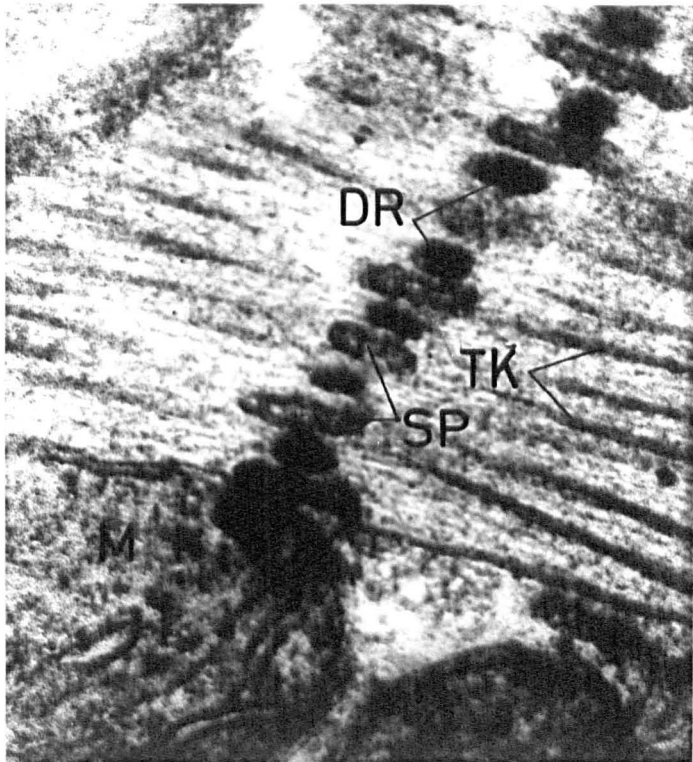
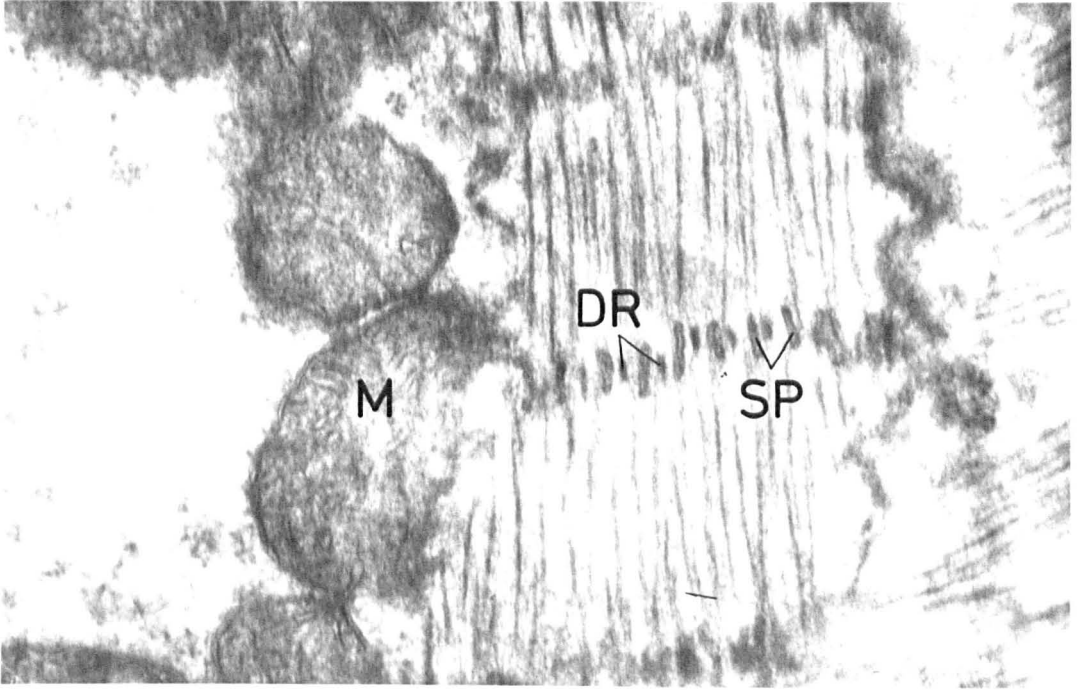


Fig. 66. TS striation in lateral myofibre. Dense bodies extend inwards from sarcolemma to interdigitate with tubules of sarcoplasmic reticulum. Thick and thin myofilaments clearly shown in TS. X38000.

Fig. 67. TS striation in lateral myofibre. Elements of striation appear in different location from that in Fig. 68. X38000.

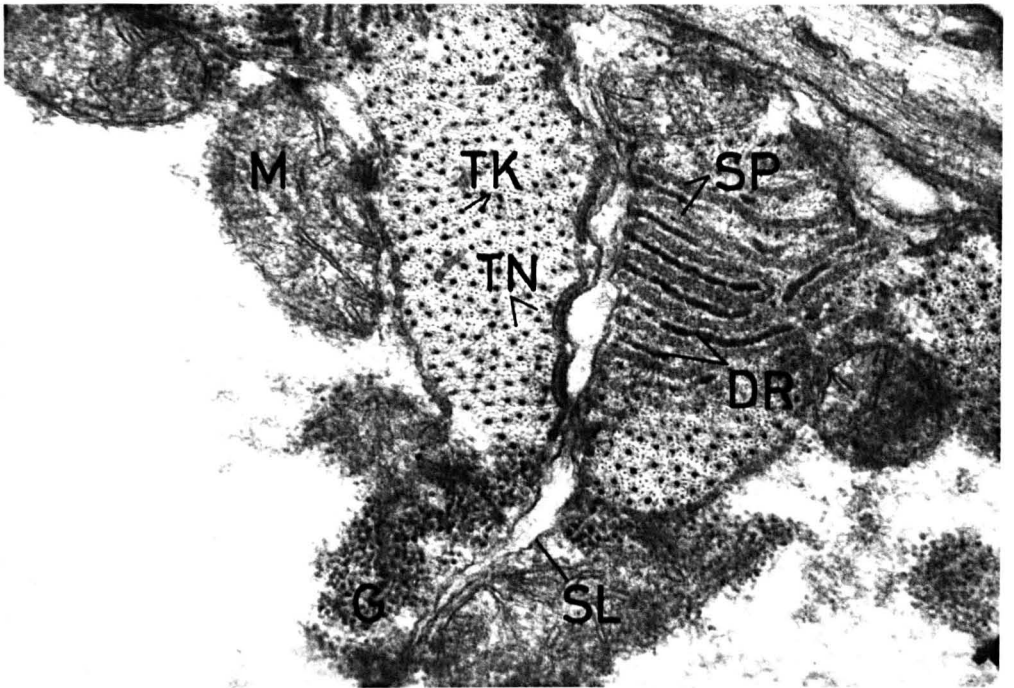
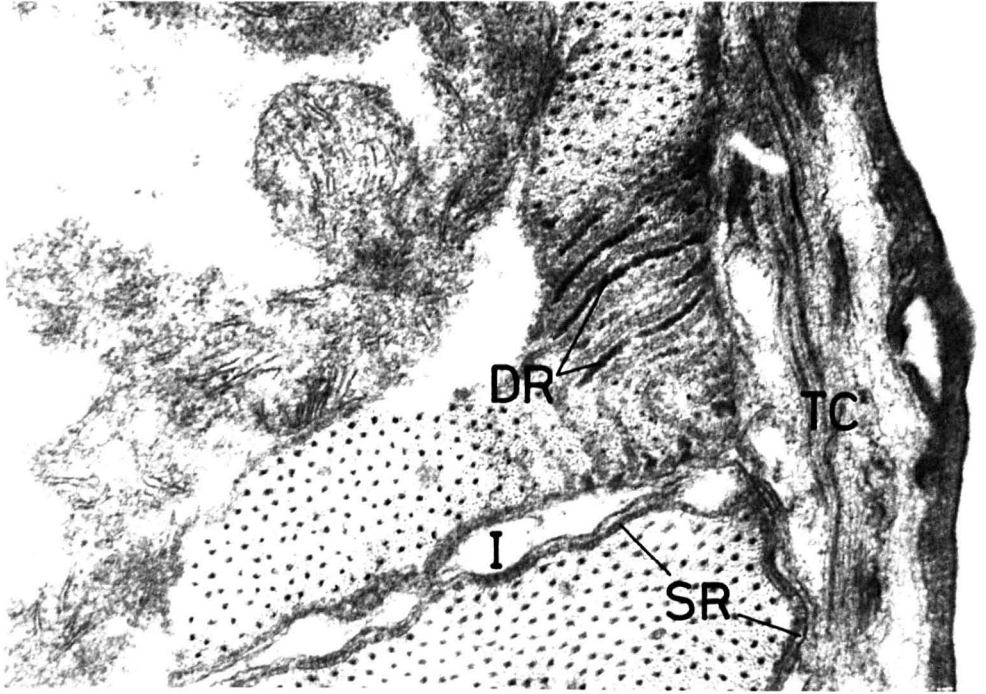


Fig. 68. TS striation in lateral myofibre. Section is slightly oblique, passing through centre of striation (at asterisk) and also through adjacent area of sarcomere, containing mainly thin filaments. Note close contact between adjacent fibres, by interdigitation. X91000.

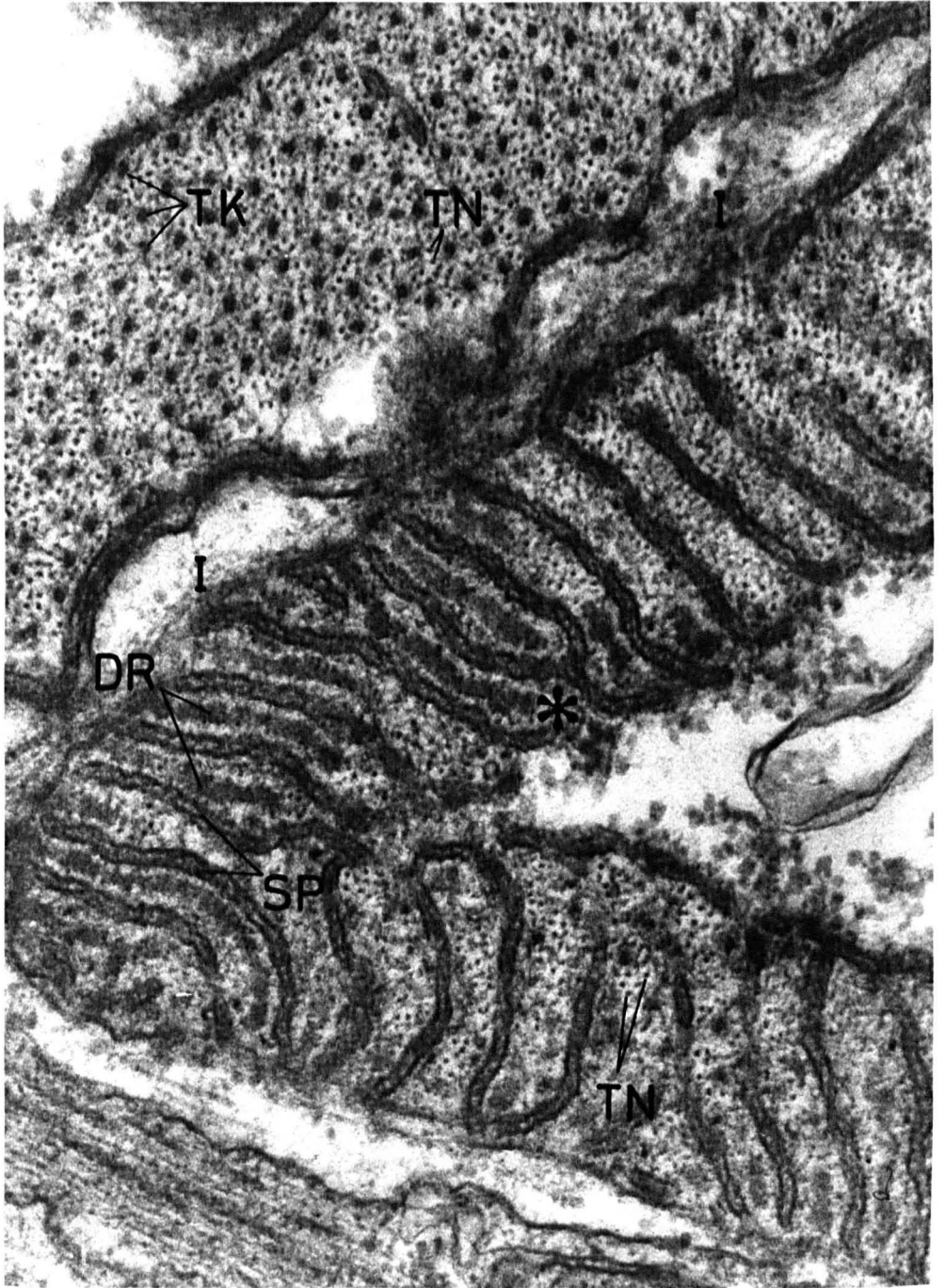


Fig. 69. LS sarcomeres of striated myofibre. Dense body attached to sarcolemma and continuous with thin myofilaments. X42500.

Fig. 70. LS base of tail, passing through part of a lateral muscle block. Note large 'clear' areas in tail 'core' and small but dense accumulations of glycogen granules. X8000.

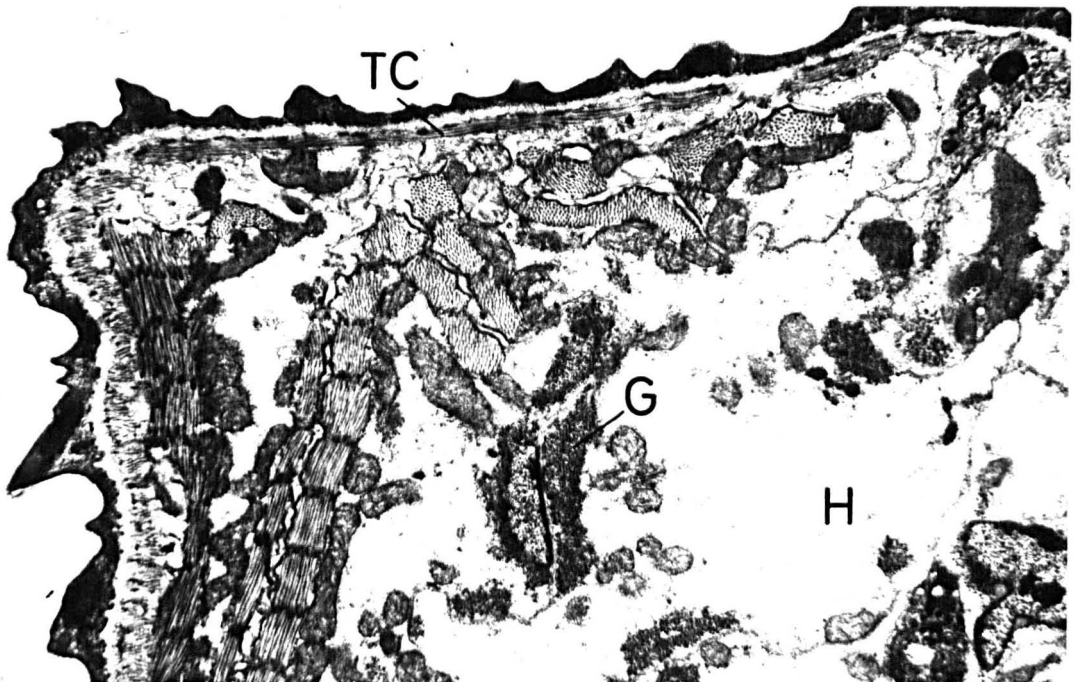
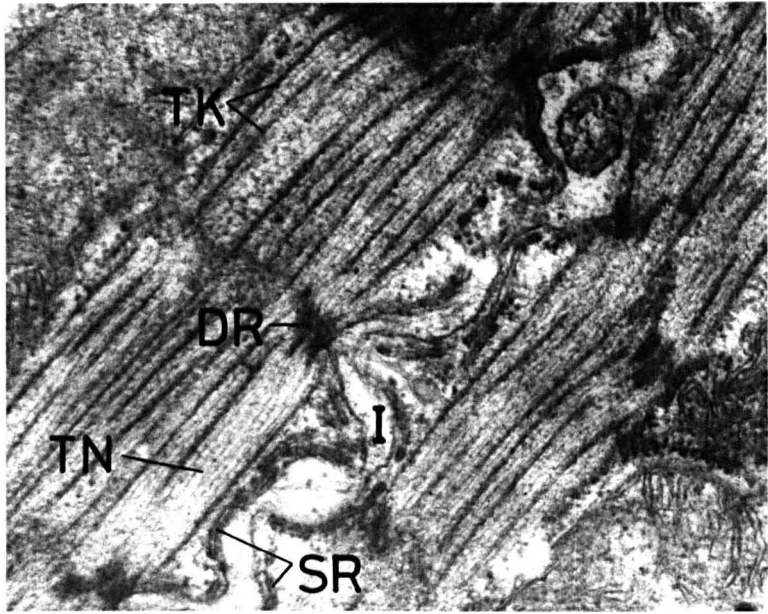


Fig. 71. TS tail stem. Glycogen granules clumped near nucleus and also in clear areas of tail core. X12000.

Fig. 72. TS tail stem. Glycogen granules at periphery of longitudinal cell and also within circular muscle. X38000.

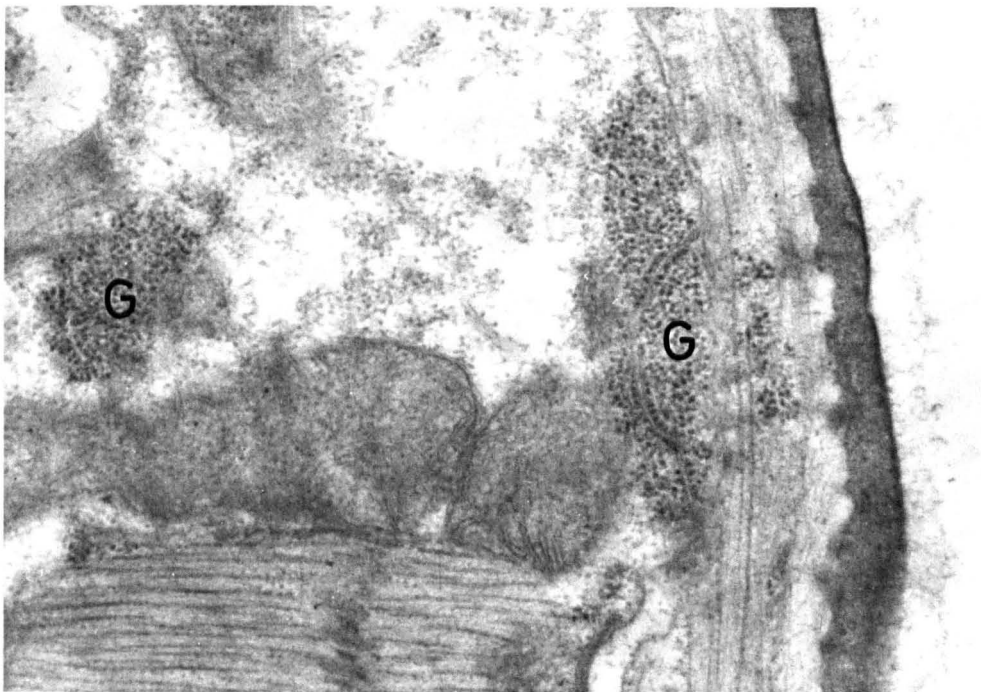
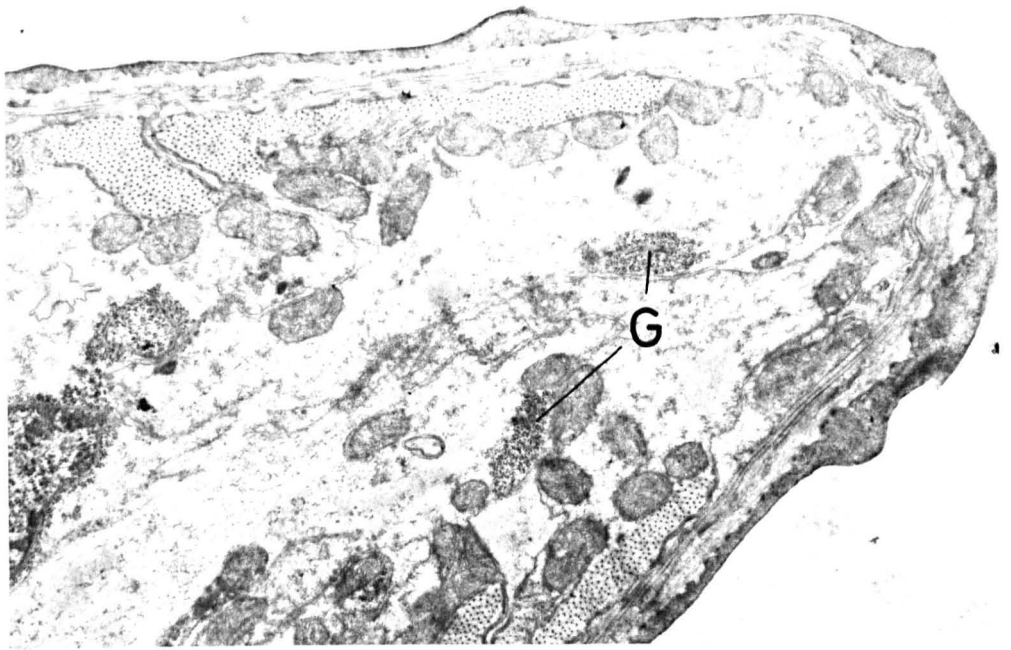


Fig. 73. Nucleus in tail stem surrounded by glycogen granules. X3400.

Fig. 74. TS tail stem. Note large mitochondria, with many internal cristae, associated with striated myofibres. X20000.

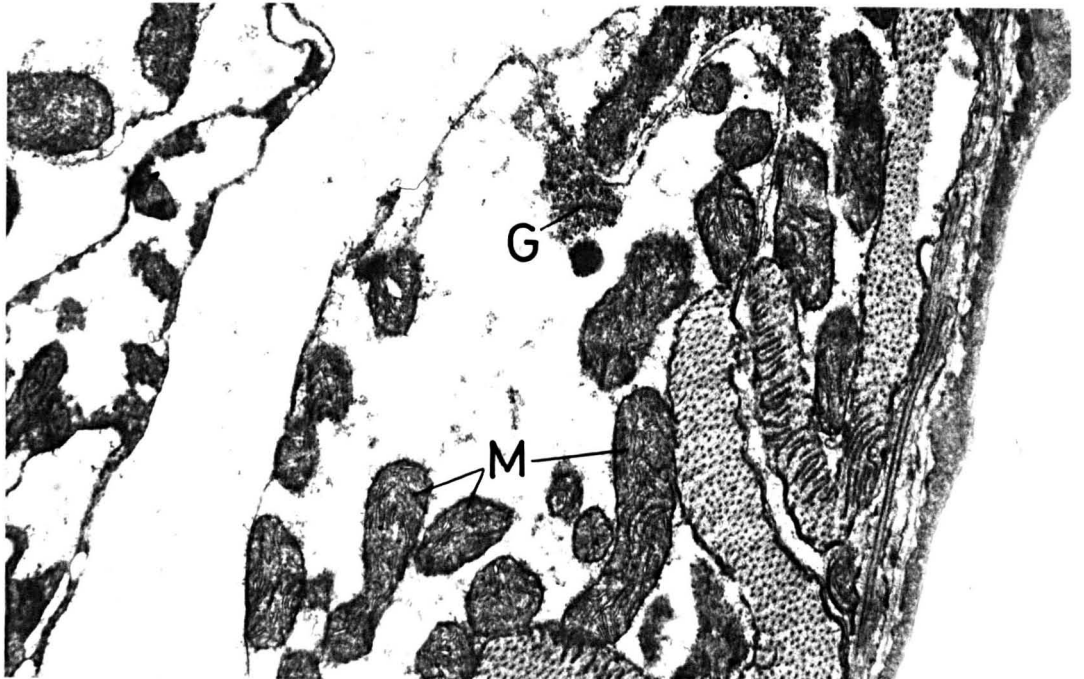
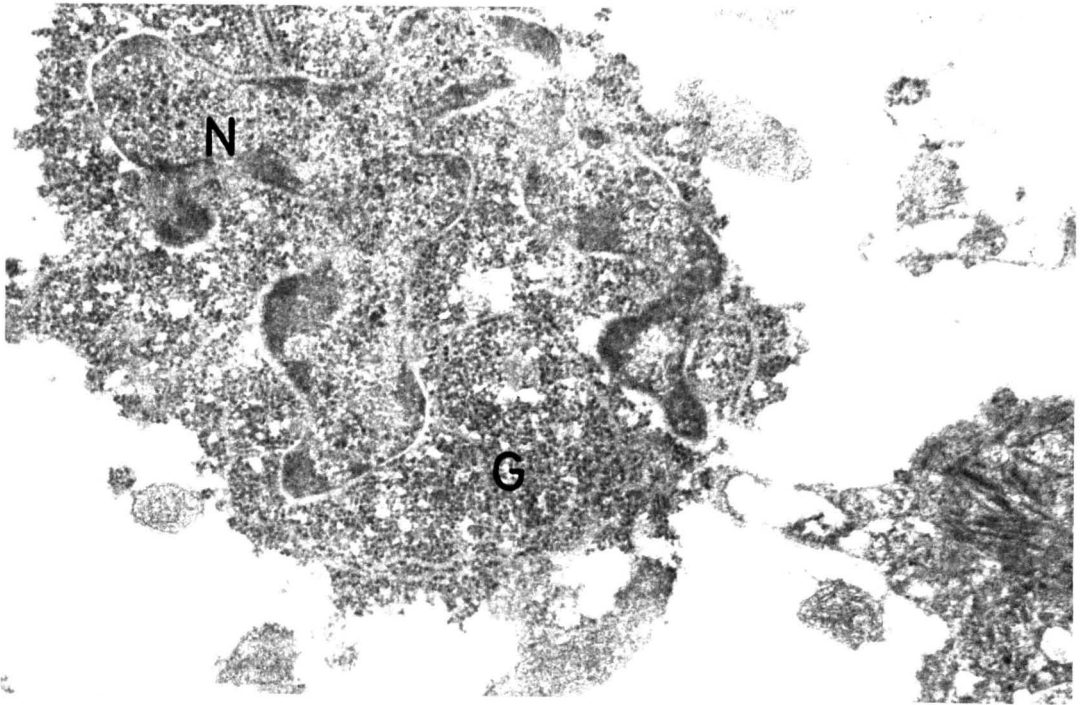


Fig. 75. LS tail stem. Mitochondria closely applied to contractile region of fibre. X 12600.

Fig. 76. TS apposed furcae to show general distribution of tissue. Muscle is mainly peripheral, excretory canals central. X4000.

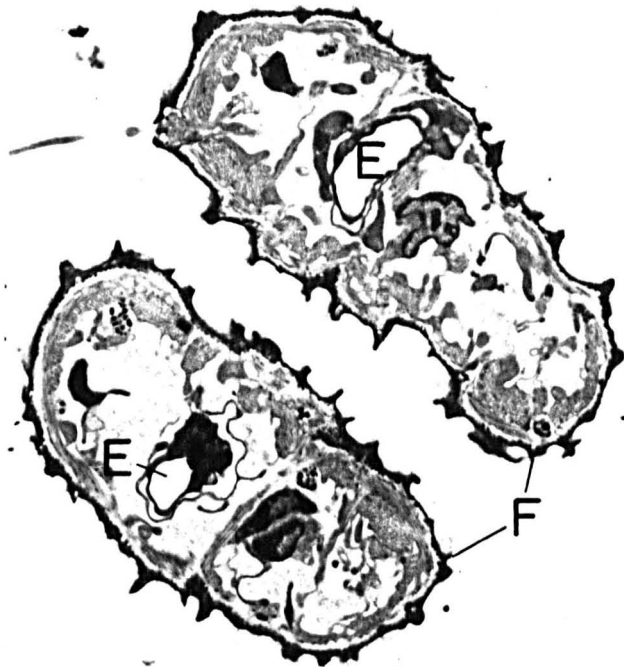
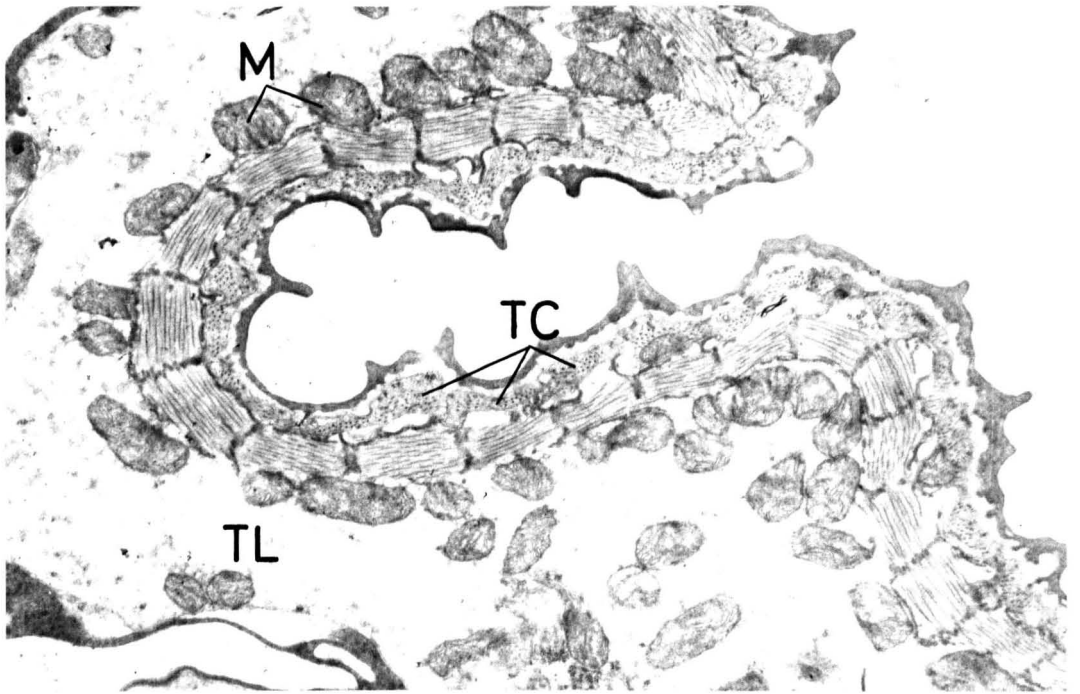


Fig. 77. TS furca. Longitudinal myofibres appear larger on posterior face of furca. Transverse ribbons of muscle pass from anterior to posterior faces. Nerve bulb in tegument possesses long terminal cilium. Note large accumulation of dense particles in nucleus. X12000.

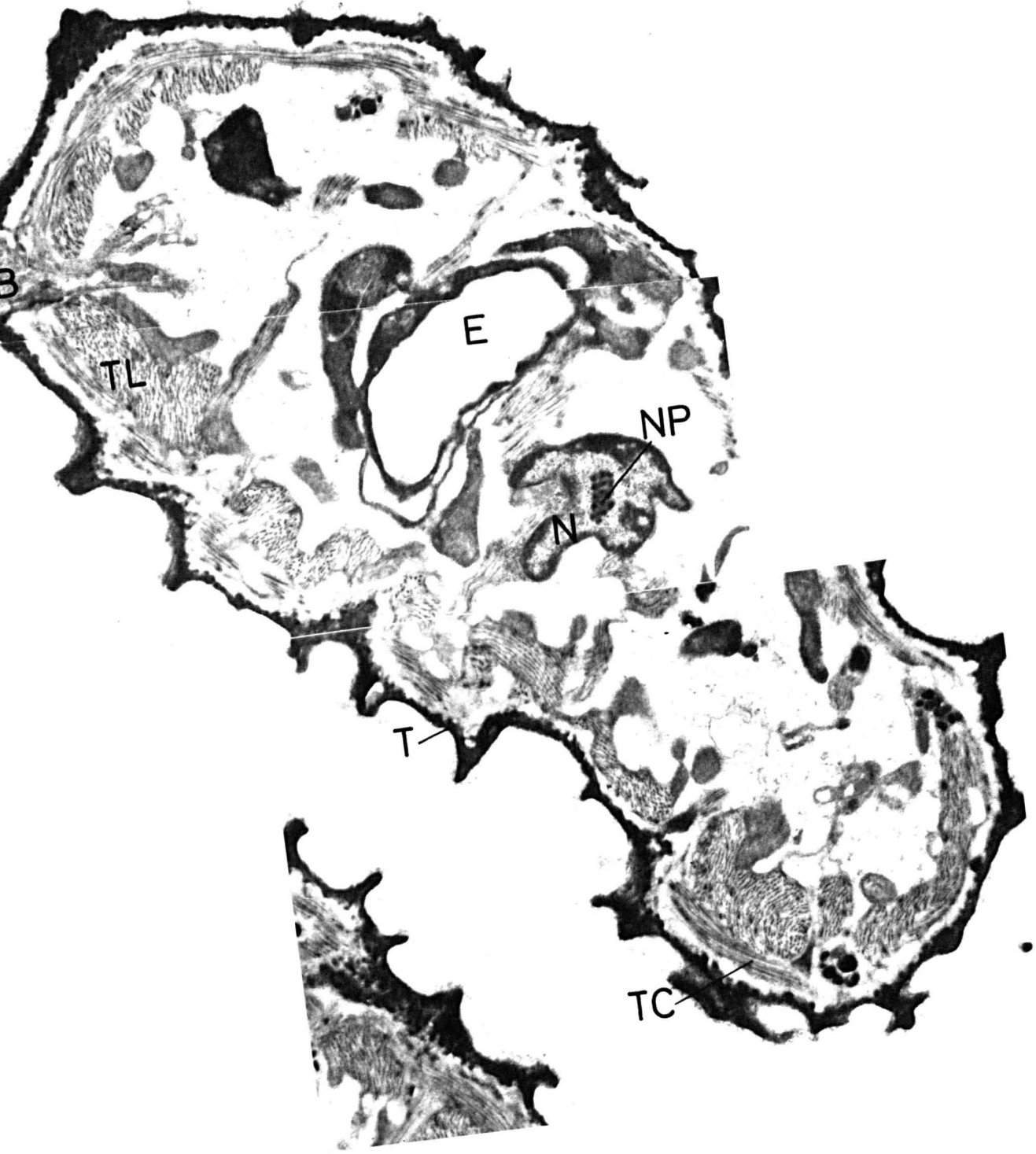

Fig. 78. TS part of furca. Myofibres similar to body fibres in fine structure. X38000.

Fig. 79. LS furca, showing longitudinal myofibres. X20100.

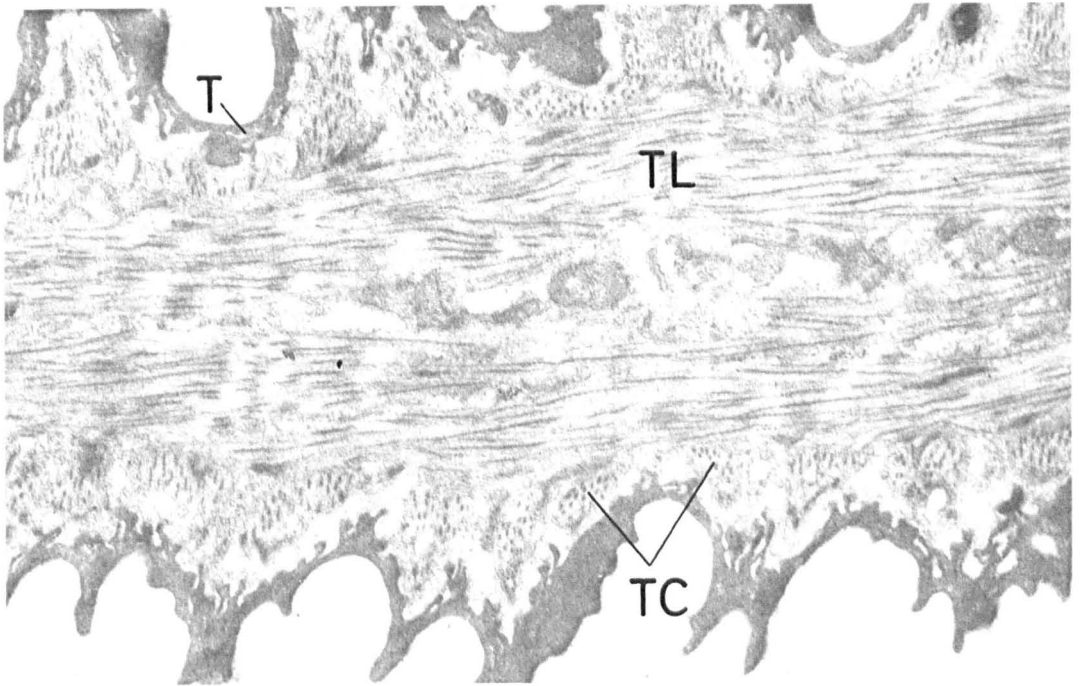
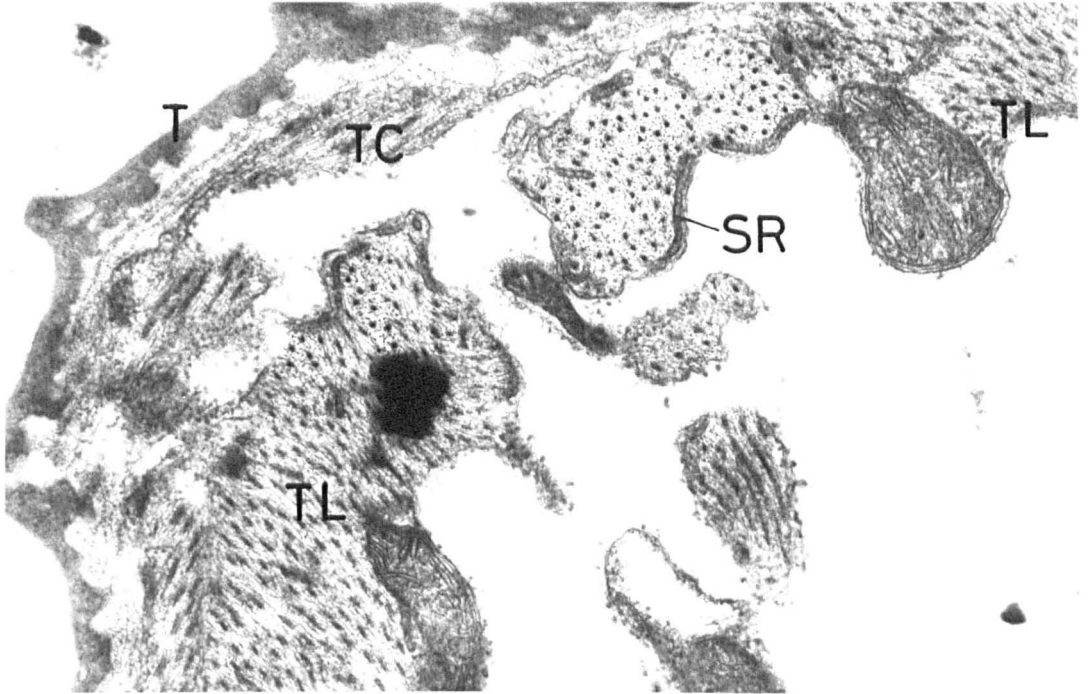


Fig. 80. TS furca showing different sizes of longitudinal myofibre, a circular fibre and a cluster of large, dense vesicles.
x12000.

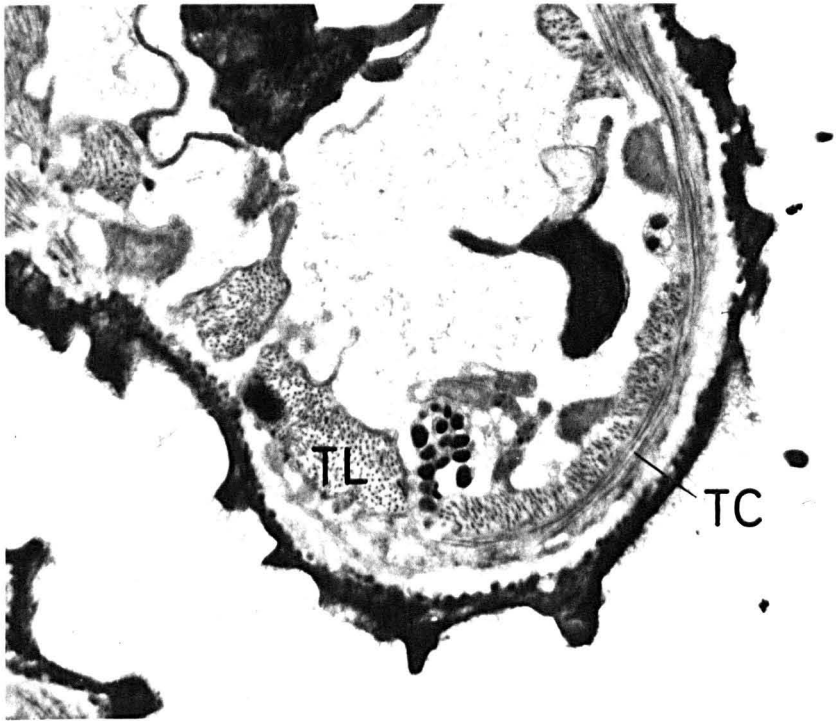


Fig. 81. LS furca which largely passes between the longitudinal fibres
Small, variously-shaped circular fibres seen. X12000.

Fig. 82. LS furca, showing circular fibres in TS and also transverse
myofibres. X12000.

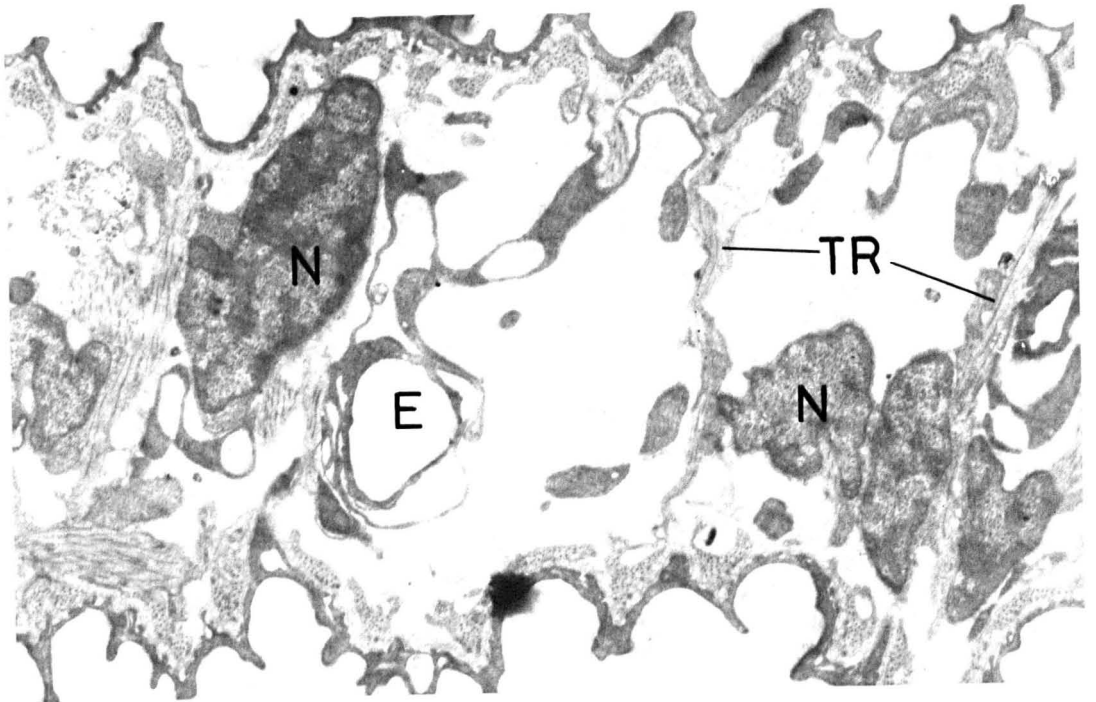
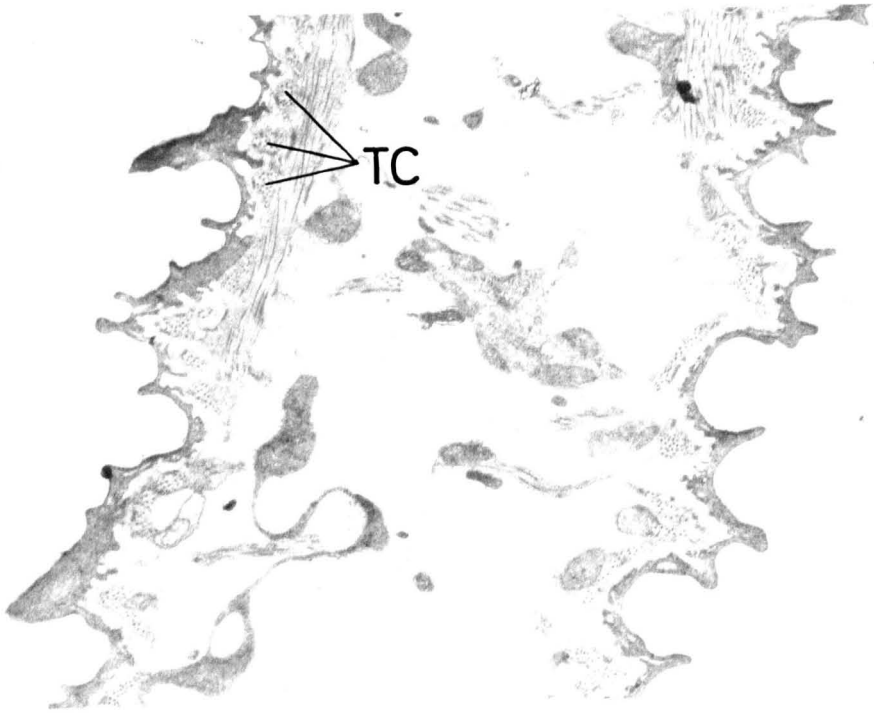


Fig. 83. LS base of furca. Transverse myofibres pass the convoluted excretory canal. X8000.

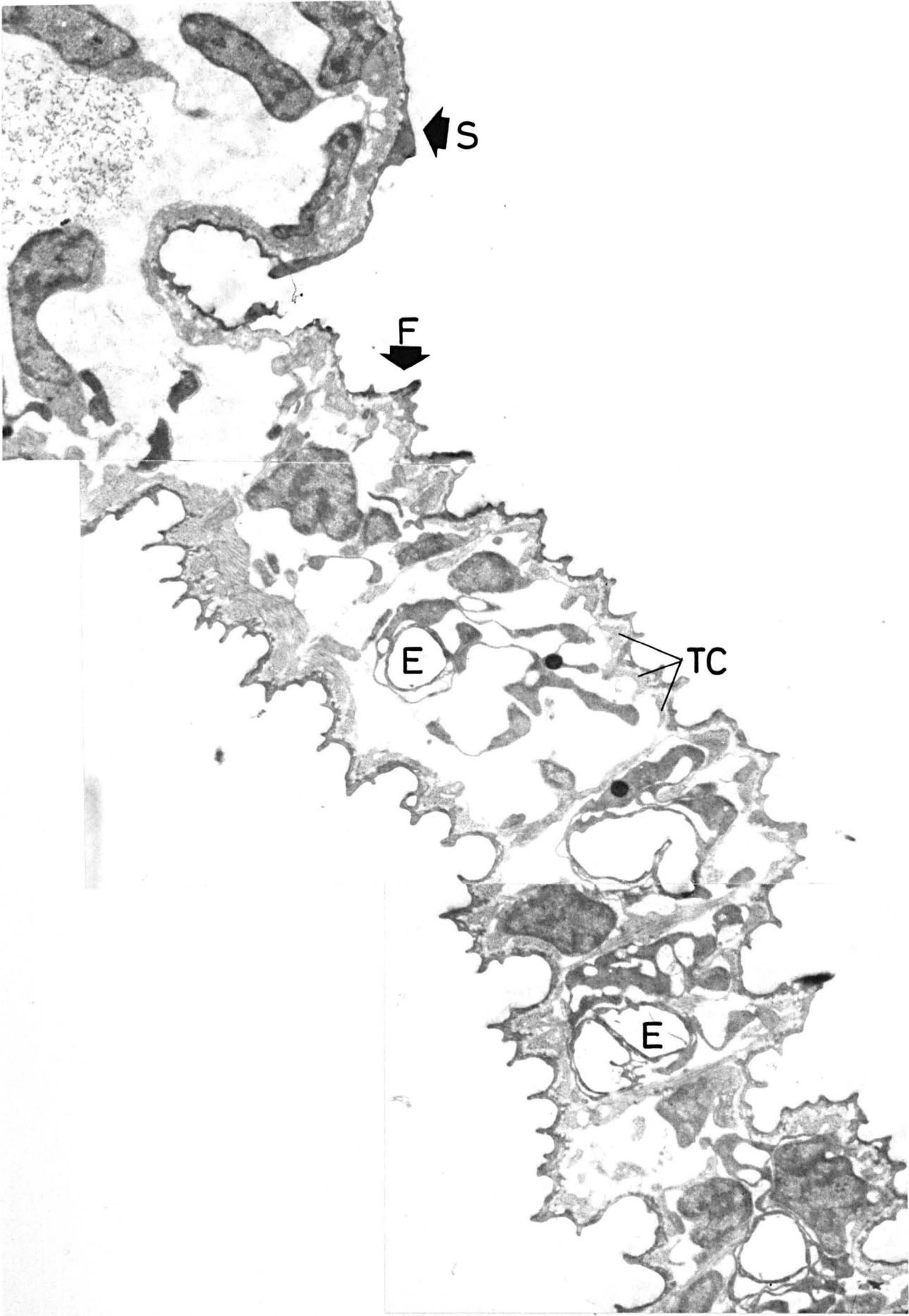


Fig. 84. LS furca to illustrate the importance of excretory canal volume as a proportion of total volume of furca. X20000.

Fig. 85. LS attachment of furca to tail stem. Circular myofibres are clearly defined in furca but there are few longitudinal fibres in this section. A conical projection lies between the two furcae at the distal end of the tail stem. X8000.

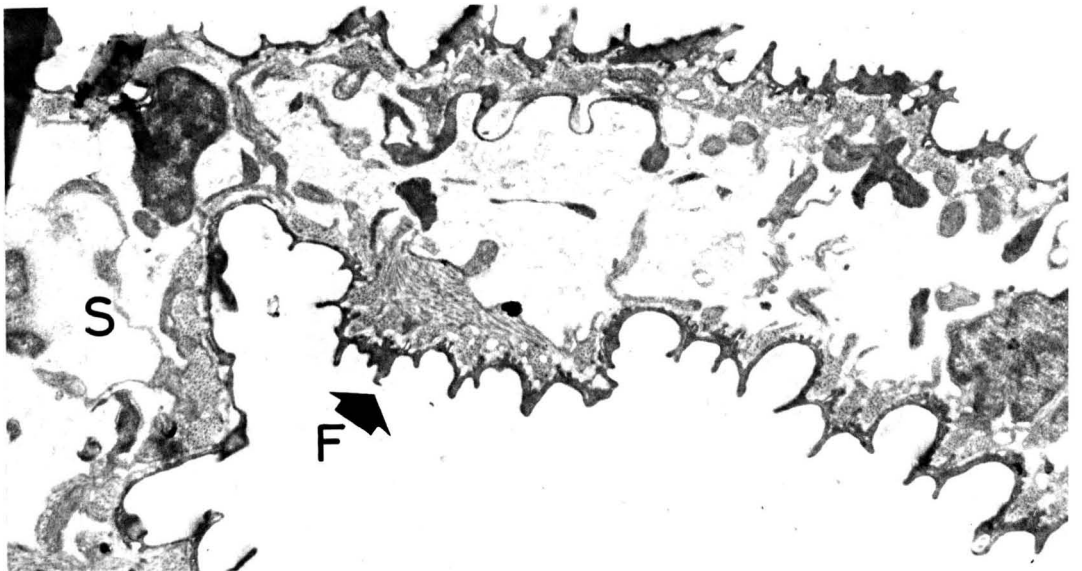
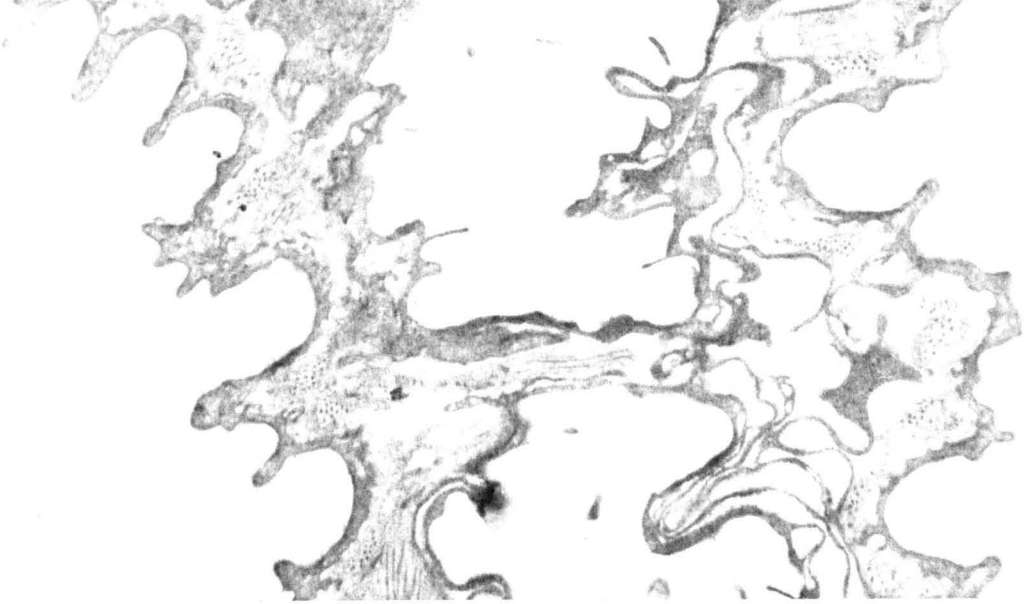
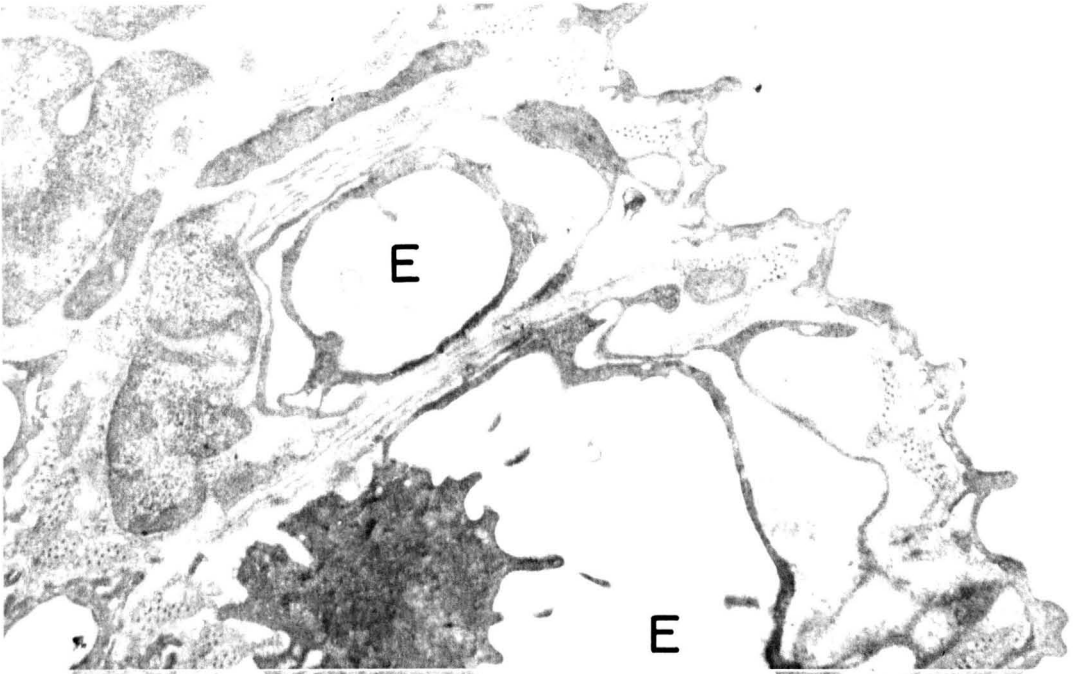


Fig. 86. LS body, showing longitudinal nerve cord and three nerve cell nuclei lying under the body wall musculature. X16000.

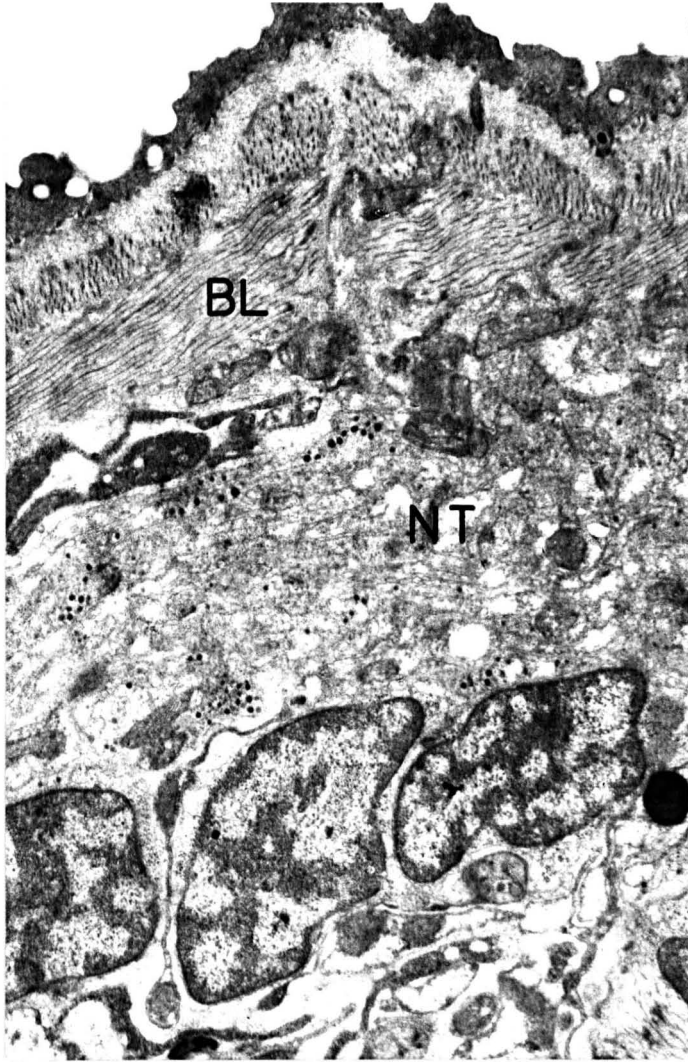


Fig. 87. TS body. Relatively small, lateral nerve cord lies between two adjacent longitudinal myofibres. X20000.

9

Fig. 88 TS anterior body. Nerve cord between body wall and oral sucker capsule; note synapse. X12000.

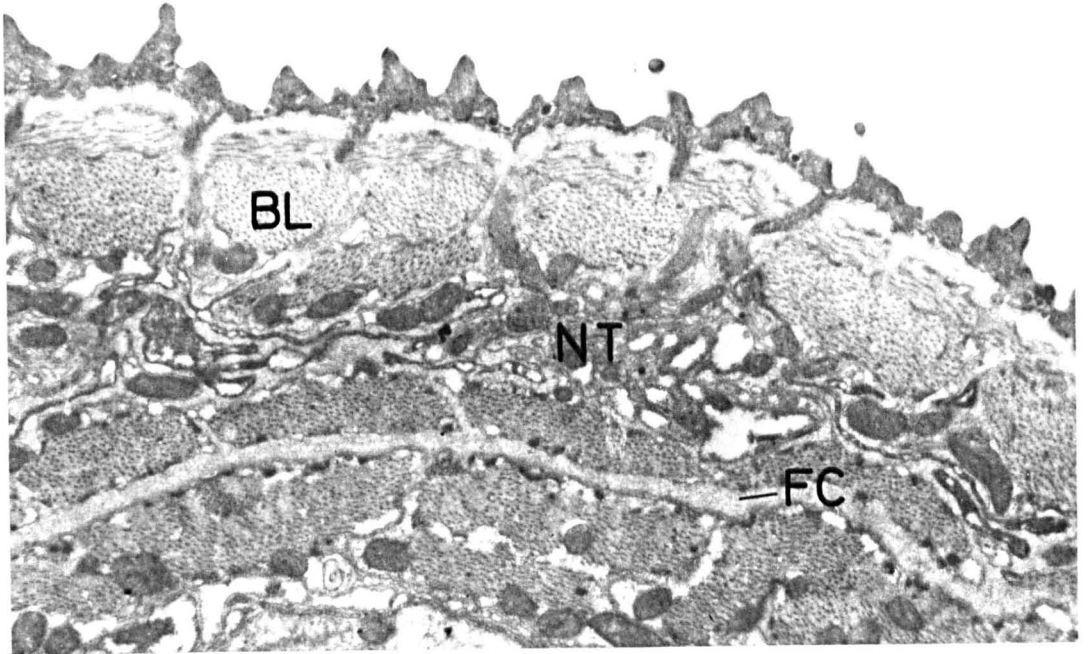
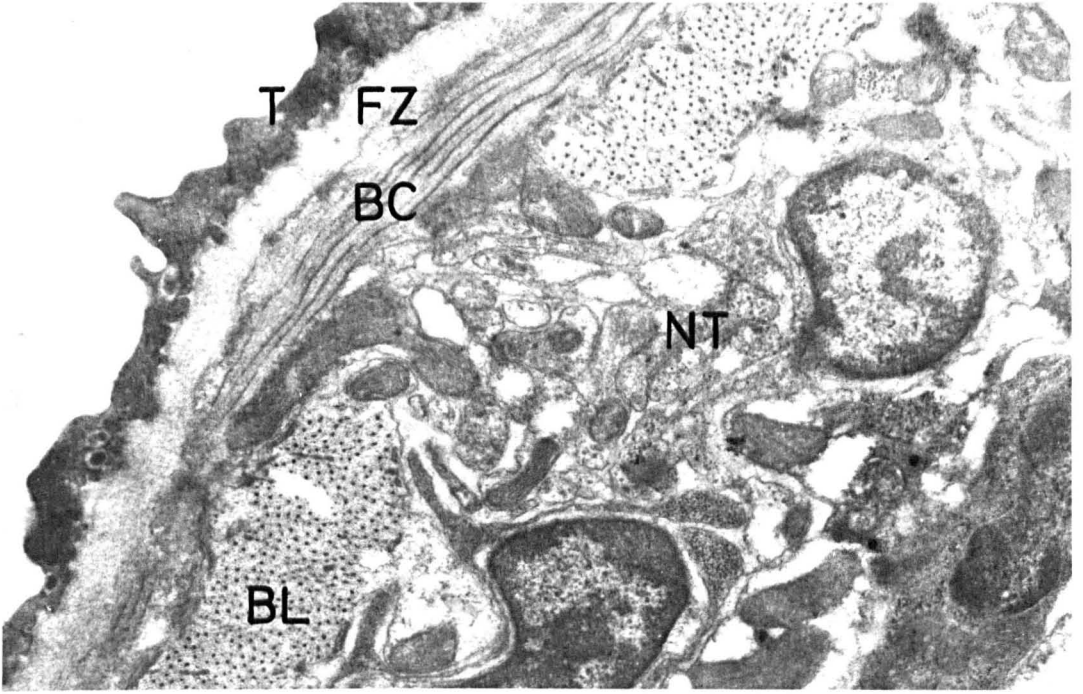


Fig. 89. TS caudal nerve mass extending between median muscle blocks dorso-ventrally. X12000.

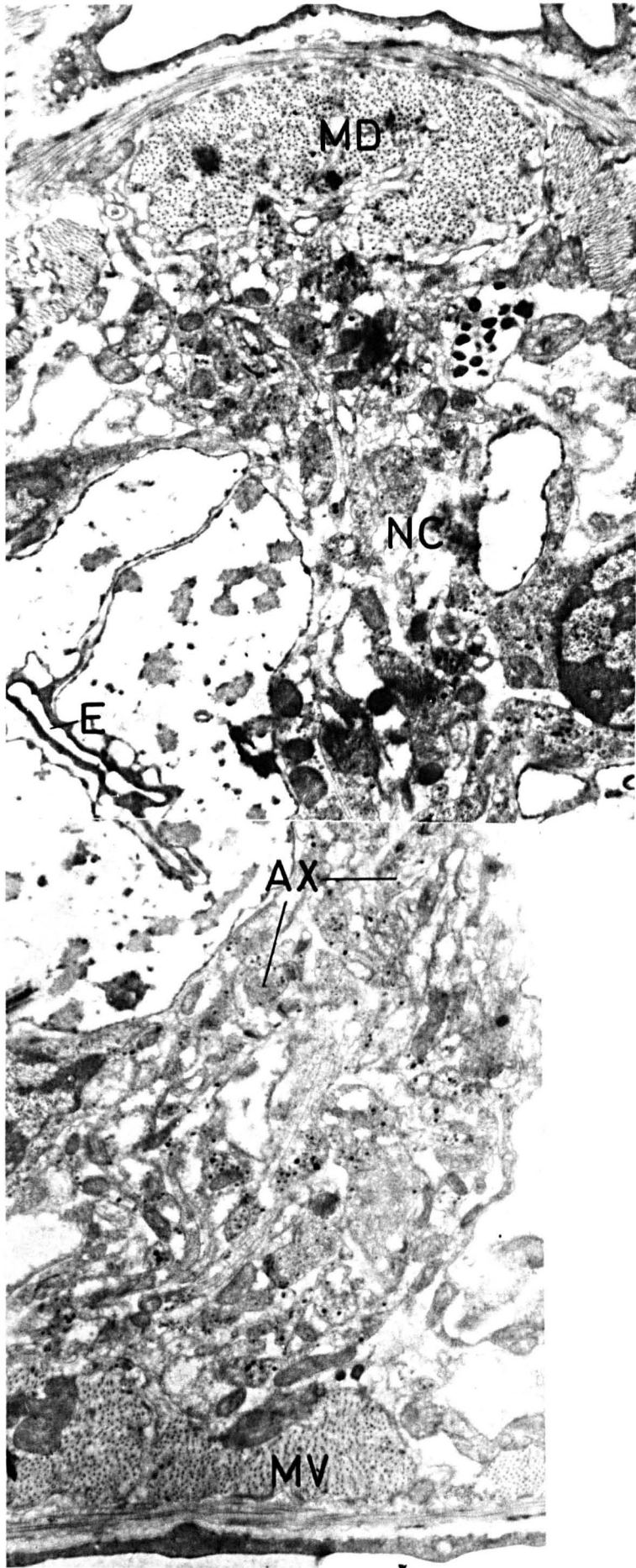


Fig. 90. TS part of caudal nerve mass. Wide distribution of small, dense vesicles in axons. X8000.

Fig. 91. LS base of tail showing part of caudal nerve mass under median muscle block. Median nerve parts from muscle to join main nerve mass. X12000.

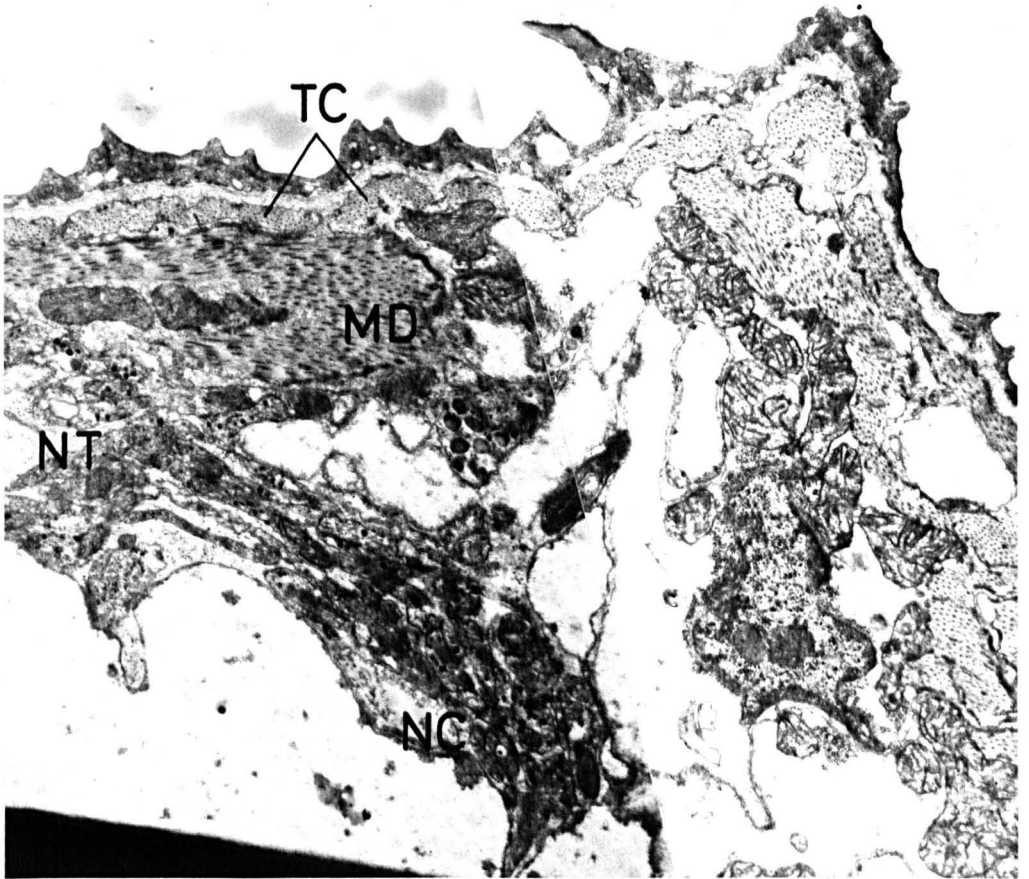
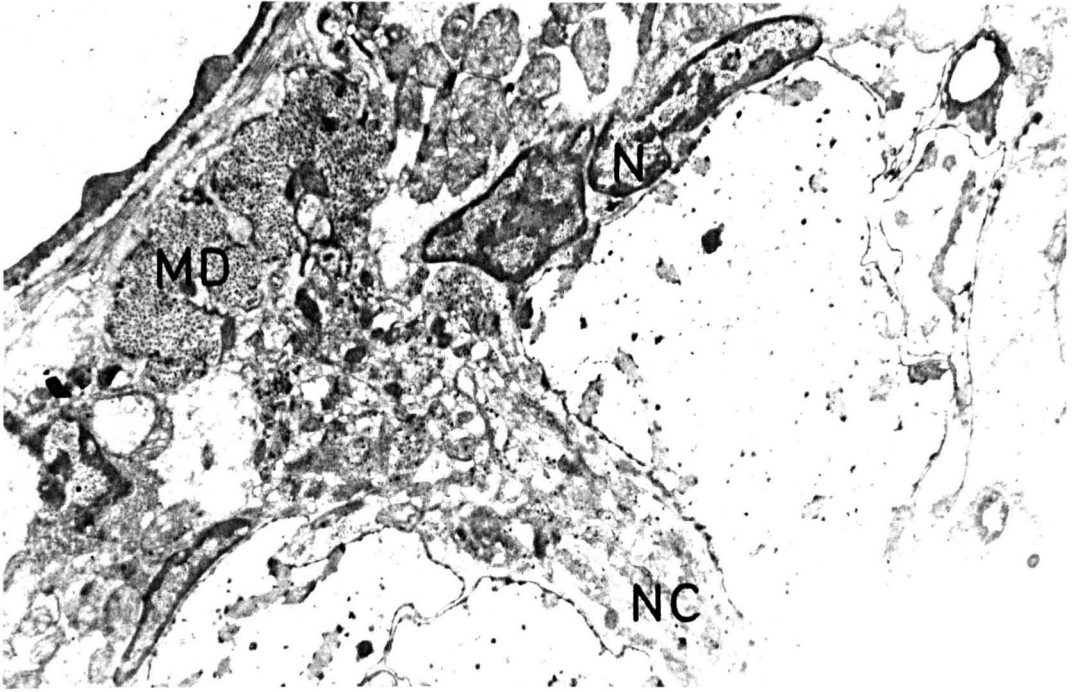


Fig. 92. TS base of median, caudal nerve and muscle block. Axon leads from nerve cord towards tail core. X45600.

Fig. 93. Central nerve ganglion in body. Small dense vesicles widely distributed, but some axons containing only clear axoplasm. Separate nuclear and axonal regions. Frequent mitochondria. X44500.

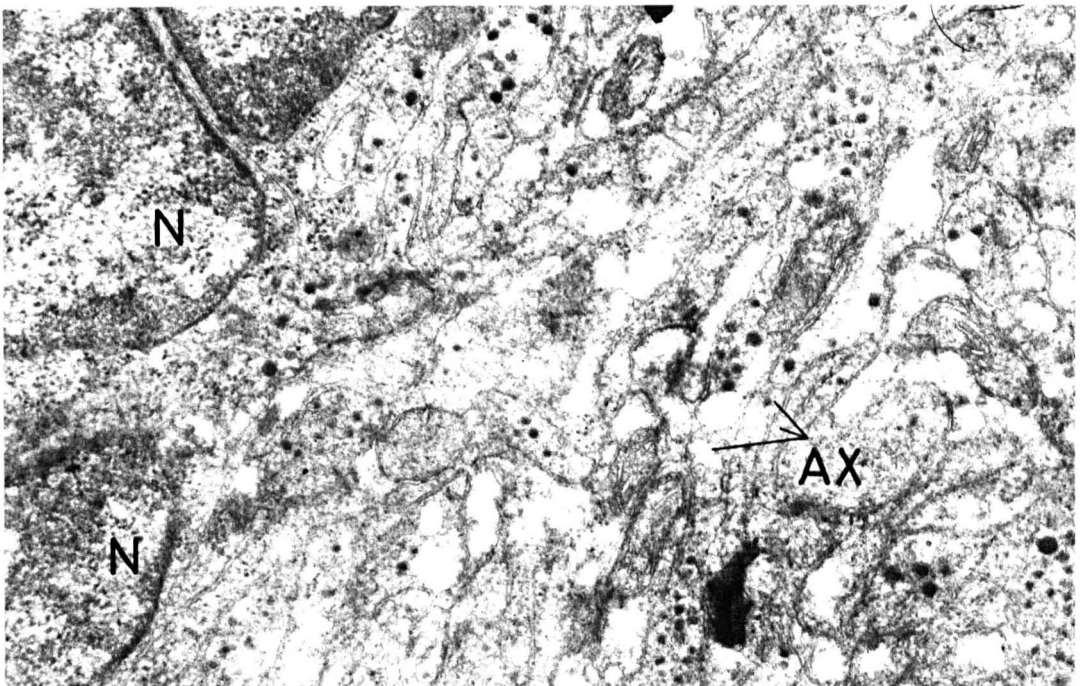
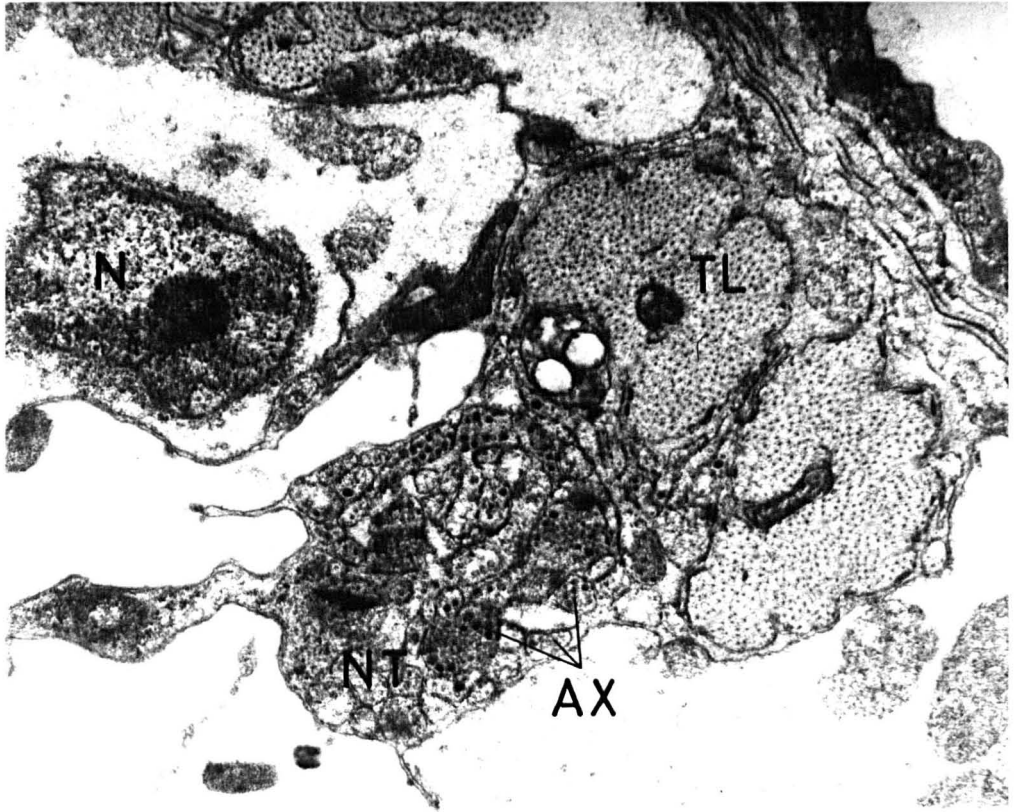


Fig. 94. TS base of tail. Possibly a nerve cell nucleus associated with median nerve cord. X16000.

Fig. 95. LS body. Longitudinal nerve cord contains distinctive synapses, with concentration of axonal vesicles. X38000.

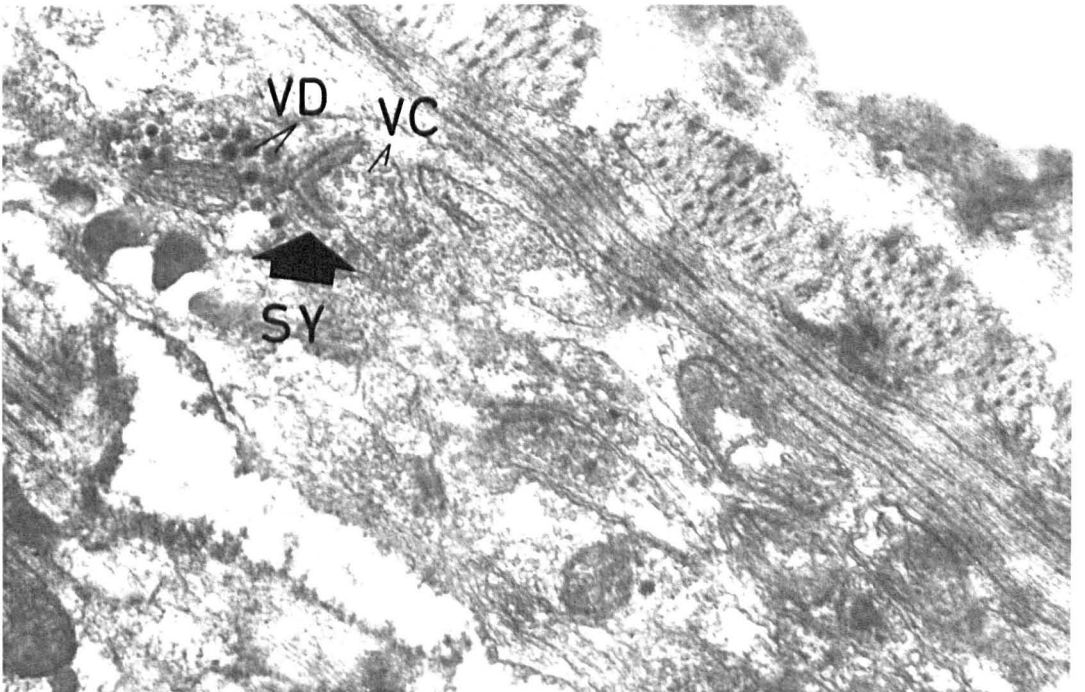
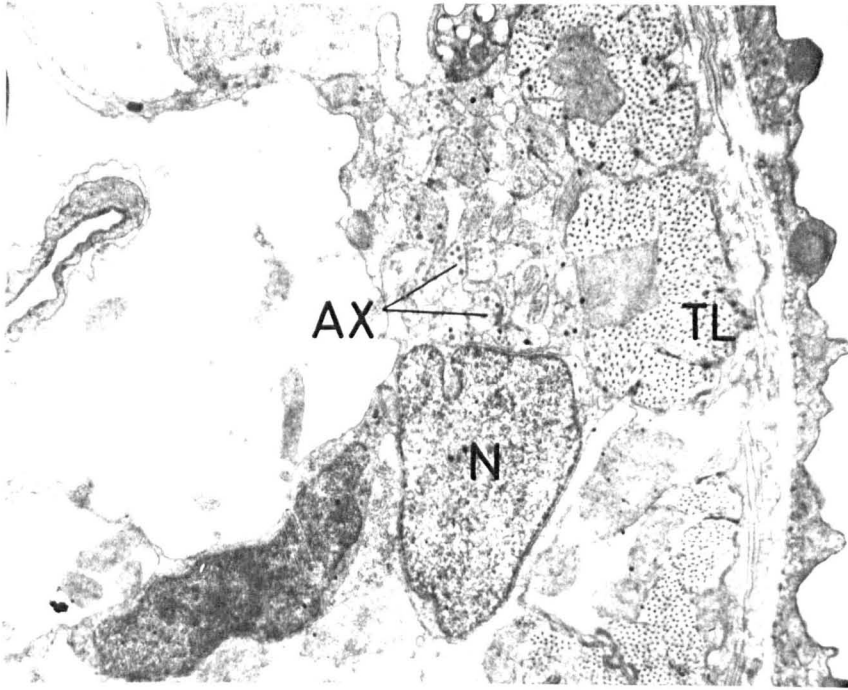


Fig. 96. TS near base of tail. Synapse in median nerve, with concentration of axonal vesicles on one side. X45800.

Fig. 97. LS median caudal nerve showing distribution of two types of axonal vesicle. X38000.

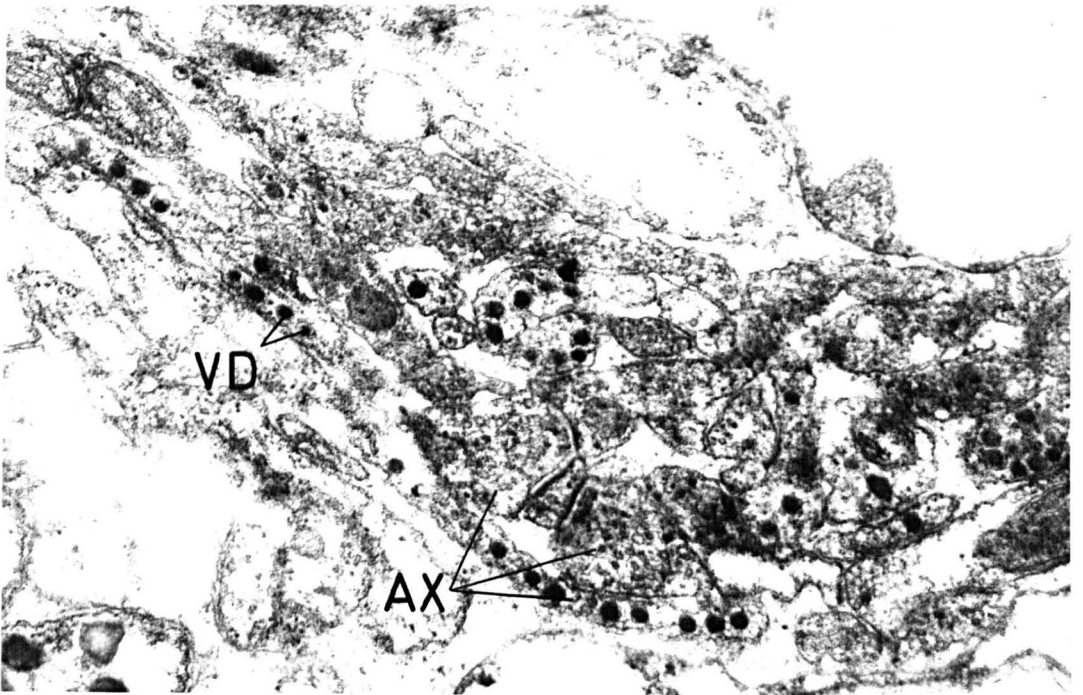
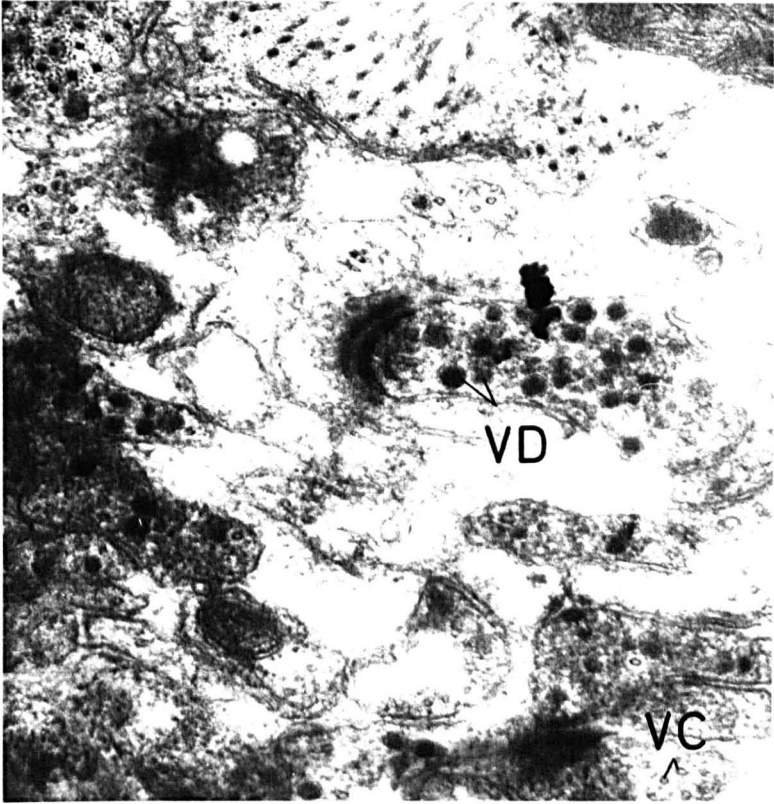


Fig. 98. LS longitudinal nerve in body. Dense axonal vesicles of varied size and also microtubules are seen. X41600.

Fig. 99. Median caudal nerve in TS. Accumulation of axonal vesicles and close approximation of nerve and myofibre membranes. X38000.

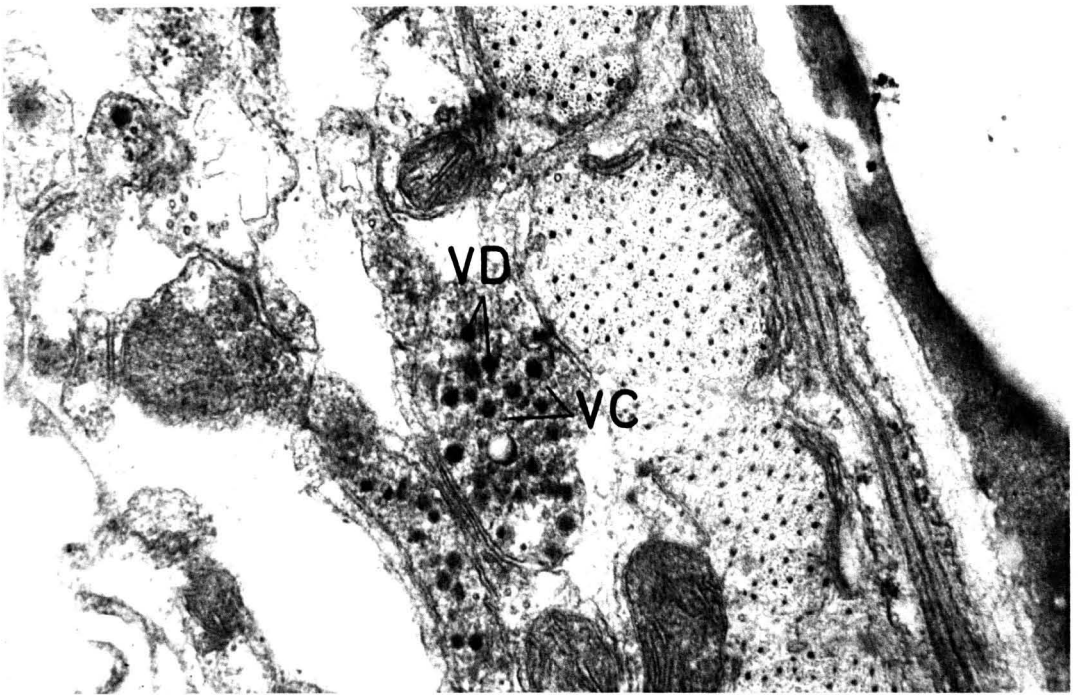
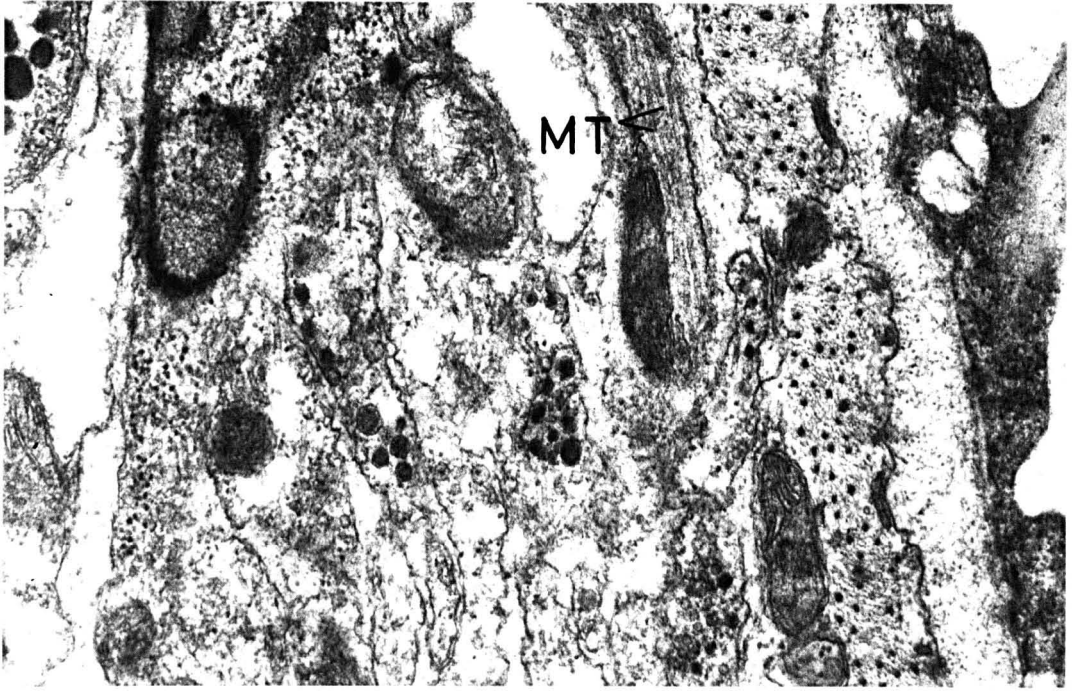


Fig. 100. LS body wall. Only circular myofibres visible, under which lies a nerve cord. Local accumulations of axonal vesicles seen. Note seemingly 'blind' tubules extending from tegument towards myofibres. X23500.

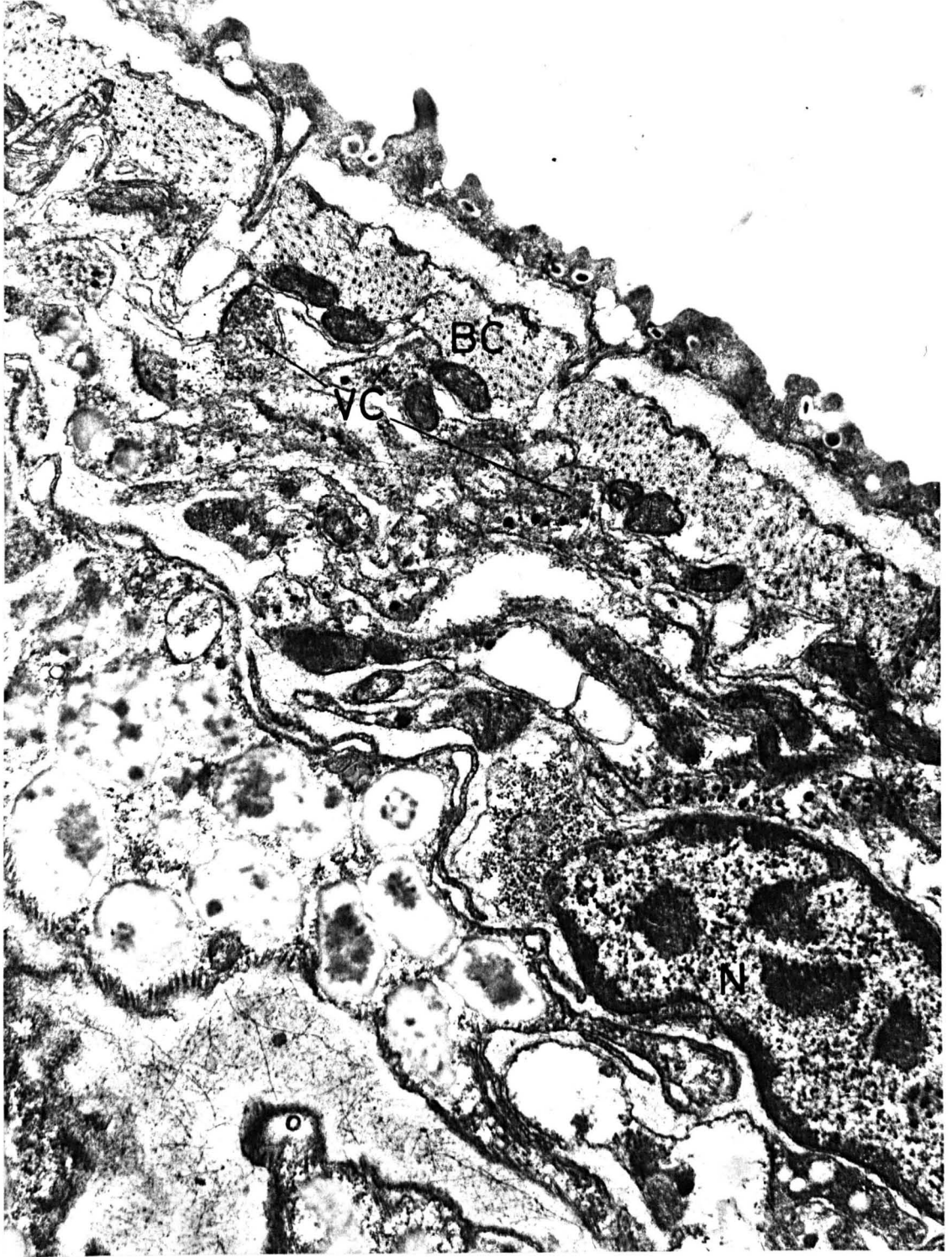


Fig. 101 LS body. Clusters of large dense vesicles associated with longitudinal myofibres. X16000

Fig. 102. Part of sensory receptor, beneath tegument; note 9(double) + 1(single) microtubule arrangement in cilium. Group of large dense vesicles is adjacent, associated with smaller, clear vesicles. X6000.

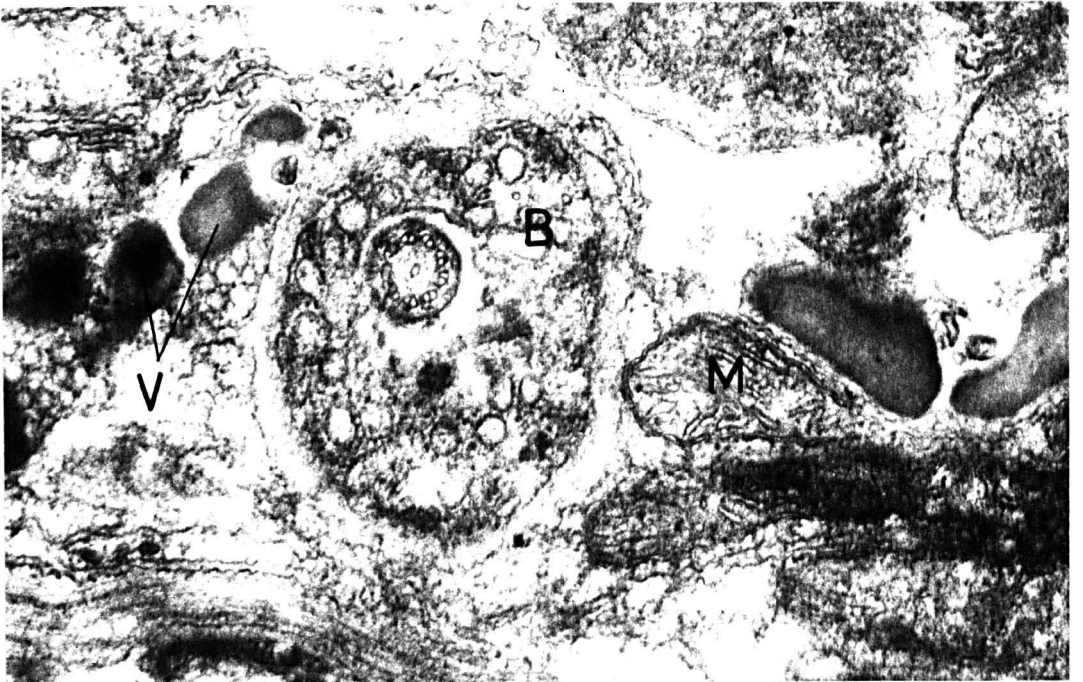
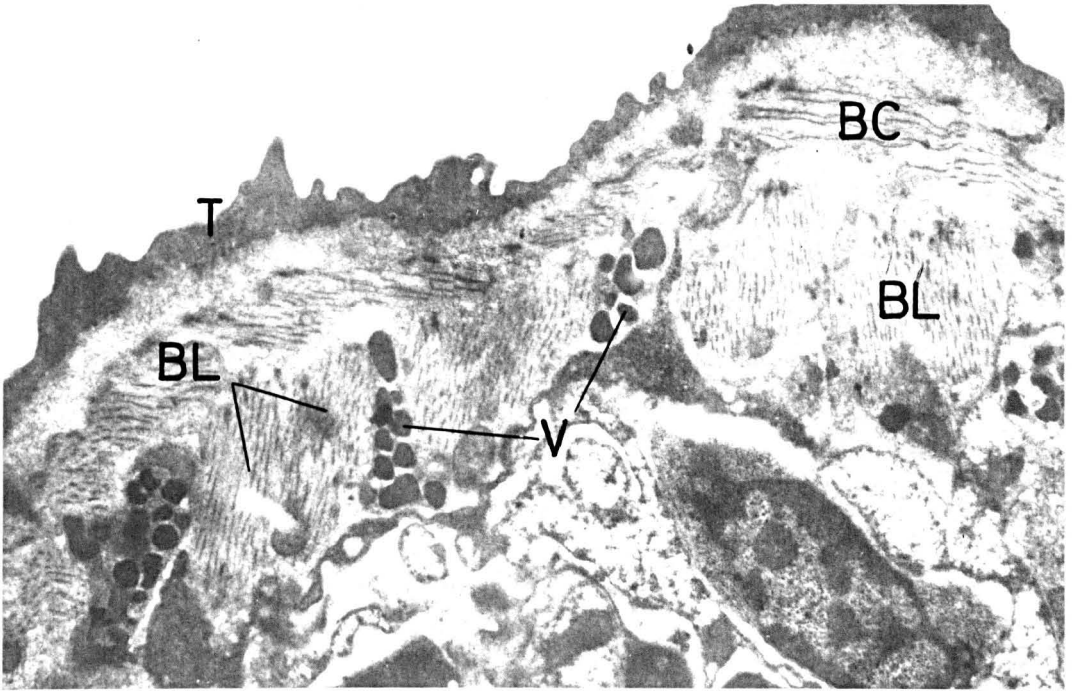


Fig. 103. LS area beneath body tegument. Large dense bodies associated with clear vesicles. Granular cytoplasm linked to tegument via tubule. X55900.

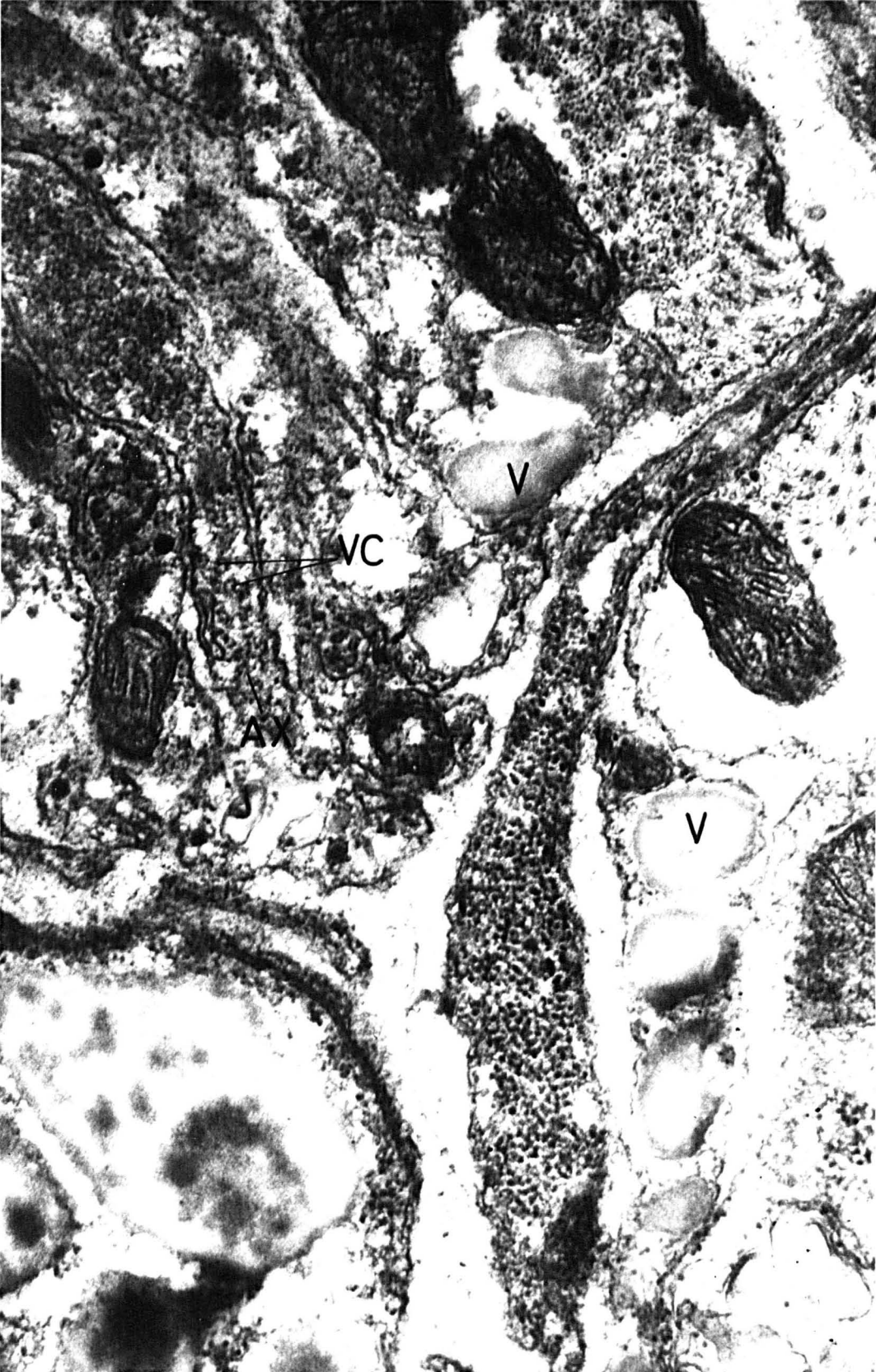


Fig. 104. Cluster of large dense vesicles adjacent to body wall musculature. X43900.

Fig. 105. Nerve bulb in body tegument contains clear vesicles. Large dense vesicles present between myofibres. X38000.

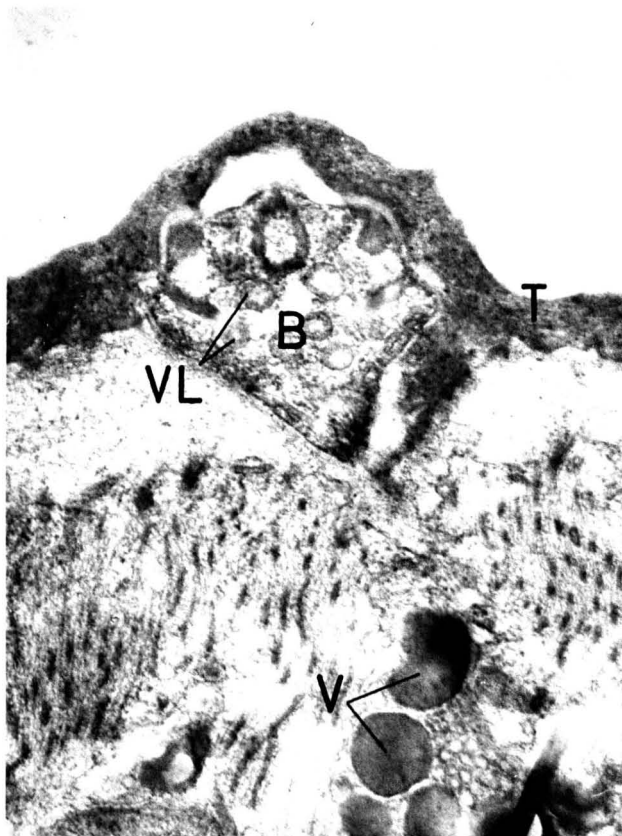
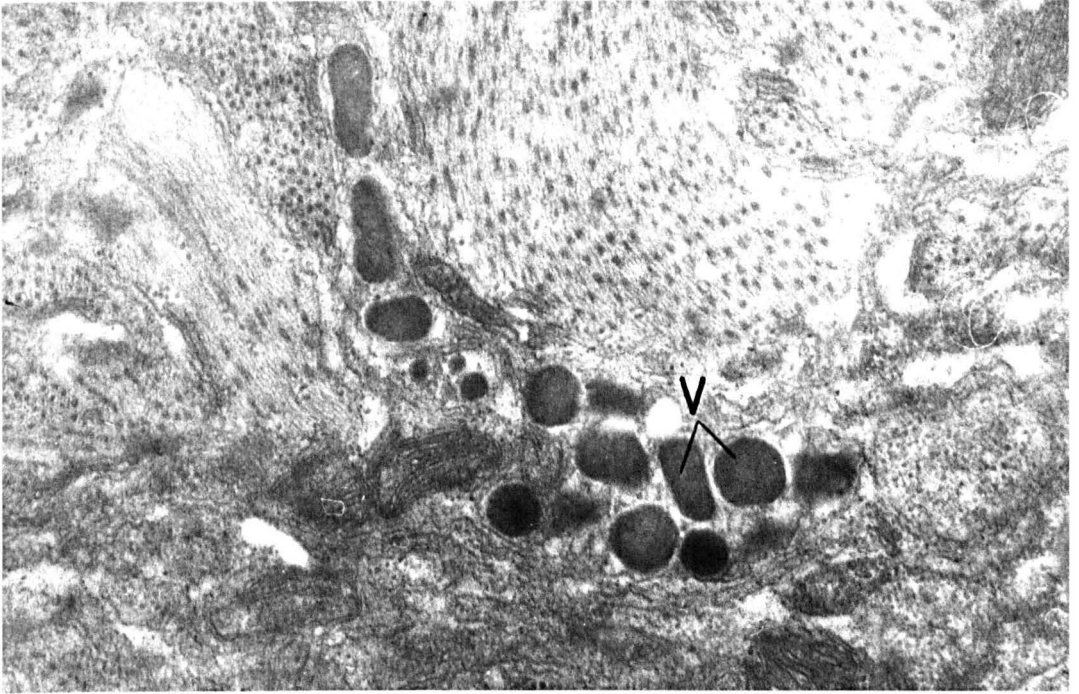


Fig. 106. Uniciliate, unsheathed receptor of tail. Bulb contains large, clear vesicles and electron-dense rings (see text). Septate desmosome joins nerve cell to tegument. X38000.

Fig. 107. Uniciliate receptor of body. Central and peripheral ciliary microtubules are attached to parts of the basal body system. X53000.

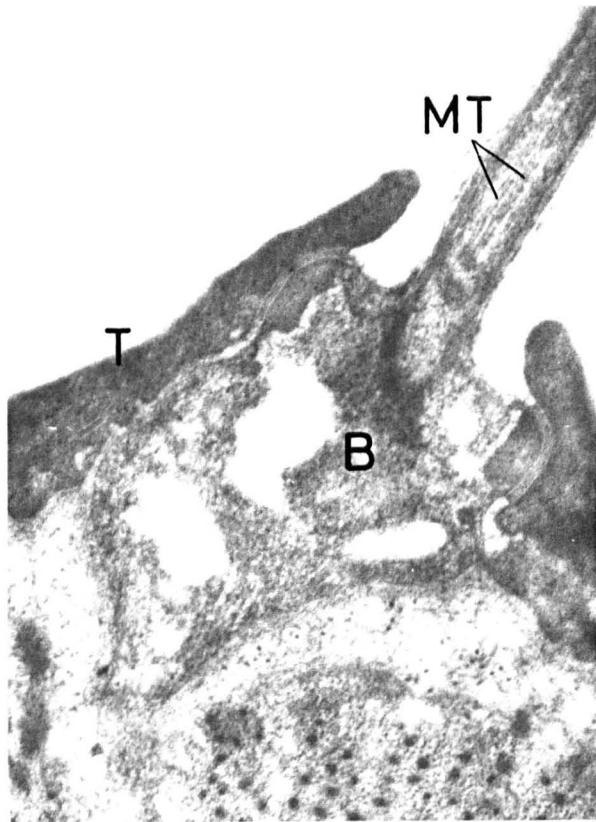
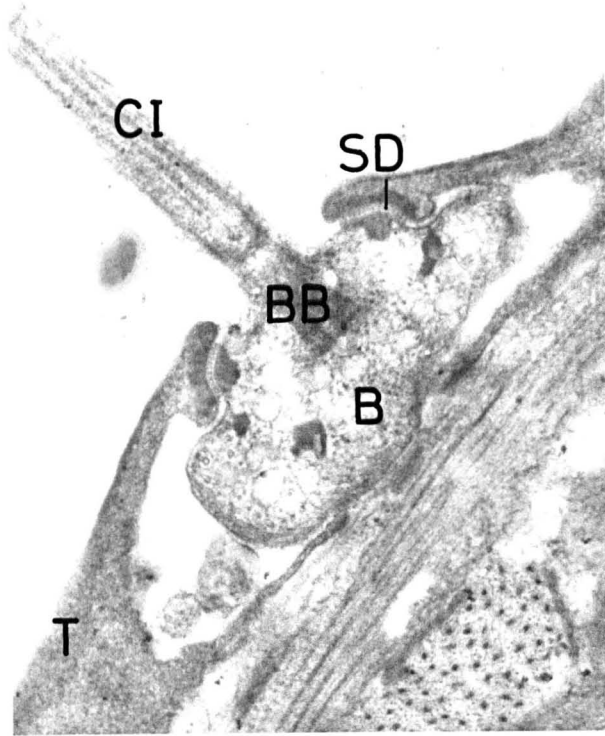
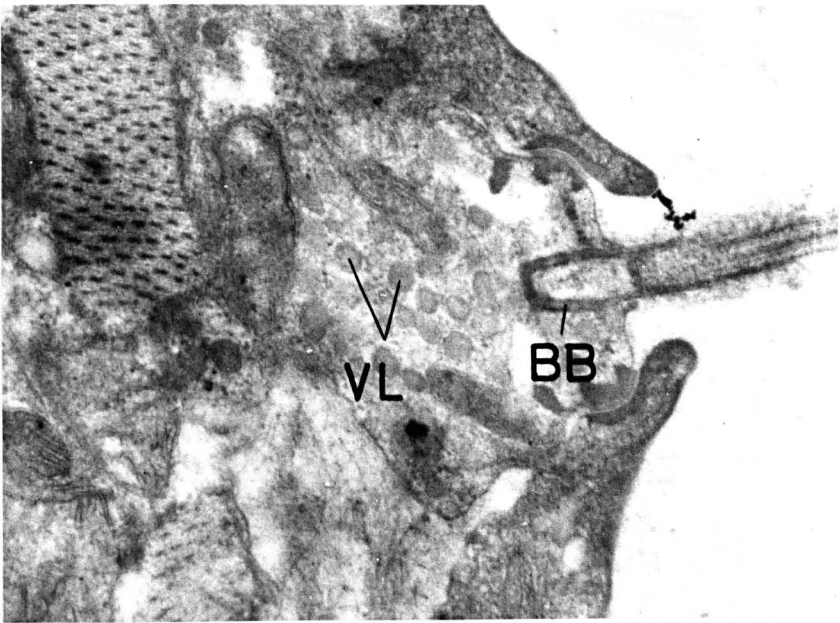
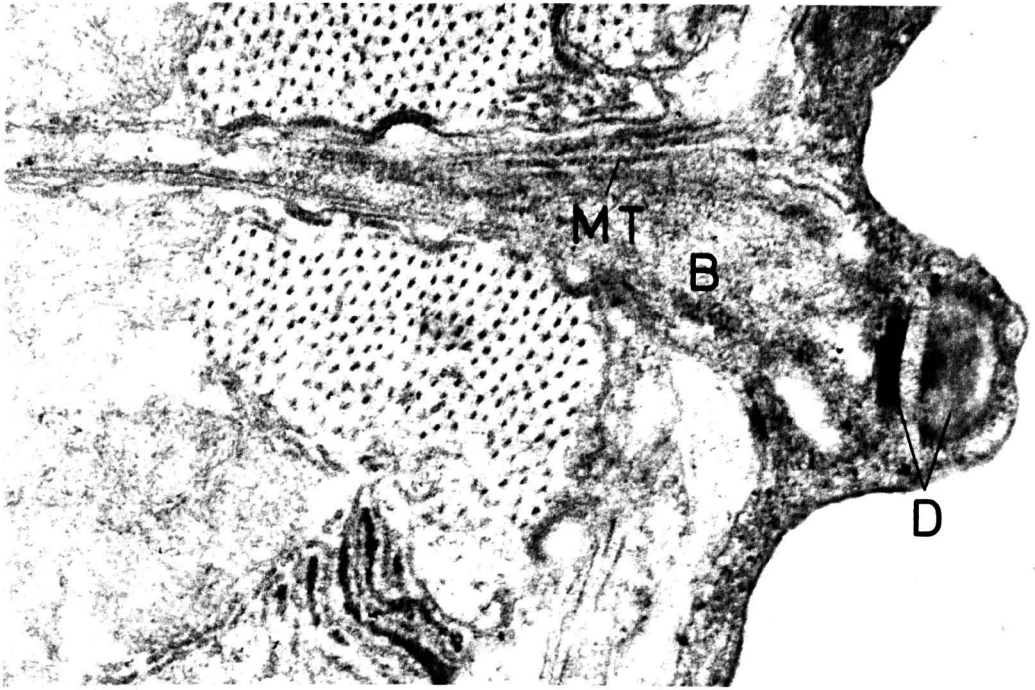


Fig. 108. Axon leads to nerve bulb in tail tegument. Parts of the desmosome system visible in tegument, as section has passed through desmosome 'collar' at edge of nerve bulb. X38000.

Fig. 109. Nerve bulb of caudal receptor. Basal plate lies under cylinder of basal body. Radial element links cylinder to peripheral dense ring. X38000.



Figs. 110-111. Sections at two levels of projecting cilium from receptor on body. Double array of tubules appears to be present.
X48600.

Fig. 112. Adjacent nerve bulbs in body tegument. Few vesicles present in one of these, which has a relatively homogeneous cytoplasm.
X38000.

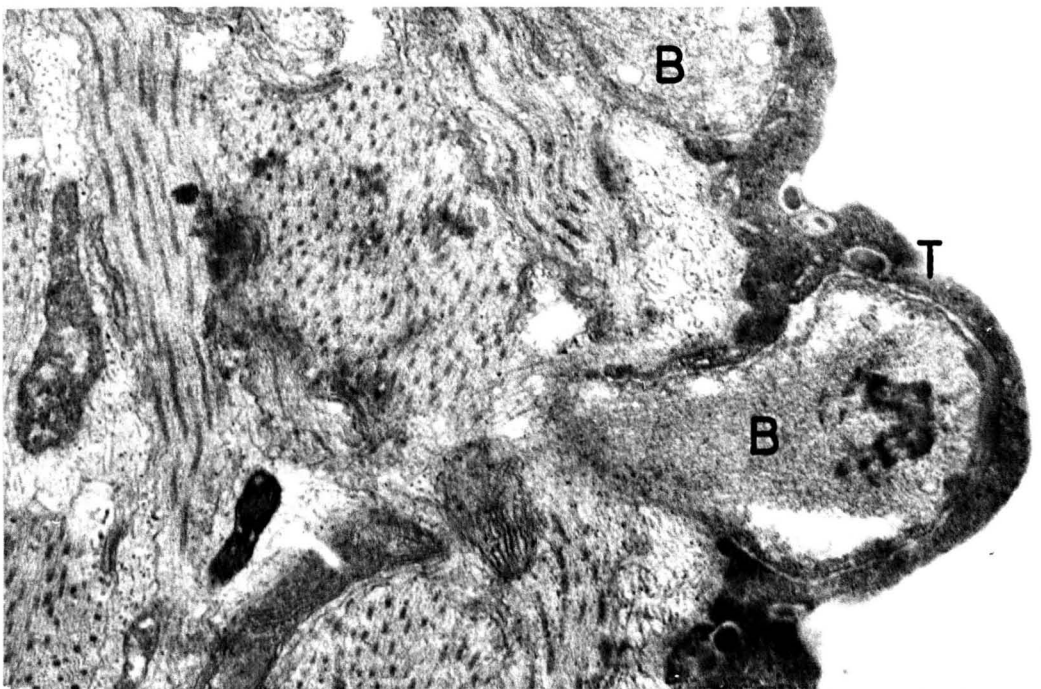

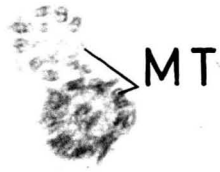


Fig. 113. TS base of tail showing axonal connection between tegumental receptor and underlying nerve cord. X12000.

Fig. 114. TS part of a body flame cell to show ciliary structure.
X272000.

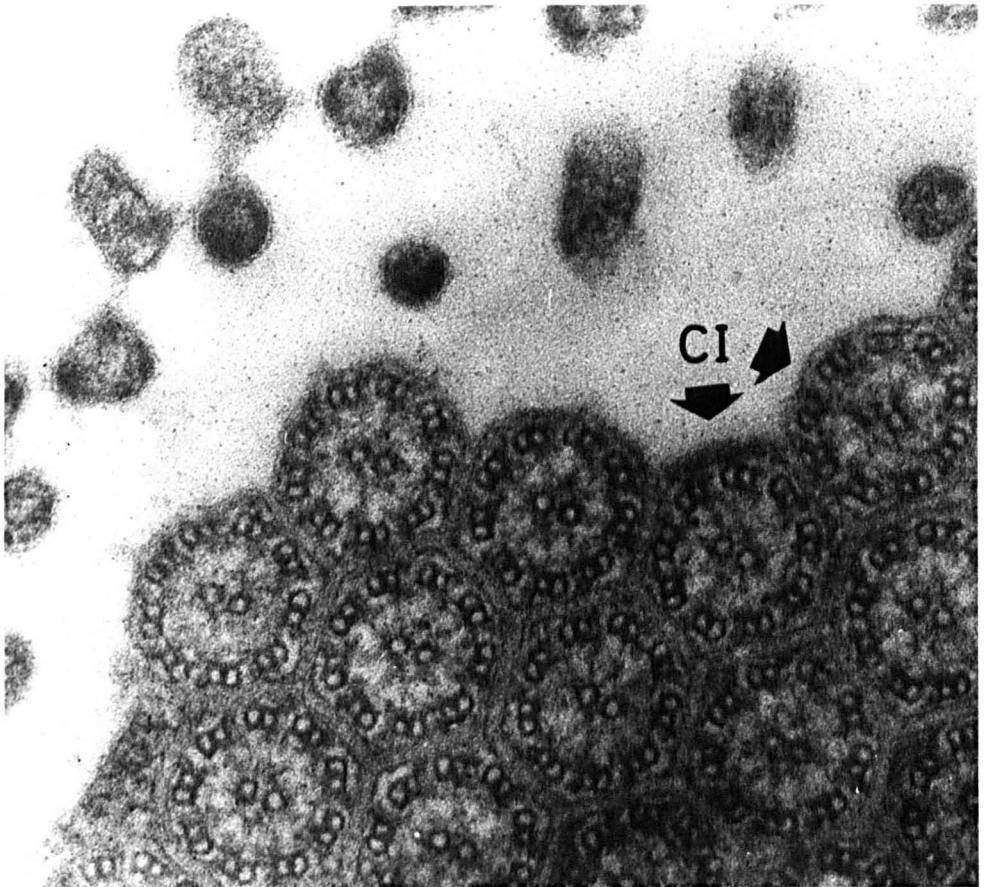
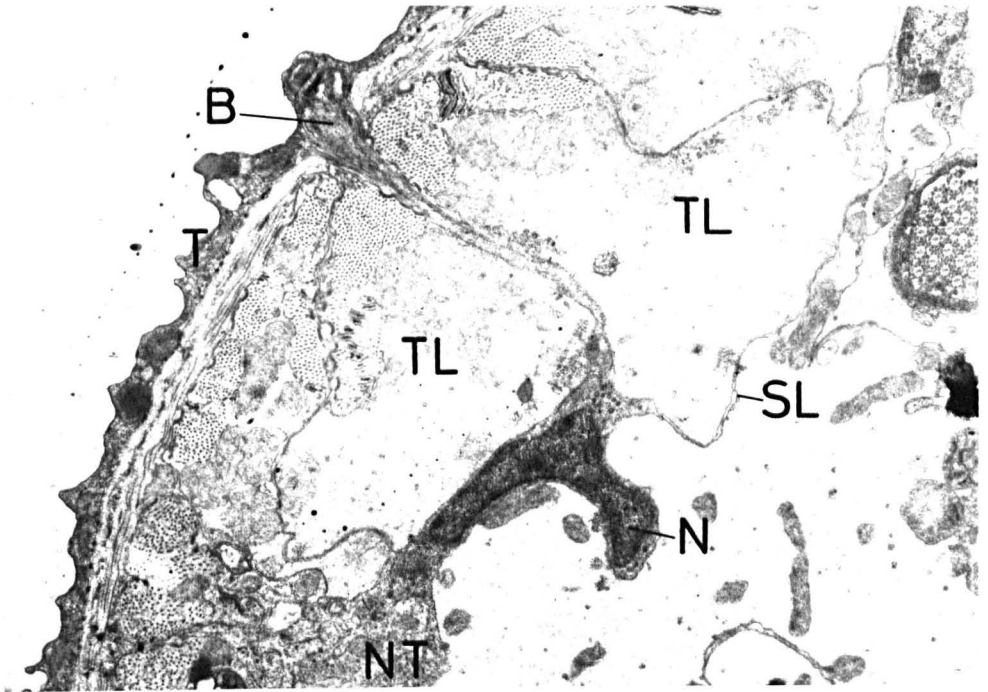


Fig. 115. LS anterior tip of body. Several receptors visible. Three channels lead from head gland to tegument. Internal longitudinal myofibres seen. X6100.

Fig. 116. LS oral disc region. Opening of a main gland cell duct as well as head gland ducts seen. Small amount of subtegumentary nervous tissue. X16000.

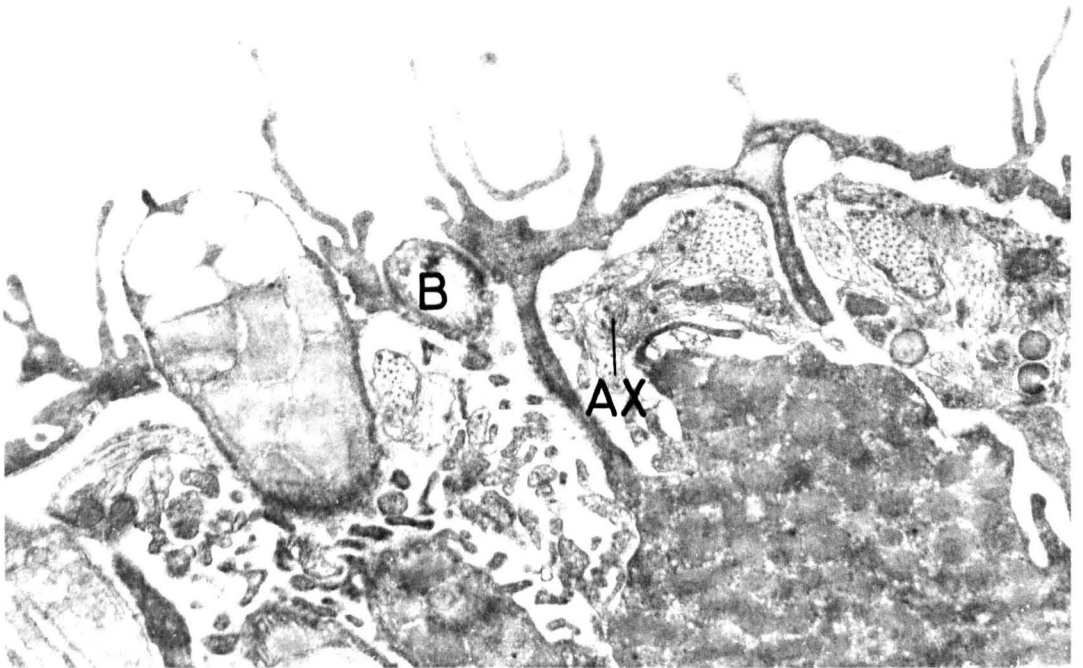
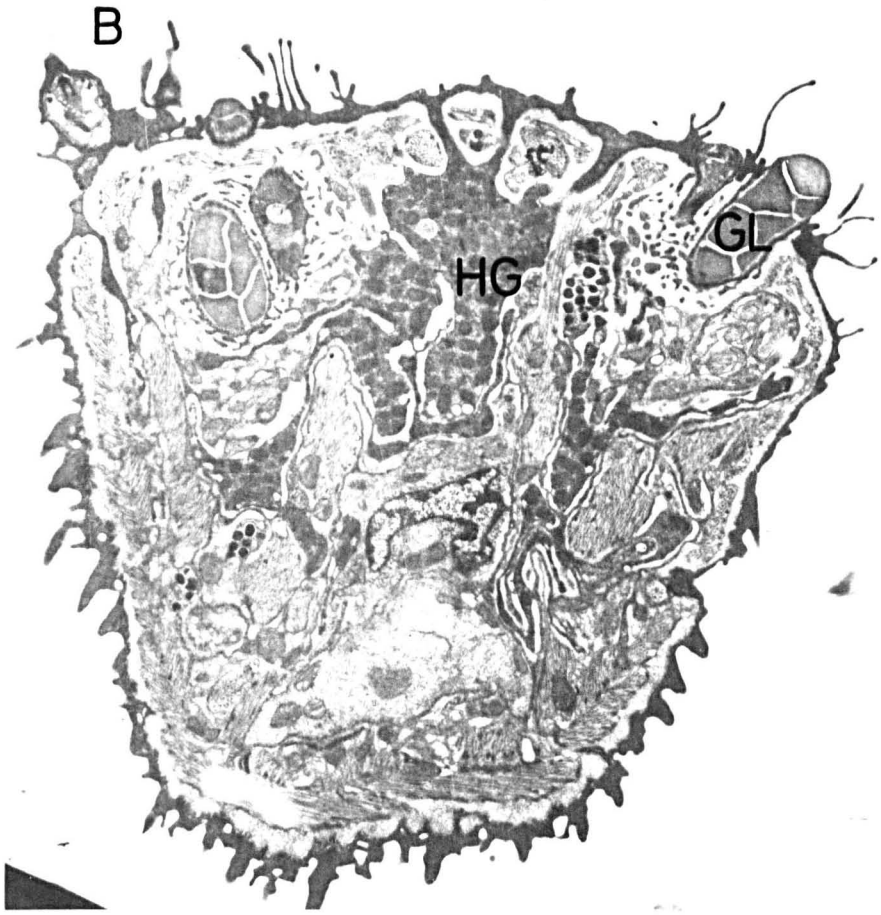


Fig. 117. IS oral disc region. Axon from sheathed, uniciliate receptor leads to subtegumentary nerve. X20000

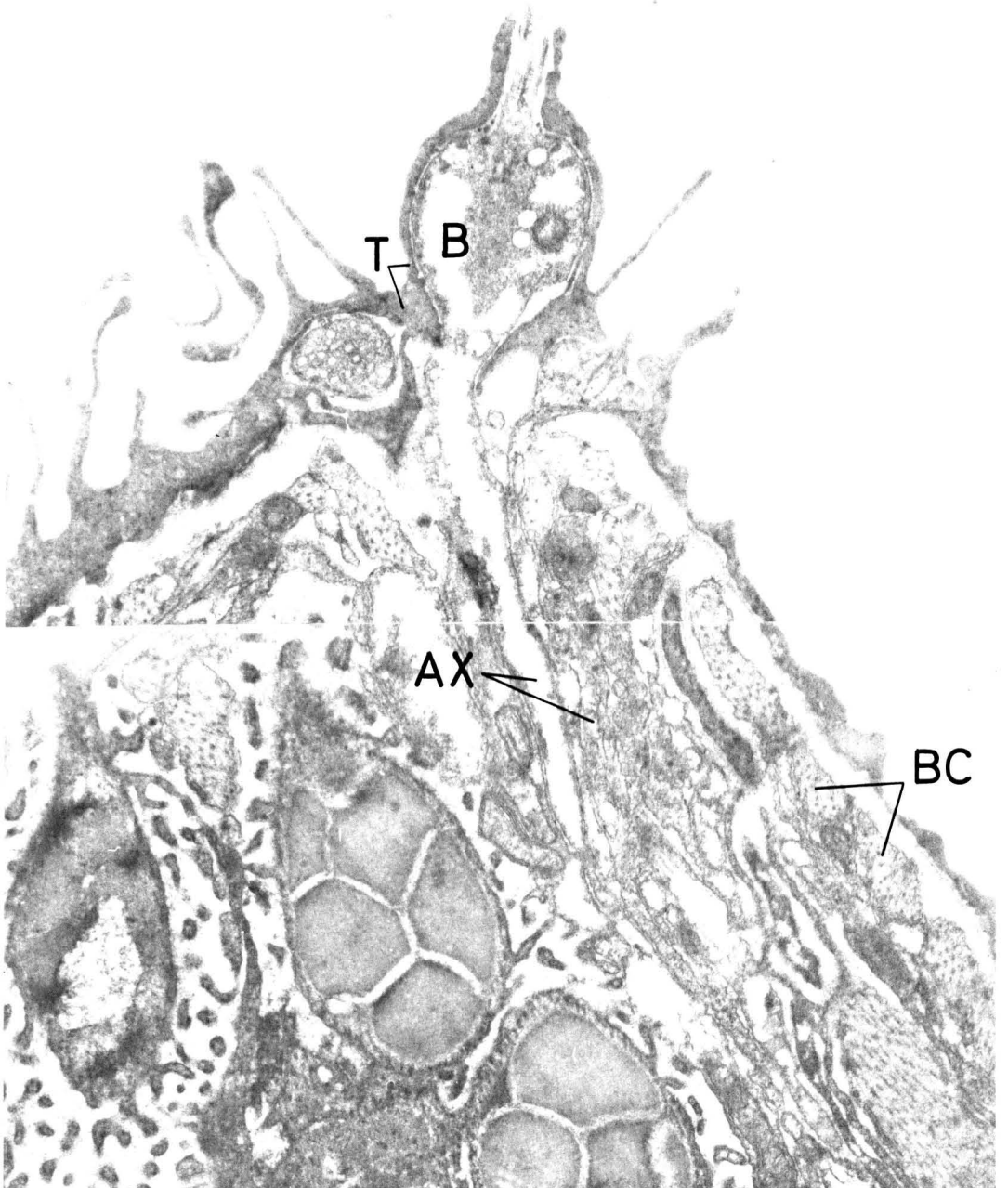


Fig. 118. Sheathed receptor of oral disc. Nerve bulb containing many large, clear vesicles. Note too group of axonal microtubules and longitudinal myofibres. X24000.

Fig. 119. Sheathed receptor of oral disc. Many clear vesicles in nerve bulb, which projects beyond body wall covered by thin layer of tegument. Latter forms sheath around cilium. X38000.

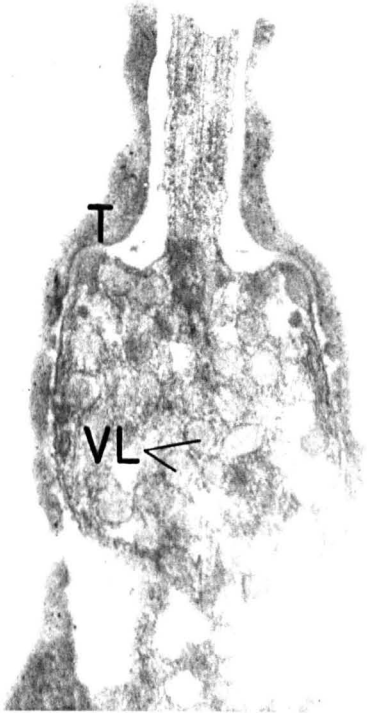
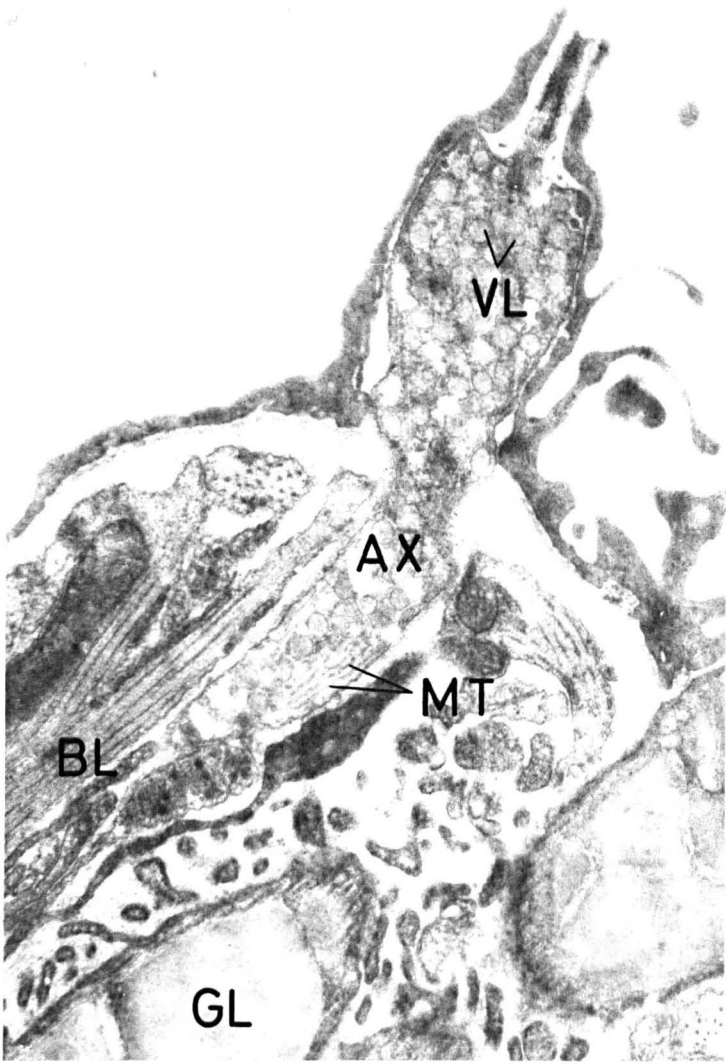


Fig. 120. Group of five nerve bulbs on oral disc. X12000.

Fig. 121. Receptors in "neck" region linked to underlying nerves.
X16000.

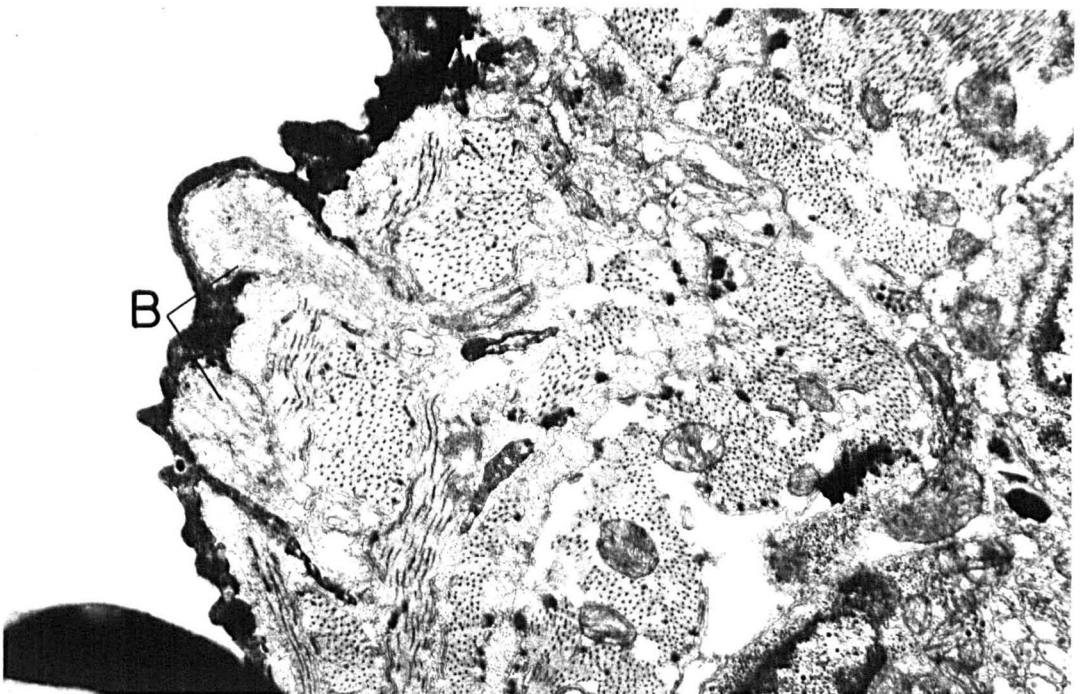
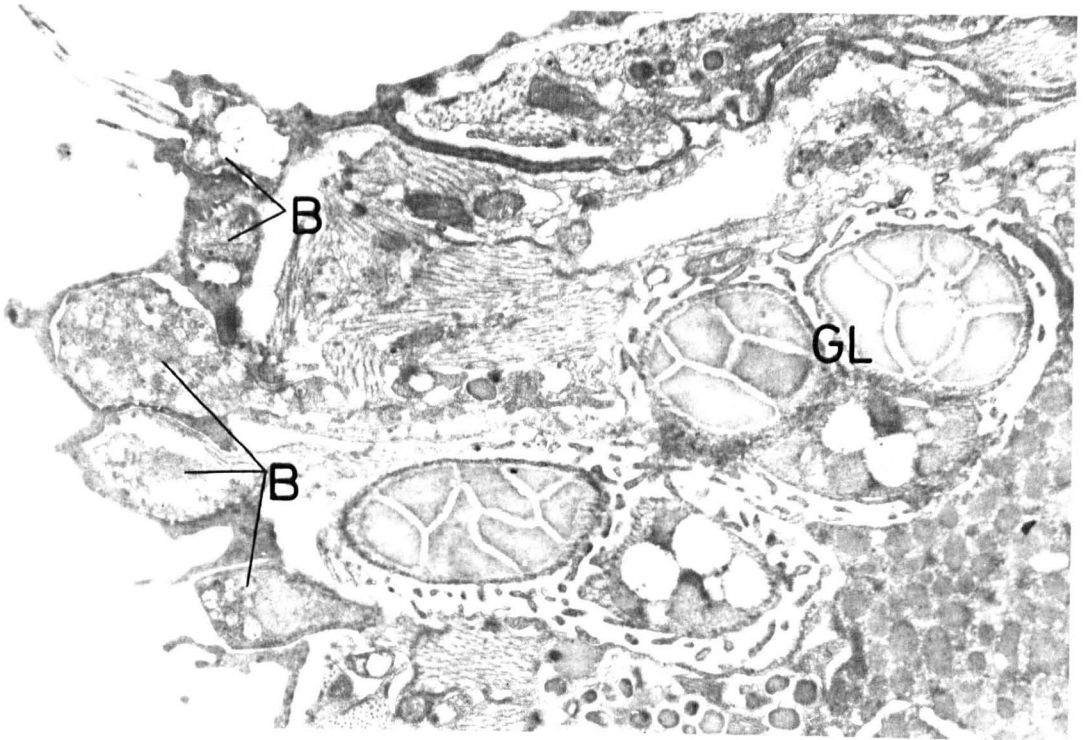


Fig. 122. Ciliated cavity receptor in body. Bulb lies beneath circular myofibres and contains group of cilia in cavity. X57000.

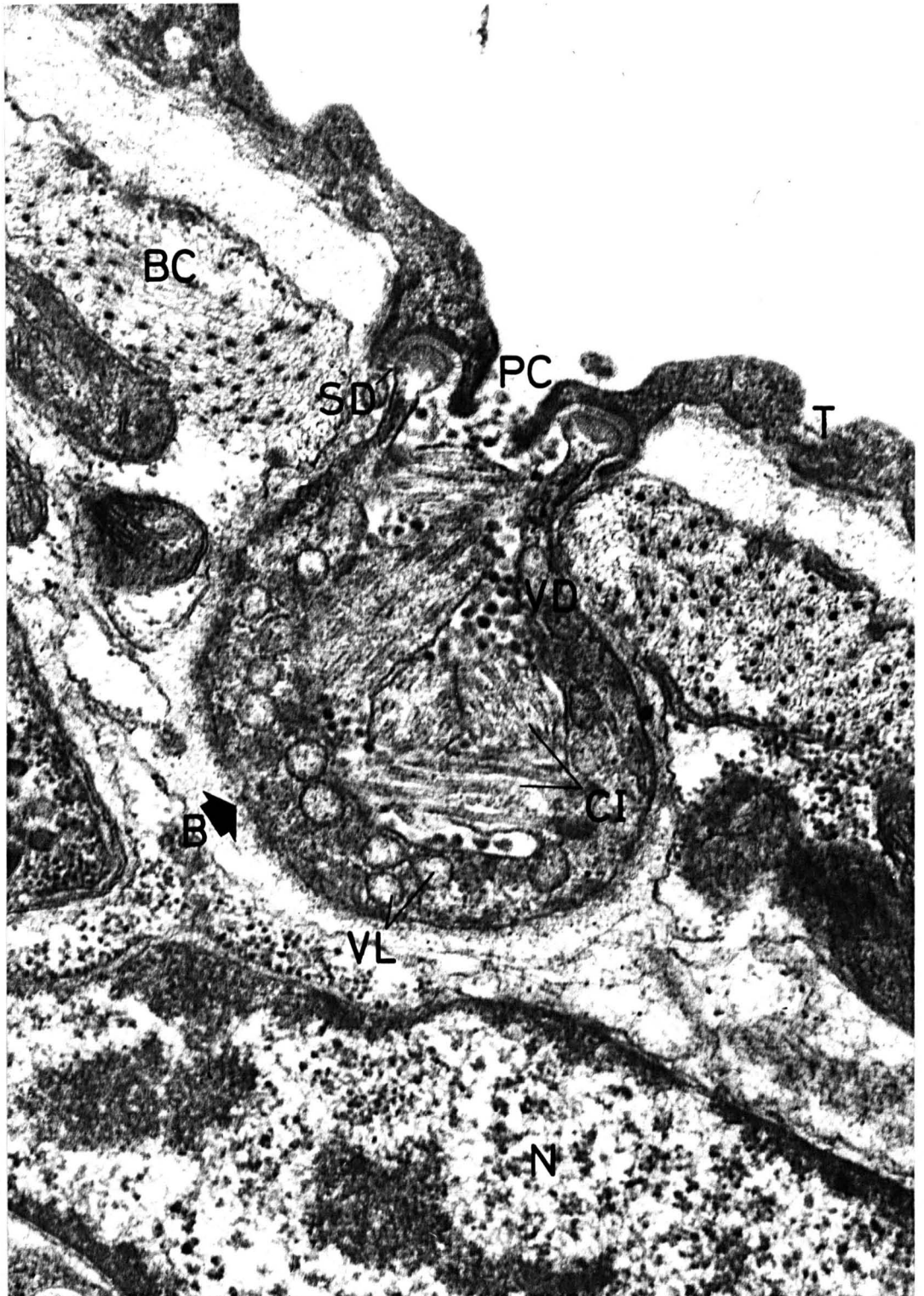

Fig. 123. Section through wall of nerve bulb shown in Fig. 124.

Prominent, large, clear vesicles seen. X57000.

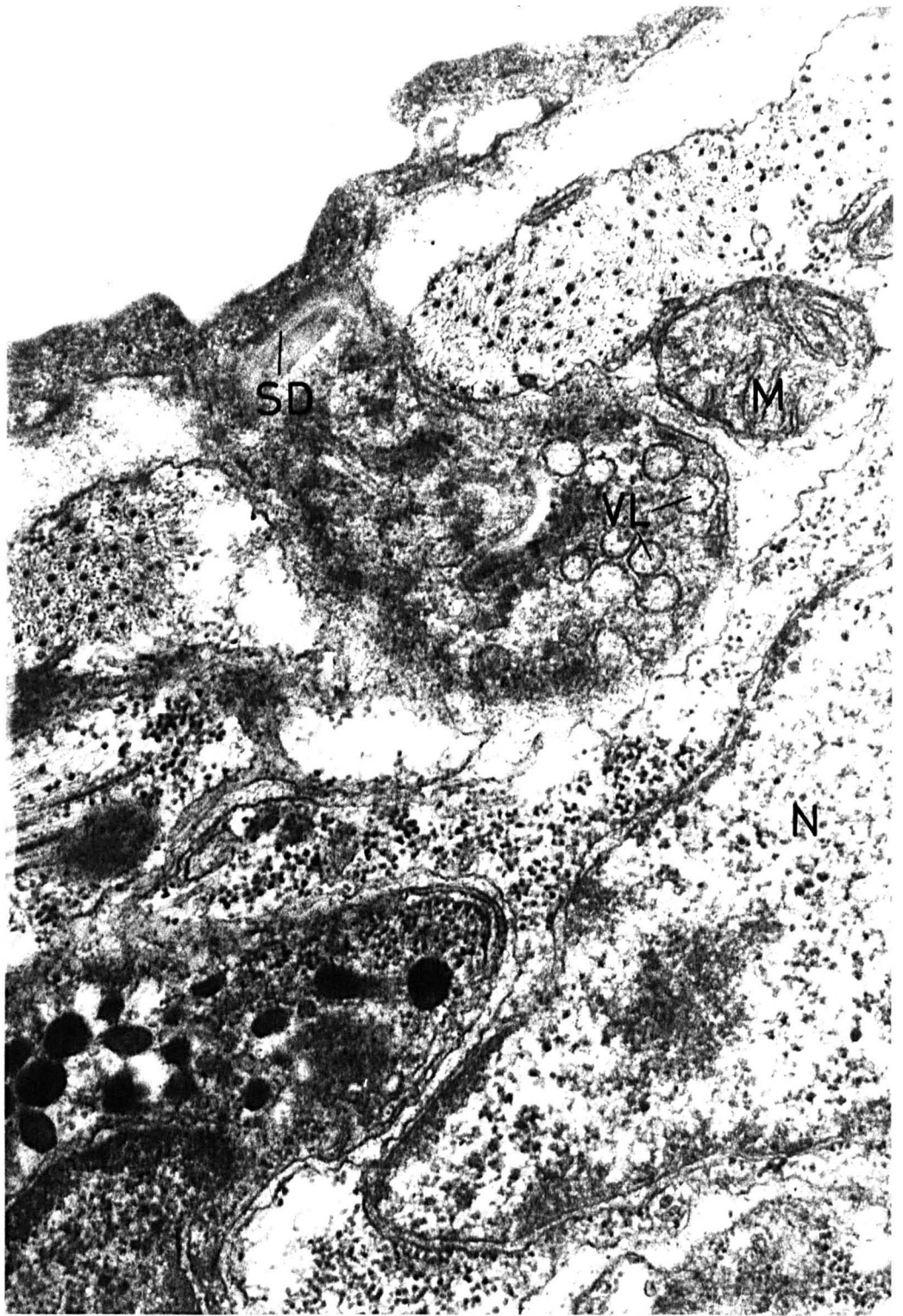

Fig. 124. Section through ciliated cavity. Cilia clearly attached to inside of bulb wall and contain 'double' microtubules. Many small, dense vesicles in cavity. Tripartite nature of desmosome attachment to tegument demonstrated. X55100.

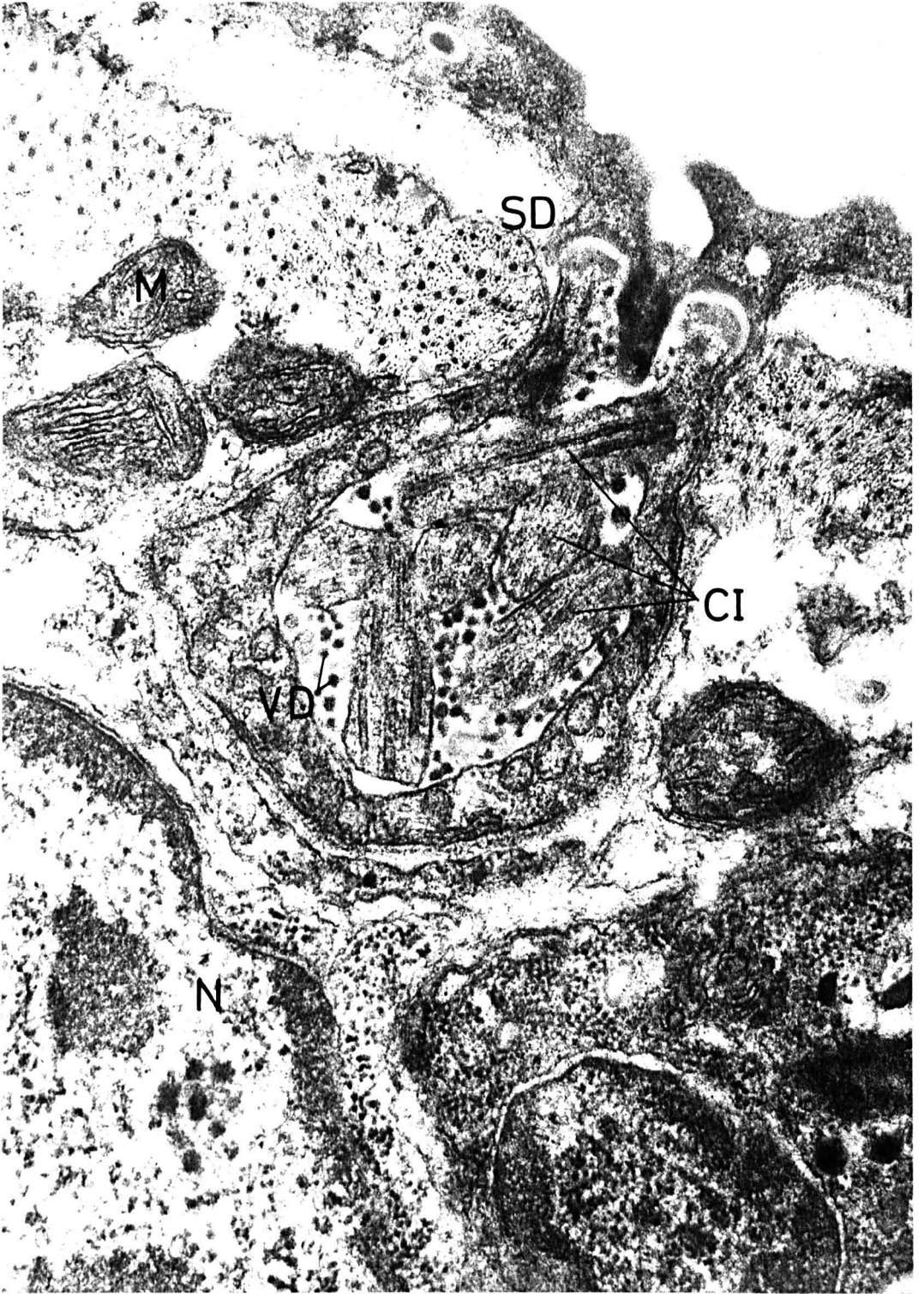


Fig. 125. Further section through same cavity as shown in Fig. 124.

X55100.

Fig. 126. Ciliated cavity near anterior end of body. Transverse sections of several cilia include 9 + 1 pattern; shape of cilia slightly irregular. X24000.

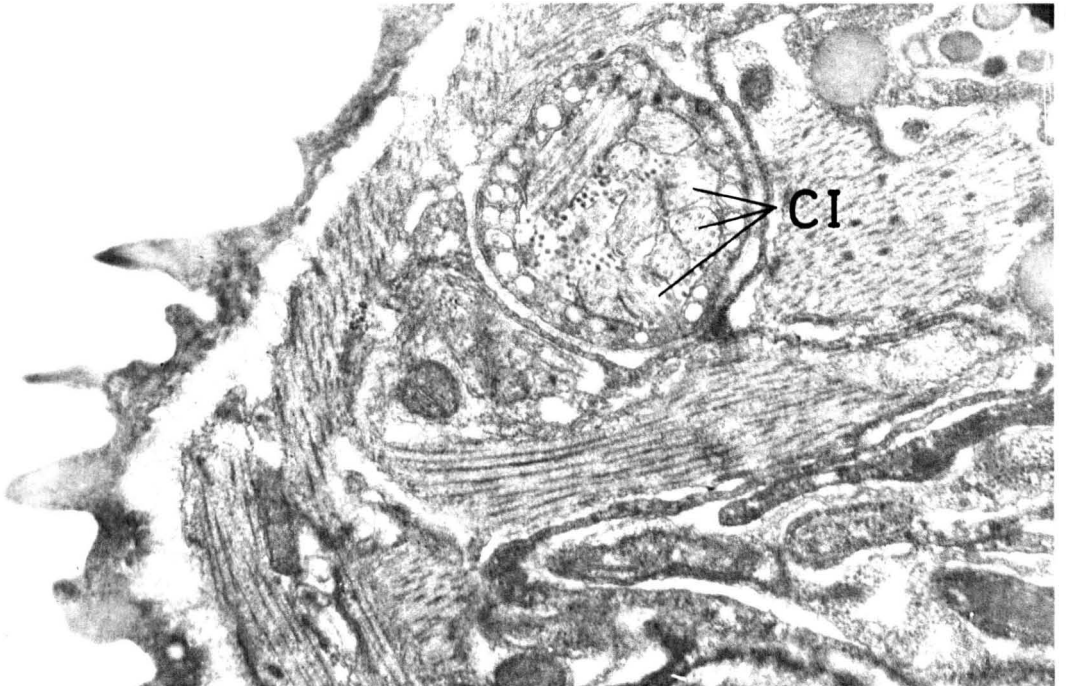
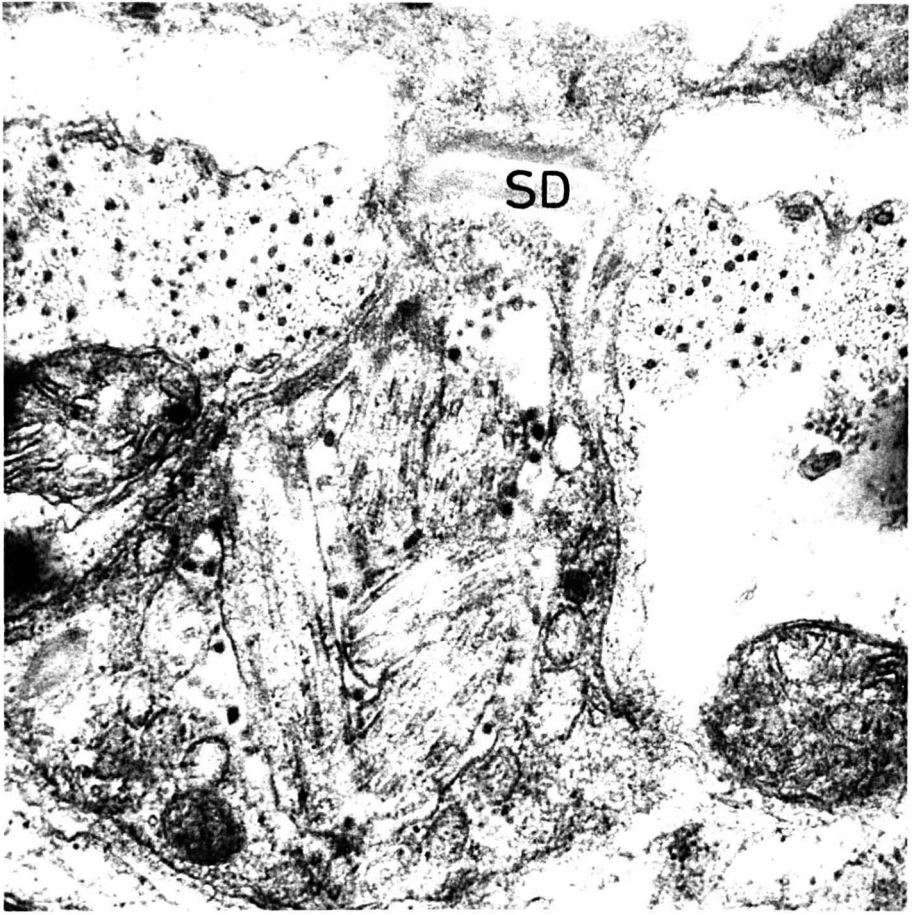


Fig. 127. Ciliated cavity receptor. Ciliary microtubules continuous with basal bodies in bulb wall. Clear vesicles present in axon. High density of small, dense vesicles in cavity. X38000.

Figs. 128-129. A pair of ciliated cavities, one situated on each side of the anterior end of the body. Both 9 + 1 and 9 + 0 microtubule patterns visible. X38000.

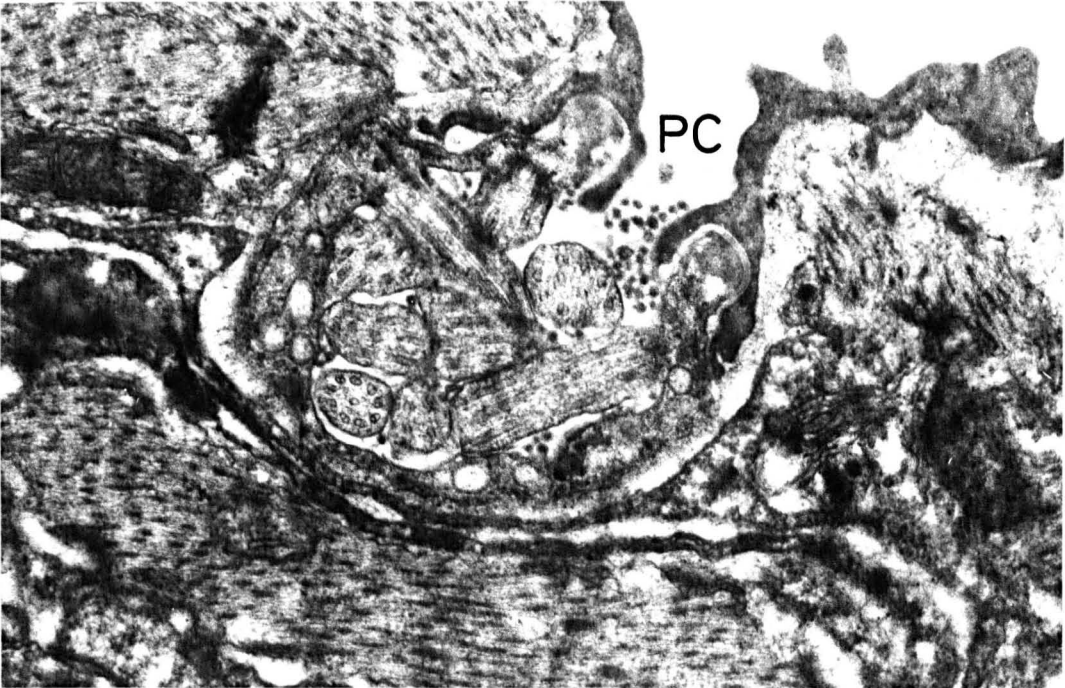
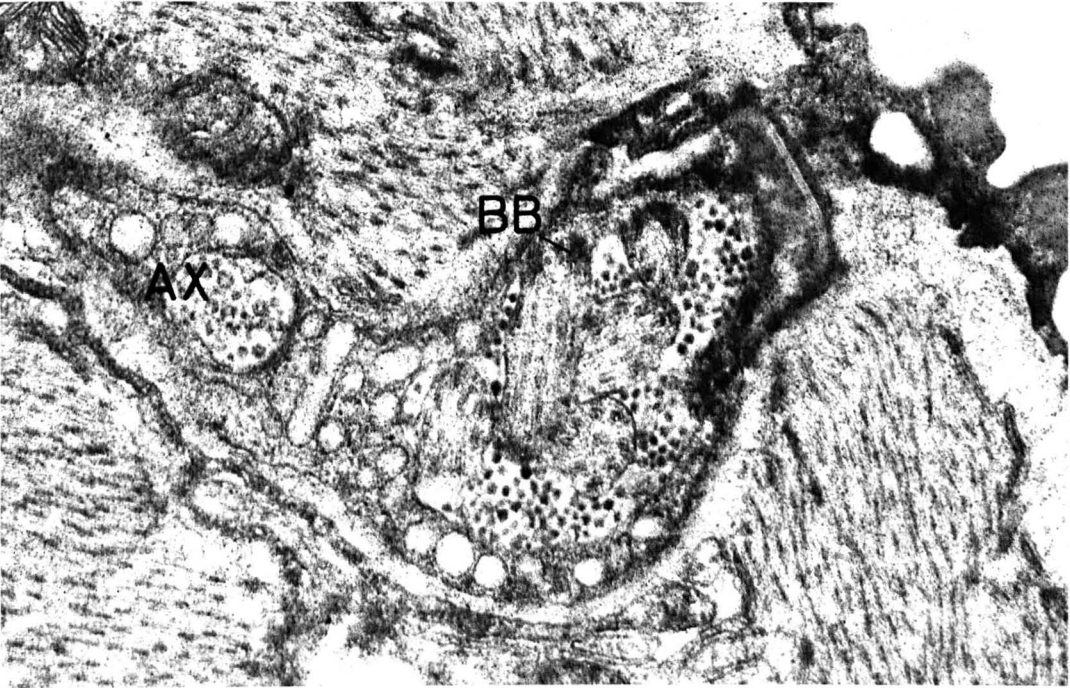


Fig. 129. See Fig. 128.

Figs. 130 - 131. Sections at two levels through a receptor complex on the oral sucker surface. Two multiciliate and one uniciliate cell are seen. X38000.

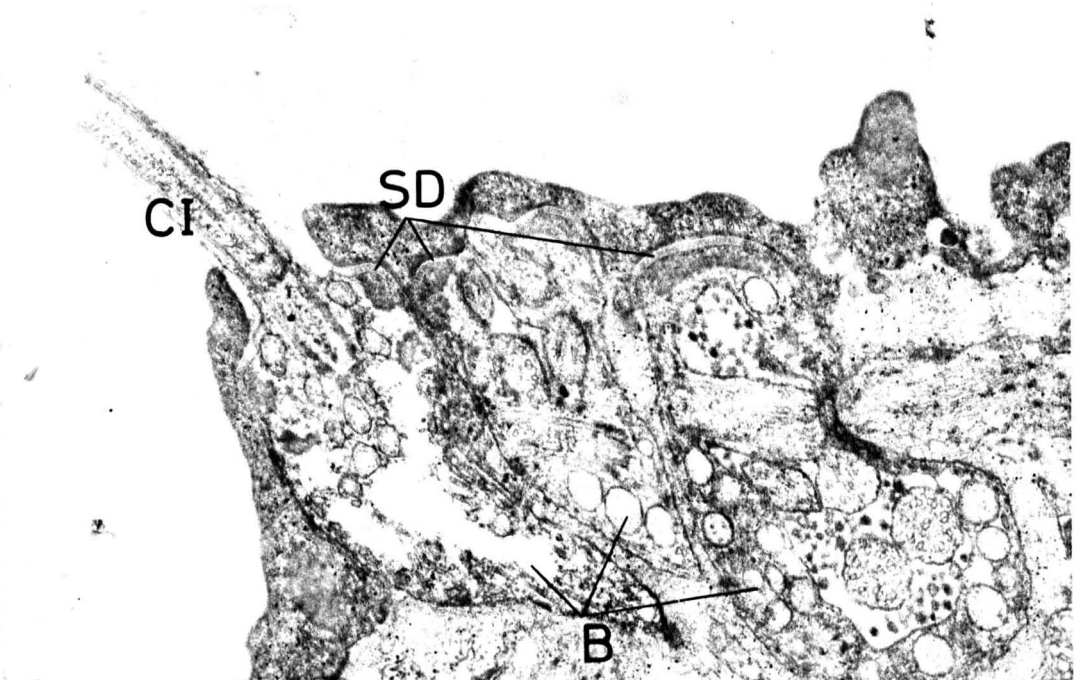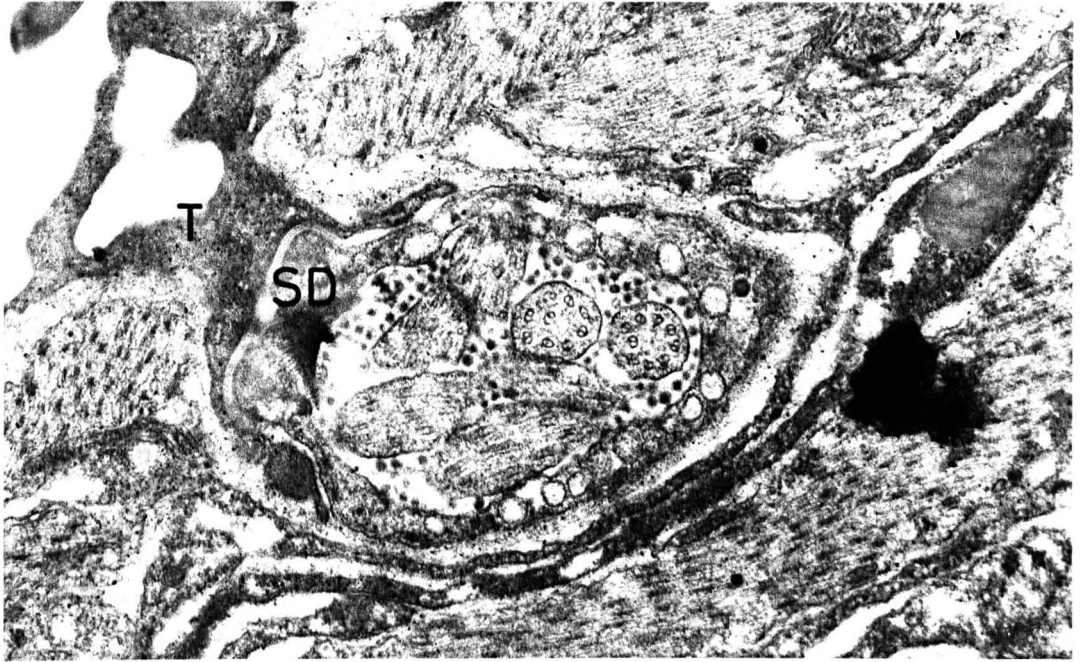


Fig. 131. See Fig. 130.

Fig. 132. At least one ciliated cavity is seen close to the group of sheathed, unciliated receptors of the oral disc. X24000.

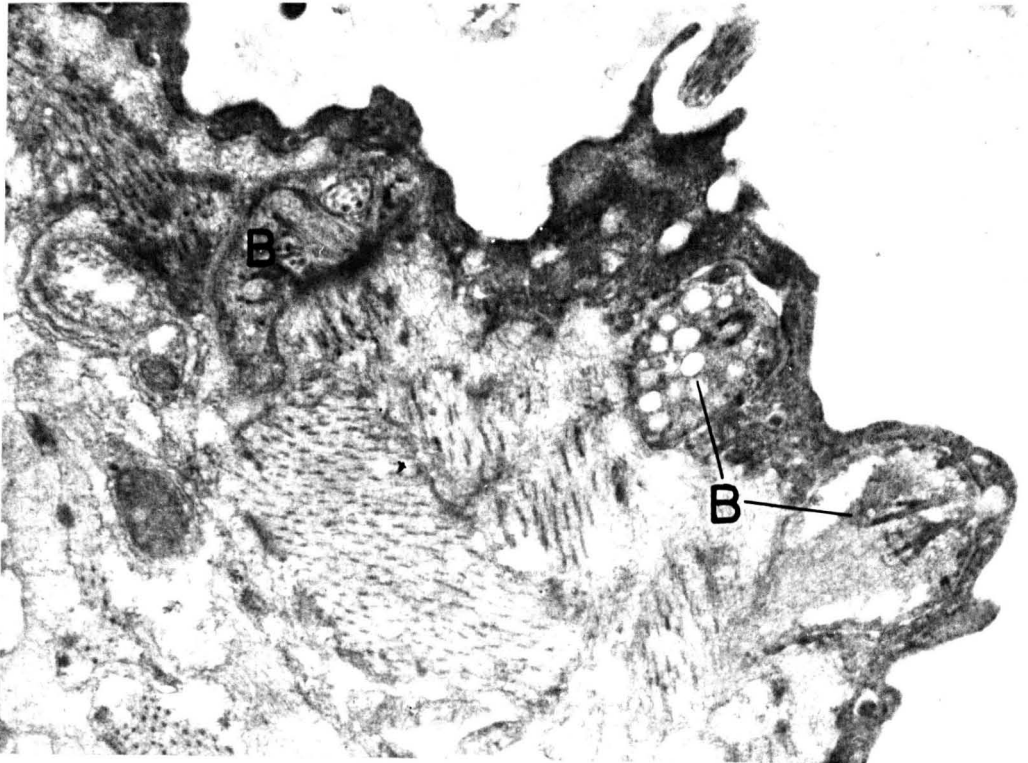
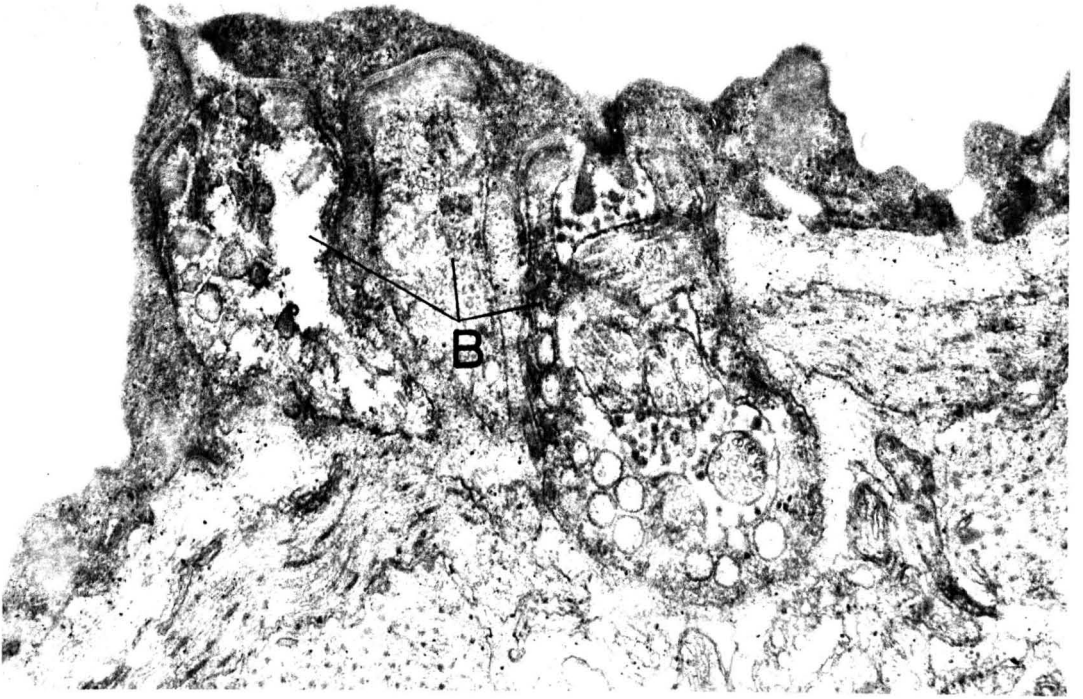


Fig. 133. Cell resembling a ciliated cavity receptor, but some cilia project through pore to the exterior. X48300.

Fig. 134. Transverse section of cilia, possibly from type of cells shown in Fig. 133. X48600.

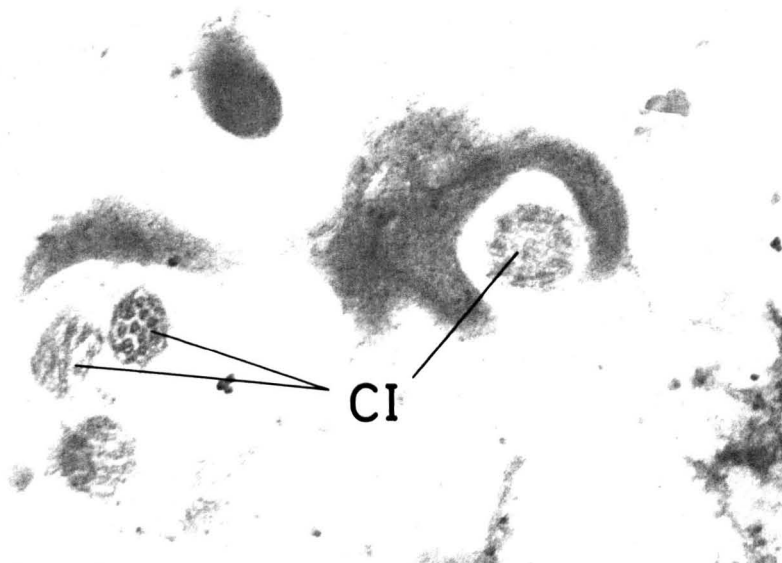
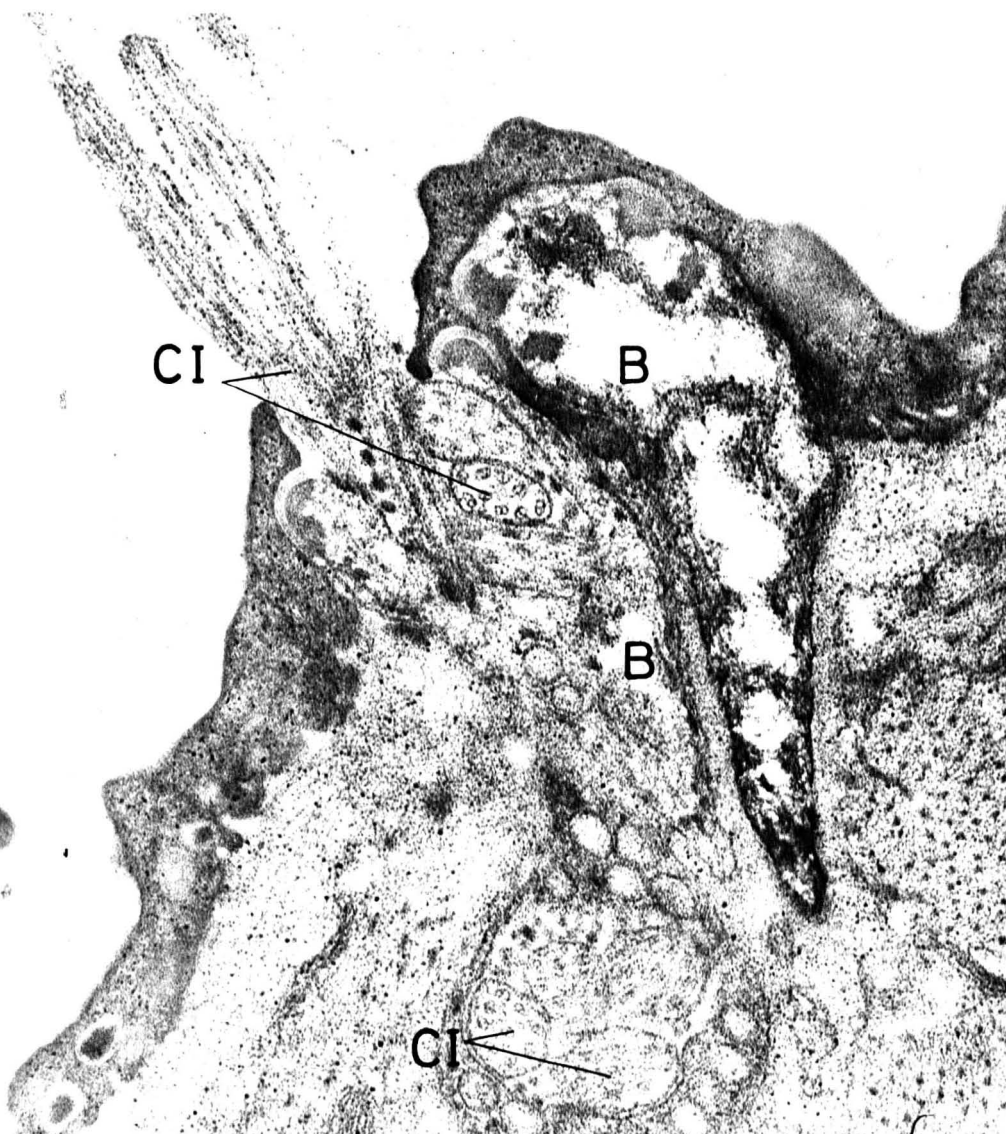
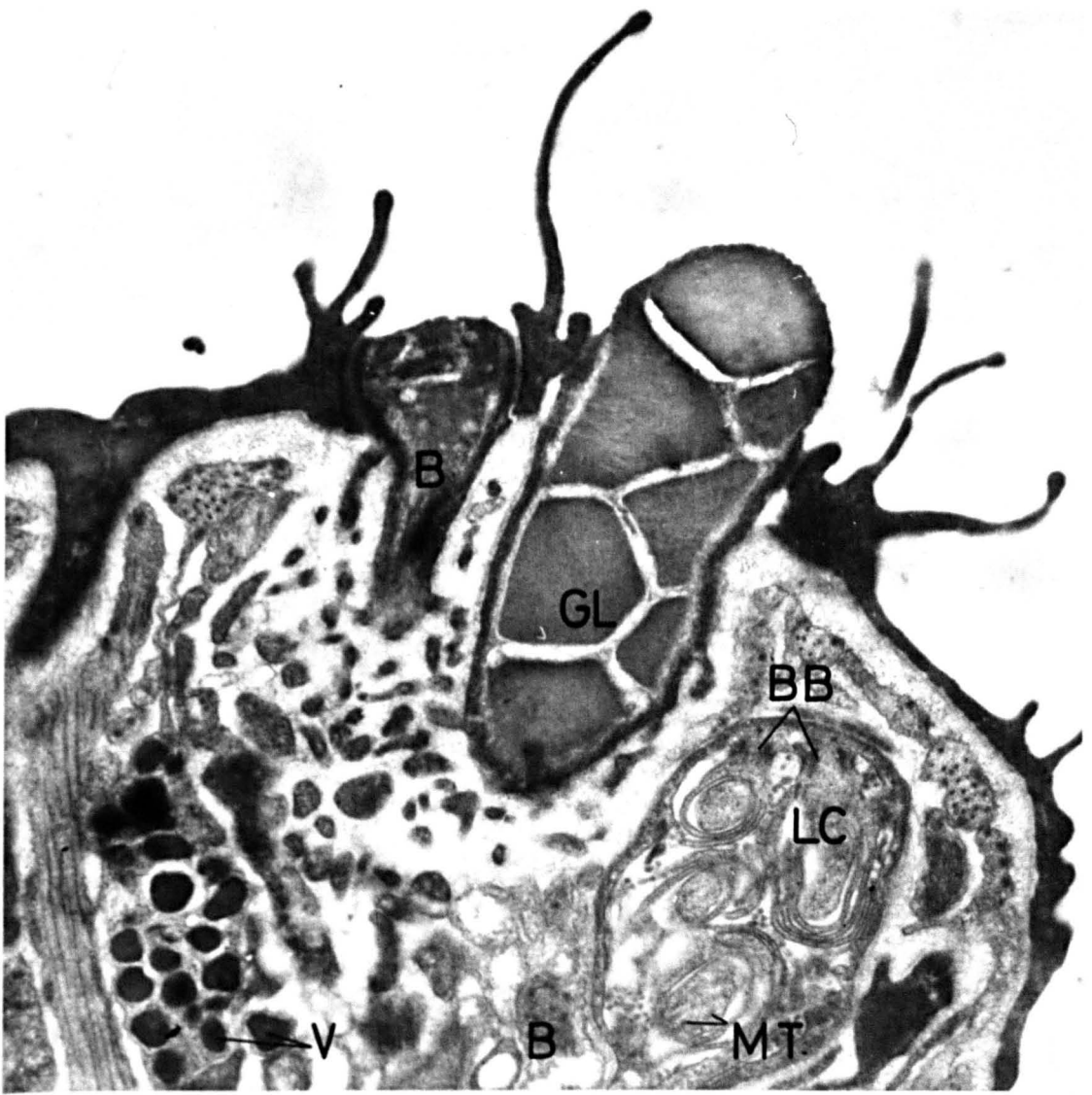


Fig. 135. Situation of one laminated receptor near gland duct exit.

Note basal bodies in wall of receptor cell. X25300.



Figs. 136-146. Light micrographs of whole mount of cercarial body.

Acetylcholinesterase preparation: +ve reaction is reddish-brown, but may also be straw-coloured.

Fig. 137 See Fig. 136.

Fig. 138. See Fig. 136.

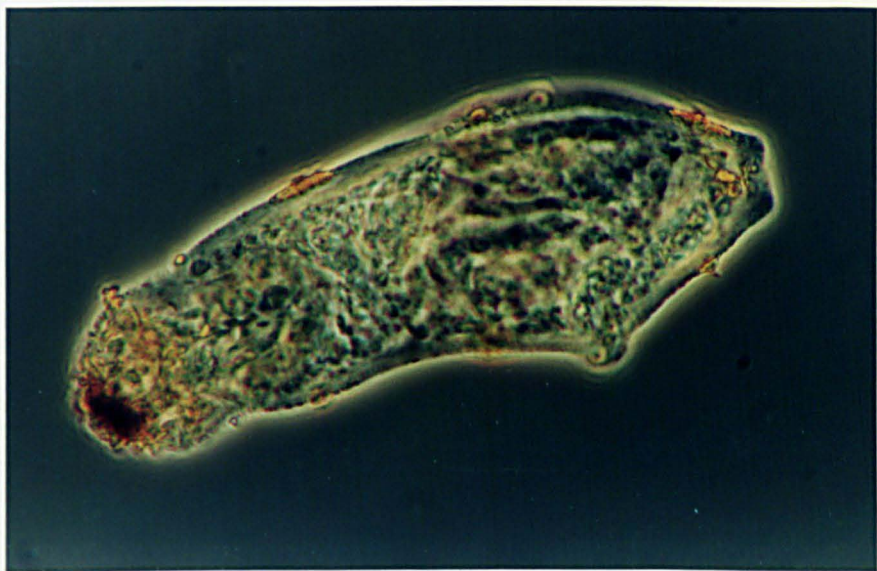
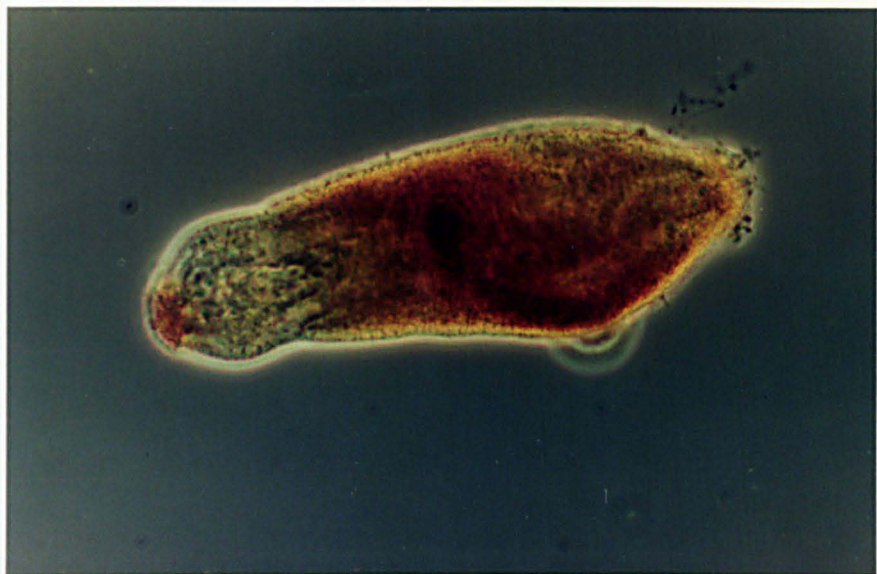
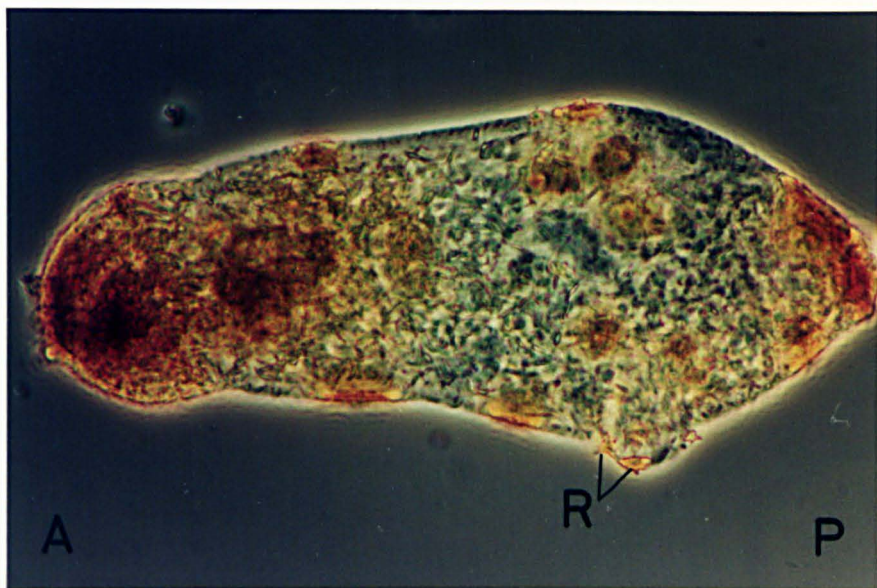Fig. 139. See Fig. 136.

Fig. 140. See Fig. 136.

Fig. 141. See Fig. 136.

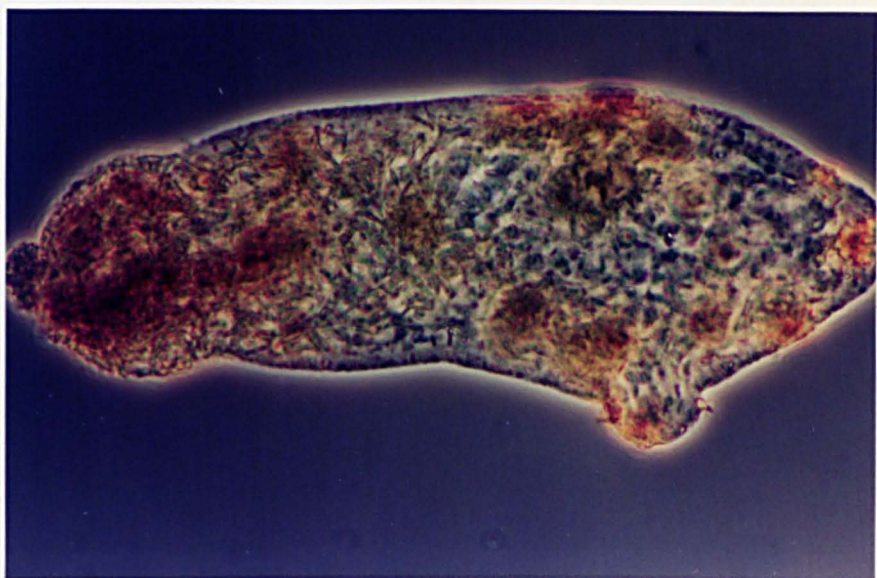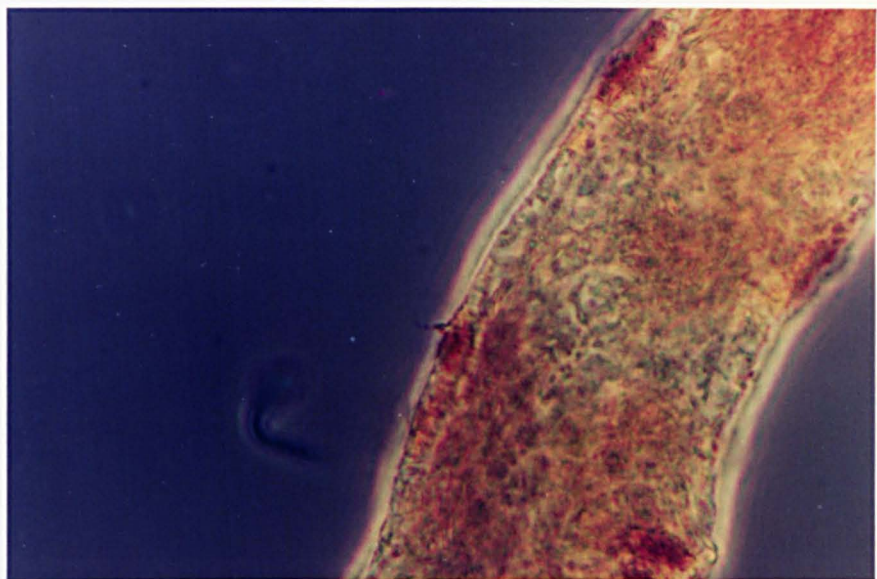

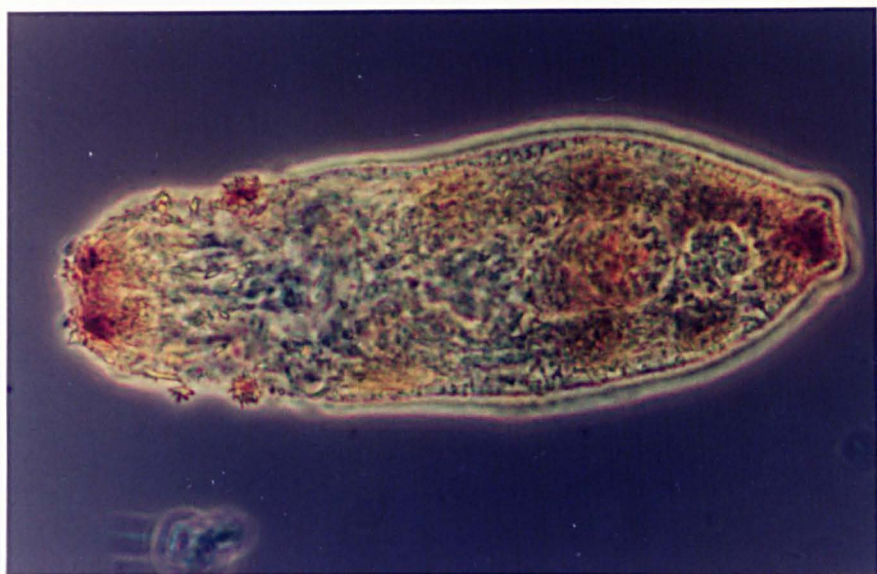
Fig. 142. See Fig. 136

Fig. 143. See Fig. 136.

Fig. 144. See Fig. 136.

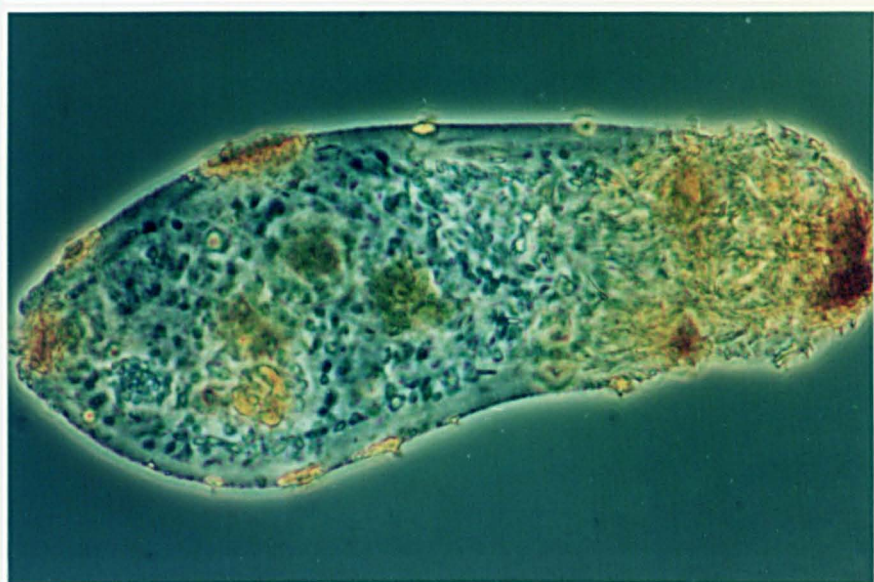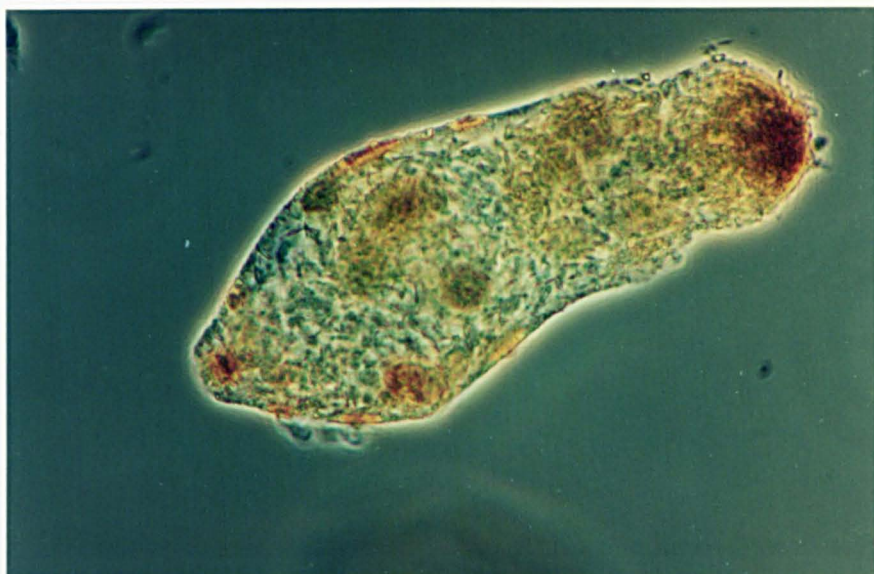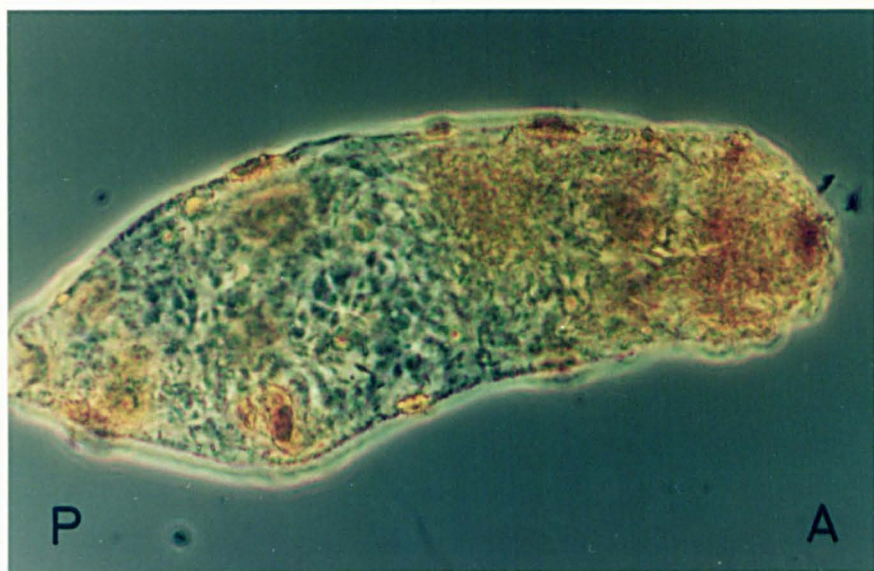


Fig. 145. See Fig. 136.

Fig. 146. See Fig. 136.

Figs. 147-152. Light micrographs of whole mounts of cercarial tail.

Acetylcholinesterase preparation : surface reactions appear
as straw-coloured regions.

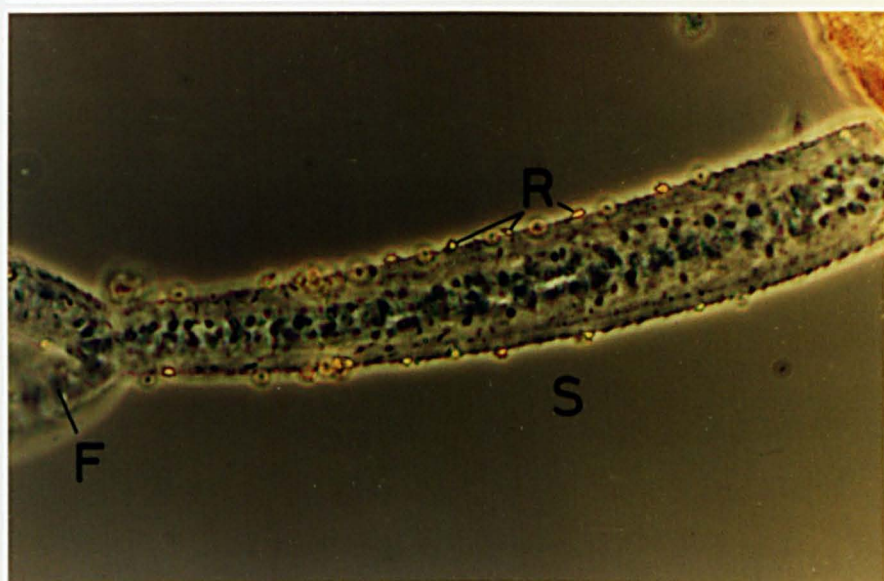
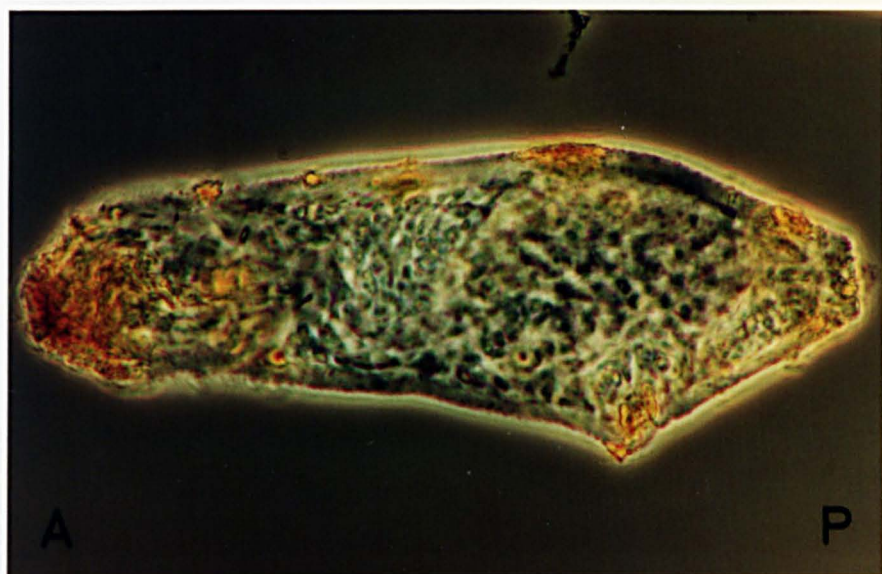
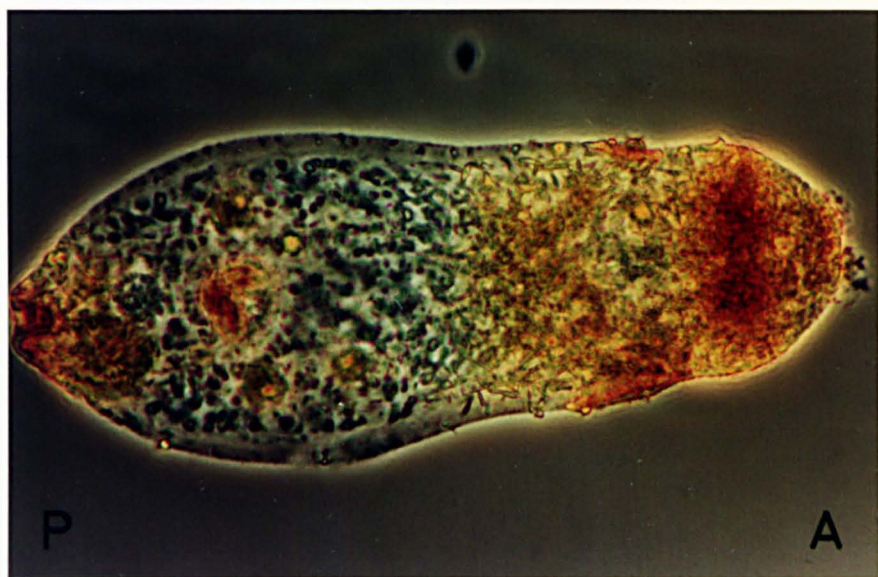Fig. 148. See Fig. 147.

Fig. 149. See Fig. 147.

Fig. 150. See Fig. 147.

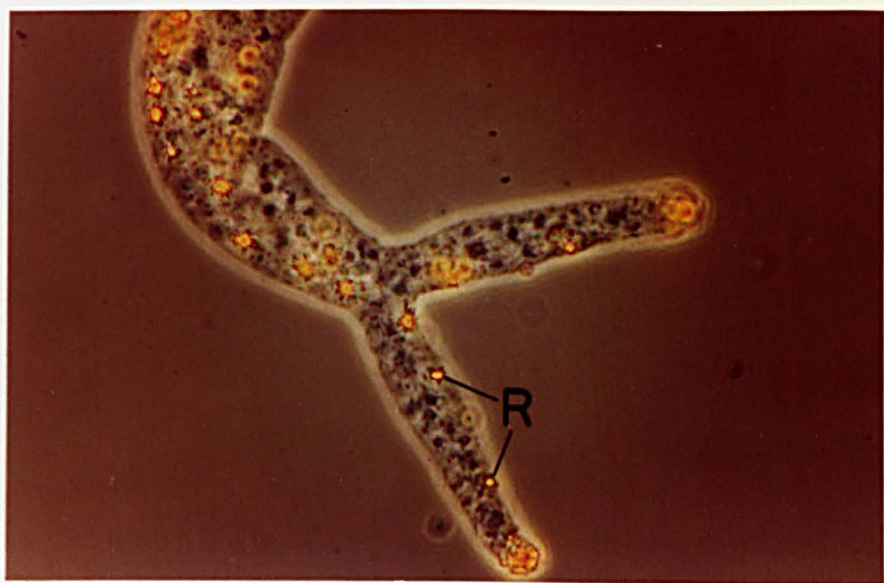
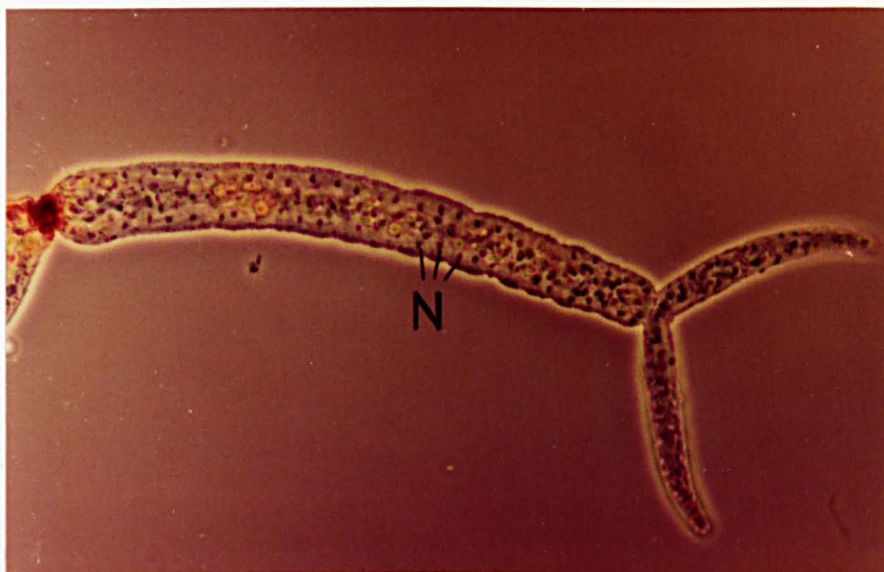
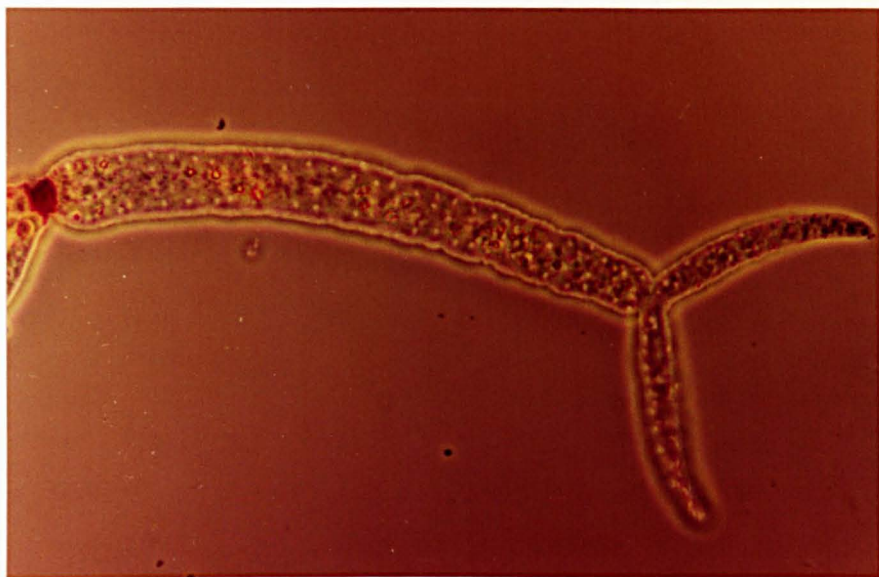
Fig. 151. See Fig. 147.

Fig. 152. See Fig. 147.

