

**The role of ultrasonography in the
investigation and management of
rheumatic conditions**

by

Dr Zunaid Karim

Submitted in accordance with the requirements for
the degree of Doctorate in Medicine

University of Leeds

October 2006

I confirm that the work submitted here is my own
and that appropriate credit has been given where
reference has been made to work of others

This copy has been supplied on the understanding that it is copyright material and
that no quotation from the thesis may be published without proper acknowledgement

Abstract

Aims: The importance of inflammation in the development of joint damage and subsequent functional limitation, together with the increasing awareness that clinical assessment is insensitive at detecting synovitis, has led to the use of modern imaging modalities such as ultrasonography (US) in rheumatology. This with an emphasis on improved detection of synovitis and earlier, more effective therapeutic intervention. The aim of this thesis was to investigate the role of US in routine practice, by validating its role in diagnosis, prognosis and therapeutic intervention, across a range of common rheumatological clinical scenarios.

Methods: Construct validity for US-detected synovitis in knee arthritides was examined by comparison with clinical assessment and arthroscopy. In order to examine the benefits of US-guided joint injections, the accuracy of guided shoulder injections was observed. As well, the efficacy of US-guided corticosteroid injections in hip osteoarthritis and predictors of outcome were also assessed. The sensitivity of US over clinical examination was assessed in a cohort of rheumatoid arthritis patients with low disease activity levels. The diagnostic and therapeutic predictive value of US-detected synovitis in inflammatory hand pain was examined in a large cohort. Finally the clinical utility of US at altering diagnosis and management in clinical rheumatology practice was prospectively examined.

Results: For detection of knee synovitis, using arthroscopy as the gold-standard, US had higher sensitivity (98 vs 85%) and specificity (75 vs 25%) than clinical assessment. Kappa values for inter- and intra-reader reliability of US were 0.71 and 0.85 respectively. In the shoulder US-guided injections were 100% accurate, but

55% had evidence of extrabursal contrast limited to the tissue planes adjacent to the bursa. Outcome following hip injection was poor, but synovitis without osteophytes on US was the best predictor of short term benefit. In rheumatoid arthritis patients in clinical remission, the majority satisfying established remission criteria, US detected gray-scale and power Doppler (PD) synovitis in 85% and 60% patients respectively. The kappa value for inter-reader reliability was 0.60 for gray-scale, and intra-reader reliability was 0.60 for gray-scale and 0.62 for PD. Most inflammatory hand pain patients without clinical evidence of an inflammatory arthritis had US synovitis (55%); and US ($p < 0.001$), but not clinical, synovitis was significantly associated with response to parenteral corticosteroid therapy. The site-specific diagnosis (53%) and management (53%) was altered in most patients referred for US in a routine clinic.

Conclusion: Ultrasonography is now well validated in synovitis detection in small and large joints, and this has substantial implications for the accurate and early diagnosis of inflammatory arthritis, as well as in monitoring outcomes to therapy in rheumatoid arthritis. Ultrasonography can aid prognosis as well as improving placement of guided intra-articular therapies. This work has demonstrated that US has a significant role to play in rheumatology practice.

Acknowledgements

I would like to thank Richard Wakefield and Philip O'Connor for teaching me to perform Ultrasonography which has been essential for this thesis and for Phil O Connor for also supervising my MD. I would like to thank Philip Conaghan for being an excellent mentor and supervisor, and Paul Emery for providing me with the opportunity to work at the Academic unit in Leeds and also for supervising my MD. For the contribution towards the inception, development and execution of the work contained in this thesis, I would like to thank Richard Wakefield and Philip Conaghan. I would like to extend a thank you to Anne-Maree Keenan for her help with endnote reference manager and the formatting of this thesis.

Thanks to my parents for ensuring I received a good education, and finally thanks to my wife Nabilah, and our children Nazir, Jameel, Sumaiyah and Aadil for their support throughout.

Arthritis Research Campaign

I would like to thank the Arthritis Research Campaign for helping fund some of this work.

Academic Unit of Musculoskeletal Disease, University of Leeds

Thanks to the many clinical colleagues and friends in the Early Arthritis Clinic for their support. I would particularly like to thank Mark Quinn and Andy Brown for the clinical assessment of subjects in much of the work in this thesis.

Chapter 3

Mark Quinn for performing arthroscopy and Karen Henshaw for collecting the arthroscopy data. Richard Wakefield for performing ultrasonography in the cohort to assess reliability, and Philip Helliwell and Elizabeth Hensor for statistical input.

Chapter 4

Philip O'Connor for performing the injections, and the radiographers in his unit for their technical support.

Chapter 5

Andrew Brown and Geraldine Jackson for performing patient assessments.

Chapter 6

Andrew Brown for the clinical assessment of patients, Claire Brown for metrology, Philip Conaghan for reading the x-rays, and Elizabeth Hensor for statistical input..

Chapter 7

Geraldine Jackson for performing metrology and co-ordinating patient appointments, and Elizabeth Hensor for statistical input.

Chapter 8

All the Consultant Rheumatologists for filling out the ultrasonography request forms and Richard Wakefield for performing ultrasonography.

Publications Arising

Karim Z, Wakefield RJ, Conaghan PG, Lawson CA, Goh E, Quinn MA, Astin P, O'Connor PJ, Gibbon WW, Emery P. The impact of ultrasonography on diagnosis and management of patients with musculoskeletal conditions. *Arthritis Rheum* 2001;44:2932-3

Conaghan PG, **Karim Z**, Green M, McGonagle D, Emery P. The use of imaging in the assessment of common rheumatological clinical problems: multiple peripheral joint swelling. In: Isenberg D, Renton P, editors. *Imaging in Rheumatology*. Oxford: Oxford University Press; 2002. P. 147-159

Karim Z, Conaghan PG. The role of ultrasonography in the diagnosis and management of rheumatic conditions. In: Marzo-Ortega H, Conaghan PG, Emery P, eds. *Arthritis care for the new millennium: the Leeds experience*

Wakefield RJ, Brown A, O'Connor P, Grainger A, **Karim Z**, McGonagle D, Conaghan P, Emery P. Rheumatological Ultrasound. *Rheumatology*. 2003;42:1001

Wakefield RJ, Goh E, Conaghan PG, **Karim Z**, Emery P. Musculoskeletal ultrasonography in Europe: results of a rheumatologist-based survey at a EULAR meeting. *Rheumatology*. 2003;42:1251-3

Karim Z, Brown AK, O Connor PJ, Quinn M, Jackson G, Wakefield RJ, Conaghan PG, Emery P. Ultrasound-guided steroid injections in the treatment of hip osteoarthritis: Comment on the letter by Margules. *Arthritis Rheum* 2004;50:338-339

Brown AK, Wakefield RJ, Conaghan PG, **Karim Z**, O'Connor PJ, and Emery P. New approaches to imaging early inflammatory arthritis. *Clinical and Experimental Rheumatology* 2004;22:S18-25

Karim Z, Wakefield RJ, Quinn MA, Conaghan PG, Brown A, Veale DJ, O Connor P, Reece R, Emery P. Validation and reproducibility of Ultrasonography in the detection of synovitis in the knee: a comparison with arthroscopy and clinical examination. *Arthritis Rheum* 2004;50:387-94

Brown AK, O'Connor PJ, Wakefield RJ, Roberts TE, **Karim Z**, Emery P. Evaluation of practice, training and assessment amongst experts performing musculoskeletal ultrasonography – towards the development of an international consensus of educational standards for ultrasonography for rheumatologists. *Arthritis Rheum* 2004;51:1018-22

Wakefield RJ, Brown AK, O'Connor PJ, **Karim Z**, Grainger A. Musculoskeletal ultrasonography: what is it and should training be compulsory for rheumatologists? *Rheumatology (Oxford)* 2004;43:821-2

Brown AK, O'Connor PJ, Roberts TE, Wakefield RJ, **Karim Z**, and Emery P. Recommendations for musculoskeletal ultrasonography by rheumatologists: setting global standards for best practice by expert consensus. *Arthritis Rheum* 2005;53:83-92

Fraser AD, van Kuijk AWR, Westhovens R, **Karim Z**, Wakefield R, Gerards AH, Landewe R, Steinfeld SD, Emery P, Dijkmans BAC, Veale DJ. A randomised, double-blind, placebo controlled, multi-centre trial of combination therapy with methotrexate plus cyclosporine in patients with active psoriatic arthritis. *Ann Rheum Dis* 2005;64:859-64

Brown AK, Wakefield RJ, **Karim Z**, Roberts TE, O'Connor PJ, Emery P. Evidence of effective and efficient teaching and learning strategies in the education of rheumatologist ultrasonographers: evaluation from the 3rd BSR musculoskeletal ultrasonography course. *Rheumatology (Oxford)* 2005;44:1068-9

Brown AK, O'Connor PJ, Roberts TE, Wakefield RJ, **Karim Z**, and Emery P. Ultrasonography for rheumatologists: the development of specific competency based educational outcomes. *Ann Rheum Dis* 2006;65:629-36

Brown AK, Quinn MA, **Karim Z**, Conaghan PG, Petefry CG, Hensor E, Wakefield RJ, O Connor PJ, Emery P. Presence of significant synovitis in rheumatoid arthritis patients with disease-modifying antirheumatic drug-induced clinical remission: evidence from an imaging study may explain structural progression. *Arthritis Rheum* 2006;54:3761-73

Karim Z, Quinn MA, Wakefield RJ, Brown AK, Green MJ, Hensor EMA, Conaghan PG, Emery P. Inflammatory hand pain: An algorithm for ultrasonography, clinical assessment and response to intramuscular methyl prednisolone treatment. *Annals Rheum Dis* 2007;66: 690-2

Brown AK, Roberts TE, O Connor PJ, Wakefield RJ, **Karim Z**, Emery P. The development of an evidence-based educational framework to facilitate the training of competent rheumatologist ultrasonographers. *Rheumatology (Oxford)* 2007;46:391-7

Brown AK, Roberts TE, Wakefield RJ, **Karim Z**, Hensor E, O Connor PJ, Emery P. The challenges of integrating ultrasonography into routine rheumatology practice: addressing the needs of clinical rheumatologists. *Rheumatology (Oxford)* 2007;46:821-9

Presentations Arising

“The effect of ultrasonography on the diagnosis and management of patients with musculoskeletal conditions”, 3rd EULAR Sonography course, Milan, Italy, April 2001

“Ultrasound- A Rheumatologists view point,” 3rd British Musculoskeletal Ultrasound course, Leeds, June 2001

“Current and future technological developments in Musculoskeletal Ultrasonography”, 4th EULAR Sonography Course, Madrid, Spain, April 2002

“Impact of Sonography on the diagnosis and management of patients with musculoskeletal conditions”, 66th ACR Annual Scientific Meeting, New Orleans 2003

“Ultrasound of the shoulder”, 3rd British Society for Rheumatology Introductory Musculoskeletal Ultrasound Course, Harrogate, 2004

“Ultrasound of the knee”, 4th British Society for Rheumatology Introductory Musculoskeletal Ultrasound Course, Newcastle, 2005

“Ultrasonography, the future of Imaging”, Wakefield PCT Target meeting, Rogerthorpe Manor Hotel, February 2007

Abbreviations

ACJ	Acromioclavicular Joint
ACR	American College of Rheumatology
ANOVA	Analysis of Variance
APL	Abductor Pollicis Longus
BMUS	British Musculoskeletal Ultrasound Society
BSR	British Society for Rheumatology
CD	Colour Doppler
CRP	C-reactive protein
CT	Computed Tomography
DMARD	Disease modifying Anti-rheumatic Drug
DRU	Distal Radio-Ulnar
EAC	Early Arthritis Clinic
EPB	Extensor Pollicis Brevis
ESR	Erythrocyte Sedimentation Rate
EULAR	European League against Rheumatism
HAQ	Health Assessment Questionnaire
HLA	Human Leucocyte Antigen
HRUS	High Resolution Ultrasonography
IC	Inter-Carpal
ICC	Intraclass Correlation Coefficients
IHP	Inflammatory Hand Pain
IM MP	Intra-muscular Methyl Prednisolone
MCP	Metacarpophalangeal
MRI	Magnetic Resonance Imaging

NPV	Negative Predictive Value
OA	Osteoarthritis
OD	Overall Diagnosis
OMERACT	Outcome Measures in Rheumatology
PPV	Positive Predictive Value
PD	Power Doppler
PIP	Proximal Interphalangeal
PJC	Painful Joint Count
PsA	Psoriatic Arthritis
PV	Plasma Viscosity
RA	Rheumatoid Arthritis
RC	Radio-Carpal
RF	Rheumatoid Factor
SJC	Swollen Joint Count
SpA	Spondyloarthropathy
SSD	Site-specific Diagnosis
THR	Total Hip Replacement
TJC	Tender Joint Count
UC	Ulnar-Carpal
US	Ultrasonography
VAS	Visual Analogue Scale

Table of Contents

Abstract	ii
Acknowledgements	iv
Publications Arising	vi
Presentations Arising	x
Abbreviations	xi
Chapter 1	1
1.1 Introduction	1
Chapter 2	3
2.1 History, Clinical Utility and Validity	3
2.2 History of Ultrasonography	3
2.2.1 Bats and Bells.....	3
2.2.2 Piezoelectricity.....	3
2.2.3 Ships and Submarines	4
2.2.4 SONAR.....	4
2.2.5 Reflectoscope and “Medical Ultrasound”	5
2.2.6 B-mode scanning.....	7
2.2.7 Musculoskeletal Ultrasonography	9
2.2.8 Dasonograph	10
2.2.9 Ultrasonography or Ultrasound?.....	13
2.3 Technological developments in Ultrasonography	14
2.3.1 Transducers	14
2.3.2 Doppler.....	17
2.3.3 Harmonics, inverted pulse modes and Gray-scale flow imaging.....	18
2.3.4 Extended field of view	18
2.3.5 Microbubbles	19
2.4 Changes in the use of Ultrasonography with time	21
2.4.1 Improvements in image quality.....	21
2.4.2 Early treatment improves outcome	21
2.4.3 Advantages of Ultrasonography.....	22
2.4.4 Disadvantages of Ultrasonography	23
2.4.5 Publications with use of Ultrasonography in Rheumatic Conditions	24
2.4.6 Ultrasonography is out of this world.....	24
2.5 Validity and Reliability of Ultrasonography	25
2.5.1 Definitions of Validity	25
2.6 What features can Ultrasonography detect?	28
2.6.1 Synovitis and Effusion	29
2.6.2 Tendon and Enteseal Pathology	47
2.6.3 Erosions.....	55

2.7 US-guided therapy	59
2.7.1 MCP, flexor tendon sheath injections	59
2.7.2 Aspiration and injection	59
2.7.3 US-guided wrist injection; injection site and response to therapy.....	60
2.7.4 US-guided carpal tunnel release; comparison with conventional surgery	60
2.7.5 Caudal injections.....	60
2.7.6 Iliopsoas abscess	61
2.7.7 Plantar fascia	61
2.8 Reliability of Ultrasonography	62
2.8.1 MCP, PIP, DIP synovitis and erosions in arthritis.....	62
2.8.2 Gray-scale, PD synovitis in finger and wrist RA.....	62
2.8.3 MCP erosions in RA	63
2.8.4 Rotator cuff tears.....	63
2.8.5 Knee effusion; comparison with clinical assessment.....	64
2.8.6 PD in knee synovitis	64
2.9 Summary and aims of this thesis	65
2.9.1 Format	65
2.9.2 Chapter 3	65
2.9.3 Chapter 4	65
2.9.4 Chapter 5	66
2.9.5 Chapter 6	66
2.9.6 Chapter 7	66
2.9.7 Chapter 8	67
2.9.8 Chapter 9	67
Chapter 3	68
3.1 Knee synovitis: Construct Validity	68
3.2 Clinical relevance	68
3.3 Abstract	69
3.3.1 Aims	69
3.3.2 Methods.....	69
3.3.2 Results.....	69
3.3.4 Conclusions.....	70
3.4 Introduction	71
3.5 Methods	73
3.5.1 Patients	73
3.5.2 Clinical Assessment	73
3.5.3 Ultrasonography.....	73
3.5.4 Medical Arthroscopy.....	77
3.5.5 Statistical Analysis.....	80

3.6 Results	81
3.6.1 Ultrasonography compared with Arthroscopy	81
3.6.2 Clinical assessment compared with Arthroscopy	83
3.6.3 Clinical assessment compared with Ultrasonography	84
3.6.4 Arthroscopic Visual Analogue Scale	84
3.6.5 Reproducibility.....	85
3.7 Discussion	86
3.8 Subsequent literature	91
3.8.1 Knee osteoarthritis	91
3.8.2 Knee rheumatoid arthritis.....	92
3.8.3 Other joints.....	95
3.9 Summary	99
Chapter 4	100
4.1 Clinical Utility: Accuracy of Shoulder Injections	100
4.2 Clinical relevance	100
4.3 Abstract	101
4.3.1 Aims	101
4.3.2 Methods.....	101
4.3.3 Results	101
4.3.4 Conclusions.....	102
4.4 Introduction	103
4.5 Methods	105
4.5.1 Patients	105
4.5.2 Injection	105
4.5.3 X-ray	108
4.6 Results	110
4.7 Discussion	111
4.8 Subsequent literature	113
4.8.1 New Techniques.....	113
4.8.2 US compared with clinical aspiration	115
4.8.3 Accuracy	115
4.8.4 Outcome	117
4.9 Summary	119

Chapter 5	120
5.1 Efficacy and Predictive Validity of Guided Hip Injections	120
5.2 Clinical relevance	120
5.3 Abstract	121
5.3.1 Aims	121
5.3.2 Methods.....	121
5.3.3 Results.....	121
5.3.4 Conclusions	122
5.4 Introduction	123
5.5 Methods	125
5.5.1 Patients	125
5.5.2 Baseline assessment	125
5.5.3 Ultrasonography.....	126
5.5.4 Repeat assessments	128
5.5.5 Outcome measures	128
5.6 Results	129
5.6.1 Baseline assessment	129
5.6.2 Response	129
5.6.3 Predictors of response	130
5.7 Discussion	132
5.8 Subsequent literature	133
5.8.1 Validity of hip synovitis; comparison with histology.....	133
5.8.2 US injection with air ‘contrast’	133
5.8.3 Efficacy in hip OA	134
5.9 Summary	135
Chapter 6	140
6.1 Clinical Utility: Synovitis in clinical remission	140
6.2 Clinical relevance	140
6.3 Abstract	141
6.3.1 Aims	141
6.3.2 Methods.....	141
6.3.3 Results.....	141
6.3.4 Conclusions.....	142
6.4 Introduction	143

6.5 Methods	146
6.5.1 Patients.....	146
6.5.2 Inclusion criteria	146
6.5.3 Definitions of remission.....	146
6.5.4 Study assessments	147
6.5.5 Demographic and clinical characteristics	147
6.5.6 Laboratory assessment	148
6.5.7 Radiographic assessment	148
6.5.8 Ultrasonography.....	148
6.5.9 Analysis.....	154
6.6 Results	155
6.6.1 Patient demographics.....	155
6.6.2 Clinical, laboratory, function and quality of life assessments	157
6.6.3 Established remission criteria assessment	158
6.6.4 Ultrasonography.....	158
6.6.5 Established remission criteria vs. imaging measures of disease activity.....	159
6.6.6 Complete clinical remission vs. US synovitis.....	160
6.7 Discussion	161
6.8 Subsequent literature	164
6.9 Summary	164
Chapter 7	165
7.1 Clinical Utility: Predictive validity of US-detected synovitis	165
7.2 Clinical relevance	165
7.3 Abstract	166
7.3.1 Aims	166
7.3.2 Methods.....	166
7.3.3 Results	166
7.3.4 Conclusions.....	167
7.4 Introduction	168
7.5 Methods	172
7.5.1 Patients	172
7.5.2 Clinical assessment.....	172
7.5.3 Ultrasonography.....	173
7.5.4 Treatment	173
7.5.5 Outcome assessment	175
7.5.6 Statistical analysis	175

7.6 Results	177
7.6.1 Patient demographics	177
7.6.2 Baseline assessment	177
7.6.3 Response to IM MP	180
7.6.4 Response to HCQ	182
7.6.5 Other outcomes	182
7.7 Discussion	184
7.8 Subsequent literature	187
7.8.1 Efficacy of IM MP	187
7.9 Summary	188
Chapter 8	189
8.1 Clinical Utility: Impact of Ultrasonography	189
8.2 Clinical relevance	189
8.3 Abstract	190
8.3.1 Aims	190
8.3.2 Methods	190
8.3.3 Results	190
8.3.4 Conclusions	190
8.4 Introduction	191
8.5 Methods	193
8.5.1 Patients	193
8.5.2 Study Procedure	193
8.5.3 Statistical analysis	194
8.6 Results	194
8.6.1 Changes in site-specific diagnosis	195
8.6.2 Changes in overall diagnosis	198
8.6.3 Changes in management	198
8.7 Discussion	200
8.8 Subsequent literature	202
8.8.1 Diagnosis	202
8.8.2 Comparison with clinical assessment	205
8.8.3 Disease progression despite improvement	209
8.8.4 Change in diagnosis	210
8.8.5 Impact on planned foot injections	210
8.9 Summary	212

Chapter 9	213
9.1 Summary and Future Directions	213
9.2 Summary of thesis	214
9.2.1 Knee synovitis.....	214
9.2.2 Accuracy of US-guided injections	216
9.2.3 Efficacy of US-guided hip injections.....	217
9.2.4 US synovitis in clinical remission.....	218
9.2.5 US synovitis is predictive of response	219
9.2.6 Clinical impact of US.....	220
9.3 What is the current role of US?	222
9.3.1 Synovitis.....	222
9.3.2 Erosions.....	224
9.3.3 Monitoring response to therapy	226
9.3.4 Disease activity assessment	226
9.3.5 Prediction of outcome	228
9.3.6 Reliability.....	229
9.3.7 US pathology.....	230
9.4 Future directions	231
9.4.1 Standardised image acquisition, definitions of pathology	231
9.4.2 Validation of new technologies.....	232
9.4.3 Reliability of US machines	233
9.4.4 How much synovitis does it take to damage?	233
9.4.5 Are the requirements for US the same for different conditions?	234
9.4.6 Are the requirements for US the same in clinical practice and research?	235
9.4.7 Other advances: what is the opposition?.....	236
9.4.8 Who should perform US?.....	237
9.4.9 Training	239
9.5 Conclusion.....	240
References	241

Figures

Figure 2.1	The Reflectoscope.....	5
Figure 2.2	Der Ultraschall in der Medizin	6
Figure 2.3	Early Foetal US.....	7
Figure 2.4	Early B-mode scanner.....	7
Figure 2.5	Compound Sector Technique.....	8
Figure 2.6	Early Abdominal US.....	8
Figure 2.7	Normal Neck	9
Figure 2.8	Volunteer in gun turret.....	10
Figure 2.9	Diasonograph- The plan.....	10
Figure 2.10	Diasonograph- Reality	11
Figure 2.11	Linear array real-time.....	11
Figure 2.12	Linear array in practice	12
Figure 2.13	Modern image: Image of foetus	12
Figure 2.14	Modern image 1:Image of foetus	12
Figure 2.15	Transducer- Multiple parallel rows (a)	16
Figure 2.16	Transducer- Concave lens.....	16
Figure 2.17	Extended field of view	19
Figure 3.1	Ultrasonography. Knee synovitis.....	75
Figure 3.2	Ultrasonography. Ballottement of effusion.....	76
Figure 3.3	Arthroscopy. Normal synovium.....	78
Figure 3.4	Arthroscopy. Increased granularity.....	79
Figure 3.5	Arthroscopy. Villous Hypertrophy	79
Figure 4.1	Ultrasonography of subacromial bursa	106
Figure 4.2	Needle placement: under direct visualisation	106
Figure 4.3	Ultrasonography with needle placement.....	107
Figure 4.4	X-ray with contrast: Intrabursal injection.....	108
Figure 4.5	X-ray with contrast: Mainly intrabursal with some extrabursal	109
Figure 4.6	X-ray with contrast: Mixed intra- and extra-bursal injection	109

Figure 5.1	US of Hip: Hip anatomy	126
Figure 5.2	US of Hip: Scanning technique.....	127
Figure 5.3	US of Hip: US image	127
Figure 5.4	Patients with improvement in VAS scores at 2, 6 and 12 weeks....	130
Figure 6.1	US of MCP: No synovitis	149
Figure 6.2	US of MCP: Mild synovitis	150
Figure 6.3	US of MCP: Mild synovitis	150
Figure 6.4	US of MCP: Moderate synovitis.....	150
Figure 6.5	US of MCP: Moderate synovitis.....	151
Figure 6.6	US of MCP: Severe synovitis	151
Figure 6.7	US of MCP: Severe synovitis	151
Figure 6.8	US of MCP: Gray scale with corresponding Power Doppler	152
Figure 6.9	US of wrist: Gray scale with corresponding Power Doppler.....	153
Figure 8.1	US requests by pathology	195
Figure 8.2	Photograph of subject without clinical synovitis.....	196
Figure 8.3	Corresponding US demonstrating synovitis/effusion	196
Figure 8.4	Impact on Intra-articular corticosteroid use.....	199

Tables

Table 3.1	Knee synovitis, validation by patient.....	82
Table 3.2	Knee synovitis, validation by compartment.....	83
Table 6.1	Demographics of RA cohort	156
Table 6.2	Clinical laboratory, function and quality of life assessments	157
Table 6.3	US findings in ‘remission’	159
Table 6.4	Complete clinical remission vs. other measures of disease activity ...	160
Table 7.1	Study design.....	174
Table 7.2	Baseline characteristics with OR of response to IM MP	178
Table 7.3	Baseline characteristics and change after IMMMP.....	179
Table 7.4	US synovitis in polyarthralgia and clinical synovitis	183
Table 8.1	Sites assessed by US, with change in SSD	197

Chapter 1

1.1 Introduction

Our department in Leeds has undertaken pioneering work which has contributed to further understanding of the role of synovitis in the development of joint damage and subsequent function limitation. The department has become particularly noted for its work in the early diagnosis of inflammatory arthritis and its aggressive management with a view to reducing joint damage. The use of imaging techniques such as Ultrasonography (US) and Magnetic Resonance Imaging (MRI) has been at the forefront of early diagnosis. My colleague, Richard Wakefield, developed the US service with support from radiology colleagues, before I joined the group and much of the work in this thesis is a result of collaboration with these people.

Rheumatologists like other physicians have always used the patient's history, clinical assessment and laboratory investigations as central to formulating a diagnosis. In the past, x-ray was the main imaging modality used to visualise changes in bony structures. With technological advances other modalities such as computed tomography (CT), US and MRI were developed allowing rheumatologists to view not only bone but also other articular structures and soft tissue. Thirty years ago diagnostic US machines were expensive and cumbersome, using gantry systems that produced coarse, static images although in the last decade systems improved and use has become more widespread.

Manufacturers seeing the potential of US, have in recent years thrown their considerable financial weight behind improving the technology that drives its use, and massive advances in technology have dramatically changed how US is used as a diagnostic tool in clinical practice. These changes include the development of faster

microprocessors, digital imaging systems, and high frequency linear-array transducers so that today we have machines that are fully portable, including some that are hand-held, and capable of high resolution real-time gray-scale and Doppler imaging.

The increasing portability and ease of use of US, accompanied with the realisation that clinical assessment is insensitive and unreliable (Eberl, Fasching et al. 1976; Hauzeur, Mathy et al. 1999), has led to increasing calls for use in day to day practice as an extension of the rheumatologists' assessment (Manger and Kalden 1995; Grassi and Cervini 1998; Wakefield, Gibbon et al. 1999; Backhaus, Burmester et al. 2001). Advances continue at such a fast rate that often by the time independent scientific research into a particular modality has taken place; newer 'better' modalities are in vogue. Examples of more recent advances include the development of Colour and tissue harmonics, microbubble contrast agents, extended field of view imaging and 3D imaging all still in the early phases of validation as an investigative tool.

Despite this relative lack of validation the role of US in Rheumatology practice has continued to expand and practice has evolved so that for most rheumatologists US has two sometimes overlapping roles. First is the every day use for clinicians as an extension of physical examination to aid clinical diagnosis, and second as an objective outcome measure used in studies. With improved training programmes and also the cost of high quality, research capable, machines falling; the use of US as an objective measure of disease activity and response to treatment, previously used mainly in research units, is becoming more widespread by rheumatologists in their daily practice.

Chapter 2

2.1 History, Clinical Utility and Validity

2.2 History of Ultrasonography

To appreciate the changes that US has undergone in the last few decades we need to have some idea of its history.

2.2.1 Bats and Bells

The first time the concept of high-frequency US had been lauded was in the late 1700's when an Italian biologist Lazzaro Spallanzi demonstrated that bats navigated in the dark using echo reflection from high frequency sound (inaudible to humans) they emitted. The next phase in the history of US started with the measuring of distance under water with SONAR (Sound Navigation and Ranging). In the early 1800's a Swiss Physicist Jean-Daniel Colladon used an underwater bell to determine the speed of sound in waves. Work spread to try and define the fundamental physics of sound vibrations, with one of the earliest publications from Lord Rayleigh (England) in 1877 entitled "The Theory of Sound" where a sound wave was first described as a mathematical equation. High frequency sound waves were probably first generated by another Englishman Francis Galton in 1876.

2.2.2 Piezoelectricity

Around the same time (1880) another breakthrough was made by Pierre and Jacques Curie in Paris when they demonstrated that when certain quartz crystals were put under mechanical stress they generated an electric charge. They later confirmed the findings of the Nobel Physicist Gabriel Lippman, that the reciprocal effect of mechanical stress being produced when a voltage difference was applied

across a crystal was also true; they called this phenomenon piezoelectricity. It was now possible to use a single crystal to generate and receive sound in the frequency range of millions of cycles per second (megahertz) namely “ultrasound”, a quality which to this day remains central to the working of modern transducers.

2.2.3 Ships and Submarines

The invention of the diode and triode allowed for the electronic amplifications required to develop ultrasound instruments. The sinking of the Titanic in 1912 led to the development of underwater sonar systems which were first used for the purpose of underwater navigation and judging water depth. The first patent for underwater echo ranging sonar was filed at the British Patent Office by English meteorologist Lewis Richardson one month after the sinking of the Titanic. The French physicist Paul Langevin has been accredited with developing the hydrophone, subsequently widely used in naval navigation, using a transducer made of a variety of thin quartz crystals glued between two steel plates with a resonant frequency of 150 KHz. The hydrophone underwent further improvements and was subsequently used to monitor German U-boats in World War I. The German U-boat UC-3 on the 23rd April 1916 was the first known submarine sunk after detection using the hydrophone.

2.2.4 SONAR

The first working sonar system was designed and built in the United States by Canadian Reginald Fessenden in 1914. Fessenden had almost a decade earlier used his research in sound waves to send a radio transmission of music to ships on the Atlantic. The Fessenden sonar was able to detect an iceberg underwater from 2

miles away, although with the low frequency, it could not precisely resolve its direction. By the mid 1930s, many ocean liners were equipped with some form of underwater sonar using the same technique developed by Fessenden of using an electromagnetic coil to emit sound before switching to a receiver mode to listen for echoes.

2.2.5 Reflectoscope and “Medical Ultrasound”

Another equally important development was the construction of ultrasonic metal flaw detectors in the 1930’s to check for flaws on metal hulls of ships then for tanks and aircraft wings. Floyd Firestone (no link with Firestone tyres) produced his patented supersonic reflectoscope in 1941.

FIG. 4. Type A sweeping and timing system. This is the pattern which appears on the screen when the crystal is not being energized. It consists essentially of a time scale which is formed by the green spot of the oscilloscope traveling along the zigzag path A, B, C, D, etc. Each microsecond the spot is deflected slightly upward so as to notch the line and thereby form a timing scale. Every eighth notch is made higher in order to assist in counting. There are eight of these higher marks per zigzag so that it requires 64 microseconds to traverse one zigzag.


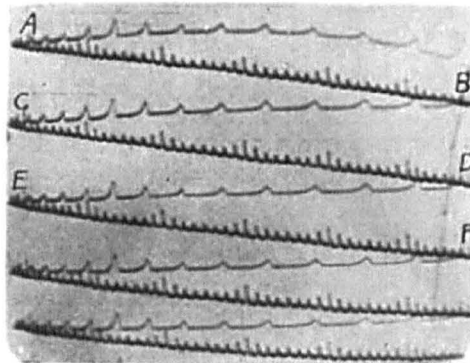


FIG. 2a. Type A supersonic reflectoscope.

Figure 2.1 The Reflectoscope

All these developments were the precursors for what led to ultrasound waves being used in the medical setting. Gohr and Wedekind from the Medical University of Koln are accredited as being the first to discuss the possibility of diagnostic ultrasound in their paper “Der Ultraschall in der Medizin” published in 1940.



Figure 2.2 Der Ultraschall in der Medizin

The Austrian Karl Dussik, a neurologist at the University of Vienna is widely accepted as the first physician to have employed ultrasound in Medical diagnosis. His paper published in 1942, based on his research on transmission ultrasound investigation of the brain, is accredited as the first paper using ultrasound in Medicine. In the 1950's Ian Donald, then Professor of Midwifery at the University of Glasgow, leading a team of clinicians and engineers established ultrasound as a clinically useful imaging modality in gynaecology and obstetrics.

Their first major publication appeared in 1958 and contained the first ultrasound images of the foetus ever published (Donald I 1958). This image from the British Musculoskeletal Ultrasound Society (BMUS) archive is one of his earliest on record.

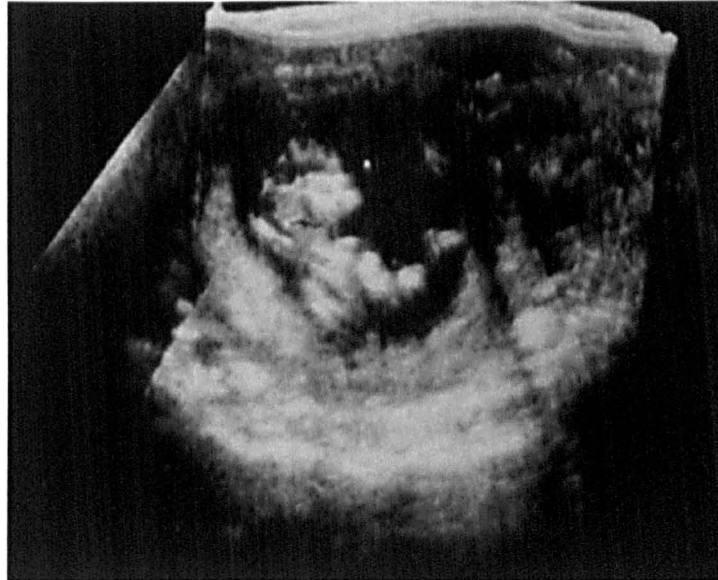


Figure 2.3 Early Foetal US

2.2.6 B-mode scanning

Donald and his colleague Tom Brown went on to build the prototype of the worlds first compound B-mode contact scanner on the frame of a hospital bed-table (Figure 2.4) with the transducer operating at 2.5 MHz in 1957 (BMUS archive).

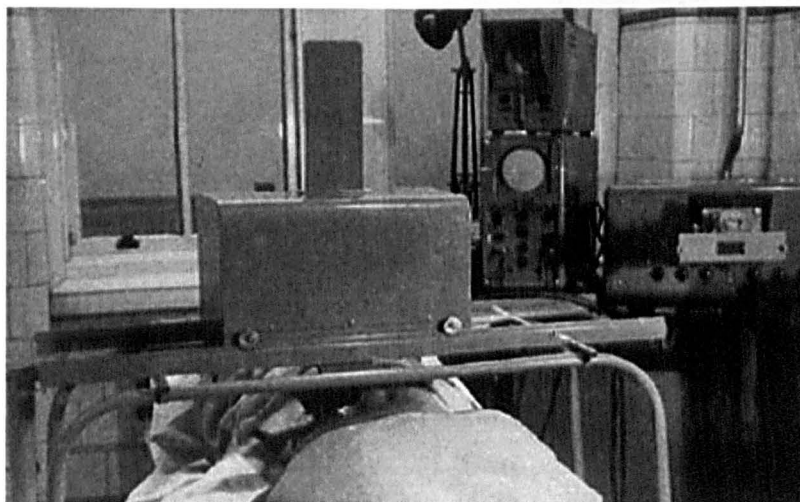


Figure 2.4 Early B-mode scanner

A compound sector technique was used to build up a two-dimensional image with gray scaling. The images were taken from different points in contact with the abdomen (Figure 2.5) and information was then used to build an echo pattern, from the skin through to the bowel (Figure 2.6). Initially machines like this were manually operated, but later machines were automated.

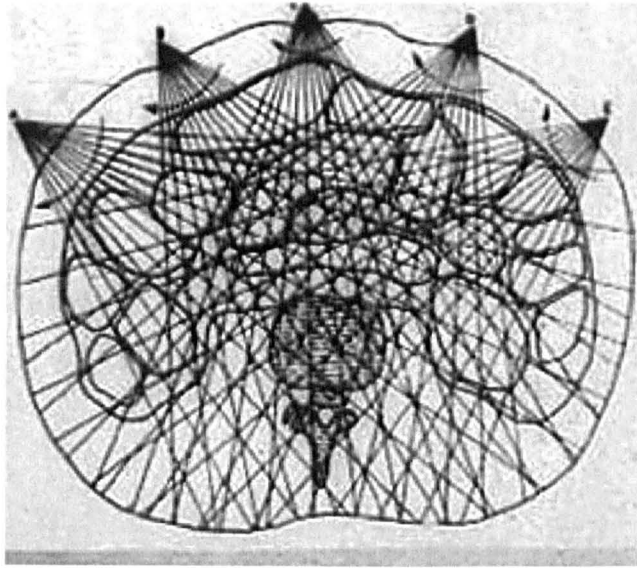


Figure 2.5 Compound Sector Technique

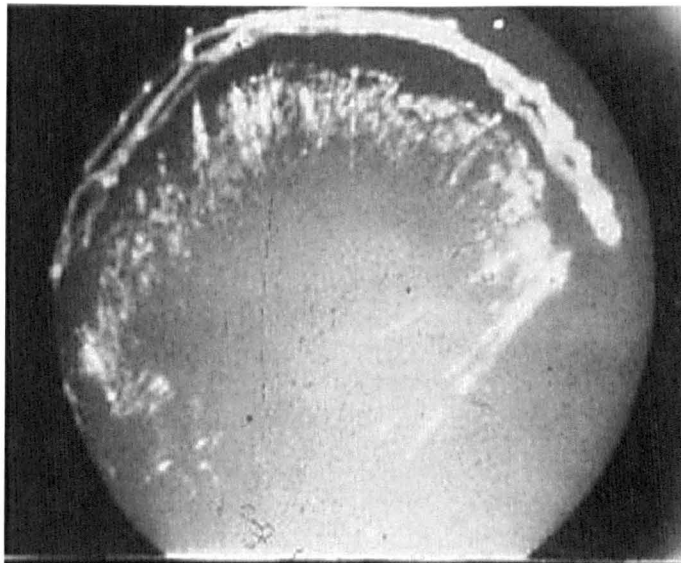


Figure 2.6 Early Abdominal US

2.2.7 Musculoskeletal Ultrasonography

In the US Holmes and Howry experimented with water tanks to achieve acoustic coupling (1956) and are accredited with one of the first images in Musculoskeletal Medicine (Howry 1955), an image of the normal neck (Figure 2.7).

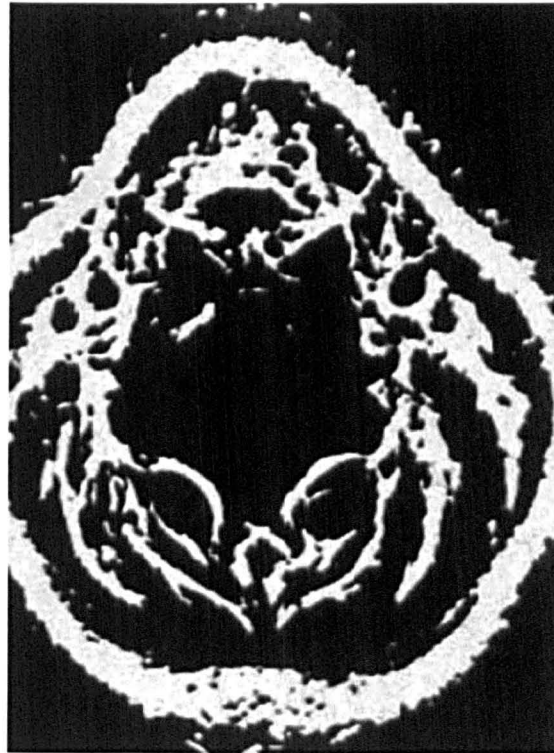


Figure 2.7 Normal Neck

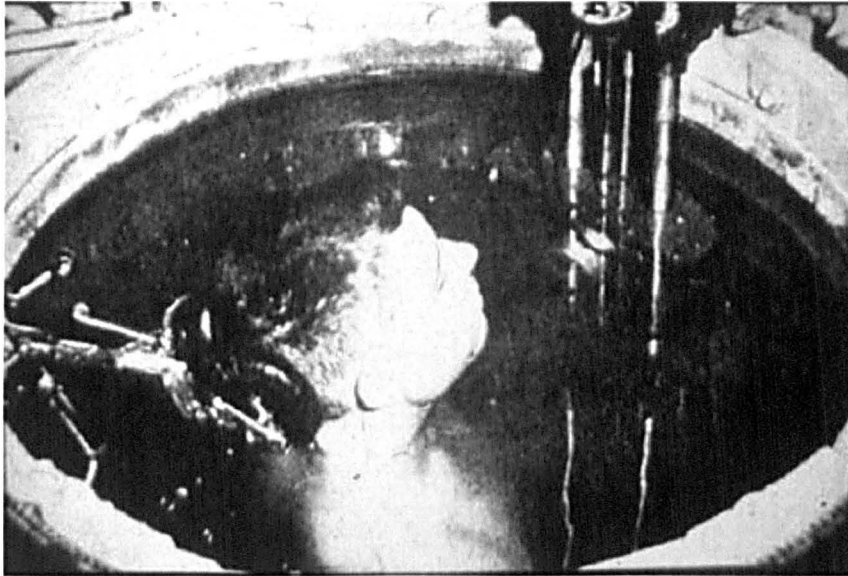


Figure 2.8 Volunteer in gun turret

This image from the BMUS (Figure 2.8) archive demonstrates how the volunteer was submerged in degassed water in a disused B29 gun turret and scanned through 360 degrees.

2.2.8 Disonograph

The Disonograph was designed and built by the same Tom Brown and Fleming in 1963. The early design of the Disonograph envisaged a matching examination couch (Figure 2.9),




Figure 2.9 Disonograph- The plan

although considerations of cost forced a compromise using a standard hospital trolley (Figure 2.10).

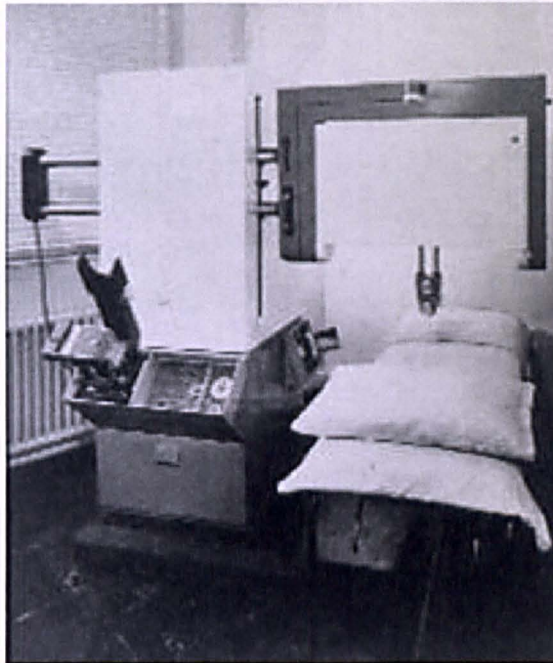


Figure 2.10 Disonograph- Reality

The Disonograph used a heavy gantry because of the need for a stable scanning platform weighing in at one ton lending itself to the nickname of the 'Dinosaurograph'! By the mid '70s linear array real-time systems had been developed which were much smaller and easier to use (Figures 2.11, 2.12).




Figure 2.11 Linear array real-time

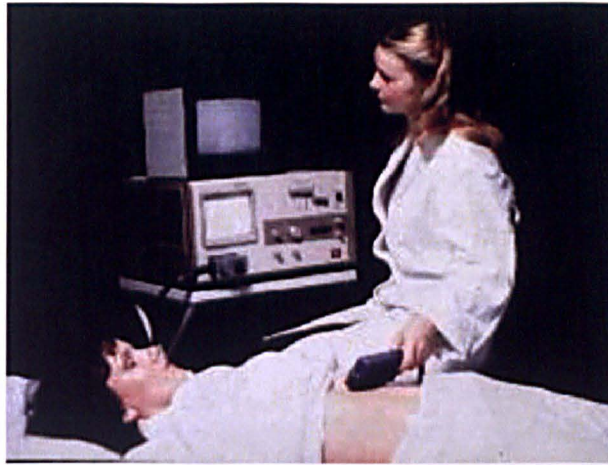

Figure 2.12 Linear array in practice

Advances in technology at all levels of the US pathway in recent years have led to marked improvements in the images that we see on our screens today (Figures 2.13, 2.14).

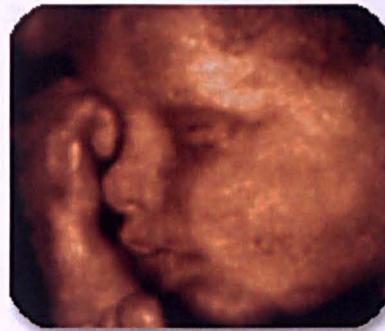

Figure 2.13 Modern image: Image of foetus

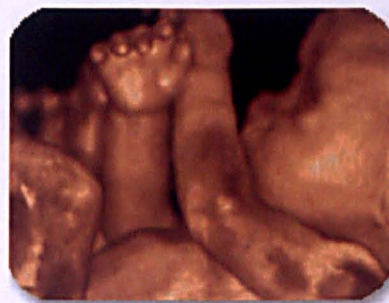

Figure 2.14 Modern image 1: Image of foetus

2.2.9 Ultrasonography or Ultrasound?

The term Ultrasonography has been used by European groups involved in musculoskeletal 'ultrasound' and our imaging group has taken on this term although in the current literature both terms are used, often interchangeably.

2.3 Technological developments in Ultrasonography

The textbook definition of US is energy generated by sound waves of 20,000 or more vibrations per second. The endpoint of this for an US machine is a transducer which gives off sound waves which are then reflected back in varying degrees from organs and tissues to the transducer, allowing a picture of what is inside the body to be depicted on a screen.

Advances in technology at all levels of the US pathway have led to marked improvements in the images that we see on our screens. Modern systems are fully digital which reduces the signal to 'noise' ratio of returning echoes, but also adds massive potential in performance related to beam formation, signal processing, image display and storage. Changes in transducer technology has not only allowed for better signalling, but also the use of different signalling techniques resulting in some of the most significant advances in applications for US and US quality (Whittingham 1997).

2.3.1 Transducers

Components

A usual transducer consists of, from the surface in, a protective layer, a lens, matching layers, an active ferro- or piezoelectric material, and a backing block. Transducers convert one form of energy to another. Piezo 'actuators' convert electrical energy to radiofrequency which is why they are referred to as motors. Piezo 'sensors' convert radiofrequency into electrical energy which is why they are referred to as 'generators'. In most cases, the same crystal can be used to perform either task. Transducers are limited by the range of frequencies over which they work mainly due to the loss of sound when converting from electrical energy to

radiofrequency, which is why we still have different transducers for different uses. One way of documenting the range of frequencies they work over is the bandwidth defined as the width of the frequency response (the transducer efficiency versus frequency relationship) at half maximum transducer output.

Signal Transmission

Improvements in methods and materials used in the transducer such as novel ways of using multiple layering of ceramics around the new piezoelectric materials all reduce the amount of energy lost in this conversion. This cuts the requirement for multiple transducers of varying frequencies but is also essential for using harmonic imaging, discussed later. The use of better piezoelectric materials alongside improvements in transducer design, digitalisation and analysis of received echoes has resulted in much higher frequency transducers that unlike previous transducers maintain penetration and resolution. The main limitation of the very high frequency transducers is the low penetration power of the ultrasonic beam. Twenty MHz transducers have an axial resolution power of 0.038 mm, but do not allow an assessment of structures deeper than 1.5 cm (Grassi and Cervini 1998). This now allows US examination of the skin, eye but also allows measurement of flow (0.5mm/s) in small 100-300 um diameter vessels.

Digitalisation

Manipulation of sound waves, both transmitted and received, as a result of digitalisation has reduced sound loss, but also allowed for new methods of sending signal. Examples include altering the waveform and duration of single pulses; or using multiple pulses or beams which allows for better resolution, but also greater

bandwidth. The introduction of contrast and 3D imaging that require a thinner more uniform image slice thickness has led to the development of transducers with multiple parallel rows of elements (Figure 2.15) (Claudon, Tranquart et al. 2002),

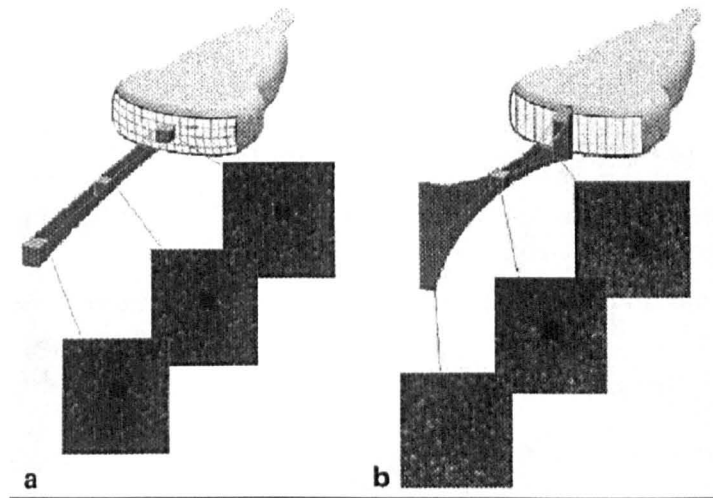


Figure 2.15 Transducer- Multiple parallel rows (a)

and also those that uses a concave lens with crystals that resonate at different frequencies, the outer aspect which resonates at lower frequencies focuses on the deeper tissues and the inner aspect which focuses on closer tissue resonates at higher frequencies which maintains clear focus at all levels (Figure 2.16) (Claudon, Tranquart et al. 2002).

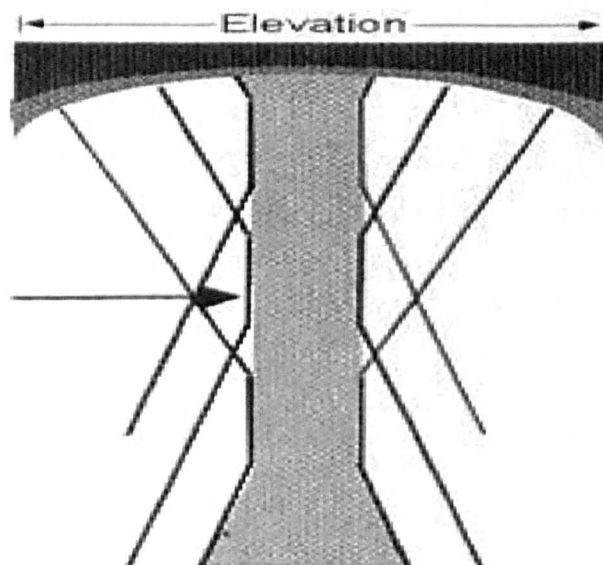


Figure 2.16 Transducer- Concave lens

Signal Reception

There have been huge advances in how transducer signal is received as well, and non-linear or harmonic imaging, first noted with contrast agents, is central to many of these advances. These are higher frequency signals which develop because US passes through compressed and non compressed tissue at different speeds and results in slight distortions that build up the further it goes into tissue. This means that tissue harmonic intensity is virtually zero at the skin, but as the US wave passes through tissue higher intensity is generated until attenuation of the US signal overcomes this when it reduces, resulting in a lower intensity. This is important because a lot of image distortion with linear imaging occurs at the skin and in this setting tissue harmonics are used to our advantage by using filters to remove the original transmitted signal. The remaining harmonic signal has less distortion and signal clutter, because this is usually caused by superficial structures like skin and fat, giving better image quality.

2.3.2 Doppler

Doppler uses reflected US waves to evaluate blood as it flows through a blood vessel. The original US wave is sent from the transducer and bounces off tissues including blood cells and the movement of blood cells causes a change in pitch of the reflected US (called the Doppler effect). This is the reason why the sound from an ambulance siren changes when it passes by. Information from the reflected sound wave is then digitally processed to provide an image that represents the flow of blood through the blood vessels. These graphs or pictures can be saved for future review or evaluation.

Colour and Power Doppler

Colour and power Doppler have been used for almost a decade in rheumatology, mostly by Wolfgang in the early days. Colour Doppler uses standard US methods to produce a picture of a blood vessel, but in addition, the Doppler sounds are converted into colours that are overlaid on the image of the blood vessel and that represent the speed and direction of blood flow through the vessel. Power Doppler (PD) is different in that whereas CD assesses flow in vessels, PD displays the amplitude of the spectral density of the Doppler signal and is determined by the amount of blood present and not flow, making it better for assessing low velocity flow in smaller vessels.

2.3.3 Harmonics, inverted pulse modes and Gray-scale flow imaging

Other advances have been the addition of harmonic and inverted pulse modes, particularly beneficial with contrast bubbles. Gray scale flow imaging is a method used to estimate flow in b-mode. This is achieved by measuring back scatter from two encoded sequences emitted very close together. Any blood flow will lead to change in signal and the resulting subtracted image is attributed to movement.

2.3.4 Extended field of view

Extended field of view imaging uses information regarding the position of the probe taken from the US images themselves as the probe is moved along a structure to construct a single landscape view (Figure 2.17) (Claudon, Tranquart et al. 2002). Using electromagnetic sensors to judge movement of the transducer has allowed so called 3D imaging, and adding to this technology using consecutive updates of these

3D images (between 4-16 cycles/sec) has created real time 4D images (4-D Kretz machine).




Figure 2.17 Extended field of view

2.3.5 Microbubbles

Mode of action

Microbubbles are less than 10 μm in diameter and work by resonating in the US beam, rapidly contracting and expanding in response to the pressure changes of the sound wave, and by helpful coincidence vibrate particularly strongly at the high frequencies used for diagnostic US. This oscillation makes them several thousand times more reflective than normal body tissues and means that they show up very clearly on US scans. In this way they enhance both gray scale images and flow mediated Doppler signals. This oscillation also means that multiple harmonic signals or overtones, just as with a musical instrument, are produced. Ultrasonography machines can be tuned to "listen" to these harmonics, producing strong preferential imaging of the microbubbles, increasing sensitivity of flow in very small vessels, so you can see capillaries with a diameter of $\pm 100\mu\text{m}$ (Blomley, Cooke et al. 2001).

Potential treatment delivery

This selective excitation can also be used to destroy microbubbles relatively easily, an effect that can be useful both in imaging and in emerging therapeutic applications. Microbubbles can potentially carry treatment and be activated at a particular site by using high frequency US beams at that site. This would usually require high acoustic power, substantially beyond that permitted for imaging, but the power needed is greatly reduced when microbubbles are present, because microbubbles lower the amount of energy necessary for cavitation; the process in which extreme oscillations induced by US pulses lead to microbubble collapse.

It is these technological advances that have pushed the boundaries of use of US in many aspects of a rheumatologists practice.

2.4 Changes in the use of Ultrasonography with time

Ultrasonography has come a long way from its first practical uses of judging water depth and locating submarines. This change in practice has occurred primarily because improvements in technology have allowed the machines to become more patient and user-friendly and also led to better quality information being gathered.

2.4.1 Improvements in image quality

In rheumatology practice, initial use was mainly confined to larger joints such as the hip (Koski, Anttila et al. 1990; Koski and Isomaki 1990), knee (Aisen, McCune et al. 1984; van Holsbeeck, van Holsbeeck et al. 1988; Rubaltelli, Fiocco et al. 1994; Ostergaard, Court-Payen et al. 1995), shoulder (Cicak, Matasovic et al. 1992; Alasaarela and Alasaarela 1994; van Moppes, Veldkamp et al. 1995), and elbow (Aisen, McCune et al. 1984; van Holsbeeck, van Holsbeeck et al. 1988; Koski 1990; Koski, Anttila et al. 1990; Cicak, Matasovic et al. 1992; Koski 1992; Alasaarela and Alasaarela 1994; Rubaltelli, Fiocco et al. 1994; Ostergaard, Court-Payen et al. 1995; Fiocco, Cozzi et al. 1996). With the improvements in transducer technology, high-frequency transducers (22-10 MHz) with a smaller footprint size became available which allowed for high resolution imaging of superficial structures such as the small joints of the hands and feet, and tendons, but also improved image quality of larger, deeper structures such as the rotator cuff and hip joint. The smaller footprint size allowed for better access and manoeuvrability between the small joints and machines have also become more portable lending to their use in the outpatient and ward setting.

2.4.2 Early treatment improves outcome

Another key reason for the increased use of US (and also MRI) has been the growing awareness that early diagnosis with early initiation and aggressive

treatment of inflammatory arthritis leads to better long-term clinical and radiological outcomes (Emery 1994; Egsmose, Lund et al. 1995; Emery and Salmon 1995; Boers, Verhoeven et al. 1997; Landewe, Boers et al. 2002; O'Dell 2002). Both US and MRI are now routinely used in many early arthritis clinics to look for the presence or absence of inflammation and damage in soft-tissue, tendons and joints. The technological improvements previously described allow for quantification of inflammation and damage, accurate diagnosis and direct therapy when appropriate and advances in three-dimensional software potentially allow for estimation of volume (Ribbens, Andre et al. 2003; Terslev, Torp-Pedersen et al. 2003). Sequential assessments allow for monitoring of response to therapy by measuring change in inflammation and also by measuring progression of damage. Being directly able to visualise structures has also contributed to a better understanding of disease pathogenesis (Kane, Greaney et al. 1999; Mc Gonagle, Gibbon et al. 1999; McGonagle, Conaghan et al. 1999; McQueen, Stewart et al. 1999; Balint, Kane et al. 2002; D'Agostino, Said-Nahal et al. 2003).

2.4.3 Advantages of Ultrasonography

Ultrasonography has the advantage over arthroscopy, traditionally used as a means of directly visualising structures within the joint and obtaining tissue samples for histological analysis, of being non-invasive. Ultrasonography, unlike x-ray and CT, is able to visualise soft-tissue structures and also lacks ionising radiation. Ultrasonography can also be used to guide aspiration and injection of joints, tendon sheaths and bursae, and can assess multiple structures in multiple planes at the same sitting. Due to the real time image acquisition and lack of physical restriction to the patient US is also able to assess real time or 'dynamic' movement of structures, and has the advantage of the patient being able to see in real time the structures being

assessed. This can allow the clinician to demonstrate and explain the nature of an underlying problem, or reassure the patient if structures are normal. Compared with MRI, US is relatively inexpensive and is easy for patients to tolerate making it particularly useful for repeated assessments.

Other imaging modalities such as x-ray, CT and MRI can be used by technicians using a system of protocols so that a specific image and image acquisition technique is used to assess a particular structure or if used to detect a particular type of pathology. The nature of image acquisition with these modalities also allows for repeat assessments, and images from different assessments are easily comparable. This also allows for investigations to be performed away from clinicians, by a less expensive technician, and images transmitted to them at another site. The restrictions due to cost and ionising radiation with x-ray, CT and MRI remain.

2.4.4 Disadvantages of Ultrasonography

The disadvantage of US is that it requires an operator that is trained to maximise the quality of images acquired and also understand the complex anatomy and functional anatomy of structures that are being visualised. Whilst using US in the outpatient or ward setting is helpful in that information, giving an earlier more accurate diagnosis, is immediately available to the clinician this needs to be weighed against the time taken away from regular outpatient duties and the costs associated with this. Due to the inability of US to penetrate bone it requires direct access to any structure it needs to visualise so has limited ability to detect pathology such as bone erosions or cartilage loss particularly in complex joints. Unlike MRI, US cannot detect pathology within bone such as bone oedema. Despite these potential limitations the use of US by rheumatologists as an additional clinical tool in the

assessment of patients with rheumatological conditions has increased (Manger and Kalden 1995; Grassi and Cervini 1998; Backhaus, Burmester et al. 2001; Wakefield, Brown et al. 2004).

2.4.5 Publications with use of Ultrasonography in Rheumatic Conditions

The increasing number of publications in recent years relating to the use of US in rheumatological practice reflects the growing use and critical evaluation of this technique. There are now publications relating to the use of US in conditions such as Rheumatoid Arthritis (RA) (Grassi, Tittarelli et al. 1993), spondyloarthropathy (SpA) (Lehtinen, Taavitsainen et al. 1994), osteoarthritis (OA) (Aisen, McCune et al. 1984) (McCune, Dedrick et al. 1990), regional pain syndromes (Manger and Kalden 1995), tendonitis (Grassi, Tittarelli et al. 1995; Nazarian, Rawool et al. 1995; Grassi, Filippucci et al. 2000), bursitis (Nazarian, Rawool et al. 1995), synovial cysts (Andonopoulos, Yarmenitis et al. 1995), Sjogrens disease (Makula, Pokorny et al. 1996), systemic sclerosis (Ihn, Shimozuma et al. 1995), temporal arteritis (Schmidt, Kraft et al. 1995), Tietze's syndrome (Martino, D'Amore et al. 1991), amyloid (Kay, Benson et al. 1992), Behcets disease (Ozdemir, Atilla et al. 1995) and rib fractures (Mariacher-Gehler and Michel 1994).

2.4.6 Ultrasonography is out of this world

In a clear demonstration of just how much US has taken off Fincke and colleagues used remote assistance to train non physician crew members to perform US of the shoulder in space (Fincke, Padalka et al. 2005).

2.5 Validity and Reliability of Ultrasonography

The increasing use of US in clinical practice has inevitably led to increased publications surrounding this matter but also for calls to investigate the true validity and reliability of US findings (Ostergaard and Wiell 2004). The knowledge that early diagnosis coupled with aggressive initiation of treatment, is essential to long term outcome in many patients with musculoskeletal conditions, has led to keen scrutiny of imaging modalities to assess their practical role in improving patient outcome. There are different types of validity depending on whether the tool being assessed is seen to have the capability of demonstrating a particular feature, whereas other types of validity include a comparison with a gold standard.

2.5.1 Definitions of Validity

Face Validity

This term is applied when a modality such as US appears to measure what it is supposed to measure. Ultrasonography is able to directly visualize structures such as synovium and tendons, has excellent image quality and spatial resolution and is capable of demonstrating certain features such as thickness of synovium, blood flow and potentially volume. This demonstrates face validity or 'credibility'.

Content Validity

Content validity suggests comprehensiveness, that is, the modality being assessed is able to cover all aspects of what is being measured. For example with the synovium US is able to detect different features of the synovium as mentioned above. Ultrasonography however cannot penetrate bone so it can be argued that when assessing bone erosions, whilst there is no doubt that US has face validity, because of incomplete access to all the bony structures (example intra-bony

pathology such as bone oedema) it may not have complete content validity. For synovitis however this is not the case.

Criterion Validity

Unlike face and content validity which is more subjective, criterion validity is the degree to which the modality being assessed reflects a 'gold standard.' There are two types of criterion validity, concurrent validity and predictive validity.

Concurrent validity

This term is applied when the modality that is being assessed is compared against a gold standard assessing the same pathology. In the case of US, an example would be, US-detected synovitis compared with synovitis detected by MRI. This is a more objective measure of validity and much of the publications discussed below fall into this category.

Predictive validity

This is described when the modality being assessed is compared against a future gold standard outcome. A simple example of this would be where US-detected synovitis is compared against progression of radiographic damage or functional impairment in the future.

Construct validity

Construct validity describes consistency with theoretic concepts for example that US-detected synovitis is related to other measures of synovitis.

Discriminant validity

This is sensitivity to change and is applied when the modality can detect clinically important changes. This requires that there must be a change over time (e.g. reduction in synovitis), and that the modality (e.g. US) must be able to reliably detect any change.

2.6 What features can Ultrasonography detect?

Accurate detection of synovitis is important for the assessment of systemic disease activity, which in turn leads to appropriate treatment. In addition the use of newer, more expensive and often more toxic, systemic therapies when clinical assessment demonstrates apparent increased disease activity has important cost implications. The detection of synovitis, tenosynovitis and enthesitis has an important role in patient management and in our unit, with referral for guided therapy, has been the commonest reason for referral to US. The presence of erosions has diagnostic and prognostic implications for many musculoskeletal conditions. This literature review concentrates on these areas attempting to separate the evidence by pathology, region of interest and validity.

2.6.1 Synovitis and Effusion

MCP in RA with controls; comparison with clinical assessment

In recent years there have been a number of studies describing changes seen in patients with RA. Grassi and colleagues (Grassi, Tittarelli et al. 1993) evaluated the ability of high frequency US (13 MHz) to detect pathological changes in the symptomatic MCP joints of 20 subjects with RA using 20 healthy subjects as controls. Ultrasonography detected soft-tissue or bone pathology in all RA patients. Sixteen patients with RA (80%) had intra articular soft tissue abnormalities; 7 patients had synovial thickening without joint effusion, 8 patients had synovial thickening and joint effusion, and 1 patient had joint effusion without synovial thickening. Loss of definition of articular cartilage in the MCP joint was observed in 17 patients (85%), and 16 (80%) had bone erosions. Regarding tendon disease; 9 patients (45%) showed widening of the flexor tendon sheaths, with marginal irregularities of the extensor tendons in 7 (35%) and flexor tendons in 8 (40%) patients. Extensor tendon rupture was observed in 2 patients (10%). The authors concluded that US assessment of the MCPs detected more pathology than conventional x-ray and suggested a role for US in the assessment of the soft-tissue in RA patients. This was one of the first papers to suggest the role of US at improving detection of soft-tissue and bone pathology in RA and also used healthy controls to demonstrate that the changes described in RA patients did not occur in the healthy population. This study did not however include any comparison with any accepted gold-standard treatment, so does not demonstrate criterion validity.

MCP, wrist in RA with controls; comparison with clinical assessment

Lund and colleagues performed a similar study but with more RA patients (29) and less healthy subjects (10) as controls. In addition to the previous study of

Grassi & colleagues they also examined the wrist, and findings were also correlated with disease activity which was assessed clinically (Lund, Heikal et al. 1995). Synovial abnormalities were confirmed to be most commonly identified in the rheumatoid hand and wrist ($p < 0.01$) compared with healthy controls. They observed significant differences in synovial abnormalities between the inactive and mildly active disease groups as well as the active and mildly active disease groups ($p < 0.01$). This study added to the literature by demonstrating that US findings of synovitis differed in patients with different disease activity states. Whilst US findings were compared with clinical disease activity, this is not true concurrent validity; because most authors would argue that a clinical assessment of disease activity, whilst commonly used in clinical practice, is not a gold standard.

PD in finger and wrist in RA; comparison with clinical assessment

In this study Qvistgaard and colleagues performed US including PD on 18 patients with RA (Qvistgaard, Rogind et al. 2001). The subjectively most inflamed joint was assessed (MCP, PIP or wrist) with US and was repeated following injection with Levovist; other measurements included ESR and HAQ. Measurements of synovial area and thickness (gray-scale), vascularisation (power/colour Doppler), and indices of the intra- and extra-synovial arterial flow (spectral Doppler) were recorded. The mean fraction of the synovium, vascularised in the patients was 0.15, and the mean indices of pulsatility and resistance were 1.92 and 0.70. The estimated vascular fraction correlated with the ESR, and the relative index of pulsatility correlated with both ESR and HAQ. The relative indices of pulsatility, an estimate of an abnormally low resistance to vascularisation, correlated with both ESR and HAQ. The authors concluded that US is a reliable tool for

estimating the size of the joint space and the synovial activity measured by the degree of vascularisation and pattern of flow.

CD in MCP, PIP RA with controls; comparison with clinical assessment

This study by Hau & colleagues (Hau, Schultz et al. 1999) assessed the MCP and PIP joints of patients with rheumatoid arthritis comparing them with healthy controls. A total of 120 normal joints and 153 RA joints (21 active, 39 moderately active and 93 inactive) were assessed. They confirmed that healthy joints had no detectable synovitis. In the RA group synovitis did not correlate clearly with disease activity; 67% of inactive joints, 82% of moderately active joints, 52% of active joints. Vascularisation performed better with significant differences in the joints of all RA sub-groups compared with those of health subjects ($p < 0.001$). There were also significant differences in the RA sub-groups; inactive versus moderately active RA ($p < 0.02$) and inactive versus R active ($p < 0.05$). This study demonstrates that US is better than clinical assessment for monitoring RA.

MCP, PIP, DIP in arthritis; comparison with MRI and scintigraphy

A study by Backhaus and colleagues (Backhaus, Kamradt et al. 1999) was the first to compare US with clinical assessment, MRI and bone scintigraphy in 60 patients with RA, OA and arthritis associated with connective tissue disease. Fourteen joints in one hand were compared with MRI and scintigraphy. Synovitis on US was defined as an anechoic or hypoechoic area in the joint space. This study demonstrated that clinical assessment, US and MRI were all significantly more sensitive than x-ray at detecting inflammatory changes in patients with low grade x-ray damage (Larsen grades 0-1), and that US detected more synovitis than MRI.

There was good correlation with the detection of synovitis using US with MRI and scintigraphy. This is one of the first studies to demonstrate concurrent validity where US-detected synovitis was compared with MRI and bone scintigraphy. It is also one of the few studies published where US was demonstrated to have detected more synovitis than MRI.

PD in MCP RA with controls; comparison with MRI and clinical assessment

This important study by Szkudlarek and colleagues used good methodology to compare PD findings with MRI in RA patients and healthy controls (Szkudlarek, Court-Payen et al. 2001). Findings with MRI were separated by the relative speed of enhancement post contrast injection. PD US was positive in 16/18 RA MCP joints that were quickly enhancing, and falsely positive in only one slowly enhancing RA MCP joint, leading to an overall sensitivity and specificity of PD US of 88.8% and 97.9%. This relatively small study provides evidence of concurrent validity.

PD with contrast in RA; comparison with MRI

This study by Magarelli and colleagues (Magarelli, Guglielmi et al. 2001) evaluated the role of Levovist during PD US assessment. Forty patients with synovitis were assessed before and after Levovist injection, MRI was performed to assess validity. Following contrast injection PD US synovitis enhanced in comparison to asymptomatic joints in the same patient. PD US and MRI findings were the same in all cases. This is a landmark study with each PD US assessment correlating with subsequent MRI assessment providing good support of concurrent validity.

Wrists, shoulders, knees in RA. Response to treatment; comparison with clinical assessment

This study assessed US in detecting response to therapy (fenbufen) in 6 RA patients, comparing it with swollen (SJC) and tender joint counts (TJC) (Spiegel, Spiegel et al. 1987). They revealed statistically significant differences between TJC and SJC, and between TJC and US findings (P less than 0.05 by kappa test statistic), but no difference between US findings and SJC (P greater than 0.05). Repeat assessment at 6 months revealed high concordance between improvement in SJC and US improvement (P less than 0.01). The authors concluded that clinical assessment of Joint swelling is accurate and like US can provide objective measurement of response to therapy. This study is important because it is one of the earliest to compare US counts with standard joint counts.

PD in MCP with response to therapy; comparison with clinical assessment

This study by Stone and colleagues used PD US to assess response following administration of corticosteroid (Stone, Bergin et al. 2001). There was significant improvement in findings with PD US as well as other clinical indices (ESR, VAS).

Effusion in thumb base OA with controls

Iagnocco and colleagues performed a control study (Iagnocco and Coari 2000) to document the range of joint distension in the thumb base (carpometacarpal joint) used high-resolution US (10 MHz) to measure distance within the joint space in 20 joints in healthy, and 57 joints in OA thumb base OA, subjects. The values obtained by measuring the distance between the apex and the base of the joint cavity triangle was significantly increased ($p < 0.001$) in OA joints compared with normals.

They concluded that the presence of effusion is highly likely if the distance, as measured in their study, is greater than 3.33 mm (mean+2 SD). This study is one of the few looking at the thumb base, using a standard assessment to detect effusion but also setting a limit of distension above which effusion is likely.

Shoulder in RA; comparison with clinical assessment and x-ray

In a study assessing the ability of US in providing additional information to clinical examination and x-ray in RA patients with shoulder pain Alasaarela and colleagues (Alasaarela and Alasaarela 1994) examined 44 RA patients (88 shoulders) They demonstrated that US detected many soft tissue lesions (in relatively early RA disease) when no radiological changes were noted. The most common US finding was subacromial-subdeltoid bursitis in 61 shoulders (69%) of 35 patients. Other findings demonstrated were; glenohumeral joint synovitis in 51 shoulders (58%) of 32 patients, biceps tendonitis in 50 shoulders (57%) of 29 patients, and degenerative changes in the supraspinatus tendon in 29 shoulders (33%) of 20 patients. They also noted that symptoms and clinical findings were non-specific and had little association with US findings. This study demonstrated that there is a poor sensitivity of clinical examination at detecting soft-tissue in the shoulder, but also that US was able to detect significant pathology in a cohort of patients with relatively early RA without x-ray changes. Whilst an interesting comparison, this is perhaps an unfair reflection on plain radiography because its primary use is to assess changes in bone texture or cortical irregularity, not to detect soft tissue changes. This study, whilst not comparing US against any gold standard, demonstrates the clinical utility of US in detecting significant changes in patients with relatively early RA, with relatively few symptoms.

Shoulder in arthritis; comparison with MRI

Alasaarela and colleagues (Alasaarela, Takalo et al. 1997) evaluated 30 patients with chronic arthritis and painful shoulders (31) with US; the findings were then compared with MRI. Ultrasonography was similar to MRI at detecting effusions in the subacromial-subdeltoid bursa, biceps tendon sheath and glenohumeral joint, but MRI was more sensitive at detecting synovitis. They concluded that US was a helpful tool in investigating the painful shoulder and suggested that because US is easily available and relatively inexpensive, it should be the first line imaging modality for soft-tissue problems of the shoulder with the proviso that for some with rotator cuff pathology both modalities may be required. This study demonstrates concurrent validity for US in the detection of effusions in the subacromial-subdeltoid bursa, biceps tendon sheath and glenohumeral joint. It is not clear whether this study, when assessing the shoulder for synovitis used an axillary view because many investigators would argue that the classic anterior and posterior approach for assessing the glenohumeral joint for synovitis, and effusion, is not as sensitive as the axillary view (Koski 1991).

Shoulder in arthritis; comparison with surgery

This study assessed 20 inpatients with arthritis one day before their shoulder operation (Alasaarela, Leppilahti et al. 1998). Changes in the subacromial-subdeltoid bursa, biceps tendon and tendon sheath, rotator cuff, and glenohumeral joint were recorded and compared with findings at operation. Compared with findings at surgery, US had a sensitivity of 93% and a specificity of 83% for the detection of effusion/hypertrophy in the subacromial-subdeltoid bursa. For

effusion/hypertrophy in the biceps tendon sheath US had a sensitivity of 100% and a specificity of 83%. Synovial effusion/hypertrophy was detected by US and at operation in all of the 12 glenohumeral joints that were evaluated at surgery. They concluded that US is a reliable method in experienced hands for the evaluation of inflammatory changes of an arthritic shoulder, with the warning that in advanced stages of rheumatoid shoulder joints, however, US is less useful, because destructive bone changes and tendon ruptures change the normal anatomy and restrict shoulder motions, limiting the visibility of US. This study is important because it confirms the concurrent validity of US comparing it with the gold standard of findings at surgery, although for the detection of glenohumeral effusion the numbers are small.

Acromioclavicular joint distension; comparison with x-ray, CT, MRI

Alasaarela & colleagues (Alasaarela, Tervonen et al. 1997) assessed 63 healthy volunteers (126 AC joints) and 32 patients (33 joints) with chronic arthritis. US was used to define the normal range of capsular distension and width of the AC joint. It was also compared with x-ray, CT and MRI for the detection of bony changes and soft tissue lesions. The mean distance of the joint capsule from the bone rim was 2.2 mm +/- standard deviation (SD) 0.5 mm in 21-32-year-old control subjects and 2.9 +/- 0.7 mm in 37-81-year-old control subjects. The mean width of the joint space was 4.1 +/- 0.9 mm and 3.5 +/- 0.9 mm in the same control groups, respectively. In detecting soft tissue changes in arthritic AC joints MRI was better than US, whereas regarding bony surface changes, CT was the best method and radiography was least sensitive but quite specific. When the distance of the joint capsule from the bone rim was < 3 mm on US, there was no synovial hypertrophy or effusion on MRI scans allowing the authors to conclude that US is useful for

excluding inflammation in the AC joint. This study is important because, using a standardised assessment; it defined a limit below which it is unlikely that there is any inflammation. This study demonstrates concurrent validity because US is compared with 'gold-standard' imaging modalities.

Hip effusion in early RA

This study of patients with rheumatoid arthritis of less than 5 years duration included 76 patients and also (Eberhardt, Fex et al. 1995) documented patient symptoms and clinical findings. This study revealed that 13/76 patients had US pathology (effusion/synovitis) bilateral in 9 patients. There was poor correlation of clinical signs with US findings; 7/13 patients with US pathology were asymptomatic, the remaining 6/13 had mild symptoms and 6/63 with normal US had symptoms. There was no difference in demographic, clinical, and laboratory findings in patients with and without hip synovitis. They concluded that hip disease occurs early in RA, US detects changes, and that there is poor correlation between clinical assessment and US findings. They added that US, rather than signs or symptoms, could identify patients with hip joint involvement and provide a rationale for early treatment. This study again demonstrates the clinical utility of US in testing patients with early disease, many of whom were asymptomatic.

Hip effusion; comparison with clinical assessment and x-ray

In an early study US was used to assess 50 patients with RA (100 hips) and compared with clinical assessment and x-ray (Koski 1989). In this study 15 patients had US-detected effusion; defined as a distance between the joint capsule and bone of more than 7 mm (14), and or a difference between the two sides of more than 1.5

mm (1). Clinical assessment was deemed as poor because in 5/15 cases the hips were asymptomatic, and routine clinical examination was abnormal in only 2 cases. X-ray was normal in 11/15 hips. The authors concluded that US hip in RA was more sensitive than x-ray for detecting abnormalities. This study demonstrates clinical utility, but does not confirm concurrent validity. X-ray was used in this study, but it is not a gold-standard for the detection of synovitis or effusion.

Hip effusion; comparison with surgery

In one of the earlier studies assessing US ability to detect synovitis or joint effusion Koski and colleagues (Koski, Anttila et al. 1990) measured distance between the neck of the femur and the capsule of the hip joint in 75 patients, 88 hips in total, prior to joint aspiration. All patients had chronic inflammatory joint disease, and had hip joint symptoms or signs. In addition, 10 other hips were assessed prior to non-replacement surgery of the joint. The study demonstrated that the US distance between neck of femur and capsule was 7 mm or greater in the majority of hips with synovial fluid following joint aspiration (29/33), and with evidence of synovitis or intra-articular effusion during open surgery (7/9). This study concluded that both joint effusion and synovitis without effusion can increase the anechoic distance between the neck of femur and the joint capsule. As a result of this work the value of an upper limit of normal of 7mm hip distension is still used by many today. This study despite the lack of controls demonstrates that US has true concurrent validity being compared with positive joint aspiration and findings of synovitis or effusion during surgery.

Knee effusion; comparison with clinical assessment

This study compared US with clinical examination for the detection of knee effusion in 50 patients (Hauzeur, Mathy et al. 1999). Using complex methodology, with different study arms assessing sensitivity of examination and correlation, they demonstrated clinical detection of effusion had 79% and 32% sensitivity and specificity respectively. Agreement was moderate ($\kappa = 0.508$) but statistically significant ($p < 0.001$) between the clinical and US examinations, agreement was slightly weaker ($\kappa = 0.446$, $p = 0.032$) between the 2 investigators for clinical examination, but strongly related ($\kappa = 0.902$) between the 2 investigators for US examination. This study demonstrates that clinical assessment is poor compared with US, and that US has good inter-observer reliability.

Knee synovitis; comparison with MRI

Ostergaard and colleagues (Ostergaard, Court-Payen et al. 1995) assessed the ability of US to detect findings in the knee of patients with arthritis using MRI as a gold standard. There were 20 subjects; 13 with inflammatory arthritis of the knee, 2 with osteoarthritis and 5 healthy controls. Assessments included detection of effusion (with volume estimation), Baker's cysts, synovial membrane and cartilage thickness. Ultrasonography correctly identified 12/12 joint effusions and 5/5 Baker's cysts detected on MRI. It also detected synovial thickening in the suprapatellar recess in 8/14 (57%) cases. Quantitative MR- and US-estimates of effusion, synovial membrane and cartilage thicknesses were taken and Spearman correlation coefficients were 0.87, 0.86 and 0.82, respectively. The authors concluded that US was reliable at demonstrating joint effusions and Baker's cysts, but insensitive for demonstration of synovial membrane and bone erosions. They added that

measurement of synovial membrane thickness, when identifiable, was precise as was measurement of cartilage thickness, but that the clinical value was limited, because the weight-bearing areas were inaccessible. This study demonstrates concurrent validity for the detection of effusions, Baker's cysts, and also for US – estimates of effusion and synovial membrane thickness.

Knee synovitis in RA response to therapy; comparison with thermography and clinical assessment

A study by van Holsbeeck and colleagues assessed 20 patients with longstanding rheumatoid arthritis (including knee involvement) but did not use controls (van Holsbeeck, van Holsbeeck et al. 1988). Knee synovitis was assessed using US thermography and clinical assessment scores, before and after intraarticular corticosteroid. In all patients synovitis, and for all modalities, regressed following injection of intra-articular corticosteroid. The quantity of synovial fluid, measured with US 10 days post injection of corticosteroid, correlated best with the patients clinical assessment. The degree of synovial thickening measured by US reduced to a maximum 3 months after corticosteroid injection. This study demonstrates the clinical utility of US at detecting changes following corticosteroid injection, but does not provide concurrent validity because most authors would not include thermography as a 'gold-standard' for detecting synovitis in the knee.

Knee synovitis in Inflammatory Arthritis response to therapy; comparison with arthroscopy

In a later study US was compared with findings at arthroscopy as the gold standard (Rubaltelli, Fiocco et al. 1994). This study validated the ability of US to detect, localise, and identify patterns of synovitis in patients with RA and psoriatic arthritis (PsA). In some patients US was repeated after synovectomy as well to detect any changes in location and pattern of synovitis. Ultrasonography was performed in a total of 12 patients with RA (13 knees) and 13 patients with PsA (14 knees) using an electronic linear transducer (7.5 MHz) or a mechanical sector transducer (10 MHz). Arthroscopy was performed within a week of US to document synovitis in 3 areas; supra-, medial- and lateral patellar recesses. Thirteen knees were also reassessed by US 2 months after synovectomy. A significant correlation was found between US and arthroscopic synovial thickness in the suprapatellar ($P < 0.02$) and medial peripatella recesses ($P < 0.02$), the sites of maximal synovial proliferation in our patients. Three distinct patterns of synovial proliferation were confirmed by arthroscopic examination: villonodular thickening in 12 knees; uniform thickening in 8 knees, and overlapping thickening in 7 knees. They concluded that US was a valid tool to localise and detect patterns of synovitis, but that there were no specific difference in pattern of synovitis between RA and PsA. This study confirmed the concurrent validity of US-detected synovitis with arthroscopy as the gold standard. There was no histological analysis which most authors would argue is the ultimate gold standard in the assessment of synovitis. This study however, demonstrates the clinical utility of US at detecting, not only changes in degree of synovitis following therapy (in this case arthroscopic synovectomy) but also the ability of US to detect different patterns of synovitis.

Knee response to therapy; comparison with clinical assessment

The same group went on to correlate in the long-term clinical with US findings following arthroscopic knee synovectomy (Fiocco, Cozzi et al. 1996). At entry to the study arthroscopic findings were used to confirm findings at US. Assessment had been taken at the outset of the study prior to arthroscopy thereafter at 2, 6 and 12 months after synovectomy or otherwise at relapse of synovitis up to 2 years post synovectomy. Information collected included synovial thickness and effusion detected by US, as well as clinical findings. After synovectomy, the clinical index and both US joint effusion and synovial thickness were significantly reduced, whereas US patterns of synovial proliferation did not show significant changes. Clinical and US findings were significantly correlated in all follow-up measurements and US joint effusion was significantly increased in the group of patients who relapsed compared to non-relapsers following synovectomy. The authors suggest that at 12 months the probability of reaching maximum improvement in US-detected joint effusion and synovial thickness as an outcome was 99% and 58% respectively; whereas the probability of achieving remission was 72%. They concluded that US findings are accurate, that US can be used to monitor response (only validated with clinical findings), and effusion at presentation predicted relapse following synovectomy. This study is limited in that the findings at follow up assessments with US were compared against clinical findings, however this study does suggest that US can be used to predict relapse following synovectomy. Relapse however, as assessed clinically, is not a true gold standard outcome which would preclude most from concluding that this confirms predictive validity.

PD in knee arthritis with controls; comparison with clinical indices

This study compared PD US with clinical indices in 22 patients with 8 healthy volunteers as controls (Giovagnorio, Martinoli et al. 2001). Presence or absence of hypervascularity, synovial thickening, effusion, and Baker's cysts were recorded. Disease activity was measured by laboratory indices of inflammation such as ESR, CRP. There were significant differences in ESR ($P= 0.039$), and other indices in patient groups defined by presence or absence of vascularity, leaving the authors to suggest that PD US is able to demonstrate synovial hyperaemia and correlates with indices of inflammation like ESR.

PD in knee arthritis; response to therapy

In this descriptive study Newman and colleagues used PD US in patients with arthritis before and after joint aspiration and intraarticular corticosteroid injection (Newman, Laing et al. 1996). They reported a decrease in synovial perfusion in all eight knees, with improvement of symptoms in seven of the eight cases. This descriptive study gives 'credibility' or face validity for the role of PD US in monitoring change to therapy.

PD in knee synovitis; comparison with histology

This important study assessed the validity of PD US at detecting changes compared with histological analysis in 20 patients following total knee replacement (Schmidt, Volker et al. 2000). Patients were scanned independently by 2 clinicians with different equipment. All 9 patients with histological changes of synovial proliferation had PD changes detected by US with 1 observer, and the other detected changes in 8/9 knees with synovitis. They confirmed that CD and PD US detected small intraarticular vessels equally, and concluded that PD and CD US were

valuable for the detection of low-grade synovitis in the knee. This study demonstrates concurrent validity with a true gold-standard.

Another important study evaluated the role of PD US in the diagnosis of synovial hypertrophy of the knee joint comparing findings with histological findings of synovial membrane vascularity (Walther, Harms et al. 2001). 23 patients undergoing arthroplasty of the knee joint had US performed prior to arthroplasty and vascularity of the synovial membrane was classified semi-quantitatively using PD US. Synovial tissue obtained during the arthroplasty was assessed for vascularity of synovial tissue, graded qualitatively. Both qualitative grading systems were controlled by analysing PD US images and histological samples using a digital image evaluation system. The correlation between the qualitative PD US results and the qualitative grading of vascularity by the pathologist was 0.89 by Spearman's rho ($P < 0.01$). Using the digital image evaluation system there was significant correlation between PD US images and analysis of synovial tissue. The authors concluded that PD US is a reliable, diagnostic method for qualitative grading of synovial vascularity. This study provides true gold-standard concurrent validity with PD US compared with histology to detect synovitis.

Knee effusion predicts relapse

I have already described the methods of Fiocco and colleagues in this study which assessed whether findings immediately post synovectomy predicted relapse (Fiocco, Cozzi et al. 1996). They demonstrated that US joint effusion was significantly increased in the group of patients who relapsed compared to non-relapser's following synovectomy. This study suggests that US can be used to predict relapse following synovectomy. It might be argued however that relapse as

assessed clinically, is not a true gold standard outcome which would preclude the conclusion that this confirms true predictive validity.

Baker's cysts; comparison with MRI

This study by Ward and colleagues assessed 36 knees in patients with suspected Baker's cysts (Ward, Jacobson et al. 2001). Baker's cyst on MRI was defined as fluid signal between the semimembranosus and medial gastrocnemius tendons. Using MRI as the gold standard US rightly diagnosed Baker's cysts in all 21 patients with evidence on MRI. Ultrasonography also incorrectly diagnosed two other knees as having Baker's cysts, which in fact were a meniscal cyst and a myxoid liposarcoma. A retrospective review of US images revealed that when hypoechoic or anechoic fluid was present between the semimembranosus and medial gastrocnemius tendons there was a hundred percent accuracy in diagnosis. The authors concluded that US is a sensitive tool for detecting Baker's cysts but to avoid incorrectly diagnosing other pathology, the presence of fluid between semimembranosus and medial gastrocnemius tendons should be a prerequisite to US diagnosis.

Ankle effusion; comparison with x-ray and MRI

In this cadaveric study Jacobson and colleagues assessed the sensitivity of US, MRI and x-ray at detecting effusions in the ankle (talotibial) joint (Jacobson, Andresen et al. 1998). Increasing volumes of fluid were injected into the ankle before imaging was performed with the ankle in dorsi-flexion, neutral, and plantar flexion. X-ray detected fluid within the anterior aspect of the ankle joint in the neutral position after 5ml of fluid was injected, and US detected fluid also in the

anterior aspect with the ankle in neutral and plantar flexion after 2ml of fluid was injected. Fluid was detected by MRI after 1 ml of fluid was injected, in the anterior aspect with the ankle in neutral and plantar flexion, and the posterior aspect with the ankle in dorsi-flexion. The authors concluded that US was more sensitive than x-ray, but less sensitive than MRI, at detecting effusions in the ankle. They also suggested that the position of the ankle impacted not only on the ability to detect effusion but also on the location where effusion is most likely to be detected. This study demonstrates concurrent validity for US and also suggests an examination technique to improve detection of joint fluid.

Response to therapy in RA; comparison with scintigraphy

In a study of patients with RA receiving radiation synovectomy US was compared with technetium scintigraphy as a measure of monitoring response (Gratz, Gobel et al. 1999). Twenty patients had radiation synovectomy in 36 joints, and bone scintigraphy assessments were performed at baseline, and after 1, 2, and 5 months. Reductions in blood pool activity were seen, and US after 3 and 6 months demonstrated a mean reduction in synovial swelling. The reduction in US-detected synovial swelling at 3 and 6 months was 1.67 and 4.38 mm respectively in the knee joint, 0.88 and 1.93mm in the larger joints (shoulder, elbow, hand, talo-tibial/subtalar), and 0.53 and 1.76 mm respectively in the finger joints. The best results clinically were observed in the finger joints. The authors concluded that there was a strong correlation between the reduction of blood pool activity, synovial swelling, and improvement of pain. This study provides a comparison with scintigraphy, but this is not generally accepted as a gold-standard assessment, so does not confer concurrent validity.

2.6.2 Tendon and Enthesal Pathology

Finger tenosynovitis in RA

Grassi and colleagues performed high-resolution US (HRUS) on finger tendons of 20 patients with RA describing their findings (Grassi, Tittarelli et al. 1995). Most, 18 patients (90%) had tendon abnormalities; 16 (80%) had widening of the flexor tendon sheath, 12 (60%) had loss of the normal fibrillar pattern, with irregularity of the flexor and extensor tendon margins seen in 50% and 30% respectively. Significant loss of tendon structure consistent with tear was seen in 10%. This study helps confirm the face validity that HRUS was able to visualise fine structures like the extensor tendons, without assessing true concurrent validity.

Finger extensor tendon partial rupture in RA; comparison with MRI and surgery

This study included 21 patients with RA and established extensor tenosynovitis undergoing surgical inspection, and compared HRUS and MRI with surgical findings (Swen, Jacobs et al. 2000). For partial tears, sensitivity and specificity were 0.27 and 0.83 for MRI, and 0.33 and 0.89 for HRUS, respectively. Positive and negative predictive values were 0.35 and 0.78 for MRI, and 0.50 and 0.80 for HRUS, respectively. Accuracy was 0.69 for MRI and 0.75 for HRUS. The authors concluded that HRUS performed better than MRI at detecting partial extensor tendon ruptures, although HRUS (and MRI) was not sensitive enough to allow for the assessment of partial extensor tendon rupture.

Finger tenosynovitis in arthritis; comparison with MRI and scintigraphy

A study by Backhaus and colleagues (Backhaus, Kamradt et al. 1999) was the first to compare US with clinical assessment, MRI and bone scintigraphy in 60 patients with RA, OA and arthritis associated with connective tissue disease.

Fourteen joints in one hand were compared with MRI and scintigraphy. This study demonstrated that clinical assessment, US and MRI were all significantly more sensitive than x-ray at detecting inflammatory changes in patients with low grade x-ray damage (Larsen grades 0-1), and that US-detected tenosynovitis correlated with findings on MRI. There was also correlation between extensor tendon tenosynovitis and scintigraphy. This is one of the first studies to demonstrate concurrent validity where US-detected tenosynovitis was compared with MRI and bone scintigraphy.

Dactylitis in PsA; comparison with x-ray

In a descriptive study Kane and colleagues described US features of dactylitis (25 digits) in 17 patients with PsA (Kane, Greaney et al. 1999). They described flexor tenosynovitis in 96% (24/25), joint synovitis in 52% (13/25), and with subcutaneous soft tissue enlargement in all dactylitic digits. They demonstrated that narrowing of joint space and periostitis on x-ray correlated with joint synovitis on US in that digit. This study confirms the validity of US at detecting joint space narrowing and periostitis. The findings of tenosynovitis, joint synovitis and soft tissue changes in dactylitic fingers are clinically helpful, but do not provide evidence of concurrent validity because the described findings cannot realistically be compared with x-ray.

Elbow effusion; comparison with x-ray and MRI

This cadaveric study (De Maeseneer, Jacobson et al. 1998) assessed the sensitivity of imaging modalities at detecting effusions in the elbow. The authors injected increasing volumes of fluid into cadaveric elbows and assessed the ability of US, MRI and x-ray to detect effusions. The elbow was assessed in full flexion

and extension to see if position improved sensitivity. They documented that in flexion fluid initially collected in the posterior elbow and fluid then spread to the anterior compartment as larger volumes were injected. X-ray detected fluid in the joint with a positive fat pad sign on lateral x-ray in elbow flexion with 5 to 10 ml of fluid injected, whereas US over the olecranon fossa with the elbow flexed detected fluid with 1 to 3 ml of fluid injected. Magnetic-resonance imaging identified joint fluid with only 1 ml of fluid injected, regardless of elbow position. The authors concluded that US was more sensitive than x-ray, but less sensitive than MRI, at detecting effusions in the elbow joint and suggested US to detect effusions in the elbow was best performed with the elbow flexed. This study demonstrates concurrent validity for US at detecting relatively small amounts of joint fluid, but also suggests a specific US technique to improve the sensitivity at detecting joint effusions.

Shoulder in arthritis; comparison with MRI

Alasaarela and colleagues (Alasaarela, Takalo et al. 1997) evaluated 30 patients with chronic arthritis and painful shoulders (31) with US; the findings were then compared with MRI. Whilst MRI was better than US at detecting full-thickness tears of the supraspinatus tendon, US had greater sensitivity detecting partial-thickness tears and supraspinatus degeneration. Biceps tendon ruptures were visualised equally well by MRI and US. The authors concluded that US was a helpful tool in investigating the painful shoulder and suggested that because US is easily available and relatively inexpensive, it should be the first line imaging modality for soft-tissue problems of the shoulder with the proviso that for some with rotator cuff pathology both modalities may be required. This study demonstrates

concurrent validity for US in the detection of supraspinatus tendon and bicep tendon pathology.

Rotator cuff tear; comparison with arthrography and surgery

Swen and colleagues determined the validity of US and arthrography to detect rotator cuff tears using findings at surgery as the gold-standard (Swen, Jacobs et al. 1998). Twenty-one otherwise healthy patients with non inflammatory unilateral chronic shoulder pain due to a possible full-thickness rotator cuff tear had US and arthrography performed prior to surgery. Sensitivity for assessment of a full thickness cuff tear was 0.86 for US and 0.77 for arthrography. Specificity was 0.88 for US and 0.92 for arthrography. They concluded that US was a useful and valid tool to detect cuff tears. This study demonstrates concurrent validity for US and arthrography.

Rotator cuff tear; comparison with MRI and arthroscopy

Swen and colleagues performed this study in 21 otherwise healthy patients with non inflammatory unilateral chronic shoulder pain due to a possible full-thickness rotator cuff tear (Swen, Jacobs et al. 1999). Ultrasonography was performed by a radiologist and a rheumatologist, blinded to each others findings, and MRI was evaluated by 2 radiologists again blinded to each others findings. Arthroscopy was performed soon after and confirmed for full-thickness tears the sensitivity for US and MRI were both 0.81, whereas specificity was 0.94 for US and 0.88 for MRI. The positive predictive value was 0.96 for US and 0.91 for MRI, and the negative predictive value 0.77 for US and 0.74 for MRI. Accuracy was 0.86 for US and 0.83 for MRI. The authors concluded that US was a valid tool to detect full

thickness cuff tears. This study demonstrates concurrent validity and also adds the assertion that US can be performed by a rheumatologist as well as a radiologist.

Painful shoulder; comparison with surgery

This study by Read and colleagues evaluated the accuracy of US for the preoperative evaluation of shoulder impingement syndrome, rotator cuff tear, and abnormalities of the long head of the biceps tendon in 42 consecutive surgical cases (Read and Perko 1998). Ultrasonography detected all of the 10 full-thickness cuff tears identified at surgery (sensitivity 1.0, specificity 0.97) but detected only 6 of 13 partial-thickness cuff tears (sensitivity 0.46, specificity 0.97). A full-thickness tear was falsely diagnosed in one case of severe cuff abrasion. Dynamic scan criteria correctly diagnosed impingement in 27 of 34 cases (sensitivity 0.79, positive predictive value 0.96), and abnormalities of the long head of the biceps tendon were accurately diagnosed with the exception of low-grade tendonitis. They concluded that US is a sensitive and accurate method of identifying patients with full-thickness tears of the rotator cuff, and or long head of biceps tendon pathology, and that dynamic US could help confirm, but not exclude, impingement.

Another similar study assessed 20 inpatients with arthritis one day before their shoulder operation (Alasaarela, Leppilahti et al. 1998). Changes in the subacromial-subdeltoid bursa, biceps tendon and tendon sheath, rotator cuff, and glenohumeral joint were recorded and compared with findings at operation. Compared with findings at surgery, US had a sensitivity of 70% and a specificity of 100% for the detection of biceps tendon rupture. US missed three intraarticular biceps tendon ruptures. For effusion/hypertrophy in the biceps tendon sheath US had a sensitivity of 100% and a specificity of 83%. For rotator cuff tear US had a

sensitivity of 83% and a specificity of 57%. US missed two small longitudinal rotator cuff tears. Three thin membranous, but intact, rotator cuff tendons were classified as full thickness tears by US. The authors concluded that US is a reliable method in experienced hands for the evaluation of inflammatory changes of an arthritic shoulder, with the warning that in advanced stages of rheumatoid shoulder joints, however, US is less useful, because destructive bone changes and tendon ruptures change the normal anatomy and restrict shoulder motions, limiting the visibility of US. This important study confirmed findings with US as being valid when compared to findings at surgery which reaches the ultimate gold standard for tendon damage and rupture.

Achilles tendon pathology; comparison with surgery

This is one of the earliest studies comparing Achilles tendon pathology with surgical findings. Lehtinen and colleagues used a 5 MHz linear array probe to examine 30 patients (34 Achilles tendons) with overuse injuries prior to surgery (Lehtinen, Peltokallio et al. 1994). Ultrasonography had an overall sensitivity of 0.96 in the detection of Achilles tendon pathology; US suggested partial Achilles rupture in 10 cases, all confirmed at surgery, but missed one seen at surgery. In this cohort US was under diagnostic for paratenonitis and over diagnostic for tendonitis, with most diagnosed by US as having tendonitis, actually having paratenonitis at surgery. The authors conclude that US is a valid tool for the diagnosis of partial ruptures. Whilst this study confirms concurrent validity for US detection of partial ruptures, the 5 MHz probe would not have had the resolution to clearly differentiate between the paratenon and tendon.

Posterior tibialis tendon pathology; comparison with surgery

In this retrospective study, Miller and colleagues studied 17 patients who had US performed prior to posterior tibialis tendon surgery (Miller, Van Holsbeeck et al. 1996). US findings of tenosynovitis in 3, partial tears in 4, and complete ruptures in 10 tendons were confirmed at surgery. A subset of patients also had MRI performed and the authors noted that 2 cases of ruptures were undiagnosed with MRI. The authors concluded that US was a reliable tool to assess the posterior tibialis tendon, and maybe a valuable tool in planning surgery, but conceded that the study was limited because it was retrospective. The findings are however still important for patients with inflammatory arthritis, particularly rheumatoid arthritis where posterior tibialis tendon disease is common, but also in patients presenting with foot and ankle pain.

Plantar tenosynovitis in inflammatory arthritis with controls; comparison with clinical assessment

This study included 25 patients with inflammatory arthritis and forefoot pain with 35 healthy controls, and included clinical findings (Koski 1995). Ultrasonography revealed twenty plantar flexor tenosynovitis in 12/25 patients. Only 6/20 affected digits had a corresponding inflamed MTP, and only 8/20 had clinical abnormalities detected on examination. The authors concluded that tenosynovitis as well as MTP joint disease can cause forefoot pain. This study demonstrates that US is more sensitive than clinical examination, but does not imply concurrent validity.

Enthesopathy; comparison with clinical assessment

This early study assessed the lower limbs of 31 patients with Spondyloarthropathy (SpA) and compared US with clinical findings (Lehtinen, Taavitsainen et al. 1994). Ultrasonography detected enthesitis in 44 enthesal sites in 20 patients, whereas with clinical examination enthesitis was diagnosed in 56 sites in 20 patients. The commonest sites were at the insertions of the Achilles tendon and the plantar fascia. Clinical examination frequently misinterpreted bursitis around the calcaneum and synovitis, and or pain in the hip and knee joints as enthesitis. The authors concluded that US was a valuable tool for detecting enthesitis and clinical examination had poor specificity compared with US.

Plantar fascia

Kane and colleagues performed a study of 4 patients (5 heels) who had failed to respond to non-guided or 'blind' injections (Kane, Greaney et al. 1998). Patients had US of their symptomatic and asymptomatic (in 3 patients) heels. Ultrasonography confirmed an increased thickness of plantar fascia in symptomatic heels compared with asymptomatic heels, loss of distinction of the distal plantar fascia borders, and reduced echogenicity of the plantar fascia. They concluded that US can effectively diagnose plantar fasciitis. This study is descriptive and, while including a relatively small amount of patients, used the asymptomatic side as a control.

2.6.3 Erosions

The detection of erosions is important because they form part of the diagnostic criteria for some conditions like RA, but also because they have prognostic implications for outcome. Much of this thesis concentrates on the detection of synovitis and tendon disease more so than erosions, so the literature review here concentrates on a few key pieces of research.

MCP, wrist erosions in RA with controls

Lund and colleagues performed a study with RA patients (29) and healthy subjects (10) as controls assessing the MCP and wrist joints and comparing their findings in the 2 groups and also comparing findings with disease activity states (Lund, Heikal et al. 1995). Erosions were confirmed to be most commonly identified in the rheumatoid hand and wrist ($p < 0.01$) compared with healthy controls. They observed significant differences in erosions between the inactive and mildly active disease groups as well as the active and mildly active disease groups ($p < 0.01$). Ultrasonographic findings however, of normal and abnormal cartilage as defined did not predict normal and disease states. This study added to the literature by demonstrating that erosions were seen more frequently in increased disease activity states.

MCP, PIP, DIP erosions in arthritis; comparison with MRI and scintigraphy

I have already described the methods of this study by Backhaus and colleagues (Backhaus, Kamradt et al. 1999). In this study US recorded changes of 'irregular joint contour' and correlated these with x-ray and MRI, and demonstrated that US detected these changes in a significant number of patients, but did not

demonstrate any significant correlation between x-ray or MRI, with US. This is one of the first studies that assessed the concurrent validity of US-detected 'erosions', but is somewhat limited by the definition of 'erosions'.

MCP in RA; comparison with x-ray and MRI

This study compared US with x-ray for the detection of erosions in the MCP joints of 100 patients with RA and 20 controls (Wakefield, Gibbon et al. 2000). A sub-group of 25 patients also had MRI performed. Intra-observer reliability of US was assessed using video recordings of 55 MCP joint scans of RA patients, and inter-observer reliability was assessed by comparing 160 MCP joint scans performed sequentially by 2 independent observers. In all RA patients (100) US detected significantly more erosions, 127 (56 patients) compared with x-ray detecting 32 erosions (26 coincided with US erosions) in 17 patients ($P < 0.0001$). Ultrasonography detected 6.5-fold more erosions than x-ray in early disease, in 7.5-fold the number of patients, compared with 3.4-fold more erosions than x-ray in late disease, in 2.7-fold the number of patients. In the sub-group with MRI, all US erosions not visible on x-ray ($n = 12$) corresponded by site to MRI abnormalities. The Cohen-kappa values for intra- and inter-observer reliability of US were 0.75 and 0.76, respectively. The authors concluded that US is a reliable technique that detects more erosions than x-ray, especially in early RA, and that US-detected erosions not seen on x-ray corresponded to MRI bone abnormalities. This study provides concurrent validity comparing US with MRI.

Knee; comparison with MRI

Ostegaard and colleagues (Ostergaard, Court-Payen et al. 1995) assessed the ability of US to detect bone erosions in the knee of patients with arthritis using MRI as a gold standard. There were 20 subjects; 13 with inflammatory arthritis of the knee, 2 with osteoarthritis and 5 healthy controls. Ultrasonography identified only 3/8 (38%) bone erosions. The authors concluded that US was insensitive for demonstration of bone erosions. This study confirms the limited role of US for detecting erosions in the knee in that weight bearing areas of the knee are largely inaccessible.

Shoulder in arthritis; comparison with MRI

I have already described the methods used in this study by Alasaarela and colleagues (Alasaarela, Takalo et al. 1997). Ultrasonography was compared with MRI in 30 patients with painful shoulders (31). Erosions of the humeral head were visualised equally well by MRI and US, but the locations occasionally differed. They concluded that US was a helpful tool in investigating the painful shoulder and suggested that because US is easily available and relatively inexpensive, it should be the first line imaging modality for problems of the shoulder. This study demonstrates concurrent validity for US in the detection of erosions.

Shoulder in RA; comparison with x-ray, CT and MRI

Another study compared US with CT, MRI and x-ray at detecting humeral head erosions, 26 patients (1 shoulder each) with RA (Alasaarela, Suramo et al. 1998). Magnetic-resonance imaging detected humeral erosions in 25 (96%) shoulders, compared with 24 (92%), 20 (77%) and 19 (73%) for US, CT and x-ray respectively. Magnetic-resonance imaging and US were both significantly superior

to CT in detecting small erosions, and US was more sensitive than MRI at detecting surface erosions on the greater tuberosity. Ultrasonography, CT and MRI detected large erosions quite similarly, but x-ray frequently missed small erosions. They concluded that US and MRI were more sensitive than traditional x-ray at detecting early erosions in the rheumatoid shoulder. This study is important because it compares US with the standard technique of x-ray but with the evolving gold standard of CT and MRI providing concurrent validity.

2.7 US-guided therapy

With increasing use of US and its ability to clearly visualise structures it was no surprise when US started being used to direct therapy to specific areas. This is partly related to the fact that with US clinicians are able to visualise the structures that they want to direct therapy to, but also able to observe for example corticosteroid directly injected into the joint. Techniques for guiding joint injections have been published (Koski 2000).

2.7.1 MCP, flexor tendon sheath injections

Grassi and colleagues have added much to the literature with their descriptive and pictorial essays on the use of US-guided therapy in arthritis. While not providing any concurrent validity they have led the way in describing techniques in Guided injections. In this pictorial essay they describe an US-guided approach to local injection of the 3rd MCP joint and flexor tendon sheath in a patient with PsA (Grassi, Lamanna et al. 1999). After determining joint and tendon synovitis they proceed to demonstrate the technique for guided injection, confirming placement of the needle before injecting corticosteroid. They conclude this is a safe and simple method to accurately guide therapy to small joints and tendons.

2.7.2 Aspiration and injection

Another review by Grassi and colleagues suggests that US has a clear role to play in the aspiration of small fluid collections, and also in the targeting of specific lesions (Grassi, Farina et al. 2001). They conclude that due the ease of learning guided needle placement this should be included in the standard training of all rheumatologists.

2.7.3 US-guided wrist injection; injection site and response to therapy

Koski has also assessed whether wrist injection is best as a single radio carpal or as a combined radio and inter-carpal injection in 50 patients. Ultrasonography was used to guide injection, and then monitor response to therapy. The combined injection had better outcomes, although clinical assessment (68%) recorded more wrists as normal at follow-up compared with US (10%) (Koski and Hermunen 2001).

2.7.4 US-guided carpal tunnel release; comparison with conventional surgery

Ultrasonography has been used to demarcate and guide incision of the flexor retinaculum in patients undergoing carpal tunnel release. In this randomised study of 103 patients comparing US-guided carpal tunnel release with conventional carpal tunnel release, similar outcomes were demonstrated with respect to numbness and paresthesiae, static two-point discrimination, and electrophysiological findings (Nakamichi and Tachibana 1997). The US-guided release group however, had better outcomes regarding pain, tenderness of the scar, and key-pinch strength at 3, 6, and 13 weeks, as well as grip strength at 3 and 6 weeks after surgery. The authors concluded that US-guided carpal tunnel release was as effective as conventional release but with potential benefits regarding certain key outcomes. This study provides concurrent validity for the role of US to guide carpal tunnel release.

2.7.5 Caudal injections

Klocke & colleagues (Klocke, Jenkinson et al. 2003) demonstrated using high resolution real time US, that it is possible to identify the sacral hiatus landmarks and subsequently guide needle placement. The authors suggest that this

technique, whilst potentially useful in all patients would be particularly useful in patients with clinically unreliable anatomic landmarks. In this study there is no formal confirmation of placement.

2.7.6 Iliopsoas abscess

McAuliffe and colleagues described a case where US was used to guide drainage of an iliopsoas abscess (McAuliffe and Clarke 1994). This was followed a few years later by Gupta and colleagues (Gupta, Suri et al. 1997) where US was used to drain an iliopsoas abscess in 51 patients as an alternative to surgery, with only 7 out of 51 patients ended up requiring surgery in the long term. This study confirmed a clear clinical utility of US allowing a less invasive guided technique to avoid the majority of patients requiring more invasive surgery.

2.7.7 Plantar fascia

Kane and colleagues performed a study of 4 patients (5 heels) who had failed to respond to non-guided or 'blind' injections (Kane, Greaney et al. 1998). All symptomatic heels had US-guided injections. Following injection one patient developed a recurrence of symptoms after 6 months, but 3 patients (4 heels) had complete relief (mean follow-up 24 months). They concluded that US can effectively diagnose and treat plantar fasciitis, suggesting one of the reasons for previous lack of response may have been misplacement of 'blind' injection. This study demonstrates a clinical utility of US. All patients had previously failed non guided or 'blind' injections, with most patients having complete relief at extended follow-up.

2.8 Reliability of Ultrasonography

One of the key advantages of US over conventional x-ray and even MRI is that it is safe, portable, and capable of multiple examinations at one sitting. With modalities like MRI, CT and x-ray standardisation of assessment and storing of images is easy and it is also possible to compare saved images with ones taken at a later date. Unlike the modalities mentioned above US is operator dependent and has lacked evidence confirming reliability.

2.8.1 MCP, PIP, DIP synovitis and erosions in arthritis

A study by Backhaus and colleagues (Backhaus, Kamradt et al. 1999) was the first to compare US with clinical assessment, MRI and bone scintigraphy in 60 patients with RA, OA and arthritis associated with connective tissue disease. Fourteen joints in one hand were compared with x-ray, MRI and scintigraphy. Twenty randomly selected patients of the original 60 had a second blinded reading of all 4 modalities. The intra-observer variation coefficient for US was 11% for synovitis and 5% for 'erosions', compared with 12 % and 17% respectively for MRI. The intra-observer coefficient of variation for bone scintigraphy was 5%, and for x-ray erosions 8%. This is one of the first studies to demonstrate the reliability of US, albeit intra-observer only, whilst also comparing this with other imaging modalities.

2.8.2 Gray-scale, PD synovitis in finger and wrist RA

In this study US including PD was performed on 18 patients with RA (Qvistgaard, Rogind et al. 2001). The subjectively most inflamed joint was assessed (MCP, PIP or wrist) by 2 independent observers and included measurement of

synovial area and thickness (gray-scale), vascularisation (power/colour Doppler), and indices of the intra- and extrasynovial arterial flow (spectral Doppler). The two investigators measured the pixel area of the synovial vessels twice. The intra-observer correlation coefficient of 74 evaluable double measurements was 0.97 ($p < 0.0001$) for investigator 1, and 0.82 ($p < 0.0001$) for investigator 2. Inter-observer reliability was tested in the first evaluation of the pictures and the correlation coefficient between investigators 1 and 2 was 0.81 ($n = 75$, $p < 0.0001$). The authors concluded that US is a reliable tool for estimating the size of the joint space and the synovial activity measured by the degree of vascularisation and pattern of flow.

2.8.3 MCP erosions in RA

This study compared US with x-ray and MRI for the detection of erosions in the MCP joints of 100 patients with RA and 20 controls (Wakefield, Gibbon et al. 2000). Intra-observer reliability of US was assessed using video recordings of 55 MCP joint scans of RA patients, and inter-observer reliability was assessed by comparing 160 MCP joint scans performed sequentially by 2 independent observers. The Cohen-kappa values for intra- and inter-observer reliability of US were 0.75 and 0.76, respectively. The authors concluded that US is a reliable technique for the detection of erosions in RA.

2.8.4 Rotator cuff tears

This study which determined the validity of US and arthrography to detect rotator cuff tears using findings at surgery as the gold-standard (Swen, Jacobs et al. 1998), also used 2 operators a rheumatologist and a radiologist to US. The inter-observer reliability for US was 0.63, compared with 0.52 for MRI, the authors

concluding that US is a valid and reliable tool that could be performed by either a rheumatologist or radiologist experienced in US.

2.8.5 Knee effusion; comparison with clinical assessment

This study compared US with clinical examination for the detection of knee effusion 50 patients (Hauzeur, Mathy et al. 1999). Using complex methodology, with different study arms assessing sensitivity of examination and correlation, they demonstrated that agreement was moderate ($\kappa = 0.508$) but statistically significant ($p < 0.001$) between the clinical and US examinations, agreement was slightly weaker ($\kappa = 0.446$, $p = 0.032$) between the 2 investigators for clinical examination, but strongly related ($\kappa = 0.902$) between the 2 investigators for US examination. This study demonstrates that US has good inter-observer reliability.

2.8.6 PD in knee synovitis

Schmidt and colleagues in a study of 20 patients assessed the validity of PD US at detecting changes compared with histological analysis following total knee replacement (Schmidt, Volker et al. 2000). Patients were scanned independently by 2 clinicians with different equipment. All 9 patients with histological changes of synovial proliferation had PD changes detected by US with 1 observer, and the other detected changes in 8/9 knees with synovitis. They concluded that both PD and CD US had good inter-observer reliability and were valuable for the detection of low-grade synovitis in the knee.

2.9 Summary and aims of this thesis

This thesis centres on looking at the role of US in daily clinical practice and using scientific research sets out to justify its use.

2.9.1 Format

Each chapter will be set out in the same format describing the clinical relevance of the study then an abstract of the study. The body of the study will have an introduction, methods section, results section; and then a discussion followed by subsequent studies relevant to the work discussed in the chapter, before a final summary.

2.9.2 Chapter 3

The construct validity of US at detecting synovitis in the knee will be assessed. Clinical examination and US are compared with findings at arthroscopy, used as the gold-standard, for the detection of synovitis in the knee. A binary (yes/no) and semi-quantitative measure of US synovitis is recorded, and the intra- and inter-observer reliability of US at detecting synovitis for both these measures is assessed.

2.9.3 Chapter 4

In chapter 4 the accuracy of US-guided injections to the shoulder sub-acromial bursa is determined, using contrast mixed with corticosteroid, confirming placement with x-ray.

2.9.4 Chapter 5

In chapter 5 the efficacy of US-guided injections in patients with arthritis of the hip is documented in an open pilot study. Baseline features with US of osteophytes and effusion are recorded, prior to US-guided injection of corticosteroid. This pilot study also evaluates whether baseline US features predict outcome.

2.9.5 Chapter 6

In chapter 6 based on the evidence that clinical detection of low-level synovitis is poor, and of ongoing joint damage despite a relative lack of disease activity on clinical assessment, we use US to assess RA patients thought to be clinical remission. Synovitis detected by US is compared with clinical indices such as metrology and CRP, and both ACR and DAS28 criteria of remission.

2.9.6 Chapter 7

In chapter 7 we demonstrate the clinical utility of US in a cohort of patients with symptoms to suggest an underlying inflammatory arthritis but without much clinical evidence to confirm this. Baseline assessment with US to document synovitis is followed by treatment with intramuscular methylprednisolone (IM MP) following a specific treatment algorithm. Using the response to IM MP as suggesting an underlying inflammatory process, response to IM MP is recorded and baseline features including US are assessed to determine predictors of response.

2.9.7 Chapter 8

In this chapter, the clinical utility of US in patients who were referred for US by their attending consultant is determined. All patients had a clinical assessment with the clinician documenting the likely pathologic diagnosis of the area in question, as well as the overall clinical diagnosis before US was performed. This study documents the referral pattern in a rheumatology academic unit, and also compares changes in the local site-specific diagnosis, overall diagnosis and management following blinded US assessment.

2.9.8 Chapter 9

This chapter will summarise the findings of this thesis and, taking into account the published literature, will discuss investigations required in the future to justify the continuing use of US in rheumatology practice.

Chapter 3

3.1 Knee synovitis: Construct Validity

3.2 Clinical relevance

Synovitis has been shown to be important for the symptoms and progression of knee arthritis. Clinical assessment is not reliable, and the gold standard assessment, findings with histology requires invasive techniques like arthroscopy. This large study using macroscopic findings at arthroscopy as gold standard determines the validity and reliability of US-detected synovitis.

3.3 Abstract

3.3.1 Aims

Accurate detection of synovitis is important in both the diagnosis and outcome assessment of arthritis. By comparing US with arthroscopy and clinical assessment, this study assessed the validity and reproducibility of US as a means of detecting synovitis in the knee.

3.3.2 Methods

Sixty consecutive patients with knee pain due to different arthritides had a clinical assessment and US of their knee performed immediately prior to arthroscopy. All 3 assessments were performed by different clinicians blinded to the other modality results. Ultrasonography and clinical assessment were compared with arthroscopically detected synovitis as the gold standard. A subset of patients was used for calculating the inter- and intra-reader reproducibility of US, using a standard dichotomous (absence/presence of synovitis) as well as testing a graded (absence/grade of synovitis) scoring system.

3.3.2 Results

Using arthroscopy as the gold standard US had a higher sensitivity (98 vs 85%), specificity (75 vs 25%), accuracy (97 vs 77%), positive predictive value (98 vs 88%) and negative predictive value (88 vs 20%) compared with clinical assessment. The Cohen-kappa values for inter- and intra-reader reproducibility of US for distinguishing between presence/absence of synovitis were 0.71 and 0.85 respectively ($p < 0.005$ for both). The weighted kappa values for distinguishing grade of synovitis were 0.65 for inter- and 0.74 for intra-reader reproducibility. The kappa value for intra-reader reproducibility of arthroscopy was 0.88.

3.3.4 Conclusions

Ultrasonography is a valid and reproducible technique for detecting synovitis in the knee, and is more accurate than clinical assessment. It may be valuable as a tool in studies investigating pain, diagnosis and treatment response in knee arthritis.

3.4 Introduction

Synovitis is the usual presenting sign of inflammatory arthritis and has a central role in the progression of joint damage in RA (Ostergaard, Hansen et al. 1999). Synovitis is also frequently present in OA especially with advanced structural damage (Pelletier, Martel-Pelletier et al. 2001) has recently been associated with the degree of knee pain (Hill, Gale et al. 2001) and predicting progression of cartilage loss in the knee (Ayril, Pickering et al. 2001). Clinical assessment of the knee for synovitis has poor sensitivity and reproducibility (Jones, Hopkinson et al. 1992; Hauzeur, Mathy et al. 1999). A more reliable method of detecting and quantifying synovitis is therefore desirable.

Arthroscopy allows direct visualisation of the synovial membrane and structures within the joint compartment. It is frequently used as a method of quantifying synovitis of the knee, and has been validated against histological findings in both OA and inflammatory arthritis (Lindblad and Hedfors 1985; Lindblad and Hedfors 1987). In addition recent evidence suggests synovitis visible on arthroscopy is a predictor of progression of OA (Ayril, Pickering et al. 2001). Magnetic resonance imaging has been shown to be a sensitive tool for detecting synovitis when compared with arthroscopy (Ostergaard, Stoltenberg et al. 1997), but issues relating to cost may affect patient access.

The use of US is increasing because it is relatively inexpensive, non-invasive, does not involve exposure to ionising radiation and as a result can be used repeatedly on the same patient in multiple anatomical areas. It therefore has the potential to assess the extent of synovitis and changes in the synovial volume over time. However, there are few validation studies of US and its ability to detect synovitis in large joints. Relatively small number studies have compared synovitis

detected by grey-scale US with MRI (Ostergaard, Court-Payen et al. 1995) and with arthroscopy (Worth, Hermann et al. 1986; Rubaltelli, Fiocco et al. 1994; Batalov, Kuzmanova et al. 1999), although the latter studies assessed only inflammatory arthritis patients with persistent knee synovitis referred for synovectomy, who may be expected to have greater volumes of synovitis. A recent publication has assessed the relatively new technique of Power Doppler US in the knee comparing it with histopathologic findings of synovial membrane vascularity in 23 patients with rheumatoid arthritis and osteoarthritis undergoing arthroplasty suggesting good correlation (Walther, Harms et al. 2001).

Whereas US has demonstrated good reproducibility for detecting erosions in the MCP joint (Wakefield, Gibbon et al. 2000) and assessing cartilage thickness in the knee (Disler, Raymond et al. 2000), there is no published data for reproducibility of knee synovitis. In this study, US and clinical assessment were compared with arthroscopy for the detection of synovitis in a large group of patients with knee pain. We also assessed the inter- and intra-reader reproducibility of US, as well as intra-reader reproducibility of arthroscopy, on a subset of patients.

3.5 Methods

3.5.1 Patients

Consecutive patients with knee pain referred for arthroscopy of the knee were included in the study. All patients had a clinical assessment and US performed by different physicians blinded to each other's findings prior to arthroscopy. The indications for referral to arthroscopy were either diagnostic or therapeutic and arthroscopy was performed on the signal knee only in all patients. Sixty knees from 60 patients were included in the study (30 female, 30 right knees). The mean age of patients was 52 (18-79) and clinical diagnoses included osteoarthritis (n=19), RA (n=16), SpA (n=14), oligoarthritis (n=4), gout (n=4) and anterior knee pain (n=3). The local research ethics committee gave approval for the study and informed consent was obtained from all patients before the procedures.

3.5.2 Clinical Assessment

All patients had a standard clinical assessment of the signal knee by the assessing physician who documented the presence or absence of synovitis, defined as the presence of an effusion (positive patella tap or bulge sign) or palpable synovial thickening.

3.5.3 Ultrasonography

An ATL (Advanced Technology Laboratories, Bothel, Washington, USA) HDI 3000 US machine with a linear array 10-5 MHz 'hockey stick' transducer was used to examine the knee on the same day as (but prior to) arthroscopy. Three areas of the knee; the medial compartment (MC), lateral compartment (LC) and suprapatella pouch (SPP) were assessed. The MC was defined as the area medial to

the patella running inferiorly past the medial joint line to the infero-medial aspect of the joint capsule; the LC the area lateral to the patella running inferiorly past the lateral joint line to the infero-lateral aspect of the joint capsule, and the SPP as the area above the patella. The retro-patella space was not included in the comparison because US is unable to fully visualise this space.

One physician (ZK) performed US on all patients, whereas for the last 10 patients US was also performed by an additional physician (RJW). Both were experienced in performing US and were blinded to the indication for the arthroscopy and clinical assessment findings, as well as the findings of the other ultrasonographer.

Ultrasonographic synovitis was defined as the presence of a thickened synovial membrane identified as the hypoechoic structure adjacent to the anechoic joint effusion and the more hyperechoic fatty tissue (Figure 3.1).

The patient was examined initially with the knee fully extended, then partially flexed to 30 degrees and each compartment was scanned in transverse and longitudinal planes. Moving the knee from the extended to partially flexed position allowed for better visualisation of all 3 compartments, but also caused movement of any synovial fluid if present, which helped create a better acoustic interface.

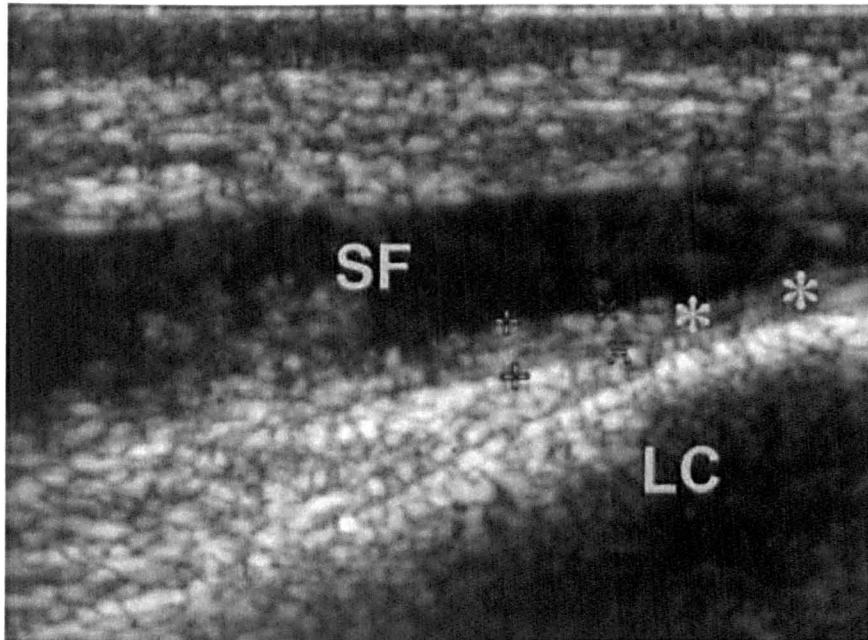


Figure 3.1 Ultrasonography. Knee synovitis.

This is a longitudinal view of the lateral compartment with the knee extended. The hypoechoic synovial membrane (+X*) with villi-like protrusions adjacent to the anechoic joint effusion and the more hyperechoic fatty tissue seen in a patient with RA. LC= Lateral Condyle, SF= Synovial Fluid.

Small amounts of fluid were detected by contraction of the quadriceps muscle and confirmed by transducer ballottement (Figure 3.2). Images of each compartment were recorded and stored on acetates with only the patients study number and compartment identified.

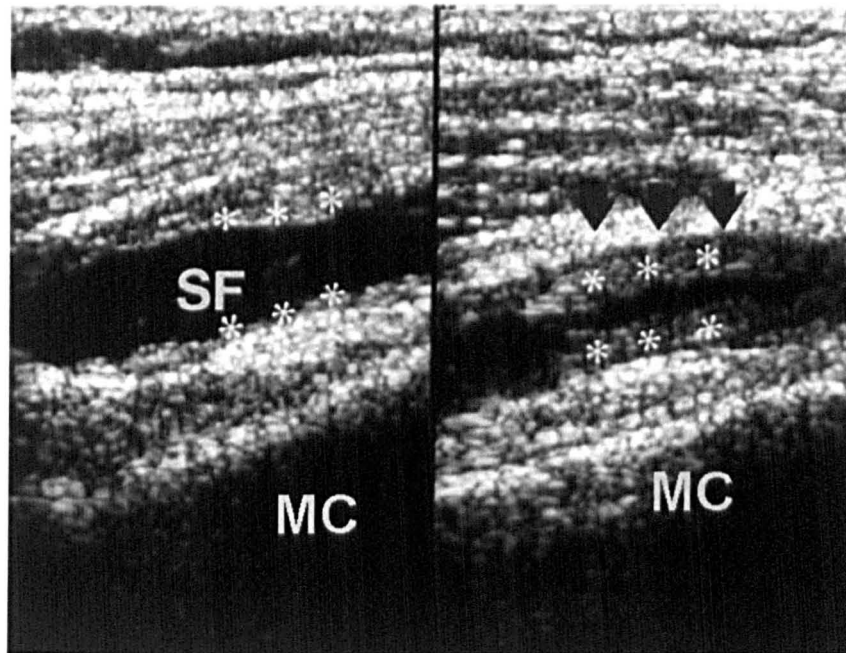


Figure 3.2 Ultrasonography. Ballottement of effusion

This is a longitudinal view of the suprapatella pouch with the knee flexed. The filled arrows demonstrate apposition of the synovial membrane (*) under pressure from the transducer. MC= Medial Condyle, SF= Synovial Fluid.

Synovitis was documented using a standard dichotomous scale as either present or absent for each of the compartments, with a semi-quantitative assessment for degree of synovitis also recorded (Normal = No synovitis; Mild = Flat thickened synovium; Moderate = Thickened synovium with few villi-like protrusions; Severe = Marked thickening with multiple villi-like protrusions). The presence or absence of synovial fluid was also documented.

Inter-reader reproducibility was calculated by comparing the findings of the 2 ultrasonographers for the 10 patients (30 compartments) who were examined independently and sequentially on the same day. Intra-observer reproducibility was calculated using stored images of 30 randomly chosen compartments reviewed a month after the end of the study period.

3.5.4 Medical Arthroscopy

A standard procedure was used to assess all knees. Arthroscopy was performed under local anaesthetic, using a Storz 2.7mm rigid arthroscope and a 5 mm drainage cannula. The physician performing arthroscopy was blinded to the findings at clinical assessment and US. Prior to insertion of the arthroscope the knee was distended with between 40 and 60ml of normal saline. The arthroscope was inserted through the infero-lateral portal with the drainage cannula in the supra-lateral portal, and the knee was lavaged with normal saline throughout the procedure. The knee was assessed in a structured manner with the SPP visualised first followed by the MC and LC.

Arthroscopic synovitis was defined as the presence of synovial membrane hypertrophy, documented as either increased granularity or villous hypertrophy (Figure 3.3, Figure 3.4, Figure 3.5) in each compartment. Increased granularity is seen as a milder form of synovitis with uniform low-grade thickening of the membrane as opposed to villous hypertrophy where there is increased thickness of the membrane with villi-like protrusions into the joint cavity. A 100 mm visual VAS to allow for comparison with an overall assessment of the knee, including the retro-patella space, was also completed by the arthroscopist. Images were captured digitally (Dyonics Vision Digital Management System 635) and intra-reader reproducibility was calculated using 30 randomly chosen images reviewed a month after the end of the study period.

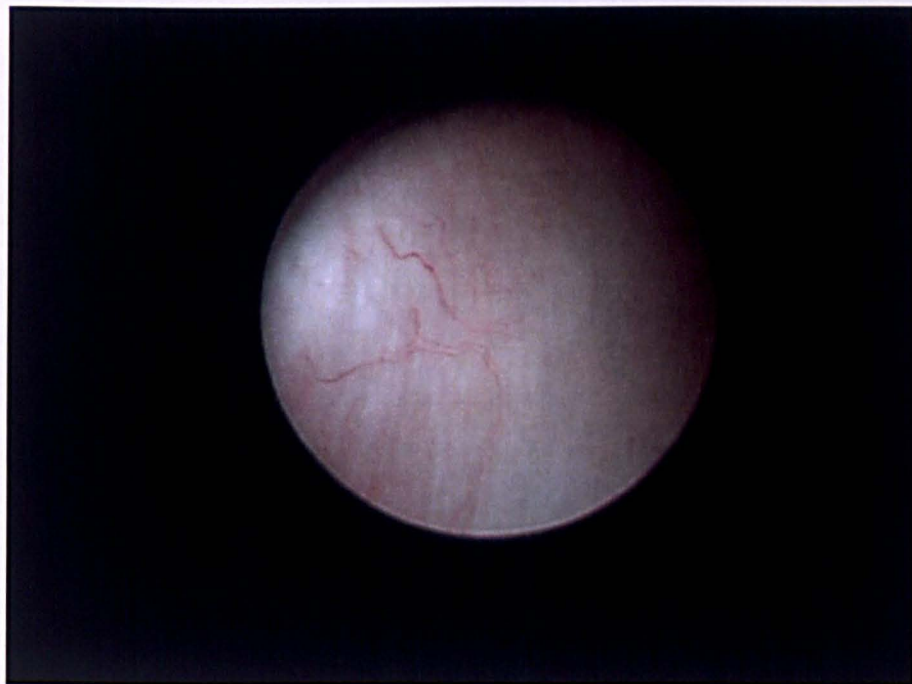


Figure 3.3 Arthroscopy. Normal synovium.

Normal Arthroscopy

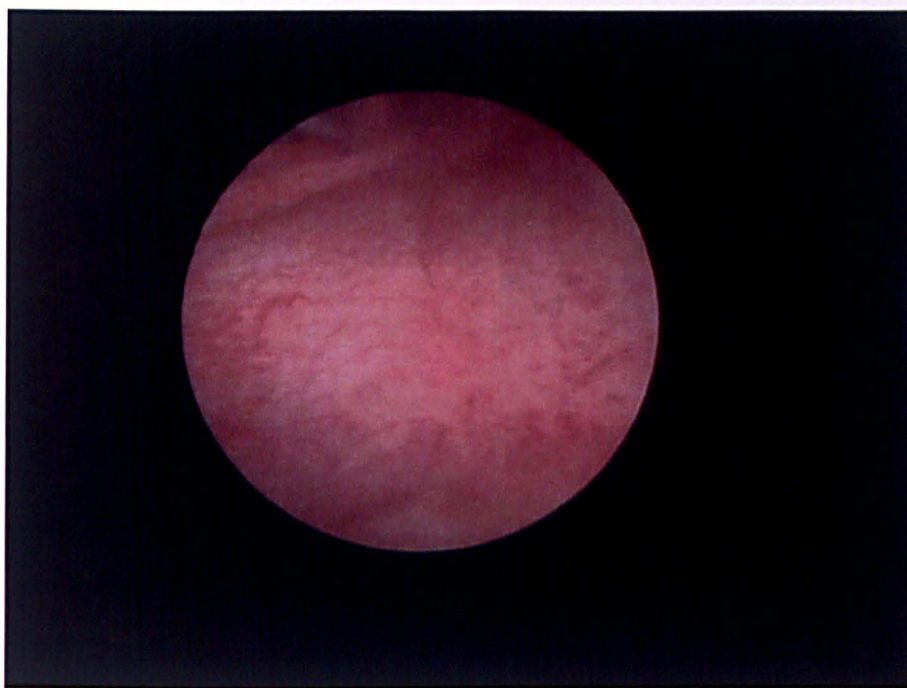


Figure 3.4 Arthroscopy. Increased granularity

Increased granularity, with the classic “cobblestone” appearance of the synovium, in a patient with RA.

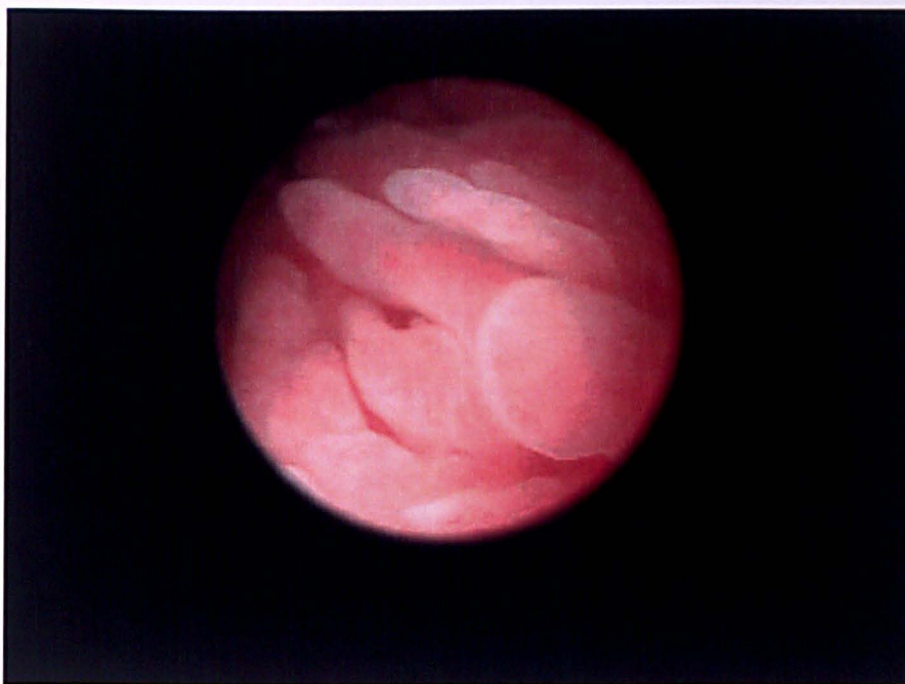


Figure 3.5 Arthroscopy. Villous Hypertrophy

Corresponding arthroscopy of patient in Figure 3.1 demonstrating villous hypertrophy.

3.5.5 Statistical Analysis

Sensitivity, specificity, positive and negative predictive values of US and clinical assessment were calculated using arthroscopy, and then arthroscopic VAS, as the gold standard. These values were then also calculated comparing clinical assessment with US as the gold standard. Intra-reader reproducibility for arthroscopy (0 = no synovitis, 1 = granularity, 2 = villous hypertrophy) as well as inter- and intra- reader reproducibility for the standard dichotomous (0 = no synovitis, 1 = synovitis) US scoring method was calculated using the Cohen-kappa test. The reproducibility of the semi-quantitative US scoring method 0-3 (0 =no synovitis, 1= mild synovitis, 2 = moderate synovitis, 3 = severe synovitis) for distinguishing grade of synovitis was calculated using a standard weighted kappa.

3.6 Results

Arthroscopy was able to assess 175/180 (97%) compartments in 60 patients. Access was difficult in 5 compartments due to plicae or adhesions. Arthroscopy detected synovitis in 52/60 (87%) patients and 119/175 (68%) compartments (differentiated as increased granularity in 43 and villous hypertrophy in 76 compartments).

3.6.1 Ultrasonography compared with Arthroscopy

Ultrasonography detected synovitis in 52/60 patients (87%) and synovial fluid was detected in all of these plus 3 other patients. Synovitis was detected in 121/175 (69%) compartments assessed by arthroscopy and in 4/5 of the compartments not accessible to arthroscopy.

Patients

In the 52 patients with arthroscopic detected synovitis (positive arthroscopy), US was positive in 51/52 (98%) and negative in 7 of the 8 (88%) negative on arthroscopy (i.e. there was one false-positive and one false-negative result with US). Using arthroscopy as the gold standard the sensitivity and positive predictive value for US was 98% for both and the specificity and negative predictive value in both 88%, resulting in an overall accuracy of 97% (Table 3.1). Synovial fluid was detected by US in 55/60 patients (92%), including all 52 patients with a positive arthroscopy plus three others (including the one US false-positive for synovitis) with a negative arthroscopy.

	US vs AR n=60 Patients	CA vs AR n=60 Patients	CA vs US n=60 Patients	US vs VAS n=60 Patients	CA vs VAS n=60 Patients
Sensitivity	98	85	87	96	85
Specificity	88	25	38	86	29
PPV	98	88	90	98	90
NPV	88	20	30	75	20
Accuracy	97	77	80	95	78

Table 3.1 Knee synovitis, validation by patient

Validation: Sensitivity, specificity, PPV, NPV, accuracy. Comparisons between modalities by patients. Clinical Assessment (CA), Arthroscopy (AR) . Numbers described as percentages.

Compartments

Ultrasonography detected synovitis in 107/119 (90%) compartments with a positive arthroscopy, and was negative in 42/56 (75%) in whom no synovitis was documented at arthroscopy. This resulted in a positive predictive value of 88%, a negative predictive value of 78% and an accuracy of 85% (Table 3.1). There was insignificant variation in sensitivity between the three compartments (Table 3.2). Ultrasonography was more sensitive at detecting villous hypertrophy (70/76 (92%)) compared with increased granularity (37/43 (86%)) as documented by arthroscopy.

	Overall (%) n=175	SPP (%) n=175	MC (%) n=175	LC (%) n=175
Sensitivity	90	91	88	92
Specificity	75	75	78	73
PPV	88	90	90	85
NPV	78	74	74	84
Accuracy	85	84	84	84

Table 3.2 Knee synovitis, validation by compartment

Validation: Sensitivity, specificity, PPV, NPV, accuracy. Comparisons between modalities by compartments. Clinical Assessment (CA), Arthroscopy (AR) . Numbers described as percentages.

3.6.2 Clinical assessment compared with Arthroscopy

Clinical assessment documented synovitis in 50/60 (83%) patients. Clinical assessment correctly identified synovitis in 44/52 (85%); 8 patients had arthroscopic synovitis undetected by clinical assessment, including the one patient with a false-negative US result. Clinical assessment was negative in 2/8 (25%) patients compared with arthroscopy (i.e. there were six false positive results); synovial fluid was detected by US in two of these six patients (including the only US false-

positive). The positive and negative predictive values of clinical assessment were 88% and 20% respectively resulting in an accuracy of 77% (Table 3.1).

3.6.3 Clinical assessment compared with Ultrasonography

Clinical assessment was positive in 45/52 (87%) and negative in 3/8 (38%) patients compared with US. This resulted in a positive predictive value of 90%, a negative predictive value of 30% and an accuracy of 80% when compared with US (Table 3.1). All of the 7 patients with US-detected synovitis not found on clinical assessment had arthroscopic synovitis.

3.6.4 Arthroscopic Visual Analogue Scale

The VAS scores for overall arthroscopic synovitis (including the retro-patella space) ranged from 5-99 mm with a mean of 34 mm. The VAS was positive in 53/60 (88%) patients; 52/53 (98%) of these had arthroscopic synovitis in the compartments under comparison, and one patient had isolated retro-patella granular hypertrophy and a VAS of 13mm.

Ultrasonography detected synovitis in 51/53 (96%) patients with a positive VAS with false negative results in the above-mentioned patient with retro-patellar disease (VAS 13 mm), and another with a VAS of 7 mm (mean 10mm). Both patients with false-negative US results had synovial fluid detected on US. Ultrasonography was negative in 6/7 (86%) patients with a VAS of zero. The positive and negative predictive values of US compared with arthroscopic VAS for overall synovitis were 98% and 75% respectively resulting in an accuracy of 95% (Table 3.1).

Clinical assessment was positive in 45/53 (85 %) patients with a positive VAS, including the one patient with isolated retro-patella disease and a VAS of 13mm. The 8 patients with a positive VAS and a (false) negative clinical assessment had VAS scores between 5 and 47 mm (mean 21). Clinical assessment was negative in 2/7 (29%) patients with a VAS of zero. The positive and negative predictive values of clinical assessment compared with arthroscopic VAS for overall synovitis were 90% and 20% respectively resulting in an accuracy of 78% (Table 3.1).

3.6.5 Reproducibility

The kappa value for agreement of intra-observer reproducibility for arthroscopy was 0.88. The kappa values using the dichotomous scale for the detection of synovitis with US were 0.71 and 0.85 for inter- and intra-observer reproducibility respectively ($p < 0.05$ for both). The weighted kappa values for agreement of the semi-quantitative US grading system were 0.65 and 0.74 for inter- and intra-observer reproducibility respectively.

3.7 Discussion

This is the largest study undertaken to validate US-detected knee synovitis in patients with a spectrum of disease and synovitis severity. It used arthroscopy as the gold standard, whilst also assessing its reproducibility and comparing US with clinical assessment. The results suggest that US can detect and accurately localise synovitis in the knee, and is more sensitive than clinical assessment. It is the first study to report the reproducibility of US-detected synovitis in the knee suggesting that US is a technique with high inter- and intra-observer reproducibility.

Compared with arthroscopy, US of the knee has the advantage of being non-invasive and able to visualise extra-capsular features such as the collateral ligaments, Baker's cysts, quadriceps and patellar tendons. We have demonstrated a high positive predictive value for US detection of synovitis suggesting that an US assessment of the knee may well negate the requirement for further, often more expensive and invasive, investigations. However, arthroscopy still has an important role particularly in differentiating between the inflammatory arthritides, performing tissue sampling under direct visualisation, and assessing the retropatellar space or the cruciate ligaments. The fact that only one knee had isolated retro-patellar granular hypertrophy (with a VAS for overall synovitis of 13 mm) suggests in this group of patients there is little additional information regarding synovitis in the retropatellar space. That US cannot fully visualise this space may be less important for the detection of synovitis.

Ultrasonography was able to detect synovitis in 7 of the 8 (88%) patients in whom clinical assessment failed to detect arthroscopic synovitis. The one patient with a false negative US had a very low arthroscopic synovitis score (VAS of 7 mm), compared with an average VAS score of 21 mm for the false negatives on

clinical assessment. This is consistent with previous reports suggesting clinical assessment is unable to detect low-grade synovitis (Martino, Angelelli et al. 1992; Hauzeur, Mathy et al. 1999). The clinical relevance of this lower grade synovitis may be particularly important in osteoarthritis where the degree of synovitis may be less, but still an important cause of symptoms (Hill, Gale et al. 2001) and predictor of damage (Ayrar, Pickering et al. 2001). This study also suggests US is more sensitive at detecting villous hypertrophy than simple granularity of the synovial membrane, which is to be expected with granularity representing an early, more subtle process with less synovial thickening compared with villous hypertrophy.

A small amount of synovial fluid may be seen in the normal knee joint with US and was present in all patients with arthroscopic synovitis including the one patient with a false-negative US result and the other patient with isolated retro-patella synovitis, suggesting increased vigilance for synovitis is warranted if synovial fluid is detected. Synovial fluid was also detected by US in 3 patients without synovitis on arthroscopy, but only one of these three had synovitis incorrectly diagnosed with US and clinical assessment, suggesting it has no major impact on the false-positive diagnosis of synovitis using these techniques.

This study demonstrates very good kappa values for inter- and intra-observer reproducibility of US in detecting the presence or absence of synovitis in the knee, and for intra-observer reproducibility for grading synovitis. This suggests US can be used with confidence in longitudinal studies by either individual or multiple operators for determining the presence or absence of synovitis, and by an individual operator for determining grade of synovitis. The level of inter-observer agreement using the semi-quantitative grading scale, although good, suggests when

using multiple operators other methods such as measurement of synovial thickness may need to be considered.

There are some limitations to this study. The use of macroscopic findings on arthroscopy as the gold standard could be questioned due to the dearth of published studies comparing this evaluation with histological changes (Parker and Keefer 1935; Yates and Scott 1975; Lindblad and Hedfors 1985; Lindblad and Hedfors 1987). The earlier studies (Parker and Keefer 1935; Yates and Scott 1975) had contrasting outcomes with one demonstrating poor (Parker and Keefer 1935) and the other demonstrating good correlation (Yates and Scott 1975), although neither took into account the variation of histological findings that can be seen within a single joint (Cruickshank 1952; Jayson and Dixon 1968; Yates and Scott 1975; Lindblad and Hedfors 1985; Hutton, Hinton et al. 1987). Studies addressing this variation, using an assessment technique similar to that of the present study, demonstrated good correlation between site-specific macroscopic findings and histological analysis (Lindblad and Hedfors 1985; Lindblad and Hedfors 1987). Our group have also demonstrated good correlation between global arthroscopic VAS for synovitis and immunohistology (CD4) (Veale, Reece et al. 1999). Furthermore the current study also demonstrates excellent intra-observer reproducibility of arthroscopy.

The clinical applicability of any gold standard is related to its pathogenic relevance, without which its prognostic capacity is diminished (Valenstein 1990). Currently there is no firm evidence that correlates histological findings with clinical outcomes, in particular joint damage. Also there appears to be only poor correlation of histological findings and CRP (Baeten, Demetter et al. 2000), an often-used surrogate of disease activity that cumulatively correlates well with disease progression (van Leeuwen, van Rijswijk et al. 1997; Plant, Williams et al. 2000). In

contrast there is a growing body of evidence which correlates synovial volume with subsequent joint erosions (Boers, Kostense et al. 2001; Conaghan, O'Connor et al. 2003). Arthroscopy directly visualises the synovium and current scoring methods offer a semi-quantitative assessment of severity and therefore disease bulk. There is a paucity of studies to correlate arthroscopic synovitis with damage (Ayrál, Pickering et al. 2001) and while further validation with US is required, this too is an area that requires further assessment.

Due to the difficulty in the anatomical delineation of the three compartments there may well be some overlap of compartments between US and arthroscopy. For example, if a patient had synovitis extending medially and laterally from the SPP the arthroscopist may have identified this as in the SPP only. The ultrasonographer however may have felt this extended into both the medial and lateral compartment hence scoring two false positives. The better results for patients as a whole compared to individual compartments (Table 3.1) may reflect this.

There is a selection bias in that all patients were referred for arthroscopy with knee pain therefore it is more likely that they would have been thought to have synovitis on clinical assessment. Furthermore the relatively low number of joints without arthroscopic synovitis (n=8) makes it difficult to extrapolate too much the specificity of US although it is clear that, even in this group where the majority of patients have synovitis, clinical assessment is relatively inaccurate.

Clinical assessment assessed the knee as a whole and did not differentiate between the retropatellar space and the other compartments, but only one patient had isolated retropatellar disease and US remained more sensitive than clinical assessment when compared with arthroscopic VAS for overall synovitis, which would have included this space. In this study the definition of clinical synovitis

deliberately did not include joint tenderness (peri-articular tenderness in the knee is common especially in degenerative and enthesal disease). Any increase in sensitivity as a result of including tenderness may have also been accompanied by an increase in false-positive diagnosis resulting in an even lower specificity and negative predictive value.

This study demonstrates that US is a valid and reproducible tool for the detection of synovitis in the knee joint and confirms previous reports that it is superior to clinical assessment.

3.8 Subsequent literature

In this chapter we evaluated the role of US in assessing knee joint synovitis, using arthroscopic findings to provide validity. Significant additions to the literature are described below.

3.8.1 Knee osteoarthritis

Clinical assessment

This cross sectional, multi-centre, European study conducted through the EULAR working group assessed six hundred patients with painful knee OA (D'Agostino, Conaghan et al. 2005). Ultrasonography was performed to determine the presence of synovitis or joint effusion. The authors found that with US; 16 (2.7%) had synovitis alone, 85 (14.2%) had both synovitis and effusion and 177 (29.5%) had joint effusion alone. They also found that US-detected synovitis/effusion had significant correlation with advanced x-ray changes (OR=2.20 and 1.91 for synovitis and joint effusion, respectively). There was also significant correlation for US inflammation with clinical signs and symptoms suggestive of an inflammatory "flare", such as joint effusion on clinical examination (OR=1.97 and 2.70 for synovitis and joint effusion, respectively) or sudden aggravation of knee pain (OR=1.77 for joint effusion). The authors concluded that US detected evidence of inflammation in over a third of patients and that this correlated significantly with advanced x-ray changes, and clinical synovitis/effusion. This study again suggests that synovitis is common in OA knee and correlates with advanced x-ray changes.

Using the same cohort of patients described above, this same group determined whether clinical findings allow recognition of synovitis in patients with painful knee OA (Conaghan, D'Agostino et al. 2005). The authors used a

classification and regression tree analysis to find combinations of predictor variables that would provide high sensitivity and specificity for clinically detecting synovitis and effusion in individual subjects. The outcome of the study was that whilst the clinical findings may have been able to demonstrate some predictors in populations with OA, clinical findings like effusion, and also x-ray, were poor predictors of inflammation in individual patients. The authors concluded that sensitive imaging techniques such as US remain the most useful tool for demonstrating inflammation in individual cases.

US findings are associated with pain

In this study 50 patients with primary OA knee had US, clinical and x-ray assessments (Naredo, Cabero et al. 2005). Findings with US were; effusion 47%, protrusion of the medial meniscus (MMP) with displacement of the medial collateral ligament (MCLD) (61%) and Baker's cyst (22%). This study also demonstrated that US effusion, protrusion of the medial meniscus (MMP) and displacement of the medial collateral ligament were all associated with a significantly higher VAS ($P<0.05$). Apart from suggesting that certain US features are associated with certain pain scores, this study also demonstrates that effusion is common in OA knee.

3.8.2 Knee rheumatoid arthritis

Clinical assessment

This study compared US with clinical assessment in 22 patients (44 knees) with RA (Kane, Balint et al. 2003). For each knee the presence of suprapatellar bursitis, knee effusion, or Baker's cyst was documented and compared with similar findings with clinical assessment. Ultrasonography detected soft tissue abnormality

in 42% compared with 28% of sites with clinical assessment. The authors concluded that US of the knee is more sensitive than clinical assessment which underestimates inflammation in knee RA. The argument has implications for the use of clinical assessment as part of disease activity scores.

Another study compared contrast-enhanced PD US with clinical assessment in 42 patients with RA knee (Carotti, Salaffi et al. 2002). Using clinical assessment patients were categorised as having inactive, moderately active or active disease. The mean value of the area underlying time-intensity curves was 216.2, 186.8 and 169.6 in patients with active, moderately active and inactive disease. The difference between patients with active and inactive disease was significant ($P<0.01$). They also found that the findings with US correlated weakly with the SJC, but strongly with DAS ($P=0.006$). The authors concluded that PD US is able to distinguish between degrees of clinical synovitis.

This same group also used PD US enhanced with bubble-contrast (Levovist) to assess changes following therapy, in this case intra articular corticosteroid injection, in RA patients (Salaffi, Carotti et al. 2004). Clinical and US assessments were performed prior to, and three weeks after injection. Clinical assessment revealed significant reduction in the index of synovitis activity from 7.0 to 3.0 ($p<0.01$), and for US all patients showed a reduction of PD signal following therapy, and a comparison between baseline and follow-up PD US quantitative scores revealed a significant reduction ($p<0.01$). Changes in the index scores of synovitis activity also correlated significantly with changes in the PD US values ($r=0.785$; $p<0.01$). Significant correlation was also observed between baseline PD US values and CRP as well. The authors concluded that PD US with contrast agent is sensitive to changes in synovial perfusion after intra-articular corticosteroid injection. Whilst

this study demonstrates significant changes in PD US findings, this only suggests the ability to detect changes rather than true concurrent validity because there is no correlation with a gold standard measure, although some may argue that correlation with reduction in CRP provides construct validity.

Validation

Power Doppler US, with microbubbles (Levovist) has been compared with arthroscopy in 17 patients (18 knees) of patients with RA or PsA (Fiocco, Ferro et al. 2003). In this study, patients had PD US performed on its own, then repeated following infusion of contrast microbubbles, then compared with arthroscopy as the gold standard. Following administration of microbubble contrast, the PD flow signal score was increased in 13/18 knees (72.2%). Microbubble enhanced PD demonstrated more reproducible PD signal using arthroscopy as the gold standard compared with un-enhanced PD, and was also more sensitive (80% vs. 30%), but less specific (62% vs. 87%) at recognising increased vascularity of synovium. The authors concluded that microbubble enhanced PD is an effective and reliable tool at detecting increases in synovial vascularity. This study confirms the validity of US using arthroscopy as the gold standard, but also demonstrates validity for bubble contrast. This study also demonstrates however, a pitfall of microbubble enhanced PD with a loss of specificity, demonstrating the need for using normal patients as controls to try and define what is normal and what is not.

Response to therapy

Fiocco and colleagues also assessed 27 knees affected by RA (12 patients) and PsA (8 patients) before and after anti-TNF alpha therapy (etanercept) and

compared findings with clinical measures (Fiocco, Ferro et al. 2005). Following treatment they demonstrated that compared to baseline measurements PD flow reduced ($p < 0.001$), parallel to reductions of CRP ($p < 0.05$), erythrocyte sedimentation rate (ESR) ($p < 0.001$), knee joint articular index ($p < 0.002$), Ritchie articular index and global health scores ($p < 0.001$). This study, whilst not demonstrating any true concurrent validity, suggests PD US is sensitive to change following treatment.

3.8.3 Other joints

There are also more publications regarding the validation of US-detected synovitis.

Rheumatoid arthritis

Small joints

I have already described earlier work by Backhaus and colleagues (Backhaus, Kamradt et al. 1999) comparing US with clinical assessment, MRI and bone scintigraphy in 60 patients with RA, OA and arthritis associated with connective tissue disease. Forty-nine of the original group had a repeat assessment 2 years later (Backhaus, Burmester et al. 2002) using similar methodology. They documented that inflammation by bone scintigraphy, and synovitis on US and MRI had significantly reduced. They did note however that US tenosynovitis of the flexor sheath was reduced significantly but increased in the extensor tendon, compared with reduction in both with MRI. The same group recently completed a 7 year review (Scheel, Hermann et al. 2006) this time using MRI, US and x-ray. Despite a loss of group numbers after 7 years US and MRI again documented significant reductions in synovitis from baseline ($p < 0.001$ for both), with significant reductions also seen in swollen and tender joint counts. The work by Backhaus & colleagues

reflects the degree to which the assessment of US has changed in the last decade, demonstrating concurrent validity where US-detected synovitis was compared with MRI and bone scintigraphy.

The same cohort of patients from an earlier study (Szkudlarek, Court-Payen et al. 2001) had injection of Levovist with any changes in flow noted (Szkudlarek, Court-Payen et al. 2003). Levovist increased the flow signal in 7/9 joints with pre-contrast flow-signal but did not add signal to the 9 joints previously without. Healthy controls remained negative, overall the relative rate of contrast enhanced MRI was significantly higher in joints with Levovist enhanced PD US compared to those without. There was also no correlation between clinical assessment and Levovist enhanced PD US. The authors concluded that intravenous contrast injection whilst not increasing the sensitivity in this study may provide additional information in the assessment of RA. No healthy controls showed contrast enhanced PD US signal.

This study compared CD US of the wrists, MCPs and PIPs in 29 RA patients with MRI and clinical assessment (Terslev, Torp-Pedersen et al. 2003). This study confirmed a highly significant association between spectral Doppler resistive index and post contrast MRI. There were also significant differences in the groups with joint swelling compared to other groups using CD US. The authors concluded that CD US was comparable with post contrast MRI and estimation as in this study using colour fraction and the resistance index obtained with CD US was a promising method for the detection of synovitis in patients with RA.

This study included 200 MTP joints of 40 patients with RA and 100 MTP joints of 20 healthy controls and assessed US, MRI and clinical examination for the detection of joint inflammation with MRI being regarded as the gold standard

(Szkudlarek, Narvestad et al. 2004) The sensitivity, specificity, and accuracy of US for the detection of synovitis were 0.87, 0.74, and 0.79 respectively, while for clinical examination; the corresponding values were 0.43, 0.89, and 0.71 respectively. For patients, US demonstrated synovitis in 36, while MRI and clinical examination revealed synovitis in 31 and 20 patients respectively. US and MRI synovitis showed intra-class correlation coefficients of 0.56-0.72 ($P < 0.0001$). The sensitivity, specificity and accuracy of US for the detection of bone erosions were 0.79, 0.97 and 0.96 respectively, while the corresponding values for radiography were 0.32, 0.98 and 0.93. With regard to patients, erosions were identified in 26 patients by US compared with 20 patients by MRI and 11 by x-ray. They also demonstrated that the sized-based gradings with US of erosions were closely related to MRI and x-ray. The authors concluded that US was more sensitive and accurate than clinical examination and had good correlation with MRI for the detection of synovitis, and that US is a valid and significantly more sensitive than x-ray at detecting erosions. This study again demonstrates the relative lack of sensitivity of clinical examination to detect synovitis in the MTP joint, and also demonstrated concurrent validity for US.

Large joints

This study by Hermann & colleagues (Hermann, Backhaus et al. 2003) used US and MRI to detect pathology in the shoulders of 43 consecutive patients with RA. US assessment included long head of biceps tendon for tenosynovitis, and subacromial or subcoracoid bursitis. This study suggests that MRI is significantly more sensitive than US. Synovitis was detected in 12 and 27 patients ($P=0.0003$), tenosynovitis in 15 and 28 patients ($p=0.0064$), and bursitis in 13 and 18 patients

(not significant), with US and MRI respectively. This study unlike previous studies (Alasaarela, Leppilahti et al. 1998) suggests US is relatively insensitive.

Comparison with histology in hip

In this important study PD US findings of synovial tissue vascularity in the hip joint have also recently been compared with histology of the same tissue (Walther, Harms et al. 2002). All involved joints were examined with US prior to arthroplasty. Samples of synovial tissue that had been assessed with US were resected and examined by a blinded pathologist for vascularity. Spearman rank correlation tests were used to assess correlation between PD US and findings at histology. Correlation between qualitative PD US and qualitative vascularity grades from histological analysis was 0.92 ($p < 0.01$). The authors concluded that PD US is valid for grading vascularity of the hip. This study, like their earlier study of the knee (Walther, Harms et al. 2001), provides true gold-standard concurrent validity with PD US compared with histology to detect synovitis.

3.9 Summary

In this chapter we confirm, using arthroscopy as the gold-standard, that US has a higher sensitivity, specificity, accuracy, positive- and negative-predictive value compared with clinical assessment. Ultrasonography also demonstrated good inter- and intra-reader reproducibility for detecting presence or absence of synovitis, as well as distinguishing the grade of synovitis, confirming that US is not only a valid and reproducible tool for detecting synovitis in the knee but also that it is more sensitive than clinical assessment.

Further work in this area includes the need for more validation with histology for gray-scale and PD US, with and without bubble contrast, concentrating not only on the ability to measure small differences in synovial thickening or vascularity, but also the reliability of these particular measurements. Quantitative analysis needs to then be compared with semi-quantitative analysis to evaluate the validity of the usually quicker semi-quantitative method for the detection of synovitis, and subsequent monitoring of response to therapy. Longitudinal studies with reliability comparisons are required to properly assess the sensitivity of US in detecting changes over time. Work in assessing US changes and corresponding sites of pain in OA, SPA and RA is very interesting and may lead to predictive validity studies in the longer term.

Chapter 4

4.1 Clinical Utility: Accuracy of Shoulder Injections

4.2 Clinical relevance

There is considerable variation in response to corticosteroid injections and the limited evidence is that up to half of these are placed inaccurately. Shoulder pain is common and the assessment of patients presenting with signs and symptoms suggesting impingement can be particularly challenging. Diagnosis often relies on a combination of physical assessment and the use of diagnostic local anaesthetic injections, and management the use of corticosteroid injections. Ultrasonography is used to guide subacromial injection, but there is limited data confirming the accuracy of placement.

4.3 Abstract

4.3.1 Aims

To determine the accuracy of US-guided subacromial injections in patients referred with shoulder pain.

4.3.2 Methods

Patients referred for US-guided injection had US performed to rule out a full thickness tear (exclusion), before having guided injection with a mixture of anaesthetic, corticosteroid, and x-ray contrast. Immediate post injection AP and axial radiographs were obtained of the injected shoulder joint. The radiographs were then reviewed and the injection was classified as being either intrabursal, extrabursal or combined intrabursal and extrabursal according to pre-defined criteria.

4.3.3 Results

Eleven patients (11 shoulders) were assessed. All 11 had evidence of subacromial bursitis, and 9 had evidence of supraspinatus tendinopathy. The supraspinatus tendon was intact in all 11.

Five (45%) of the injections were assessed as being entirely intrabursal with the remaining 6 (55%) assessed as combined intra- and extrabursal injections. No injections were entirely extrabursal. Extrabursal contrast was limited to the tissue planes adjacent to the bursa with no evidence of contrast within the glenohumeral joint. No patients suffered any immediate complications as a result of the injections performed and no patients had to be excluded from the study.

4.3.4 Conclusions

US-guided injections into the subacromial bursa are accurate, but extravasation along the needle track is common.

4.4 Introduction

Subacromial impingement is a common and well recognised cause of shoulder pain in young and middle aged patients. The diagnosis of shoulder disorders can be difficult but US has proved to be of diagnostic value in the identification of tears and calcific tendonitis of the rotator cuff (van Moppes, Veldkamp et al. 1995; Alasaarela, Takalo et al. 1997; Read and Perko 1998; Swen, Jacobs et al. 1998; Swen, Jacobs et al. 1999). The clinical assessment of impingement is particularly challenging and relies on a combination of physical examination and the use of diagnostic local anaesthetic injections. Studies assessing clinical impingement tests against arthroscopic findings have shown manoeuvres such as the Neer or Hawkin's tests to be of only limited diagnostic value (MacDonald, Clark et al. 2000).

Diagnostic injections aim to place local anaesthetic in the subacromial bursa and then assess patient response. Marked improvement in the patient's symptoms and signs strongly suggests a diagnosis of subacromial impingement. These injections are usually performed by clinicians in the outpatient clinic using a standard approach as a 'blind' procedure. Previous studies have demonstrated that these are often inaccurate. In a study of patients who had shoulders injections only 4/14 attempted subacromial injections (29%), and 10/24 attempted glenohumeral injections (42%) were accurate (Eustace, Brophy et al. 1997). A cadaveric study demonstrated that subacromial bursa injection was successful in 20 shoulders (83%), but in 15 (62%) other structures were also infiltrated, including seven injections in the rotator cuff (Partington and Broome 1998). In another study 'blind' injections were accurate in approximately half of all cases and 50% large joints (Jones, Regan et al. 1993). These figures raise serious doubt

about the validity of blind injections for both diagnostic and therapeutic injections of the subacromial bursa.

Although US has been used to guide joint injections in rheumatology practice, and injections into the shoulder sub-acromial bursa are common in our practice (Brown, Karim et al. 2001), the only publication to my knowledge at the time of this work is for guided injections into the shoulder (glenohumeral) joint (Cicak, Matasovic et al. 1992). In this study 24 patients had US-guided shoulder arthrography using a posterior, as opposed to the traditional anterior, approach with 100% accuracy and without any evidence of injury to adjacent structures or extravasation of injection.

The importance of placement of injections has been demonstrated by the study of Eustace and colleagues described above, where patients with accurate shoulder injections had improved VAS and range of movement outcomes in comparison to those with inaccurate injections (Eustace, Brophy et al. 1997). In a separate study of 19 patients with de Quervain's tenosynovitis, accurate injections also led to better outcomes (Zingas, Failla et al. 1998).

The aim of this study was to assess the accuracy of US-guided injection of the subacromial bursa.

4.5 Methods

4.5.1 Patients

11 consecutive patients with painful arc syndrome of the shoulder and US findings of bursitis without a full thickness cuff tear were prospectively studied. These patients were primary care referrals for shoulder x-ray and US with a clinical request to continue to diagnostic or therapeutic injection dependant on the US findings. Patients allergic to iodinated contrast or to triamcinolone acetonide were excluded from the study, and informed consent was obtained from all patients prior to injection.

4.5.2 Injection

All patients had US and injection performed by an experienced musculoskeletal radiologist (POC). An ATL (Advanced Technology Laboratories, Bothel, Washington, USA) HDI 3000 US machine with a linear array 10-5 MHz transducer was used to examine the shoulder. Once US findings ruled out full thickness tear (Figure 4.1) the shoulder to be injected was held in an extended and internally rotated position, and the needle path was identified using the US probe and the puncture site marked.

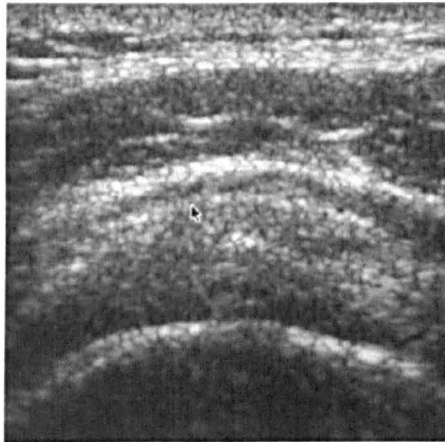


Figure 4.1 Ultrasonography of subacromial bursa

Figure 4.1 The subacromial bursa is demonstrated as the hypoechoic area above the more echogenic supraspinatus tendon (with black arrow).

The skin was then cleaned with chlorhexidine gluconate surgical skin preparation and a small dermal injection of 1% lignocaine was performed using a 25G needle. A 21 gauge needle was then directed into the subacromial bursa under US-guidance, virtually parallel to both bursa and the transducer to ensure excellent needle visualisation (Figure 4.2, Figure 4.3).

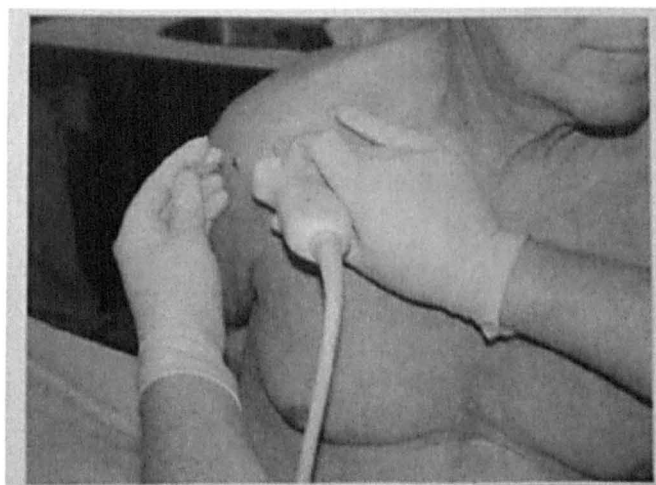


Figure 4.2 Needle placement: under direct visualisation

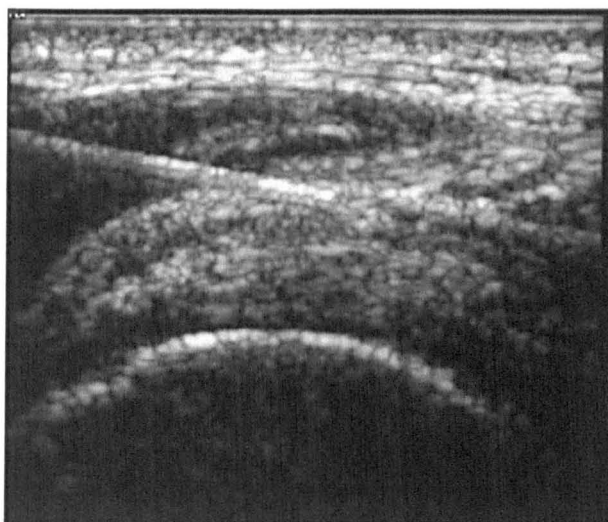


Figure 4.3 Ultrasonography with needle placement

Figure 4.3 The needle is passed into the bursa under direct visualisation.

To allow injection under direct visualisation a short connector tube was attached to the needle to enable the operator to scan while injecting. The patients were injected with 20mg corticosteroid (triamcinolone acetonide, 0.5ml), 3.5mls of local anaesthetic (1% lignocaine) and 6mls of iodinated contrast (Ultravist 370, Schering) into the subacromial bursa via a 21G needle sited under US monitoring. If the injection was seen to collect around the needle tip, the needle was repositioned until free flow, without local accumulation, away from the needle tip was obtained.

4.5.3 X-ray

Anterior-posterior and axial x-rays of the injected shoulder were obtained immediately after injection and reviewed by 2 Musculoskeletal Radiologists (JR and PR) who gave a consensus opinion as to the placement of each injection. The injection was then classified as being either intrabursal, extrabursal or combined intrabursal and extrabursal. The position of contrast was determined using the standardised criteria derived from cadaveric studies (Strizak, Danzig et al. 1982; Beals, Harryman et al. 1998). An intra-bursal injection was defined as a 'cap' like collection of contrast with clearly defined rounded borders lying in a subdeltoid position extending lateral to the greater tuberosity, and extrabursal injections were defined as having unconstrained, sharp margins (Figure 4.4, Figure 4.5, Figure 4.6)

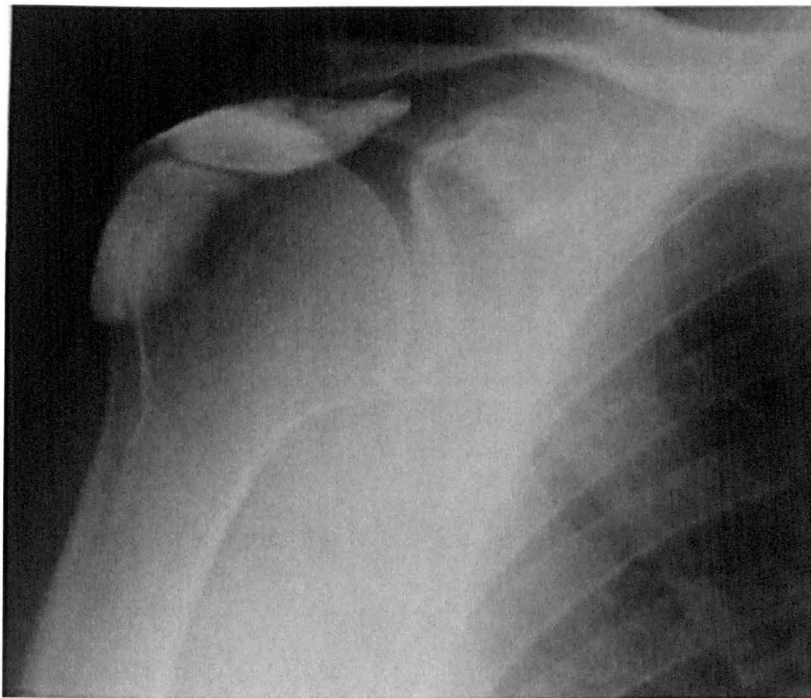


Figure 4.4 X-ray with contrast: Intrabursal injection

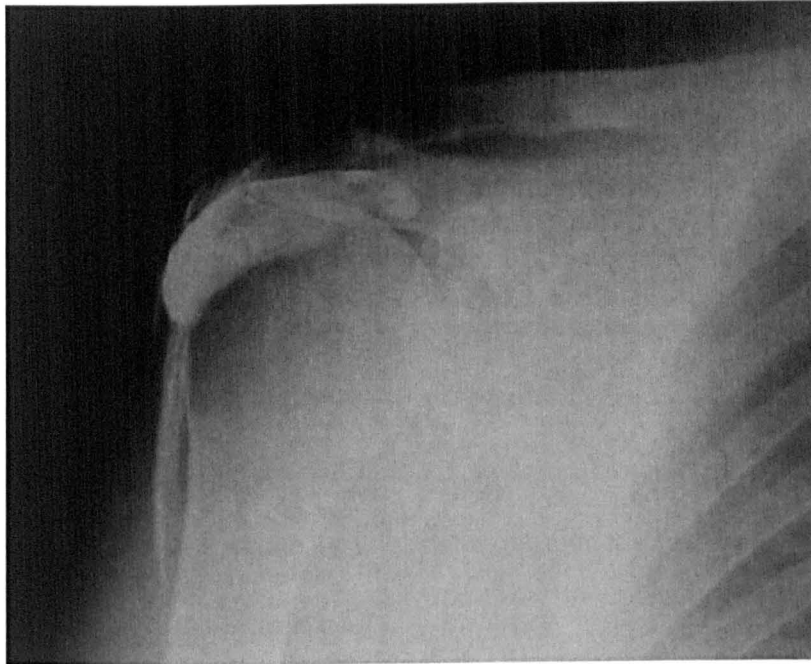


Figure 4.5 X-ray with contrast: Mainly intrabursal with some extrabursal

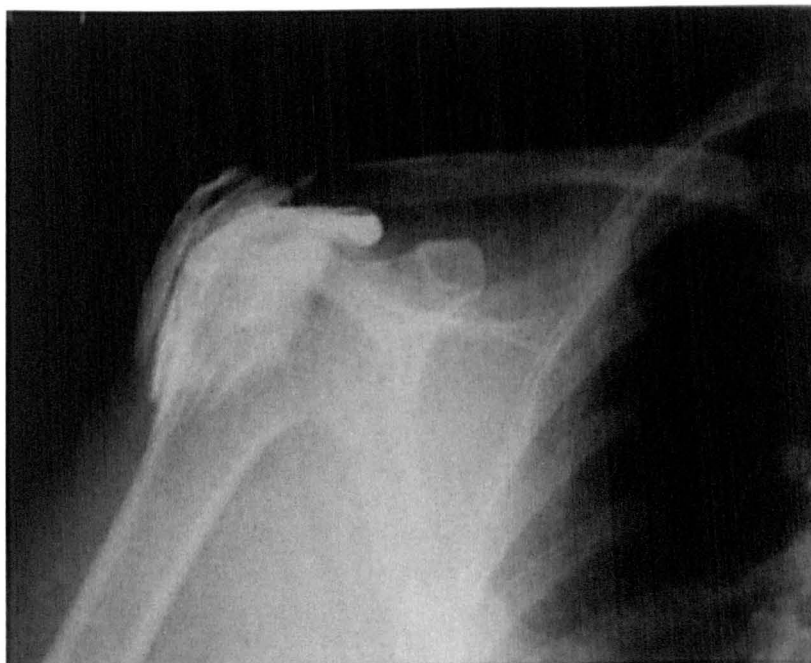

Figure 4.6 X-ray with contrast: Mixed intra- and extra-bursal injection

4.6 Results

A total of eleven patient injections were assessed (4 left, 7 right shoulders). There were 8 men, 7 women; age range 31-55, mean age 46. All patients had unilateral shoulder symptoms and none had a diagnosis of inflammatory arthritis such as RA or PsA. The initial US showed all eleven to have subacromial bursitis and evidence of impingement (bunching of the subacromial bursa under the coracoacromial ligament as the arm is flexed, abducted and externally rotated from an extended and internally rotated position). Nine out of the eleven had supraspinatus tendinopathy but in all eleven the supraspinatus tendon was intact.

After review of the plain radiographs five (45%) of the injections were assessed as being entirely intrabursal with the remaining 6 (55%) assessed as combined intra- and extrabursal injections. No injections were entirely extrabursal. Extrabursal contrast accumulation was limited to the tissue planes adjacent to the bursa with no evidence of contrast within the glenohumeral joint.

No patients suffered any immediate complications as a result of the injections performed and no patients had to be excluded from the study.

4.7 Discussion

Clinical tests for impingement have limited diagnostic value with studies showing the Neer and Hawkins tests to have high sensitivity but low specificity when compared to an arthroscopic gold standard (MacDonald, Clark et al. 2000) while the 'drop-arm' and Yergason tests have low sensitivity and high specificity (Calis, Akgun et al. 2000). Furthermore many studies and clinical practices are based upon the assumption that blind injections are accurate (Petri, Dobrow et al. 1987; Vecchio, Hazleman et al. 1993; Winters, Sobel et al. 1997).

The requirement for accurate placement of diagnostic injections is manifest. Therapeutic injections may require exact placement, since accurate injections are shown to have greater therapeutic effect (Eustace, Brophy et al. 1997; Zingas, Failla et al. 1998). It has not yet been shown whether accurate placement of subacromial injections is essential although as the Neer classification clearly describes a pathological process centred on the subacromial bursa it would seem logical for injection treatment of impingement to be sited within the bursa (Neer 1983).

In our study nearly half of all injections performed US-guidance were entirely intrabursal, with 100% being at least in part intrabursal. The definition applied by the observers in determining the presence of intrabursal contrast required good distension to demonstrate the rounded clearly defined outline of the subacromial-subdeltoid bursa, suggesting the remaining injections all had a substantial intrabursal component. Since it is anatomically impossible for a purely extrabursal injection to enter the bursa in normal patients, it is therefore likely that the retrograde extravasation down the needle track in between the injection and the performance of the x-ray is the likely cause for the combined intra and extrabursal injections.

In the study of posterior approach US-guided glenohumeral injections however, there were no extravasations noted (Cicak, Matasovic et al. 1992), although the shoulder joint will accept more fluid without a noticeable increase in pressure and in our study 10mls of fluid was injected. In the cadaveric study 7/20 injections involved infiltration into the rotator cuff, which while alarming is not truly representative of clinical practice where one would expect resistance to injection, and patients to describe discomfort if the needle entered the cuff (Partington and Broome 1998). The study involving de Quervain's tenosynovitis where the APL and EPB tendons are in close proximity, with the smaller EPB often deeper than the APL tendon suggests that in complex areas US-guided injection may be advantageous.

The main limitation of this study is that it is relatively small, and the large volume of injection with contrast does not reflect usual practice when using US to guide injections.

4.8 Subsequent literature

In this chapter we evaluated the accuracy of US-guided injections of corticosteroid (with contrast) in the shoulder subacromial bursa, confirming placement with x-ray immediately after injection. There have been a large amount of publications related to this subject since this original work was carried out. Significant additions to the literature are described below.

4.8.1 New Techniques

'Blind' knee injection

In this study using an injection mixture of air and x-ray contrast, patients were either ascribed to receive an intraarticular (20 knees) or extraarticular injection (10 knees) (Glattes, Spindler et al. 2004). Using the hypothesis that a small amount of air injected into the knee produces an audible "squishing" sound with range of motion patients were assessed for this sign immediately after injection. Clearly audible squishing sounds were present in 17/20 (85%) intraarticular and none of the extraarticular injections. The authors concluded that this simple technique can confirm accurate placement of injection and should be routinely documented.

US-guided carpal tunnel injection

In this pictorial essay guided injection in carpal tunnel syndrome associated with tenosynovitis of the finger flexor tendons is demonstrated (Grassi, Farina et al. 2002). Using a thin metal clip placed on the skin the best injection site is determined, before the needle is guided under direct visualisation. They conclude this is a safe and simple method to accurately guide therapy in carpal tunnel syndrome.

US injection with 'air' contrast

This descriptive study demonstrates the technique of adding air to the injection to provide echo contrast that is easily detected with US (Qvistgaard, Kristoffersen et al. 2001). US was used to guide the needle into the joint (knee or hip) and 0.5-1 ml of atmospheric air and 1 ml lignocaine 1% was injected with direct visualisation. In the hip joint the injected air was readily demonstrated with a sharp echoic contrast on the US recording. In the knee best results were seen with injection into either the suprapatellar bursa or lateral joint space. The authors suggest this simple technique should be used with US to avoid using contrast and x-ray to confirm placement.

A similar study using small volumes of air in the injection mixture has demonstrated good echo contrast under direct US visualisation in the wrist, shoulder, knee, ankle and foot joint (Koski, Saarakkala et al. 2005).

US-guided surgery

This study describes findings in 75 patients who had US-guided percutaneous tenotomy of the Achilles tendon under local-anaesthetic in the outpatient setting after failure of conservative therapy (Testa, Capasso et al. 2002). Sixty-three patients had prolonged follow-up; 35 were rated excellent, 12 good, 9 fair, and 7 poor. The US findings of thickening persisted in the operated tendons even 8 years after the operation, without interfering with physical training. The authors argue that this technique should be used in patients with localised tendinopathy and avoided in diffuse tendon disease.

4.8.2 US compared with clinical aspiration

A study compared the accuracy of palpation-guided with US-guided needle placement in small joints for fluid aspiration (Raza, Lee et al. 2003). Palpation-guided injections were intra-articular in 59% (6/12 PIP and 4/5 MCP joints) cases. In comparison US-guided injections were intra-articular in 96% of cases (24/26 PIP and 27/27 MCP joints).

A similar study by Balint and colleagues performed a study of joint aspiration comparing conventional 'blind' needle placing techniques with US-guided placement (Balint, Kane et al. 2002). A total of 61 consecutive patients were included in this study. In the group that had conventional 'blind' aspiration, 32 joints in 30 consecutive patients were referred for joint aspirated, compared with 31 consecutive patients having US-guided aspirations. Ten joints (32%) had fluid aspirated using the 'blind' technique compared with 30 (97%) using US, however there was no difference in the volumes of fluid aspirated when successful aspiration occurred to confirm the presence and location of fluid. The authors concluded that US was a useful tool in guiding aspiration and also joint injection.

4.8.3 Accuracy

Subacromial bursa

This study which is similar in methodology to the study by Eustace and colleagues (Eustace, Brophy et al. 1997) compared outcomes in 48 patients with 'blind' subacromial injections. All injections included x-ray contrast with the corticosteroid and local anaesthetic (Esenyel, Esenyel et al. 2003). Using an anterolateral approach 42/48 (87%) injections were accurate. This study also assessed

outcome, and while both accurate and inaccurate injections demonstrated improvement 2 hours after injection (local anaesthetic effect) patients with inaccurate injections had relapsed as opposed to the accurate injection group where improvement continued. The authors concluded that accurate injections had a longer effect.

In a cadaveric study, the anterolateral approach was compared with the posterior approach (Mathews and Glousman 2005). Using x-ray contrast the anterolateral approach was deemed to be accurate in 18/20 (90%) compared with 16/20 (80%) of posterior injections. The authors concluded that using fluoroscopy to confirm injection, accuracy was good and that there was no significant difference between either approach.

In another study (Yamakado 2002) using the anterolateral approach, subacromial injections using x-ray contrast, were seen to be accurate in 39/56 (70%) of cases. Twelve (21%) were seen in and around the deltoid muscle; 2 (4%) were in the glenohumeral joint; and 3 (5%) were subcutaneous. The authors concluded that whilst the majority of injections were in the subacromial bursa a significant number entered the deltoid.

Glenohumeral joint

This cadaveric study compared the anterior versus the posterior approach (20 shoulders each) to inject the glenohumeral joint (Sethi and El Attrache 2006). They found that the anterior approach had an 80% accuracy rate, compared with 50% accuracy for the posterior approach. The authors concluded that the anterior approach to glenohumeral joint injection was more appropriate.

US-guided hip injections

This study used US-guided intra-articular sodium hyaluronate in 10 patients with hip OA (Pourbagher, Ozalay et al. 2005). Each patient received three injections, 1 per week for three consecutive weeks using contrast medium injected and confirmed with CT prior to injection with hyaluronate. CT confirmed accurate placement in all 30 injections. This study provides a good level of concurrent validity for guided injections in the hip, confirmed with CT.

4.8.4 Outcome

US-guided injection; Calcific tendonitis

This study of US-guided injections in calcific tendonitis demonstrates considerable benefits in 34/39 patients without complications in any of the 39 cases (Galletti, Magnani et al. 2004). The authors suggest that this is a simple relatively low cost method of treating calcific tendonitis.

Calcific tendonitis; comparison with 'blind' injections

Chen and colleagues performed a randomised controlled short-term injection trial of 40 patients with US confirmed subacromial bursitis (Chen, Lew et al. 2006). Patients were randomly allocated to have a 'blind' or US-guided injection. This study demonstrated significant increases in the range of abduction of patients with US-guided injections from 69 to 139 degrees. The improvement in the 'blind' injection group (71 to 100 degrees) did not reach statistical significance. The authors concluded that US-guided injections can result in significant improvement in shoulder abduction.

Painful shoulder; comparison with 'blind' injection

This prospective randomised study, compared US-guided (n=21) injection with 'blind' (n=20) injection in patients with painful shoulders (Naredo, Cabero et al. 2004). Following corticosteroid injection significantly greater improvements in both shoulder function and pain were observed in patients who had received US-guided injection. This was also accompanied by greater accuracy of needle placement.

Plantar fasciitis; comparison with 'blind' injection

This study randomly divided patients with plantar fasciitis into US-guided (n=12) or the standard palpation-guided (n=13) injection (Tsai, Hsu et al. 2006). Following injection of corticosteroid and local anaesthetic patients were assessed at 2 weeks, 2 months, and 1 year later. Following injection there was significant improvements in both groups for pain, tenderness, as well as reduction in plantar fascia thickness and number of patients with hypoechogenicity. The recurrence rate however was significantly higher in the palpation-guided group (6/13) compared with the US-guided group (1/12) ($p < 0.05$). The authors suggested that US-guided treatment reduced recurrent rate in plantar fasciitis. In contrast another study with similar methodology and patient numbers, but without time-structured follow-up did not show any difference between palpation and US guided injection (Kane, Greaney et al. 2001). Like the study mentioned above, they too demonstrated a reduction in plantar fascia thickness.

4.9 Summary

In this chapter we confirm the accuracy of US-guided subacromial injections in patients with shoulder pain. In our study all our injections were intrabursal with 6/11 having a small extrabursal element as well. We argue that this is likely the result of extravasation in part due to the volume injected.

More work needs to be done to determine the accuracy of injection techniques using dissection and imaging modalities like CT including randomisation to guided or 'blind' injections to provide comparison. Thereafter, the impact of these more accurate injection techniques need to be assessed in randomised longitudinal studies with validated outcome studies.

A larger study incorporating controlled randomisation to a 'blind' injection arm using the same volume of injection would have ruled out any potential bias from this. Despite this the results of this study have important implications for the use of US in guiding diagnostic and therapeutic injections of the subacromial bursa, and provide vital baseline data for future studies to assess the therapeutic impact of guided versus blind injections.

Chapter 5

5.1 Efficacy and Predictive Validity of Guided Hip Injections

5.2 Clinical relevance

Intra-articular corticosteroid injections are commonly used in rheumatology practice to provide symptoms relief. Until recently they have not been commonly used in hip OA, one of the reasons being the technical difficulty in delivering such injections. As a consequence corticosteroid injection is omitted from current treatment guidelines although the same procedure is advised in knee OA.

Ultrasonography, a safe non-invasive procedure may represent a credible alternative to fluoroscopy especially owing to the lack of radiation exposure. It can localise collections of fluid within the joint allowing guided aspiration if infection is a concern, as well as being able to check accuracy of the injection without the use of contrast and ionising radiation, as is the case with fluoroscopy. In addition US is able to detect features of OA such as joint space narrowing and osteophyte formation that may help predict response to therapy.

5.3 Abstract

5.3.1 Aims

In this prospective pilot study the efficacy of US-guided intraarticular corticosteroid hip injections were evaluated. Baseline features were documented to assess predictive validity of response.

5.3.2 Methods

Patients over 18 wait listed for THR were invited to take part in the study, with exclusions. Baseline assessment included X-ray and US of the hip and clinical parameters including VAS scores. Corticosteroid was injected under US-guidance, and clinical assessments were repeated at 2, 6 and 12 weeks.

5.3.3 Results

Eleven patients were recruited with a mean age 63 (53-72), and a mean VAS for pain at baseline 78 mm. Six patients had severe OA changes on x-ray and the remaining 5 had moderate OA. Eight had an effusion on US; 4 each with moderate and severe x-ray OA changes. Five patients had anterior osteophytes on US; 3 with severe and 2 with moderate OA on x-ray. Six (55%) patients described a response at 2 weeks, compared with 4/11 (33%) and 3/8 (38%) at 6 and 12 weeks respectively.

Of the 6 responders at 2 weeks; 2 had severe OA on x-ray but both had US effusion, compared with 4 who had moderate OA (3 with US effusion). At week 6; 3/4 responders had moderate OA on x-ray, all with US effusions, and these 3 continued to benefit up to week 12. All five patients with an effusion but without osteophytes on US, responded at week 2 with 4/5 (80%) and 3/4 (75%) continuing to respond at 6 and 12 weeks respectively. Only 1/5 (20%) patients with osteophytes on US responded at 2 weeks.

5.3.4 Conclusions

In this study severe OA on x-ray and US osteophytes were both (not surprisingly) associated with poor response (20%), whereas those with an effusion but no osteophytes on US had the greatest chance of sustained response (75%), suggesting that this may be a predictor of favourable response.

5.4 Introduction

Osteoarthritis is the commonest cause of total hip joint replacement. The indication for this procedure is pain and loss of function as a result of joint disease that has not responded adequately to conservative therapy. Maintaining good muscle strength and optimising weight is important to good outcome post-surgery. This is difficult when symptoms reduce patients' mobility.

Intra-articular corticosteroid injections are commonly used, for short-term relief of joint symptoms (van Holsbeeck, van Holsbeeck et al. 1988; Blyth, Hunter et al. 1994; Hochberg, Altman et al. 1995; Hochberg, Altman et al. 1995; Newman, Laing et al. 1996; Creamer 1997; Jacob and Sallay 1997; Fredberg, Bolvig et al. 2004), in rheumatology practice to provide relief of symptoms, and are suggest as part of the medical management of knee OA (Hochberg, Altman et al. 1995) but until recently they have not been commonly used in hip OA. A commonly used explanation is the technical difficulty in delivering such injections and concern over accuracy (Hochberg, Altman et al. 1995; ACR subcommittee 2000) because the hip is a deep and difficult to palpate joint, as a result these injections are traditionally given under fluoroscopic control.

As a consequence corticosteroid injection is omitted from current treatment guidelines (Hochberg, Altman et al. 1995). Many patients awaiting total hip replacement (THR) have not had a trial of corticosteroid and the efficacy of these drugs in patients with more severe arthritis requiring hip replacement has not been tested.

Ultrasonography, a safe non-invasive procedure may represent a credible alternative to fluoroscopy especially owing to the lack of radiation exposure. It can

localise collections of fluid within the joint allowing guided aspiration if infection is a concern, as well as being able to check accuracy of the injection without the use of contrast and ionising radiation, as is the case with fluoroscopy. In addition US is able to detect features of OA such as joint space narrowing and osteophyte formation that may help predict response to therapy.

Ultrasonography of the hip is able to accurately detect effusions and synovitis in RA patients (Koski, Anttila et al. 1990), even early in disease (Eberhardt, Fex et al. 1995). It is able to detect and aspirate effusions in patients without symptoms (Koski and Isomaki 1990). In comparison clinical assessment when compared with US has poor sensitivity (Koski 1989; Eberhardt, Fex et al. 1995). Set criteria for the detection of hip effusion have been determined (Koski 1989).

The main aim of this pilot study is to determine whether corticosteroid injections improve pain and function in patients with severe osteoarthritis of the hip, and also to identify any baseline features that predict response.

5.5 Methods

5.5.1 Patients

All information gathered was returned to a database manager, and stored on a stand-alone computer with multiple levels of security and an audit trail.

All patients fulfilling ACR criteria for hip OA (Altman, Alarcon et al. 1991), with ongoing pain and disability despite NSAID and analgesic use awaiting total hip replacement were invited to take part. All received patient information leaflets as well as adequate time and opportunity to discuss the study before giving consent. The local ethics committee approved the study. Patients unwilling or unable to give consent, and those with contraindication to corticosteroid, evidence of generalised inflammatory arthritis, co-existent serious medical illness or malignancy were excluded. Patients who had received corticosteroid in the last 3 months or those with pending THR (within 3 months) were excluded.

5.5.2 Baseline assessment

The baseline assessment included documenting analgesic requirements, hip range of movement (ROM), 100 mm visual analogue scale (VAS) for pain during rest, walking and at night. Patients had x-ray of the affected hip (unless performed within the last year) for conventional assessment of joint damage; scored by a Rheumatologist blinded to US findings as mild, moderate or severe.

5.5.3 Ultrasonography

Ultrasonography was performed using an ATL HDI 3000 (Advanced Technology Laboratories, Bothel Washington, USA) machine, by a rheumatologist (ZK) experienced in US having performed more than 15 hip injections. The patient was positioned supine with the hip extended (leg straight) and slightly externally rotated. A curvi-linear array 5-3 MHz transducer, was placed in an oblique saggital plane anteriorly (see Figure 5.1, Figure 5.2, Figure 5.3) on the patient, and the neck of femur was identified in the longitudinal axis. The degree of osteophytosis and capsule distension was measured measured; $\geq 7\text{mm}$ capsular distension was defined as definite effusion following published validation of US findings with surgery (Koski, Anttila et al. 1990).

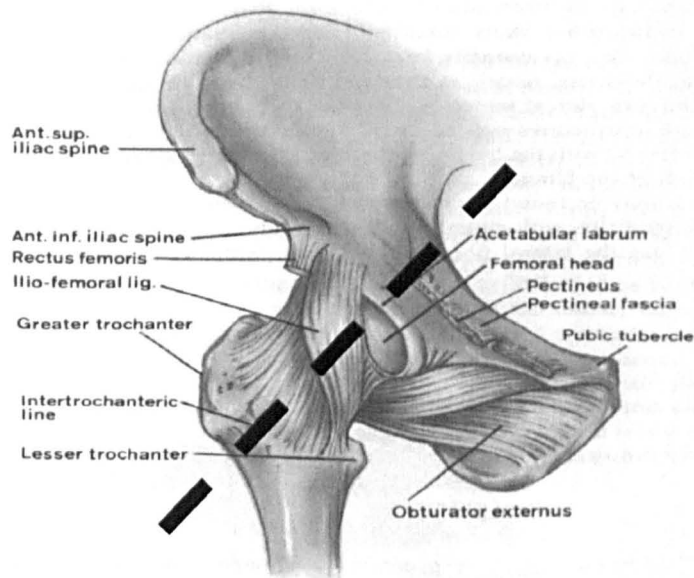


Figure 5.1 US of Hip: Hip anatomy

- - - - = Line of transducer

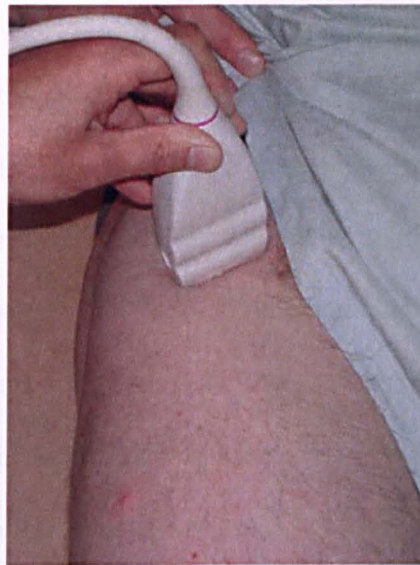

Figure 5.2 US of Hip: Scanning technique

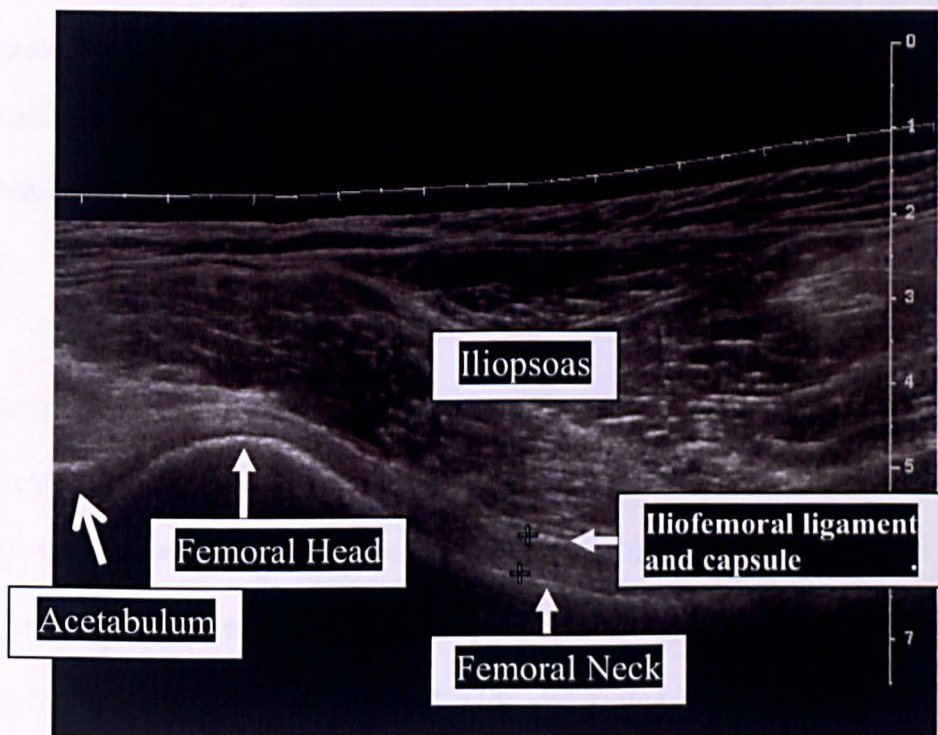


Figure 5.3 US of Hip: US image

A transverse scan was also performed to ensure major vessels were avoided. The injection site was then marked over the neck of femur before the skin was thoroughly cleaned with antiseptic. The needle was inserted perpendicularly through the skin and capsule onto the neck of femur, hence avoiding the risk of needle injury to the cartilage. Forty mg triamcinolone acetonide (1ml) with 20 mg lignocaine hydrochloride (2 ml) was injected into the hip, and follow-up US was performed to check for correct placement of the injection in the joint. Patients were advised to rest the joint for the next 24 hours. A full aseptic technique was used during the injection to reduce the risk of introducing infection.

5.5.4 Repeat assessments

Follow-up visits were performed at 2, 6 and 12 weeks when response to corticosteroid injection was noted and baseline assessments except x-ray and US were repeated.

5.5.5 Outcome measures

Response to the injection, defined as a reduction in VAS pain scores $>15\text{mm}$ (arbitrary cut-off) for walking, was the main outcome. Other outcome measures were number of patients with reduction in VAS pain scores $>15\text{mm}$ at rest and at night, change in WOMAC, increase in hip ROM $>15^\circ$ and analgesic requirements. Baseline findings on X-ray and US were analysed for any features that might predict response. There was no previous data available on which to base any meaningful sample size calculation, and the small numbers in this study precluded any meaningful statistical analysis.

5.6 Results

5.6.1 Baseline assessment

Eleven patients were recruited (7 female), with a mean age 63 (53-72), The mean VAS for pain at baseline was; at rest 69 mm, walking 78 mm, and at night 72 mm. Six patients had severe OA changes on x-ray and the remaining 5 had moderate OA. With US assessment 8 had an effusion; 4 each with moderate and severe OA changes. Five patients had anterior osteophytes on US; 3 with severe OA 2 of whom had an effusion, and 2 with moderate OA one with an effusion. Post-injection all injections were confirmed to be accurately placed by US. Three patients did not complete the week 12 assessment.

5.6.2 Response

Six patients (55%) described a >15 mm reduction in VAS for walking at 2 weeks, compared with 4/11 (33%) and 3/8 (38%) at 6 and 12 weeks respectively. There were also >15mm reductions in VAS for pain at rest (4/11, 3/11, and 2/8 at 2, 6, and 12 weeks respectively), and at night (5/11, 3/11, and 3/8 at 2, 6, and 12 weeks respectively) (Figure 5.4).

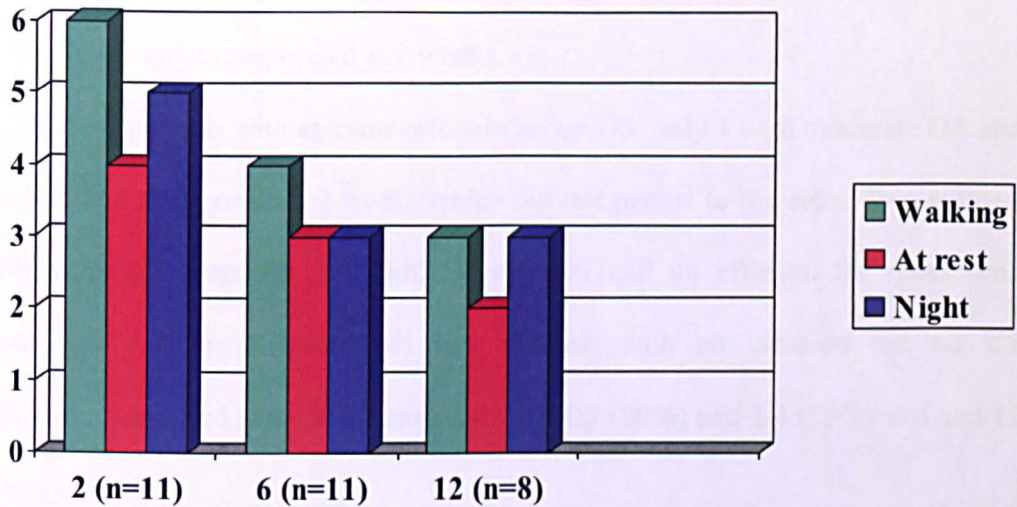


Figure 5.4 Patients with improvement in VAS scores at 2, 6 and 12 weeks

Two (18%) others reported a benefit from the injection at the 2nd week assessment, which did not persist, but did not meet the pre-defined criteria of response (partial response). Four patients described a reduction in analgesic use at two weeks, and 2 of these maintained this through week 6 and 12 assessments. No patient had an improvement in hip range of movement. There were no complications such as joint infection.

5.6.3 Predictors of response

Of the 6 responders (>15 mm reduction in VAS for walking) at 2 weeks; 2 had severe OA on x-ray but both had US effusion, compared with 4 who had moderate OA (3 with US effusion). At week 6; 3/4 responders had moderate OA on x-ray, all with US effusions, and these 3 continued to benefit up to week 12. All five patients with an effusion but without osteophytes on US, responded at week 2 with 4/5 (80%) and 3/4

(75%) continuing to respond at 6 and 12 weeks respectively. Only 1/5 (20%) patients with osteophytes on US responded at 2 weeks.

Of the 5 patients with anterior osteophytes on US; only 1 with moderate OA and no effusion, had a response at 2 weeks which did not persist to 6 weeks. Two patients described a partial response; one with severe OA and no effusion the other with moderate OA and an effusion. All five patients with an effusion but no US osteophytosis responded at week 2 compared with 4/5 (80%) and 3/4 (75%) at 6 and 12 weeks respectively.

When response was compared with x-ray changes, of the 6 patients with severe OA on x-ray; two (33%) and one (17%) patient had a positive response at 2 and 6 weeks respectively (both with an effusion), but not persisting to week 12. No patient with severe OA and US osteophytosis had responded at week 2, although one described a partial response. Four (80%) of patients with moderate OA on x-ray had a positive response at 2 weeks; 3/5 (60%), all with effusions and no US osteophytosis, sustained this through weeks 6 and 12.

5.7 Discussion

In this study of patients with OA hip awaiting THR, response to injection was moderate and short-lived for most. In this study severe OA on x-ray and US osteophytes were both (not surprisingly) associated with poor response (20%), whereas those with an effusion but no osteophytes on US had the greatest chance of sustained response (75%), suggesting that this may be a predictor of favourable response.

Ultrasonography is a safe, non-invasive imaging modality able to assess effusions as well as other features of OA such as joint space narrowing and osteophyte formation; although in the hip access to the joint is limited (mainly anterior). In this study patients were not enrolled and injected at the same time because of ethical considerations, but in standard practice this can be performed during the same outpatient visit reducing the need for a return visit. US has the advantage of being able to check accuracy of the injection during the procedure without the use of contrast or any ionising radiation. It can also localise collections of fluid within the joint allowing guided aspiration if infection is a concern.

This study suggests certain patients waiting THR may benefit from corticosteroid injection. Although the numbers involved in this study were small, it also suggests x-ray and US findings can be used to predict response even in patients with severe disease. A prospective study with larger numbers is required to investigate this further.

5.8 Subsequent literature

In this chapter we covered work regarding the role of US in guiding hip injections and also to predict prognostic groups. Significant additions to the literature are described below.

5.8.1 Validity of hip synovitis; comparison with histology

In this important study PD US findings of synovial tissue vascularity in the hip joint have also recently been compared with histology of the same tissue (Walther, Harms et al. 2002). All involved joints were examined with US prior to THR, and samples of synovial tissue that had been assessed with US were resected and examined by a blinded pathologist for vascularity. Spearman rank correlation tests were used to assess correlation between PD US and findings at histology. Correlation between qualitative PD US and qualitative vascularity grades from histological analysis was 0.92 ($p < 0.01$). The authors concluded that PD US is valid for grading vascularity of the hip. This study, like in their earlier study of the knee (Walther, Harms et al. 2001), provides true gold-standard concurrent validity with PD US compared with histology to detect synovitis.

5.8.2 US injection with air ‘contrast’

Two studies described in the previous chapter have recently described the technique of adding air to the injection to provide echo contrast which is easily detected with US (Qvistgaard, Kristoffersen et al. 2001; Koski, Saarakkala et al. 2005), including one which specifically assessed the hip (Qvistgaard, Kristoffersen et al.

2001). The authors suggest this simple technique should be used with US to avoid using contrast and x-ray to confirm placement.

5.8.3 Efficacy in hip OA

In a study of 510 patients Margules and colleagues performed fluoroscopic guided injections of corticosteroid into the hip and assessed response 8 weeks later (Margules 2001). Twenty-one out of 234 (9%) of patients with severe hip OA had benefit of pain at 8 weeks compared with 131/226 ((58%) with moderate OA. There was improvement ($>10^\circ$) in range of movement (internal rotation) in 108/226 (48%) hips with moderate OA, but no patient with severe OA described improvement. They concluded that corticosteroid injection in OA had potential benefit and required further investigation.

A later study in 28 patients with rapidly destructive hip OA assessed whether fluoroscopic guided corticosteroid followed by non-weight bearing (4-6 weeks) reduced the need for THR (Villoutreix, Pham et al. 2006). Twenty-seven out of twenty-eight patients required THR (including 20 within one year of injection), and the authors concluded that this was not an effective management for rapidly destructive hip OA.

5.9 Summary

In this chapter we confirm that patients with at least moderate hip OA can benefit in the medium-term from US-guided injection (indirect guidance) of corticosteroid. This study suggests that findings at US, particularly effusion and lack of osteophytes, may predict those likely to respond. In an important study synovitis as defined by PD US (we used gray-scale only) correlates well with histology (Walther, Harms et al. 2002). In our study we guided and confirmed placement of injection with US, and there is also evidence that us-guided hip injections are accurate from a study using contrast with CT to confirm 100% placement (Pourbagher, Ozalay et al. 2005).

The study by Margules and colleagues have found better outcomes in a larger group of patients (Margules 2001), but their group while including patients with moderate and severe arthritis probably had less severe disease than our group who were all waiting hip replacement. It seems however, that there is no role for corticosteroid injections at the other end of the severity spectrum, with no benefit in rapidly destructive hip OA (Villoutreix, Pham et al. 2006).

Future work should include a placebo-controlled randomised study of guided injection to remove 'placebo' response, and also include features that might predict response. The data from our pilot study provide valuable baseline data for power calculations for future studies.

LEEDS HIP US-GUIDED INJECTION STUDY

WEEK 0- DEMOGRAPHIC DATA

Patient id code: _____

<p>Please affix patient label here</p>

Weight _____ kg

Height _____ cm

ESR _____

PV _____

CRP _____

RF titre _____

ANA _____

Urate _____

Ultrasound findings

Study hip

Right

Left

(please circle)

Joint space narrowing

0123

Osteophytes

0123

Capsular distention

0123

_____ mm

Radiographic damage

(please circle)

Mild

Moderate

Severe

LEEDS HIP US-GUIDED INJECTION STUDY

WEEK 0

Patient id code: _____

Date: __/__/__

Pain relieving medication

1. _____

2. _____

Study hip

Right

Left

(please circle)

1. With respect to your painful hip, how much pain do you have during the day, at rest?

No pain

_____mm

Pain as severe
as it could be

2. With respect to your painful hip, how much pain do you have during the day, when walking?

No pain

_____mm

Pain as severe
as it could be

3. With respect to your painful hip, how much pain do you have during the night?

No pain

_____mm

Pain as severe
as it could be

LEEDS HIP US-GUIDED INJECTION STUDY

WEEK 2

Patient id code: _____

Date: __/__/__

Pain relieving medication

1. _____

2. _____

Do you think the injection has helped Yes No

Study hip Right Left (please circle)

1. With respect to your painful hip, how much pain do you have during the day, at rest?

No pain _____ mm Pain as severe
as it could be

2. With respect to your painful hip, how much pain do you have during the day, when walking?

No pain _____ mm Pain as severe
as it could be

3. With respect to your painful hip, how much pain do you have during the night?

No pain _____ mm Pain as severe
as it could be

4. How do you think the injection has helped overall? (please circle)

-1 0 1 2 3

Worse No different Mild Moderate Marked

LEEDS HIP US-GUIDED INJECTION STUDY

WEEK 6 12

Patient id code: _____

Date: __/__/__

Pain relieving medication

1. _____

2. _____

Do you think the injection is still helping Yes No

Study hip

Right

Left

(please circle)

1. With respect to your painful hip, how much pain do you have during the day, at rest?

No pain

_____ mm

Pain as severe
as it could be

2. With respect to your painful hip, how much pain do you have during the day, when walking?

No pain

_____ mm

Pain as severe
as it could be

3. With respect to your painful hip, how much pain do you have during the night?

No pain

_____ mm

Pain as severe
as it could be

4. How do you think the injection has helped overall? (please circle)

-1

0

1

2

3

Worse

No different

Mild

Moderate

Marked

Chapter 6

6.1 Clinical Utility: Synovitis in clinical remission

6.2 Clinical relevance

Early, aggressive therapy and more effective DMARDs have contributed to increasing rates of clinical remission in RA. Despite this, progression of disease with structural damage may still occur, suggesting ongoing disease activity and questioning the validity of current methods of remission assessment. Ultrasonography is more sensitive than clinical assessment at detecting synovitis, and in this study we tested the hypothesis that US-detected synovitis is present in clinical states of remission.

6.3 Abstract

6.3.1 Aims

More timely and effective RA therapy has contributed to increasing rates of clinical remission. However, progression of structural damage may still occur despite patients satisfying clinical assessment based remission criteria, suggesting ongoing disease activity and questioning the validity of current methods of remission assessment. We tested the hypothesis that US-detected synovitis is present in clinical states of remission.

6.3.2 Methods

107 RA patients on DMARD therapy, judged to be in remission by their consultant rheumatologist were studied. Patients underwent clinical, laboratory, functional and quality of life assessments. DAS28 and ACR remission criteria together with strict clinical definitions of remission were applied. Ultrasonography of the hand and wrist was performed using standardised acquisition and scoring techniques. In a cohort of patients inter- and intra-observer reliability of US was assessed.

6.3.3 Results

Irrespective of which clinical criteria were applied to determine remission, the majority of patients continued to have evidence of active inflammation using an imaging assessment. Even in asymptomatic patients with clinically normal joints, 73% had grey-scale synovial hypertrophy and 43% increased power Doppler signal on US. Inter- and intra-observer reliability to detect synovitis was 0.60 for both, and intra-observer reliability for PD was 0.62.

6.3.4 Conclusions

Ultrasonography detected synovitis in most RA patients satisfying remission criteria with normal clinical and laboratory findings. This sub-clinical synovitis may explain the observed discrepancy between disease activity and outcome. Ultrasonography is reliable for detecting synovitis in low disease activity states, and may be necessary for accurate evaluation of disease state and confirmation of '*true remission*'.

6.4 Introduction

The treatment of rheumatoid arthritis (RA) is directed at suppressing inflammation with the aim of eliminating synovitis and establishing a state of remission (Emery and Salmon 1995). Remission is regarded as the ideal therapeutic target for patients with RA, as further joint damage and disability should be prevented and function and quality of life maintained. Rates of remission are increasing with modern therapeutic strategies and more effective drug treatments (Boers, Verhoeven et al. 1997; Mottonen, Hannonen et al. 2002; Klareskog, van der Heijde et al. 2004; Korpela, Laasonen et al. 2004). It is therefore important to ensure that our methods of disease activity assessment are accurate in order that correct management decisions can be made for the most favourable patient outcome.

Current methods used to evaluate remission in RA largely rely on composite scores based on clinical and laboratory assessment and include the ACR Remission Criteria (Pinals, Baum et al. 1982) and Disease Activity Score (DAS) (van der Heijde, van 't Hof et al. 1990; Prevoo, van 't Hof et al. 1995; Prevoo, van Gestel et al. 1996). Such measures have the disadvantage of not directly measuring inflammation at the primary site of pathology (Lee, Lee et al. 1997) and may be subject to confounding influences (Balsa, Carmona et al. 2004; Paulus 2004). In addition, reports suggest a disparity between clinical state and outcome with evidence of progression of joint damage despite apparent remission (Mulherin, Fitzgerald et al. 1996; Molenaar, Voskuyl et al. 2004). This has been interpreted as evidence of a dissociation between synovitis and subsequent erosive joint damage (Kirwan 2004) but could reflect the inadequate sensitivity of the traditional clinical approaches to detection of synovitis.

Ultrasonography is capable of directly visualising and objectively quantifying synovial inflammation. There are increasing data to support US validity as a disease assessment tool as well as its superior sensitivity compared to clinical assessment at detecting inflammation (Backhaus, Kamradt et al. 1999; Szkudlarek, Court-Payen et al. 2001; Walther, Harms et al. 2001; Backhaus, Burmester et al. 2002; Grassi 2003; Karim, Wakefield et al. 2004; Wakefield, Brown et al. 2004).

There have also been two studies with controls assessing any increase in sensitivity using US enhanced with micro-bubble contrast agent (Levovist in both). In the first study with 46 RA patients (Klauser, Frauscher et al. 2002), CD US was positive in 7 (8%) of 83 inactive joints, in 31 (52%) of 60 moderately active joints, and in 32 (58%) of 55 active joints. Following infusion of Levovist CD was positive in 41 (49%) of 83 joints with inactive RA, in 59 (98%) of 60 joints with moderately active RA, and in all 55 joints with active RA, confirming significant improvement in detection of vascularisation following Levovist. A smaller study of 15 patients and 3 controls (1 MCP each) however, whilst noting increased signal in 7/9 joints with pre-contrast flow-signal did not detect signal to the 9 joints previously without signal following contrast (Szkudlarek, Court-Payen et al. 2003). In this study, unlike the first there was also no correlation between clinical assessment and Levovist enhanced PD US. In both studies healthy joints did not demonstrate vascularisation before or after contrast.

In a recent study of 200 MTP joints in 40 patients with RA with 100 healthy controls, US was compared with MRI and clinical examination for the detection of joint inflammation with MRI being regarded as the gold standard (Szkudlarek, Narvestad et al. 2004). The sensitivity, specificity, and accuracy of US for the detection of synovitis were 0.87, 0.74, and 0.79 respectively, while for clinical examination; the

corresponding values were 0.43, 0.89, and 0.71 respectively. Another study confirmed a highly significant association between spectral Doppler resistive index and post contrast MRI in 29 RA patients (Terslev, Torp-Pedersen et al. 2003). In this study there were also significant differences in the groups with joint swelling compared to other groups using CD US. The authors concluded that CD US was comparable with post contrast MRI and estimation as in this study using colour fraction and the resistance index obtained with CD US was a promising method for the detection of synovitis in patients with RA.

Levels of MRI (Ostergaard, Hansen et al. 1999; Huang, Stewart et al. 2000; Conaghan, O'Connor et al. 2003; McQueen, Benton et al. 2003) and US-detected synovitis (Taylor, Steuer et al. 2004) have also been shown to correlate with subsequent bone damage and functional outcomes. This suggests imaging modalities offer the potential to provide a more accurate measure of disease activity than the established clinical methods, and may be particularly useful in states where levels of inflammation may be low and assessment may be more challenging. The aim of this study was to assess the degree of US-detected synovitis in patients in clinical remission.

6.5 Methods

6.5.1 Patients

In this prospective controlled cohort study, 107 patients attending rheumatology outpatient clinics at Leeds General Infirmary were studied. Ethical approval for the project was obtained from the Leeds Teaching Hospitals NHS Trust Ethics Committee. Written informed consent was obtained from all subjects prior to inclusion.

6.5.2 Inclusion criteria

Using their clinical judgment, consultant rheumatologists identified patients from their outpatient clinics who they believed to be in remission (*'physician remission'*) using whatever assessments they thought necessary. In addition, all patients satisfied the following criteria: (1) RA classified according to ARA criteria (Arnett, Edworthy et al. 1988); (2) Over 18 years of age; (3) At least 12 months disease duration; (4) No disease flare within preceding 6 months; (5) Stable treatment for 6 months; (6) No clinical indication to change treatment.

6.5.3 Definitions of remission

Three definitions of remission have been applied in this study and used in the analysis:

1) *'Physician remission'*: RA deemed to be in remission in the clinical judgment of the consultant rheumatologist, using whatever assessments they consider necessary. This reflects stable, controlled disease, requiring no change in therapy (see inclusion criteria);

- 2) '*Established remission criteria*': subjects satisfying the ACR (Pinals, Baum et al. 1982) or DAS28 remission criteria (van der Heijde, van 't Hof et al. 1990; Prevoo, van 't Hof et al. 1995; Prevoo, van Gestel et al. 1996);
- 3) '*Complete clinical remission*': asymptomatic patients with no objective examination findings of disease activity, indicated by the absence of painful, tender or swollen joints on formal metrology.

6.5.4 Study assessments

Patients had their ACR Remission status (Pinals, Baum et al. 1982) determined at -2 and 0 months (baseline). Inclusion criteria were applied at both these time points by their consultant rheumatologist. At baseline, they underwent full clinical, laboratory, functional, quality of life and imaging assessments.

6.5.5 Demographic and clinical characteristics

The following demographic and clinical characteristics were recorded at baseline: age, sex, ethnicity, marital status, presenting history of RA, presence of RF, extra-articular RA features, current and previous DMARD's and other therapies, duration of current remission, other medical and occupational history. Clinical data included duration of morning stiffness; Likert and VAS for fatigue, joint pain, observer assessment of disease activity and VAS for the patient's global impression of health and disease activity; number of painful, tender and swollen joints as assessed by an independent, trained metrologist. Health Assessment Questionnaire (Fries, Spitz et al. 1980) and quality of life (RAQoL) (de Jong, van der Heijde et al. 1997; Whalley, McKenna et al. 1997) questionnaires were completed and corresponding scores

calculated. Remission and disease activity scores were calculated using the ACR Remission Criteria (Pinals, Baum et al. 1982) and DAS28 (Prevoo, van 't Hof et al. 1995).

6.5.6 Laboratory assessment

Full blood count, ESR, PV, CRP and RF were measured at baseline. Human leucocyte antigen typing was performed to assess presence of RA susceptibility alleles (shared epitope).

6.5.7 Radiographic assessment

Standard posterior-anterior x-rays of the hands, wrists and feet were obtained. Radiographic damage was scored using the Genant scoring method (Genant, Jiang et al. 1998; Jiang, Genant et al. 2000) by a single experienced reader, who was blinded to all other imaging and clinical findings.

6.5.8 Ultrasonography

Each patient received an US assessment of the dominant hand and wrist joints using gray-scale and PD. Eight joint regions were imaged with US: the 2nd-5th MCP and RC, UC, IC, and DRU joints of the wrist. Ultrasonography was performed by a single experienced operator (ZK), blinded to all other study findings, using an ATL HDI 3000 machine with a 10-5 MHz linear array 'hockey-stick' transducer, according to EULAR guidelines (Backhaus, Burmester et al. 2001). The presence and location of any synovial hypertrophy and tenosynovitis was recorded with reference to the OMERACT/EULAR pathology definitions (Wakefield, Balint et al. 2005).

Synovial hypertrophy was graded in gray-scale using a 0-3 semi-quantitative scoring method (the Leeds Score) (Karim, Brown et al. 2004; Wakefield, Green et al. 2004) (0:no synovial hypertrophy; 1:mild; 2:moderate; 3:severe) (Figures 6.1-6.7; examples of grading system) and the maximal area of enhancement on PD was recorded using a previously described semi-quantitative technique (Newman, Laing et al. 1996) (0:normal/minimal vascularity; 1:mild hyperaemia; 2:moderate; 3:marked) (Figures 6.8, 6.9; examples of grading system)). Tenosynovitis was recorded as either present or absent.

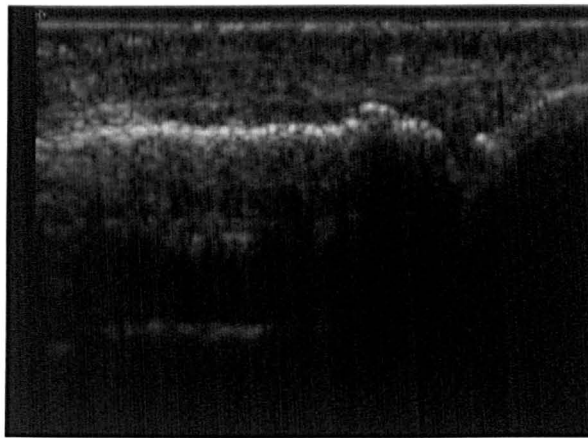


Figure 6.1 US of MCP: No synovitis

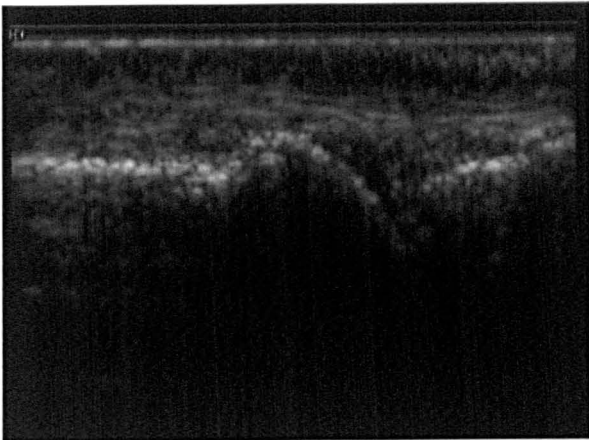


Figure 6.2 US of MCP: Mild synovitis

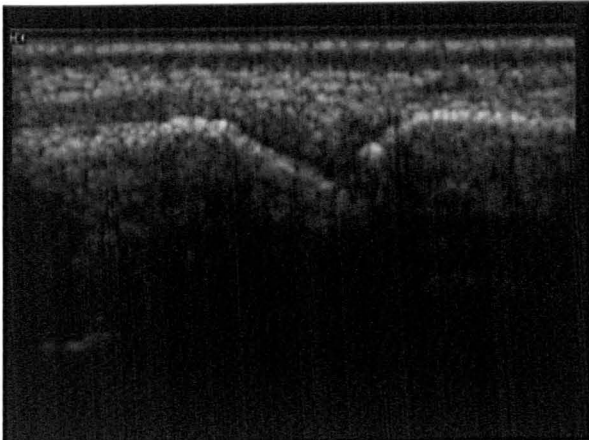


Figure 6.3 US of MCP: Mild synovitis

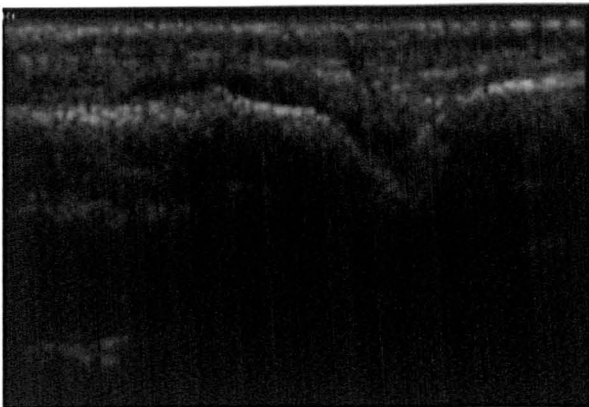


Figure 6.4 US of MCP: Moderate synovitis

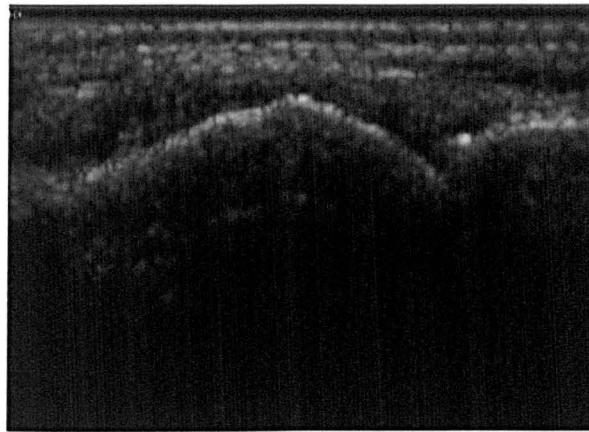


Figure 6.5 US of MCP: Moderate synovitis

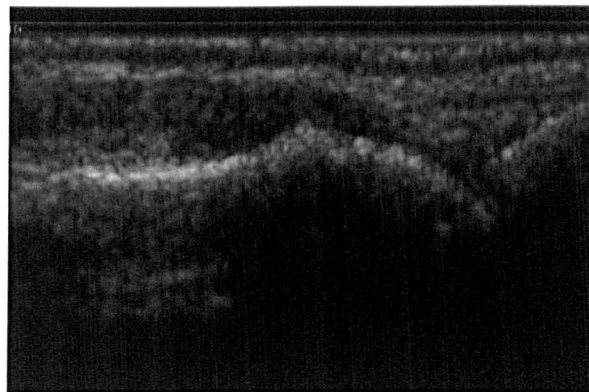


Figure 6.6 US of MCP: Severe synovitis

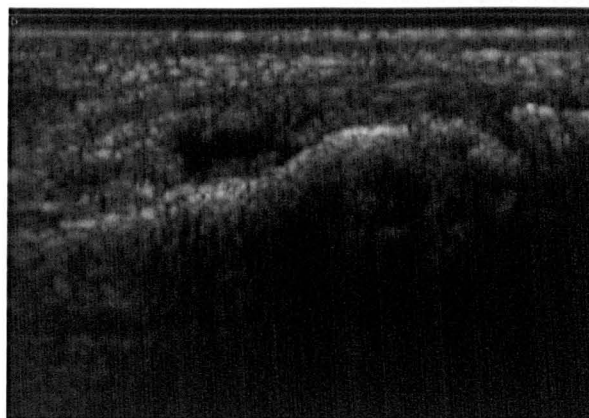


Figure 6.7 US of MCP: Severe synovitis

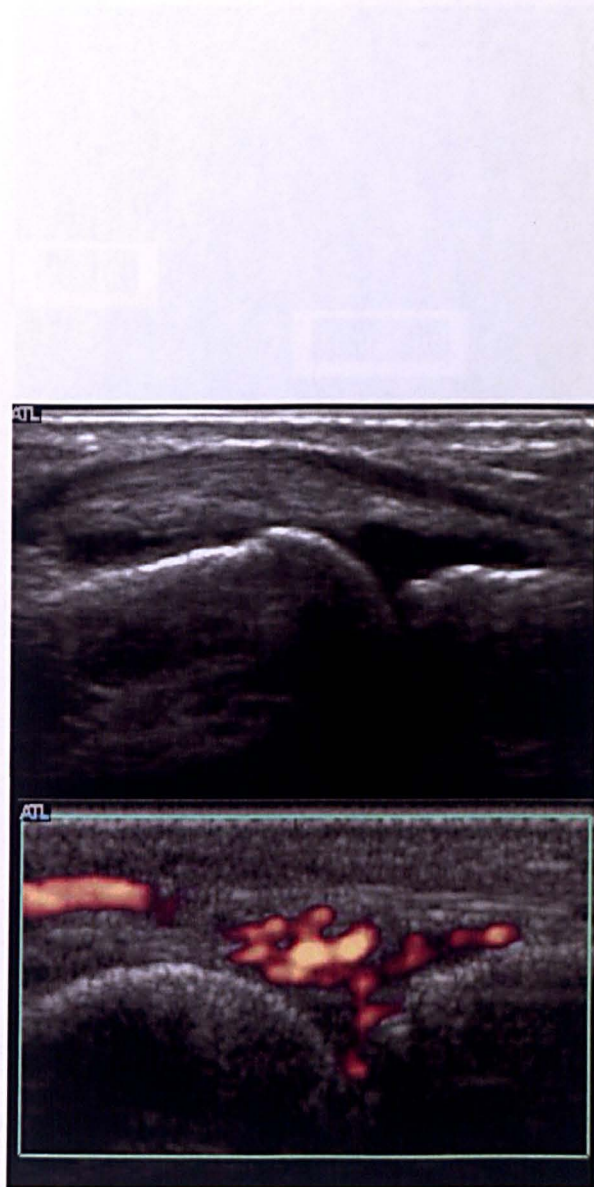


Figure 6.8 US of MCP: Gray scale with corresponding Power Doppler

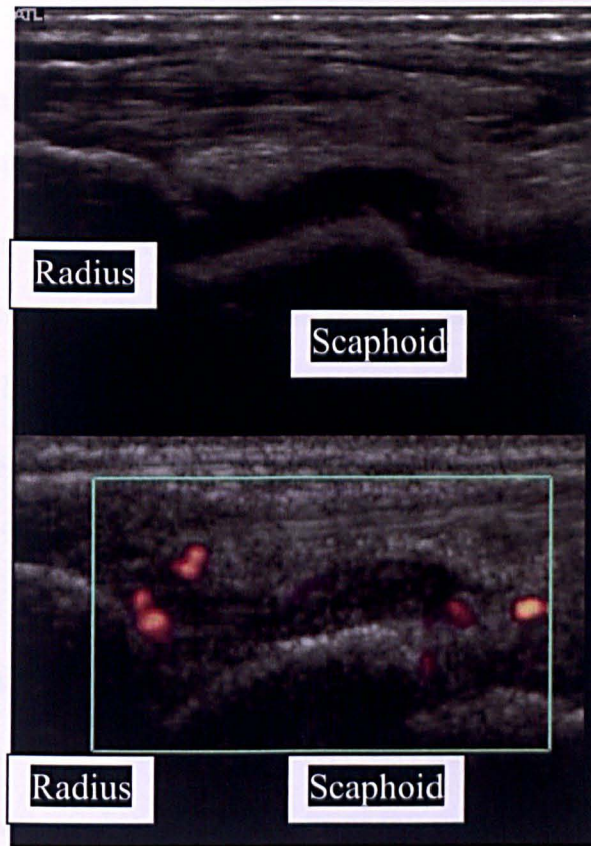


Figure 6.9 US of wrist: Gray scale with corresponding Power Doppler

Each patient assessment took approximately 30 minutes and representative images were archived. Inter-observer reliability was determined by a second experienced rheumatologist ultrasonographer (RJW) performing US assessments of 120 joint regions in a random subset of 15 patients, and comparing the findings of the two rheumatologists. Each examiner performed their US assessment independently and sequentially, blinded to all other study data. Intra-observer reliability was assessed by blinded re-scoring of the archived US images in the same subset, approximately 12 months after the original US assessment.

6.5.9 Analysis

Data evaluation and statistical analysis was carried out using SPSS Version 11.5. Normally distributed continuous data were analysed using parametric tests (independent t-test, ANOVA) and were summarised with means and standard deviations. Non-normally distributed and ordinal data were analysed using non-parametric tests (Mann-Whitney U, Kruskal-Wallis) and were summarised with medians and ranges. Categorical data were analysed using Chi-squared tests. The Holm correction (Holm 1979) was used to correct for multiple comparisons on a family-wise basis. Critical P for testing at the 5% level of significance was set at $P=0.003$ for Chi-squared, Mann-Whitney U and Kruskal-Wallis tests, and at 0.005 for independent t-tests and ANOVAs. Inter and intra-observer agreement was calculated by overall agreement (percentage of observed exact agreement), intraclass correlation coefficients (ICC) and kappa statistics (un-weighted for dichotomous scoring e.g. presence/absence of synovitis; weighted for semi-quantitative scoring).

6.6 Results

6.6.1 Patient demographics

One-hundred and seven patients satisfied the *physician remission* inclusion criteria. All provided written consent prior to taking part in the study. The study population was predominantly female (66%) with a mean age of 56 years. The control group comprised 71% females with a mean age of 38 years. Sixty four percent of patients were RF positive and 61% were shared epitope positive. The mean disease duration was 7 years and median period of remission was almost 2 years. Eighty-one percent had evidence of radiographic erosions in the hands or feet. Ninety-nine percent of the study subjects had received DMARD therapy during the course of their disease and the majority had received more than one drug. Ninety-two percent of the cohort were currently taking DMARD therapy, with oral methotrexate and sulphasalazine being the most commonly used medications; 24% were taking combination therapies; 5 patients were currently receiving biologic drugs either as mono or combination therapy and 4 patients had previously received biologic therapy. Forty percent were currently receiving an NSAID prescription and 2% were taking oral prednisolone (≤ 5 mg). (Table 6.1)

<i>Age (mean, range)</i>		56 years (23-81)	
<i>Sex</i>		66% female, 34% male	
<i>Duration of RA (median, range)</i>		7 years (2-38)	
<i>Rheumatoid factor +ve (>40iu) (mean titre)</i>		64% (249)	
<i>Shared epitope positive</i>		61%	
<i> homozygote</i>		15%	
<i> heterozygote</i>		46%	
<i>Duration of remission [median (range)]</i>		22 months (6-144)	
<i>Radiographic erosions in hands and/or feet</i>		81%	
<i>Radiographic scoring</i> <i>[median (range)]</i> <i>(total n=94)</i>	<i>Hands/wrists</i>	% patients with erosions	69%
		Erosion score	4 (0 – 51)
		JSN score	2 (0 – 39)
		Total score	6.5 (0 – 90)
	<i>Feet</i>	% patients with erosions	65%
		Erosion score	2 (0 – 24)
		JSN score	1 (0 – 32)
		Total score	2.25 (0 – 48)
<i>Current DMARD therapy</i> (median 1; range 0-3)		0	8%
		1	68%
		2	18%
		3	6%
<i>Previous DMARD therapy</i> (median 1; range 0-4)		0	46%
		1	32%
		2	13%
		3	8%
		4	2%
<i>Current NSAID</i>		40%	
<i>Current oral steroid</i>		2% (all ≤5mg)	

Table 6.1 Demographics of RA cohort

6.6.2 Clinical, laboratory, function and quality of life assessments

Clinical and laboratory measures of disease activity were all low, as measured by Likert scale and VAS, duration of early morning stiffness, formal joint counts and acute phase markers (Table 6.2). The group had generally low levels of functional impairment and disability as assessed by HAQ and only mild quality of life impairment as measured by RAQoL.

	Likert scale [%]				VAS (0-100) [median (range)]
	<i>Nil</i>	<i>Mild</i>	<i>Moderate</i>	<i>Severe</i>	
Fatigue	89	3	7	1	20 (0-81)
Joint pain	79	15	6	0	14 (0-81)
Patient global assessment	n/a	n/a	n/a	n/a	14 (0-71)
Physician's global assessment	38	62	0	0	10 (0-30)
Early morning stiffness [median (range)]					0 minutes (0-120)
Painful joint count (/80) [median (range)]					0 (0-22)
Tender joint count (/28) [median (range)]					0 (0-15)
Swollen joint count (/28) [median (range)]					1 (0-13)
PV [mean, standard deviation]					1.64 (0.09)
ESR (mm/hr) [median (range)]					10 (1-57)
CRP (mg/L) [median (range)]					5 (0-30)
Function	HAQ Disability score (0-3) [median (range)]				0.38 (0-2.5)
Quality of life	RAQoL (0-30) [median (range)]				3 (0-23)
ACR Remission	Yes				59 (55%)
	No				48 (45%)
DAS28	Remission (<i>score <2.6</i>)				61 (57%)
	Low disease activity (<i>score >2.6 & <3.2</i>)				21 (20%)
	Moderate disease activity (<i>score >3.2 & <5.1</i>)				24 (22%)
	High disease activity (<i>score >5.1</i>)				1 (1%)

Table 6.2 Clinical laboratory, function and quality of life assessments

6.6.3 Established remission criteria assessment

Of the 107 patients in *physician remission*, 55% fulfilled the ACR remission criteria and 57% satisfied DAS28 remission (DAS28 score <2.6) (Table 6.2). The mean DAS28 score was 2.5 (SD 0.96; range 0.64-5.42).

6.6.4 Ultrasonography

Ninety patients (85%) had evidence of synovial hypertrophy with gray-scale and 60% had increased PD signal, confirming active synovitis. In all patients, 843 joint regions in the hand and wrist were examined with US. Eighty-six percent (725) of these joints had no clinical synovitis (SJC=0) on clinical assessment. Of these, 36% (263) had synovial hypertrophy detected with US, despite normal clinical findings. Of the 354 joints with US synovial hypertrophy, 82% (291) were graded as mild, 16% (57) moderate and 2% (6) severe using the Leeds score. Increased PD signal was demonstrated in one third of these joints. Tenosynovitis was uncommon but was more likely to be detected at the wrist (Table 6.3).

The reliability of US imaging was calculated. For inter-observer reliability exact agreement was found in 91% for presence/absence of synovial hypertrophy and 92% for PD signal, with a kappa 0.60 for presence/absence of synovial hypertrophy. Using the semi-quantitative grading system, exact agreement was found in 38% for synovial hypertrophy and 92% for PD, with a weighted kappa of 0.53 and ICC of 0.57 for synovial hypertrophy. For intra-observer reliability exact agreement was found in 82% for presence/absence of synovial hypertrophy and 90% for PD signal, with a kappa 0.60 for presence/absence of synovial hypertrophy and 0.62 for PD. Using the semi-

quantitative grading system, exact agreement was 66% and 60%, with a weighted kappa of 0.55 and 0.59, ICC 0.54 and 0.38 for synovial hypertrophy and PD respectively.

Number of patients with US pathology				
Gray-scale synovitis [number (%)]		90 (84.9%)		
Increased PD signal [number (%)]		64 (60.4%)		
Tenosynovitis [number (%)]		40 (37.7%)		
Frequency (%) of US pathology (per patient, per joint)				
	MCP2	MCP3	MCP4	MCP5
Synovitis	67.9	64.2	44.3	33.0
Power Doppler	13.2	14.2	3.8	1.9
US	RCJ	UCJ	DRU	Inter-Carpal
Synovitis	38.1	39.0	18.3	30.5
Power Doppler	34.3	18.1	5.8	18.1

Table 6.3 US findings in ‘remission’

6.6.5 Established remission criteria vs. imaging measures of disease activity

Eighty-one percent and 55% of patients in ACR remission had US synovitis and PD signal respectively, compared with 84% and 51% of patients in DAS28 remission. Patients not satisfying ACR or DAS28 remission criteria were more likely to have a significantly greater number of joints with US-detected synovial hypertrophy; 90% patients not in ACR remission compared with 81% in remission, and 100% patients in DAS 28 remission compared with 84% in remission.

6.6.6 Complete clinical remission vs. US synovitis

Despite a total absence of joint symptoms and signs, 73% of patients in *complete clinical remission* had US synovitis with associated PD flow in 43% (Table 6.4).

Variable	Zero P/T/S joints	>Zero P/T/S joints	P-value
N (% of total patients)	31 (29.0)	76 (71.0)	n/a
Early morning stiffness (minutes) [median (range)]	0 (0 – 60)	0 (0 – 120)	MWU 0.032
Joint pain: [n,%]			Chi 0.059
nil	26 (83.9)	70 (92.1)	
mild	2 (6.5)	1 (1.3)	
moderate	2 (6.5)	5 (6.6)	
severe	1 (3.2)	0 (0)	
VAS (mm) [median (range)]			
Fatigue	22.0 (0 – 66)	20.0 (0 – 81)	MWU 0.706
Joint pain	11.0 (0 – 28)	18.0 (0 – 81)	MWU 0.012
Patient global disease activity	12.0 (0 – 47)	16.5 (0 – 71)	MWU 0.052
Physician global disease activity	8.0 (0 – 22)	11 (0 – 30)	MWU 0.010
Physician's global assessment:			Chi 0.007*
Asymptomatic	18 (58.1)	23 (30.3)	
Mild	13 (41.9)	53 (69.7)	
Joint counts – median (range):			
Painful	0 (0 – 0)	0 (0 – 22)	MWU <0.001
Swollen	0 (0 – 0)	2 (0 – 13)	MWU <0.001
Tender	0 (0 – 0)	1 (0 – 15)	MWU <0.001
HAQ disability score [median (range)]	0.25 (0 – 2.5)	0.44(0– 2.25)	MWU 0.062
RAQoL [median (range)]	3 (0 – 17)	3 (0 – 23)	MWU 0.288
CRP ^a (mg/L) [median (range)]	0 (0 – 15)	5 (0 – 23)	MWU 0.515
ESR ^b (mm/hr) [median (range)]	9 (2 – 34)	9.5 (2 – 52)	MWU 0.514
PV ^c [mean (standard deviation)]	1.60 (0.07)	1.63 (0.10)	T 0.068
ACR remission criteria met	29 (93.5)	30 (39.5)	Chi <0.001
DAS28 disease activity category			Chi <0.001
Remission	29 (93.5)	30 (39.5)	
Low disease activity	2 (6.5)	19 (25.0)	
Moderate disease activity	0 (0)	24 (31.6)	
High disease activity	0 (0)	0 (0)	
Total number of patients with synovitis ^d	22 (73.3)	68 (89.5)	Chi 0.037
Total number of joints with synovitis			MWU <0.001
MCPs [median (range)]	1 (0 – 4)	3 (0 – 4)	
Wrist	0 (0 – 3)	1 (0 – 4)	
Total	2 (0 – 6)	4 (0 – 8)	
Total number of patients with increased PD signal ^d	13 (43.3)	50 (65.8)	Chi 0.210
Total number of patients with tenosynovitis ^d	7 (23.3)	33 (43.4)	Chi 0.055

Bold signifies a statistically significant difference. * Trends towards a difference, which following correction for multiple comparisons were not significant. ^a N = 31/74, ^b N = 30/76, ^c N = 25/66, ^d N = 3

Table 6.4 Complete clinical remission (i.e. zero painful/tender/swollen joints) vs. clinical, laboratory and imaging measures of disease activity of RA cohort

6.7 Discussion

One hundred and seven RA patients were identified as being in a state of remission based on clinical assessment by their consultant rheumatologist (*physician remission*). Such an assessment accurately reflects the pragmatic clinical judgments that are made every day in routine rheumatology practice. Objectively, all of these patients had clinical and laboratory measures which confirmed low levels of inflammation. Applying the *established remission criteria*, the cohort was divided into two roughly equal sets of ACR and DAS28 remission and non-remission. In addition, employing our definition of *complete clinical remission*, one third of the patients had a total absence of painful, swollen or tender joints. However, when disease activity was assessed using US, the majority of patients had ongoing active synovitis, irrespective of which criteria were used to define remission. Furthermore, there were no significant differences in the number of patients with US synovitis and their remission status determined by either ACR or DAS28 classification or joint count metrology. These observations provide evidence that current methods of remission assessment including DAS and ACR remission criteria do not necessarily correlate with an absence of disease so may be inaccurate measures of true RA remission.

The findings from this study may have a number of important pathophysiological implications. These data provide a possible pathological explanation for the paradoxical observation that patients in apparent remission may experience progression of joint damage (Mulherin, Fitzgerald et al. 1996; Molenaar, Voskuyl et al. 2004). The primacy of synovitis in RA and a direct link between inflammation and structural damage has been established using MRI (McGonagle, Conaghan et al. 1999;

Conaghan, O'Connor et al. 2003), and it is recognized that even relatively small amounts of MRI synovitis or bone oedema may cause new erosions (Ostergaard, Hansen et al. 1999; Huang, Stewart et al. 2000; McQueen, Benton et al. 2003) and that bone damage is unlikely to occur in the absence of inflammation (Conaghan, O'Connor et al. 2003). A recent study has also demonstrated that US synovitis correlates to x-ray damage 1 year on (Taylor, Steuer et al. 2004) in patients with RA. Given this evidence, one may predict that the synovitis identified in this cohort may result in subsequent structural damage. Therefore, the persistence of active synovitis may be the explanation for adverse outcome despite patients achieving ACR and DAS28 remission.

Ultrasonography was used to assess the degree of sub-clinical disease in this large cohort of RA patients in clinical remission and identified ongoing synovitis. The advantage of US over clinical assessment has again been demonstrated, with approximately a third of clinically normal joints having synovial hypertrophy on US. Ninety-two percent of patients in this cohort were receiving DMARD therapy, almost exclusively traditional non-biologic drugs. It may be that such therapies are not sufficiently potent to completely suppress inflammation, and that US imaging is required to assess these patients to decide whether increase in DMARD therapy is required. The reliability of US has again been demonstrated, consistent with published data (Backhaus, Kamradt et al. 1999; Qvistgaard, Rogind et al. 2001; Ribbens, Andre et al. 2003; Szkudlarek, Court-Payen et al. 2003) in patients with higher levels of synovitis.

This study confirms the hypothesis that the majority of patients achieving ACR and DAS28 remission status as well as asymptomatic patients with no objective signs on joint assessment have sub-clinical synovitis when assessed with US. Therefore, it appears that such clinical remission criteria may not select patients with an absence of inflammation and as such may be inaccurate measures of true remission. This observation may explain the apparent discrepancy between clinical improvement and progression of joint damage in some patients with RA and could be important in determining therapeutic decisions such as how far to pursue disease suppression.

Ultrasonography is a sensitive measure of joint inflammation and may provide a more accurate assessment of remission. Modification of the current RA remission criteria may be required in light of these findings in order to optimize disease activity assessment and facilitate the most favourable outcome for our patients. These data support the use of US for accurate assessment of disease state even when clinical measures of response have normalised, and suggests that true remission should be defined with an imaging (in this case US) based assessment.

6.8 Subsequent literature

The work from this chapter has only just been completed and there are no relevant additional publications to my knowledge.

6.9 Summary

In this chapter we continue the theme of this thesis assessing the role of US in patients with clinical remission. This study again reveals the insensitivity of clinical assessment and also the degree of sub-clinical disease present even in this group with apparently low disease activity, demonstrating widespread synovitis regardless of the type of remission criteria imposed. This suggests that US because of its validity, and easy use should be included in any future definition of remission. The reliability of US in low grade synovitis is also established for the first time.

Future work is ongoing with his cohort to assess the long term outcome of sub-clinical disease. Healthy age-matched controls are required to differentiate between normal and abnormal perfusion, and any US findings in this sub-group should be correlated with other standards such as MRI or ideally histology.

Chapter 7

7.1 Clinical Utility: Predictive validity of US-detected synovitis

7.2 Clinical relevance

Hand pain with significant stiffness is a common clinical presentation to rheumatologists. These patients often lack clinical evidence of inflammation which makes diagnosis challenging, and the knowledge that some of these patients may develop a persistent arthritis is of concern. Our group has demonstrated sub-clinical synovitis in many patients groups and we hypothesised that detecting synovitis would predict how patients respond to therapy.

7.3 Abstract

7.3.1 Aims

Hand pain with stiffness without obvious clinical synovitis is a common clinical presentation to rheumatologists, with the outcome varying from spontaneous resolution of symptoms to the development of rheumatoid arthritis. This study assessed the response and predictors of response to intramuscular methyl prednisolone (IM MP) and hydroxychloroquine (HCQ) using a standardised treatment protocol.

7.3.2 Methods

Patients were defined as having inflammatory hand pain (IHP) if they had predominant hand pain and morning stiffness of at least 30 minutes duration, with specific exclusions. All received a standardised clinical US assessment prior to receiving IM MP. Response (primary outcome) at 4 weeks was a patient perceived 50% improvement in symptoms; responders who relapsed received repeat IM MP and HCQ.

7.3.3 Results

102 patients were recruited. 21% RF positive, 23% had clinical synovitis, 25% raised CRP and 55% US synovitis. 73% satisfied our definition as responders, reflected by significant reductions in morning stiffness, HAQ, painful and tender joint counts, and patient VAS's ($p \leq 0.006$ for all). US synovitis ($p < 0.001$) and RF ($p = 0.04$), but not clinical synovitis ($p = 0.74$), were significantly associated with response to IM MP. 86% who remained on HCQ long-term reported a benefit.

7.3.4 Conclusions

Treatment with IM MP produces significant improvement of symptoms and function in most patients with IHP. Presence of US synovitis and RF were the best predictors of response; responders whose symptoms recurred benefited from repeat IM MP and HCQ. This study suggests a practical management algorithm for patients with IHP. The potential role of imaging-detected synovitis in predicting response requires further investigation.

7.4 Introduction

The presence of concomitant hand pain and stiffness is common, accounting for between 5-50% (Wolfe, Ross et al. 1993; van der Horst-Bruinsma, Speyer et al. 1998; Quinn, Green et al. 2003) of presenting complaints to rheumatologists. These patients often lack clinical evidence of inflammation which makes diagnosis challenging and less reliable (Gormley, Steele et al. 2001). Their outcome however is not necessarily benign as such patients can develop persistent, joint-damaging disease such as RA. Using classification criteria for RA in patients with recent onset arthritis has inherent difficulties as classic features may be absent early on (Harrison, Symmons et al. 1998; Green, Marzo-Ortega et al. 1999), but also because only a small number of patients that fulfil criteria at presentation continue to do so after a few years (Mikkelsen and Dodge 1969; O'Sullivan and Cathcart 1972; Dugowson, Nelson et al. 1990).

Studies that have assessed patients with so-called early undifferentiated disease have usually defined their cohort by a failure to satisfy other accepted diagnostic criteria, whilst also including features suggesting the potential to evolve into a persistent inflammatory arthritis (Wolfe, Ross et al. 1993; van der Horst-Bruinsma, Speyer et al. 1998; Quinn, Green et al. 2003). The lack of a specific diagnostic category, with patients being variably labelled as 'undifferentiated arthritis' (UA) (Schumacher 2002) or 'hand undifferentiated arthritis' (HUA) (Quinn, Green et al. 2003), makes comparisons between studies difficult. Hand involvement has also been suggested as a specific marker of poor prognosis having the greatest likelihood of persistence of symptoms and DMARD use (Jansen, van Schaardenburg et al. 2002).

Synovitis on clinical examination (Boers, Kostense et al. 2001) and MRI (Conaghan, O'Connor et al. 2003; McQueen, Benton et al. 2003; Ostergaard, Hansen et al. 2003) predicts bone damage in RA and large cohort studies suggest early DMARD therapy in RA improves outcome (Boers, Verhoeven et al. 1997; American College of Rheumatology Subcommittee on Rheumatoid Arthritis 2002; Landewe, Boers et al. 2002; O'Dell, Leff et al. 2002). Imaging modalities such as US (Backhaus, Kamradt et al. 1999; Karim, Wakefield et al. 2001) and MRI (Klarlund, Ostergaard et al. 1999; Goupille, Roulot et al. 2001; Conaghan, O'Connor et al. 2003; McQueen, Benton et al. 2003; Ostergaard, Hansen et al. 2003) are able to detect synovitis in joints without clinically detectable synovitis, so called 'sub-clinical' synovitis.

Ultrasonography has also demonstrated good levels of reliability at detecting synovitis in the small joints of the hands (Backhaus, Kamradt et al. 1999; Ribbens, Andre et al. 2003). It could be envisaged that imaging-detected synovitis may be used to enhance existing classification criteria, thereby allowing for earlier diagnosis and therapeutic intervention, with consequent improved outcome. Ultrasonography is safe, relatively inexpensive and can be used for multiple real-time, dynamic assessments in the outpatient setting offering a valuable addition to the evaluation of patients with early inflammatory arthritis. Such attractive attributes have contributed to the increasing use of ultrasonography by rheumatologists throughout Europe and more recently in North America.

Corticosteroids are used to treat a flare of inflammatory symptoms and to maintain disease control in oligoarthritis (Green, Marzo-Ortega et al. 2001), RA (Boers, Verhoeven et al. 1997), and osteoarthritis (Hochberg, Altman et al. 1995; Creamer 1997). The actions of corticosteroid include inhibition of cell receptor transcription, and

down regulation of adhesion molecule and cytokine (e.g. IL-1, IL-6, TNF α) expression (Barnes 1998). Intramuscular methyl prednisolone is used as an alternative to oral prednisolone in an attempt to reduce long-term side effects although there is little data assessing its efficacy. Hydroxychloroquine, a DMARD with a low toxicity index, has been used with benefit in RA (Clark, Casas et al. 1993; Tsakonas, Fitzgerald et al. 2000), connective tissue disease (Williams, Egger et al. 1994) and inflammatory osteoarthritis (Robertson, Rice et al. 1993; Bryant, des Rosier et al. 1995). Recently it has been suggested HCQ works in part by blocking the innate immune response to bacteria by interfering with Toll-like receptor signalling and as such may prevent the progression to arthritis (Klinman 2003).

In this proof of concept study we tested the hypothesis that patients presenting with predominant hand pain and stiffness have an inflammatory aetiology to their symptoms and should respond to corticosteroids, with those that had evidence of synovitis most likely to respond. We wished to establish a practical, clinically useful management algorithm and HCQ, chosen because of its mild toxicity, was given to responders who subsequently relapsed. Following the logic that inflammation is suppressed by steroids and DMARDs, we tested the hypothesis that patients presenting with hand pain and stiffness most likely to respond to IM MP would be those with synovitis; either clinically or detected by US. In addition, those patients with a good response to IM MP have a predominant inflammatory aetiology to their symptoms and are therefore most likely to respond to a DMARD.

Therefore the primary aim of the study was to assess this group's response to IM MP. Secondary aims included predictors of this response US synovitis in particular, and the response and predictors of response to HCQ.

7.5 Methods

7.5.1 Patients

Patients presenting to the Leeds Early Arthritis clinic with symptoms of inflammatory hand pain (IHP) of more than 3 months duration failing to respond to, or intolerant of NSAIDs were invited to take part. Inflammatory hand pain was defined as predominant hand pain, with diurnal variation of symptoms and early morning stiffness of the hands (EMS) ≥ 30 minutes. Patients with predominant hand pain were assessed due to the increased probability of persistence and disease evolution (Jansen, van Schaardenburg et al. 2002), and to minimise overlap of patients with classic oligoarthritis (mainly affecting lower limbs). Patients with skin psoriasis were included.

Patients with clinical synovitis in ≥ 5 joints, or satisfying ACR classification criteria for RA (Arnett, Edworthy et al. 1988) or the European Spondyloarthropathy Study Group criteria for spondyloarthropathy (Dougados, van der Linden et al. 1991) were excluded. Patients with other inflammatory arthritis including gout, or connective tissue illness were also excluded, as were those with a history of sensitivity to corticosteroid or hydroxychloroquine. Written informed consent was obtained prior to entry into the study and approval for the study was obtained from the Local Research Ethics Committee.

7.5.2 Clinical assessment

Baseline assessment was undertaken in the early arthritis clinic on a single visit and included a full history and physical examination including metrology by an independent joint assessor. Clinical synovitis was documented by the assessing physician, as defined by two out of three of i) joint swelling, ii) joint tenderness and iii) reduced range of movement (Green, Marzo-Ortega et al. 2001; Quinn, Green et al.

2003). Other data collected included EMS, pain relieving medication, and 10cm VAS for hand pain and stiffness completed by the patient, and for disease activity completed by the patient and physician. Functional disability was assessed using the HAQ. Laboratory tests included C-reactive protein, rheumatoid factor (RF), anti-nuclear antibodies and uric acid, with a RF titre of >40 IU, and an ANA of >1/80 titre defined as positive.

7.5.3 Ultrasonography

Ultrasonography was also undertaken by a single rheumatologist (ZK) experienced in US to document synovitis. Synovitis was defined as the presence of abnormally hypoechoic intra-articular tissue, which, unlike synovial fluid, is non-displaceable and only poorly compressible. The 2nd to 5th MCP and PIP joints of the hand with the most symptoms, or the dominant hand if similar symptoms, were examined using an ATL HDI 3000 (Philips) with a 10-5 MHz hockey stick transducer with a small footprint size (24x10mm) to improve access to the finger joints. The palmar and volar aspects of all MCP's were assessed plus the radial and ulnar aspects of the 2nd and 5th MCPs respectively. The PIP joints were assessed from all 4 aspects as above, and each area was imaged in longitudinal and transverse planes.

7.5.4 Treatment

Patients received an IM injection of 120mg MP (patients \leq 55kg were given 80mg) at baseline assessment. Patients were then reviewed after 4 weeks to assess response and have all baseline assessments except US and blood tests repeated. Thereafter patients were reviewed every 12 weeks for a further 48 weeks. The study protocol allowed NSAID or analgesic use for symptom relief during the study period, but corticosteroid use other than within the protocol was not allowed. Responders to IM

MP who subsequently relapsed (recurrence of original symptoms) were treated with a further IM MP and started on HCQ 200mg daily and observed to assess response after 24 weeks of HCQ treatment. Non responders continued with NSAID and analgesic therapy as required. Any patients who subsequently fulfilled criteria for a specific rheumatic condition (e.g RA) had this documented and treated accordingly (Table 7.1).

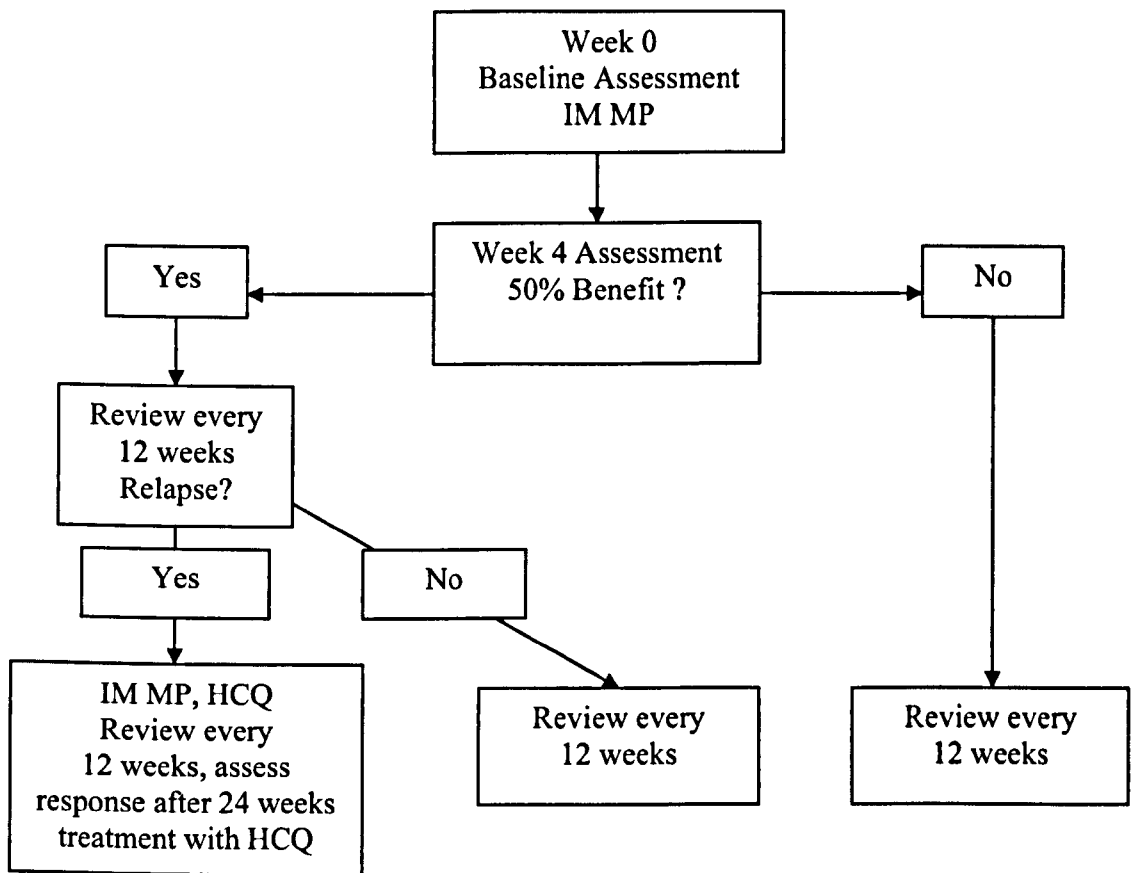


Table 7.1 Study design

7.5.5 Outcome assessment

The primary outcome was response to IM MP at 4 weeks, defined as a 50% improvement in patient symptoms (hand pain and stiffness) in response to a direct question from the assessor. Secondary outcome measures included change in baseline assessments at 4 weeks, change in pain relieving medication use, and predictors of response to IM MP. For the later observational arm of the study, response and predictors of response to HCQ, also defined as a 50% improvement in patient symptoms, were measured. The number of patients evolving into a specific rheumatic condition and side effects of therapy including new-onset diabetes or osteoporotic fracture were also documented.

7.5.6 Statistical analysis

The change in EMS, HAQ, joint counts, and visual analogue scores after IM MP were calculated by subtracting individual baseline data from the 4 week follow-up data. These changes were then compared between responders and non-responders using non-parametric Mann-Whitney U tests. Following Bonferroni correction for multiple comparisons, critical P for testing at the 5% significance level was set at 0.006 for these tests.

Maximum likelihood logistic regression was performed to identify any variables that might affect the odds of responding to treatment. Initially, separate models were run for each predictor in order to obtain age- and sex-corrected odds ratios for each. Prior to entry into the models, age was converted to a 4-level categorical variable based on the quartiles of its distribution. EMS was assigned to three categories: 30-59 minutes, 60-119 minutes, ≥ 120 minutes. Having run models for each predictor

separately to obtain univariate odds ratios, we then created a multivariate model, which consisted of three blocks: demographics (age, sex); markers of inflammation (EMS, CRP and RF); synovitis (clinical and US). The demographics block was forced into the multivariate model, but the variables in the remaining two blocks were added sequentially on a stepwise, likelihood ratio basis (inclusion/exclusion criteria $P=0.05/0.1$).

Logistic regression analysis for predictors of response to HCQ could not be performed due to the small numbers of non-responders to HCQ. Sensitivity, specificity and predictive values were assessed using the standard measures.

7.6 Results

7.6.1 Patient demographics

One-hundred and sixteen patients were screened, fourteen of whom were excluded at screening because they had less than 30 minutes early morning stiffness. One-hundred and two patients were recruited and received IM MP but eleven, whose baseline characteristics were similar to the rest, did not attend the 4 week assessment and were excluded from the study. The majority of the remaining ninety-one patients were female (81%), the mean age was 51 years (18-86), with duration of symptoms between 3-18 months (mean 7 months). Four patients were ≤ 55 kg and received 80 mg IM MP

7.6.2 Baseline assessment

The RF titre was positive in 21% (19/89), CRP was raised in 25% (23/91) and ANA positive in 5% (4/87). Clinical synovitis was detected in 23% patients (21/91); the remaining 70 patients that did not have any clinically-detectable synovitis were labelled the 'arthralgia' group. Synovitis was detected by US in 55% patients (50/91) (Table 7.2). Seventy-two patients were on pain relieving medication at baseline; 44 on NSAIDs, 23 on analgesics and 5 on both.

The median duration of EMS for the group was 60 with a HAQ of 1, PJC of 10, TJC of 14, and SJC of 2. The patients VAS for hand pain and stiffness, and disease activity were both 55 mm, while the physician VAS for disease activity was 18 mm (Table 7.3).

Variable	All patients N=91 (%)	Responders N = 66 (73%)	Non-responders N = 25 (27%)	Age/sex-adjusted OR (95% C.I.)	P =
Age<41	24 (26)	15 (23)	9 (36)	(reference category)	-
41 – 49	21 (23)	16 (24)	5 (20)	2.12 (0.59 – 7.64)	0.25
50 – 61	23 (25)	18 (27)	5 (20)	2.45 (0.64 – 9.36)	0.19
≥62	23 (25)	17 (26)	6 (24)	1.88 (0.52 – 6.86)	0.34
Female	74 (81)	53 (80)	21 (84)	0.75 (0.21 – 2.60)	0.75
Elevated CRP	23 (25)	18 (27)	5 (20)	1.51 (0.48 – 4.78)	0.48
RF positive	19*(21)	18***(28)	1** (4)	9.30 (1.15 – 75.39)	0.04
Clinical synovitis	21 (23)	16 (24)	5 (20)	1.23 (0.37 – 4.11)	0.74
Arthralgia	70 (77)	50(76)	20 (80)	0.81 (0.24-2.72)	0.74
US synovitis	50 (55)	45 (68)	5 (20)	9.28 (2.84 – 30.35)	<0.001
EMS					
30 – 59	32 (35)	23 (35)	9 (36)	(reference category)	-
60 – 119	35 (38)	24 (36)	11 (44)	0.72 (0.24 – 2.19)	0.56
≥120	24 (26)	19 (29)	5 (20)	1.48 (0.41 – 5.39)	0.55

Table 7.2 Baseline characteristics with OR of response to IM MP

Baseline characteristics for all patients, responders and non-responders, with odds ratios for response to IM MP adjusted for age and sex. RF data not available for 2 patients;

*total N = 89, **total N = 24, ***total N = 65

Table 7.3 Baseline characteristics and change after IMMP

Baseline characteristics and change after four weeks following IM MP for all patients, non-responders, and responders to steroid. Figures presented are medians (range). P values are for improvement in baseline assessments between responders and non-responders using non-parametric Mann-Whitney U tests. *total N = 90 **total N = 80

Variable	Baseline			Change over 4 weeks			Mann-Whitney U test P =
	All patients	Non-responders	Responders	Overall	Non-responders	Responders	
EMS (minutes)	60 (30 to 320)	60 (30 to 320)	60 (30 to 320)	-30 (-320 to 120)	0 (-120 to 120)	-35 (-320 to 30)	<0.001
HAQ	1 (0 to 2.75)	1 (0 to 2.13)	1.06 (0 to 2.75)	-0.13 (-1.50 to 0.75)	0 (-0.38 to 0.38)	-0.38 (-1.50 to 0.75)	<0.001
PJC*	10 (0 to 72)	9 (0 to 44)	10 (1 to 72)	-3 (-48 to 22)	0 (-36 to 22)	-6 (-48 to 16)	<0.001
TJC	14 (0 to 72)	18 (0 to 72)	10 (0 to 58)	-2 (-43 to 30)	0 (-24 to 30)	-3 (-43 to 18)	0.006
SJC	2 (0 to 24)	2 (0 to 16)	2 (0 to 24)	-1 (-17 to 6)	0 (-11 to 3)	-1 (-17 to 6)	0.500
Pain/Stiffness VAS (mm)	55 (3 to 98)	53 (3 to 96)	59.5 (9 to 98)	-16 (-71 to 44)	-1 (-63 to 44)	-26.5 (-71 to 42)	<0.001
Disease activity VAS (mm)	55 (2 to 100)	50 (2 to 100)	56 (2 to 98)	-16 (-82 to 49)	0 (-47 to 49)	-20.5 (-82 to 43)	<0.001
Physician VAS**(mm)	18 (0 to 91)	18 (4 to 64)	21 (0 to 91)	-3.5 (-57 to 23)	2 (-52 to 12)	-6.5 (-57 to 23)	0.007

7.6.3 Response to IM MP

A positive response to IM MP was noted in 73% (66/91) of patients; 28% (18/65) were positive for RF and 27% (18/66) of responders had a raised CRP, and all 4 patients with a positive ANA responded to IM MP. Sixteen responders (24%) had clinical synovitis and 50/66 (76%) had arthralgia, and synovitis was detected by US in 68% (45/66) (Table 7.2). Nineteen patients in total discontinued pain relieving medication (14 on NSAIDs and 5 on analgesics).

Age and sex- adjusted logistic regression analyses on individual baseline characteristics demonstrated a significant association between response to IM MP and US synovitis (OR 9.28, $p < 0.001$) and RF (OR 9.30, $p = 0.04$), but not for clinical synovitis (OR 1.23, $p = 0.74$) or an elevated CRP (OR 1.51, $p = 0.48$) (Table 7.2). There were only small, non-significant differences in baseline assessments between responders and non-responders to IM MP (Table 7.3).

Change in baseline assessments

Overall responders had a reduction in EMS of 35 minutes and a reduction in HAQ of 0.38 compared with no change in both for non-responders ($p < 0.001$ for both). Changes in metrology for responders saw a reduction in PJC of 6 compared with no change ($p < 0.001$), a reduction in TJC of 3 compared with no change ($p = 0.006$), and a reduction in SJC of 1 compared with an increase in 1 ($p = 0.500$) in non-responders. The patients VAS for hand pain and stiffness in responders reduced by 26.5 mm compared with 1mm and VAS for disease activity reduced by 20.5 mm compared to no change in non-responders ($p < 0.001$ for both). The physician VAS for disease activity reduced by 6.5 mm in responders compared with an increase of 2 mm ($p = 0.007$) in non-responders (Table 7.3).

Predictors of response to IM MP

Multivariate regression analyses were performed for age, sex, EMS, CRP, RF, CS, and US synovitis. Age and sex were forced into the model; all other variables were entered on a forwards, stepwise basis. The stepwise selection process excluded EMS, clinical synovitis and CRP from the model, leaving age, sex, RF, and US synovitis in the model. Of these variables, only US synovitis made a significant contribution, with RF being retained in the model but not having a sufficiently great individual impact to emerge as a significant predictor. The presence of US synovitis at baseline significantly increased the odds of response to IM MP (adjusted OR = 8.77, 95% C.I. 2.46 – 31.19, $P < 0.001$). The adjusted odds ratio for RF was 5.73 (95% C.I. = 0.65 – 50.16, $P = 0.115$). This model correctly predicted 83.1 percent of responders and 50% of non-responders (Nagelkerke R-squared value 0.341, Hosmer & Lemeshow goodness-of-fit test $p = 0.56$).

Age and sex did not make significant individual contributions to the model, so an additional logistic regression model containing only US synovitis and RF (forced entry) was created. This performed somewhat better than the first model, correctly predicting 72.3 percent of responders and 79.2% of non-responders to IM MP (Nagelkerke R-squared value 0.327, Hosmer & Lemeshow goodness-of-fit test $p = 0.75$). In this second model US synovitis at baseline was associated with a significant increase in the odds of response (adjusted OR = 7.41, 95% C.I. = 2.51 – 21.82, $P < 0.001$), although RF again did not make a significant contribution to the model (adjusted OR = 5.48, 95% C.I. = 0.63 – 47.71, $P = 0.123$) (Table 7.2).

7.6.4 Response to HCQ

Following IM MP 36% (24/66) of responders remained well to the end of the study period (52 weeks) and did not receive any further IM MP or HCQ. Sixty-four percent (42/66) of responders relapsed (all within 24 weeks) and were treated with repeat IM MP and HCQ. Thirty-three percent (14/42) of patients stopped taking HCQ within the first 3 months; 11 were unable tolerate HCQ, and 3 were non-compliant. Of those that remained on HCQ (with minimum follow up of 28 weeks) 86% (24/28) reported a benefit. Thirty-three percent (8/24) of responders had a raised CRP and 22% (5/23) were positive for RF. Twenty-five percent (6/24) had clinically-detectable synovitis and 75% (18/24) had arthralgia. Sixty-three percent (15/24) of responders had US synovitis at baseline. Seventy-nine percent (11/14) of the patients who stopped taking HCQ within the first 3 months relapsed.

Predictors of Response to HCQ

In patients who remained on HCQ long-term, US synovitis at baseline had a positive predictive value of 94% (15/16); compared with 82% (18/22) for arthralgia, 83% (5/6) for a positive RF, and 89% (8/9) for a raised CRP. All 6 patients with clinical synovitis and all 3 with a positive ANA responded to HCQ.

7.6.5 Other outcomes

Eight out of 91 patients (9%) developed RA during the course of the study; 6 had responded to IM MP, and 3 of these 6 also responded to HCQ given later. Two patients developed psoriatic arthritis, with 1 each labelled as having reactive arthritis and gout. No patients developed diabetes and there were no reports of osteoporotic fracture.

We also compared the finding of clinical synovitis in patients with US synovitis. At baseline 50 patients had US synovitis; 16 of whom had clinical synovitis (5 patients with clinical synovitis did not have US Synovitis). Forty-five responders to IM MP had US synovitis; 14 of whom had clinical synovitis (2 patients with clinical synovitis did not have US Synovitis) (Table 7.4).

	Clinical Synovitis		Arthralgia		Total
	US -ve	US +ve	US +ve	US -ve	
All patients	5	16	34	36	91
Responders	2	14	31	19	66
Non-responders	3	2	3	17	25

Table 7.4 US synovitis in polyarthralgia and clinical synovitis

Relationship between US synovitis, clinical synovitis and response to IM MP. US +ve = US synovitis, US -ve = no US synovitis. Nearly half the arthralgia group had US synovitis and proportionately more non-responders had clinical synovitis without US synovitis than responders.

7.7 Discussion

This is the first study to examine the clinical features of IHP and relate their response to IM MP; in particular to study the predictive value of baseline features in such patients. This study demonstrated that most patients respond well to IM MP and, consistent with our hypothesis, US synovitis at baseline was significantly associated with this response. This potentially provides an insight into the pathological basis of these patients' symptoms, and may also indicate that our traditional methods of assessment are not sensitive enough to detect this level of synovitis suggesting a possible role for US. We also observed that many who respond to IM MP relapse; and HCQ may be an appropriate choice of DMARD therapy in this sub-group.

We defined response as a patient-perceived 50% improvement in symptoms in the absence of any known appropriate outcome measures, and using this definition, responders had a significant reduction in most baseline assessments compared to non-responders. In addition the reduction in HAQ of 0.38 following IM MP (Table 7.3) is greater than what is considered to be the minimal clinically significant difference in HAQ for RA (0.22) (Wells, Tugwell et al. 1993), and for a combination of arthritides (0.20) (Redelmeier and Lorig 1993), suggesting our definition of response is likely to be clinically significant.

The logistic regression analyses identified 2 models, which only reasonably predicted response to IM MP suggesting other factors, not recorded in this study, may affect response to steroid. That US synovitis remained a significant predictor of response throughout all of the logistic regression models suggests there is an association between the presence of US synovitis at baseline and the odds of

responding to corticosteroid. Further research with a greater number of patients is required to assess the true extent of this.

Contrary to our expectations clinical synovitis was not a factor at predicting response. One explanation may be that clinical examination has poor accuracy in detecting “clinically important synovitis” that may be amenable to therapy. In our study US detected synovitis in almost half of those without clinically detectable synovitis, thus demonstrating the insensitivity of clinical assessment at detecting low-grade inflammation. Another explanation might be that patients with clinical synovitis have a greater amount of inflammation and our response criteria of greater than 50% patient-perceived improvement may have been too stringent excluding some patients with a partial response. The fact that 2 patients who developed RA, were defined as non-responders according to this criteria might support this.

This study highlights the varying outcome of this cohort of patients with IHP. One third of patients remained well, either due to the impact of corticosteroid or spontaneous resolution, although other results suggest this is not an entirely benign group. The baseline HAQ scores in our study were similar to those with early RA (Wolfe and Cathey 1991; Harrison, Symmons et al. 1996) and inflammatory polyarthritis (Guillemin, Suurmeijer et al. 1994), and with over 1 in 10 developing a specific chronic inflammatory arthritis these patients should be monitored carefully. Most patients in our study did not have clinical synovitis and we also excluded those with polyarthritis, but despite our cohort appearing more benign, with less documented clinical synovitis, than previous studies (Green, Marzo-Ortega et al. 2001; Jansen, van Schaardenburg et al. 2002; Schumacher 2002; Quinn, Green et al. 2003) similar numbers developed a specific rheumatic disease.

A possible limitation of the study was that it was a pragmatic study evaluating a clinical algorithm, and not a placebo controlled trial. We included patients with a diagnosis of OA because this is a common condition that on its own does not exclude the presence, or the development, of arthritis such as RA. Another possible limitation is that we did not have long-term assessments for those patients on HCQ, but this reflects standard patient care where patients are asked whether they felt they have responded to medication. It could be argued that part of the response to HCQ could be a result of the repeat IM MP, but response to HCQ was assessed after 24 weeks and most patients that stopped HCQ relapsed, suggesting response to HCQ rather than IM MP. This highlights the need for a randomised control trial.

In summary this study provides preliminary evidence, insights into pathology and an approach to the management of patients with inflammatory hand pain. We suggest that in patients who present with predominant hand pain, stiffness, and signs of synovitis one can justify the use of IM MP. Furthermore, those patients with synovitis demonstrable on US only should also receive an IM MP injection. Where US assessment is not available it is still reasonable to proceed with an IM MP if inflammatory symptoms but not signs are present.

One could predict from our results that the majority of patients would get significant short to medium term benefit. If they respond to IM MP and have a recurrence of symptoms it is reasonable to undertake a trial of HCQ expecting that some will have side effects.

7.8 Subsequent literature

7.8.1 Efficacy of IM MP

Since this work has been done there has been a randomised placebo controlled trial of monthly injections of IM MP in active RA demonstrating that IM MP has short term benefit over placebo (Choy, Kingsley et al. 2005). Disease activity improved more rapidly than in the placebo group, but this did not continue at 6 months. There was however a significant reduction in erosion counts in the treatment arm. The treatment group did however, suffer significantly more adverse reactions (55 vs 42) including vertebral fracture and diabetes, as well as a significantly greater drop in hip bone density compared with placebo. The results of this study warn that IM MP given as a series of 24 monthly injections can cause considerable side-effects and suggest that if a patient has increased disease activity; the best option is to increase DMARD therapy if possible and consider any potential benefit of IM MP against the potential risks as described.

7.9 Summary

In this chapter we suggest a possible underlying inflammatory aetiology of many patients that present with symptoms, but no signs, to suggest inflammatory arthritis. In this study most had sub-clinical synovitis and US synovitis was the best predictor of response to IM MP which we assumed was a pointer to an inflammatory aetiology. The treatment algorithm we used is a practical way of managing this group of patients.

Further work should include a repeat US assessment to evaluate the outcome of sub-clinical synovitis after IM MP and determine whether any change in synovitis reflects response. Patients need to be randomised to receive placebo or IM MP to remove any placebo effect bias, and also to observe the natural progression of this group.

Chapter 8

8.1 Clinical Utility: Impact of Ultrasonography

8.2 Clinical relevance

The use of US is increasing because US is safe (uses no ionising radiation), non-invasive and can be used repeatedly in an outpatient setting providing immediate access for patients. Availability of US varies widely between hospitals with most referrals for specific conditions such as rotator cuff tears, often requiring a visit to the radiology department and then a return visit to the referring physician. There is however a paucity of data assessing its actual impact on patient management. This is the first study to assess the impact of US in a rheumatology clinic using it as an adjunct to routine clinical assessment.

8.3 Abstract

8.3.1 Aims

The aim of this study was to investigate the diagnostic and therapeutic impact of US in a routine rheumatology setting.

8.3.2 Methods

One hundred consecutive referrals for US from rheumatology outpatient clinics were assessed. The referring clinicians documented the site-specific clinical diagnosis (SSD), overall diagnosis (OD) and management plan before US. Ultrasonography was then performed in the clinic and the patient immediately reviewed by the referring clinician with the US report. Any change in diagnosis or management as a result of US was recorded.

8.3.3 Results

One hundred and twenty-one sites were examined by US. Ultrasonography altered SSD in 53/100 (53%) and the OD in 5/100 (5%) patients. Management plan was altered in 53/100 (53%) patients and predominantly involved changes to guided corticosteroid therapy (36 patients) although use of disease modifying anti-rheumatic drugs was also altered (13 patients). The most frequent reason for referral to US was to assess synovitis in 86/121 (71%) sites, and the MCP joints were the most scanned sites in 45/121 (37%).

8.3.4 Conclusions

This study demonstrated that US has a positive impact on diagnosis and therapy offering important benefits when used as an adjunct to clinical examination in the rheumatology setting. If this transfers into improved outcome, it is likely to have major implications for the future practice of rheumatology.

8.4 Introduction

There is increasing interest in the use of US in rheumatology (Grassi and Cervini 1998; Wakefield, Gibbon et al. 1999; Tan, Wakefield et al. 2003; Kane, Bruyn et al. 2006). Ultrasonography is non-invasive, safe (uses no ionising radiation) and can be used repeatedly in an outpatient setting providing immediate access for patients. Unlike conventional x-ray and other imaging modalities, US can be repeated as often as necessary since it does not involve ionising radiation or high unit costs. Availability of US varies widely between hospitals with most referrals for specific conditions such as rotator cuff tears. This usually requires a separate visit to the radiology department and then a return visit to the referring physician.

Advances in technology has made US more amenable to assess smaller joints and there is accumulating evidence that US is more accurate than clinical examination in the detection of synovitis and tenosynovitis in small joints (Grassi, Tittarelli et al. 1993; Grassi, Tittarelli et al. 1995; Lund, Heikal et al. 1995; Backhaus, Kamradt et al. 1999; Swen, Jacobs et al. 2000). The benefits of US have also been determined in the assessment of the painful shoulder (Alasaarela, Takalo et al. 1997; Swen, Jacobs et al. 1998), hip (Koski 1989; Koski, Anttila et al. 1990), knee (Hauzeur, Mathy et al. 1999; Ward, Jacobson et al. 2001), ankle (Koski 1990; Jacobson, Andresen et al. 1998), and in conditions such as RA (Gratz, Gobel et al. 1999), OA (Iagnocco and Coari 2000), and SpA (Lehtinen, Taavitsainen et al. 1994). In addition, US also enables accurate placement of corticosteroid injections (Cicak, Matasovic et al. 1992).

Rankine and colleagues in a controlled prospective observational study, have assessed the influence of lumbar spine MRI on the management of patients with low back and leg pain, with a clinical diagnosis of neural compression (Rankine, Gill et al. 1998). Of the 72 patients examined, 65 (90.3%) had leg pain as a predominant feature and 31 (43%) had abnormalities in neurological examination. Following MRI 23/48 (47.9%) of patients had management changed from surgery to conservative management. The diagnosis altered in 50 % of cases with the largest change in diagnosis occurring in 13 patients where MRI did not confirm the clinical impression of nerve root compression. Interestingly 17 with no abnormality on neurological examination were subsequently treated by surgery which included all 12 patients treated by spinal fusion. The authors concluded that the major impact of MRI was to avoid surgery with its potential morbidities. There is a paucity of similar data on the effect of US on these processes (Grassi and Cervini 1998; Wakefield, Gibbon et al. 1999).

This study evaluated the diagnostic and therapeutic impact of musculoskeletal US in rheumatology outpatient clinics.

8.5 Methods

8.5.1 Patients

Of 520 rheumatology outpatients seen in the Department of Rheumatology at Leeds General Infirmary, 100 consecutive patients referred for US were included in this observational study. These were referred from an early arthritis clinic (EAC) and general clinics. The EAC is a 'fast-track' referral service for patients with a history suggestive of inflammatory arthritis of less than 12 months duration. The local ethics committee approved the study and informed consent was obtained from all patients. All patients referred for US as part of a research protocol were excluded.

8.5.2 Study Procedure

All patients underwent a routine assessment, which included a detailed interview and clinical examination by an experienced physician. Information with the referral included the indication for US, the site of interest and site-specific diagnosis (SSD), e.g. synovitis, tenosynovitis. The overall diagnosis (OD), (e.g. rheumatoid arthritis, gout) and management plan were recorded separately i.e. data not available to the person performing US. Patients then had US performed during the same clinic visit using an on-site ATL HDI 3000 (Advanced Technology Laboratories, Bothel Washington, USA) machine, which operated throughout clinic time. A linear array 10-5 MHz 'hockey stick' transducer was used to examine most joints, being particularly useful for the small joints. A curvi-linear array 5-3 MHz transducer was used to examine the hip. An experienced rheumatology research fellow (RJW) trained by musculoskeletal radiologists performed the US. The physician subsequently reviewed the patient in the same clinic with the US report.

Any change in the diagnosis or management plan as a result of US was documented. The completed referral forms were then returned to an independent database manager who was not involved in the clinical or US assessment.

8.5.3 Statistical analysis

The number of changes in management and diagnosis are presented descriptively. The primary outcome measure was change in SSD after US. Change in OD and management were secondary outcomes.

8.6 Results

Of the 100 patients referred for US, 73 were female and the mean age was 50 years (range 17-87). Fifty-eight patients were referred from general clinics and 42 from EAC; there were 30 new patients in total. Sixty-four patients were referred to confirm a diagnosis alone, with 36 referred to confirm a diagnosis with the aim of subsequent local corticosteroid injection. Twenty of these 36 (56%) had reported a poor response to a previous 'blind' corticosteroid injection.

A total of 121 sites were examined by US, the commonest sites being the small joints of the hands and feet with the MCP the most frequently requested in 45/121 (37%) sites (Table 8.1). The most common request of US was to confirm the presence or absence of synovitis 86/121(71%), followed by enquiries regarding enthesitis 11/121 (9%) and tenosynovitis 9/121(7%) (Figure 8.1).

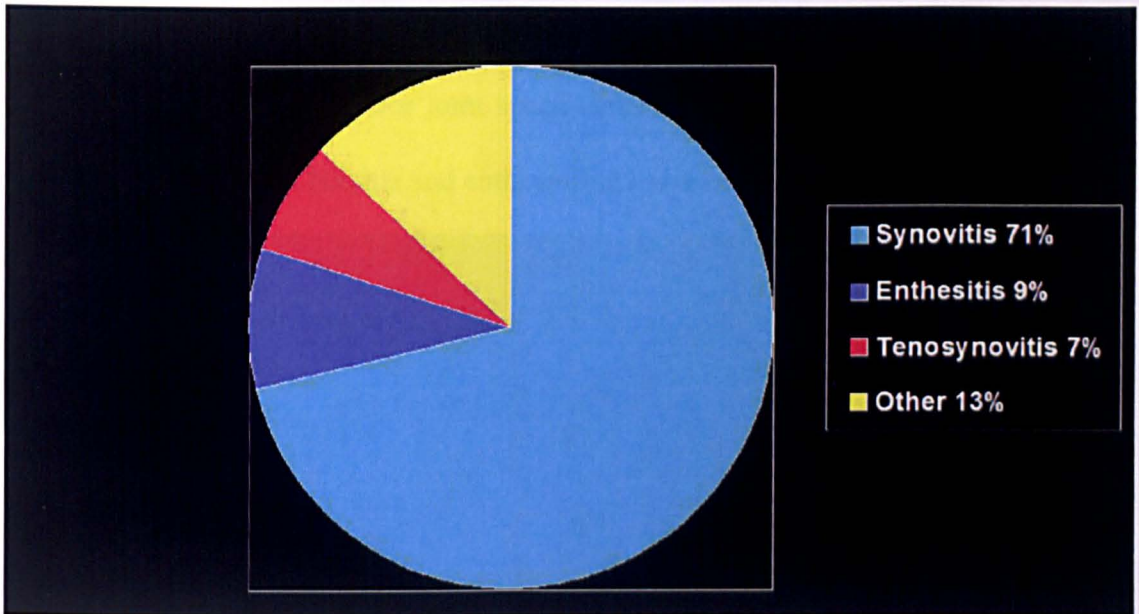


Figure 8.1 US requests by pathology

With regard to OD, of the 100 patients, 45 had a pre-US diagnosis of inflammatory arthritis, 35 had a local diagnosis only (eg. epicondylitis, rotator cuff tendonitis), 12 patients were diagnosed as having degenerative disease and 8 had other diagnoses including crystal arthropathy and polymyalgia rheumatica.

8.6.1 Changes in site-specific diagnosis

The SSD was changed in 53/100 (53%) patients and 60/121 sites (50%). The most frequent change in diagnosis was the clinical assessment of synovitis, which changed in 43/60 (72%) sites. In order of frequency the changes in clinical SSD were: synovitis in 43/60 (72%) sites, tenosynovitis in 7/60 (12%) sites and enthesitis in 5/60 (8%) sites. There were similar changes in SSD in both EAC and general clinic patients.

For synovitis this involved documenting no synovitis on US when synovitis had been clinically diagnosed in 18 sites; demonstrating synovitis on US when none was detected clinically in 18 (Figure 8.2, Figure 8.3). In the remaining 7 sites, the

pre-US diagnosis of synovitis was changed to degenerative changes (defined as the presence of osteophytes and/or joint space narrowing) without synovitis in 3 sites, tenosynovitis in 2, and bursitis and enthesitis in 1 site each.

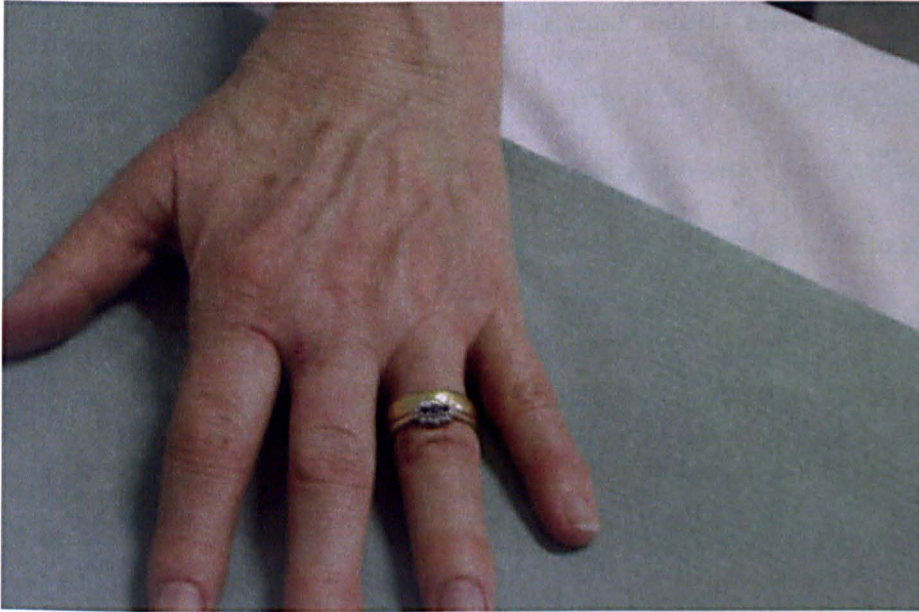


Figure 8.2 Photograph of subject without clinical synovitis

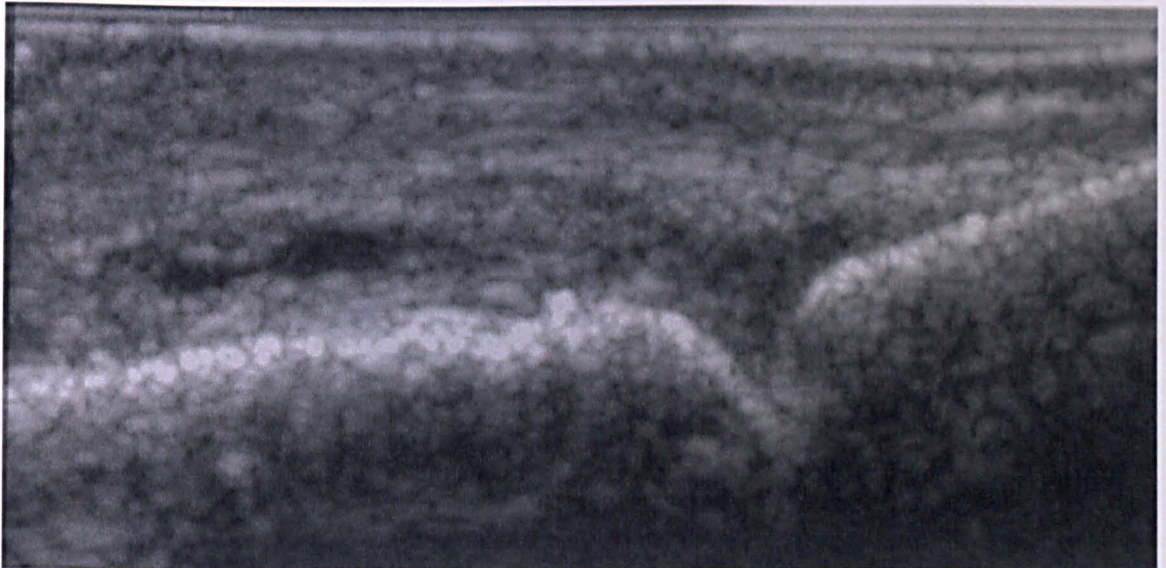


Figure 8.3 Corresponding US demonstrating synovitis/effusion

For tenosynovitis the SSD was changed; to synovitis in 4, no pathology in 2 and periostitis in 1 site. The diagnosis of enthesitis was changed; to synovitis and bursitis in 2 sites each, and to normal in 1 site.

The commonest site where SSD was altered was at the most frequently scanned joints; MCPs in 24/60 (40%) and the wrist in 8/60 (13%) sites (Table 8.1). Ultrasonography was also able to provide additional information, not provided by clinical examination in 55 sites; this included erosions, osteophytes, reduced joint space and calcific tendonitis.

Site of scan	Number (%)	Frequency of SSD change (%)
Overall	121 (100)	60/121 (50)
Metacarpophalangeal joints	45 (37)	24/45 (53)
Wrist	17 (14)	8/17 (47)
Proximal interphalangeal joints	15 (12)	5/15 (33)
Hindfoot	12 (10)	7/12 (58)
Knee	10 (8)	5/10 (50)
Forefoot	7 (6)	6/7 (86)
Elbow	5 (4)	1/5 (20)
Others	10 (8)	4/10 (40)

Table 8.1 Sites assessed by US, with change in SSD

8.6.2 Changes in overall diagnosis

The OD was changed in 5/100 (5%) patients. Two patients had a clinical diagnosis of rheumatoid arthritis altered to seronegative spondyloarthropathy after US documented enthesal pathology. In one patient with a clinically hot swollen elbow (suspected joint sepsis) US documented extensive enthesitis without any joint effusion; in another patient with PMR and suspected peripheral synovitis, US confirmed joint synovitis but also erosive changes with the OD then being changed to rheumatoid arthritis (RA). A seropositive patient with monoarthritis of the wrist had US, which documented symmetrical synovitis of the wrist and MCPs with erosions in the wrist hence the OD being changed to RA. There were a further 8/100 (8%) patients, 7 of whom were new referrals, in which US helped confirm a provisional OD. Seven of these had a diagnosis of inflammatory arthritis confirmed after US documented a combination of synovitis, tenosynovitis and erosions, and in 1 patient US documented degenerative changes confirming the OD of osteoarthritis.

8.6.3 Changes in management

The management plan was altered in 53/100 (53%) patients after US, in 39 due to a change in SSD and in 14 as a result of US confirming a provisional SSD.

Corticosteroid therapy was affected in 43 patients. The decision to give a soft tissue or intra-articular corticosteroid injection was altered in 22 patients: 12 were withheld and 10 given at a different site. In addition, 14 patients had a 'newly planned' injection after US. Only 14 of the original 36 (39%) intended injections were given at the planned site (Figure 8.4). Parenteral corticosteroid therapy was affected in 7 patients, 6 were newly planned and 1 withheld, as a result of US. Two of the patients with a newly planned parenteral corticosteroid were also commenced

on disease modifying anti-rheumatic drug (DMARD) therapy because of a new OD after US.

Disease modifying drug therapy was affected in 13 patients; increased in 10 patients due to the detection of extensive subclinical synovitis and reduced in 3 due to an absence of synovitis demonstrated by US. Other changes included 4 new podiatry referrals, 2 planned diagnostic medical arthroscopies withheld and 1 new x-ray referral after US. Seven patients had more than 1 management change.

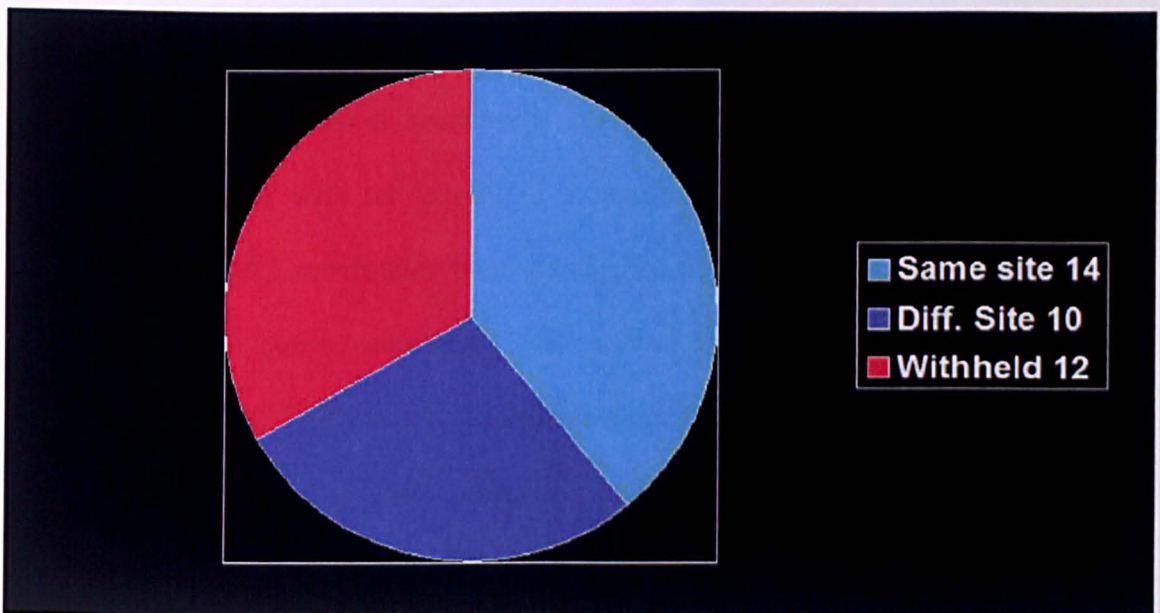


Figure 8.4 Impact on Intra-articular corticosteroid use

Same site: Injections were given at the planned site (n=14)

Diff. Site: Injections were still, given, but at a different site (n=10)

Withheld: No injection given (n=12)

8.7 Discussion

This study suggests that US has a diagnostic and therapeutic impact in the majority of referred patients attending rheumatology clinics. When these findings are applied in the context of all patients attending clinics during the study period, US has an impact on diagnosis and management in at least 10% (53/520) of all cases. This study also documents the referral pattern when rheumatologists have direct access to US, with most patients referred for assessment of small joint synovitis and guided injections.

Accurate detection of synovitis is important not only for appropriate local treatments but also, with the advent of expensive systemic therapies, to assess disease activity and subsequent bone damage. Early treatment of inflammatory arthritis improves patient outcome (Stenger, Van Leeuwen et al. 1998; Green, Marzo-Ortega et al. 1999) and potentially reduces the cost to society in the long-term. Consistent with previous reports, this study demonstrates a poor correlation between US and clinical examination in the detection of synovitis; the changes to DMARD therapy were mainly a result of US detecting subclinical synovitis.

A study of 40 patients with RA observed over 6 years demonstrated ongoing progression of x-ray damage despite improvement in clinical indices like ESR and grip strength (Mulherin, Fitzgerald et al. 1996). Another study using MRI concluded that progression of disease occurs early in disease and also found disagreement between clinical improvement and progression of MRI erosions (McQueen, Stewart et al. 1999). Our findings, in addition to the evidence that US is able to differentiate between active and inactive disease in RA (Hau, Schultz et al. 1999), concur with their conclusion that patients with clinically stable disease are often under-treated emphasising the role for better assessment modalities like US.

Response to corticosteroid injections is known to vary considerably, and there is evidence that accurately placed injections lead to better outcomes (Jones, Regan et al. 1993; Eustace, Brophy et al. 1997). Interestingly the majority of patients referred with a planned corticosteroid injection reported a poor response to a previous blind corticosteroid injection and, in this study as a consequence of US, less than half received the injection at the pre-US planned site. The impact of US on corticosteroid injections therefore reflects the inability of clinical assessment to accurately localise pathology; and may explain part of the variation in response to conventionally placed injections.

The US examinations took place in the outpatient department where direct access has the advantage of immediate alteration in management, if necessary, without additional hospital visits and waiting time. This helps reduce both the direct and indirect costs to the hospital service and the patient. After initial capital expenditure, the only running costs for US are the service contract and operators' time, in this case taking 10-15 minutes per patient assessment.

There are limitations to this study. There was an initial selection bias since the patients assessed were all referred for US in the first instance, suggesting a degree of uncertainty in the diagnosis or management at the outset. Although a change in the clinical diagnosis or management plan is an important first step to demonstrate, it does not necessarily follow that outcome will be improved. Any benefit will have to be offset with the additional cost of US equipment and training, but should also take into account the direct and indirect cost benefit of a 'one-stop' patient service.

8.8 Subsequent literature

In this chapter we evaluated the impact of US in the diagnosis and management of rheumatology patients. Significant additions to the literature are described below.

8.8.1 Diagnosis

Inflammatory OA

To evaluate the ability of high resolution US in the diagnosis of erosive OA, 110 patients had plain x-ray with US of the DIP and PIP joints (Iagnocco, Filippucci et al. 2005). The presence of articular bone surface irregularities defined as either marginal osteophytes or central erosions was recorded. Central erosions were detected by US in 16/22 (72.7%) patients with x-ray features of erosive OA and in none of 88 patients with classical hand OA without erosions on x-ray. Sensitivity and specificity for the detection of central erosions by US were 73% and 100%, respectively. The positive and negative likelihood ratios were 100% and 94%. This is the first study to evaluate the presence of erosions in patients with erosive OA by US. The authors conclude that US is a useful technique for differentiating erosive and classical hand OA.

Carpal Tunnel Syndrome

This study assessed US diagnosis with nerve conduction study diagnosis of carpal tunnel syndrome (Swen, Jacobs et al. 2001). Sixty-three patients with a clinical diagnosis of carpal tunnel syndrome, waiting carpal tunnel release, had US and nerve conduction studies performed. The criterion for diagnosis of carpal tunnel syndrome, and the gold-standard, was 90% or greater improvement of initial complaints 3 months after surgery. Following surgery, 47 patients (75%)

experienced 90% or greater relief of complaints. Using this criterion, mean cross sectional area of the median nerve for patients with CTS was 11.3 mm² compared to 6.1 mm² in the control group. The sensitivity to detect carpal tunnel syndrome was 0.70 and 0.98, and specificity was 0.63 and 0.19 positive predictive value was 0.85 and 0.78, negative predictive value was 0.42 and 0.75, and accuracy was 0.68 and 0.78, all for US and nerve conduction study respectively. The authors concluded that while US was slightly less sensitive it was significantly more specific than nerve conduction study.

Scaphoid fracture

This study used US to assess patients with clinically suspected scaphoid fractures (Senall, Failla et al. 2004). Eighteen patients attending accident and emergency with a history of wrist trauma, snuffbox tenderness, swelling, and a negative wrist x-ray were assessed. Ultrasonography correctly identified 7/9 cases of scaphoid fracture that were eventually positive on x-ray. Eight out of 9 cases were correctly identified as negative. Ultrasonography had a sensitivity of 78% and specificity of 89%, with a positive predictive value of 88% and negative predictive value of 80%. The authors concluded that US should be used in suspected cases of fracture where x-ray is negative. This study again demonstrates a clinical utility of US. Whilst US clearly has face and content validity to detect scaphoid fracture this study potentially adds concurrent validity because in the clinical setting repeat x-ray of the wrist to confirm scaphoid fracture would be seen as an acceptable gold standard. This study was limited however by the fact that US incorrectly identified one case as negative, which x-ray subsequently found as having scaphoid fracture. Whilst scaphoid fracture is probably more appropriately discussed in an orthopaedic

setting, we see many patients with hand and wrist pain, a significant number of whom describe a history of trauma. It is important that Rheumatologists are aware of this but also aware of the validity of US in assessing this feature.

Lateral epicondylitis

This study evaluated US features in patients with a clinical diagnosis of lateral epicondylitis including healthy patients as controls (Levin, Nazarian et al. 2005). Ultrasonography of the common extensor tendon was performed in 10 asymptomatic volunteers (20 elbows), and 22 patients (37 elbows) with symptoms of lateral epicondylitis. Abnormal images were assessed to see how many pre-set US findings were demonstrated. Using a clinical diagnosis of epicondylitis as the gold standard US demonstrated sensitivities ranging from 72% to 88% and specificities from 36% to 48% amongst the three readers. Odds ratios for the following findings were statistically significant ($P < .05$): calcification of common extensor tendon, tendon thickening, adjacent bone irregularity, focal hypoechoic regions, and diffuse heterogeneity, however odds ratios for lateral epicondyle enthesophytes were statistically significant ($P < 0.05$) for the first (of 2) reading sessions only. Odds ratios for linear intrasubstance tears and peritendinous fluid were not statistically significant. The authors concluded that there was a statistically significant relationship between symptoms and intra-tendon calcification, tendon thickening, adjacent bone irregularity, focal hypoechoic regions, and diffuse heterogeneity. This study describes common US features in lateral epicondylitis.

Plantar fasciitis

This study used PD US to demonstrate findings in plantar fasciitis by assessing both heels of 20 patients with unilateral plantar fasciitis, with 20 healthy volunteers as controls (Walther, Radke et al. 2004). Duration of disease was noted and pain was assessed using a VAS score. Moderate or marked hyperaemia was found with PD US in the plantar fascia and the surrounding soft tissue along the first cm distally from the insertion in 8 (40%) of the 20 symptomatic heels and in 1 patient (5%) on the asymptomatic side. There were no significant abnormalities in any of the control group and the difference between both groups was significant ($p<0.05$). This study suggests that PD US is valuable in diagnosing, and also gives some insight into the potential pathogenesis of plantar fasciitis.

8.8.2 Comparison with clinical assessment*Rheumatoid arthritis*

This study assessed the relationship between clinical examination and effusion detected by US in the MTP and ankle joints in 30 patients with RA (Luukkainen, Saltyshev et al. 2003). Altogether 288 MTP joints were assessed with agreement between clinical examination and US in 194. Of the 60 ankle joints assessed there was agreement in only 34. The Kappa coefficient between investigations was 0.165 in MTP and 0.043 in ankle joints. The authors concluded that there was a poor agreement between clinical assessment and US in the foot.

This study included 200 MTP joints of 40 patients with RA and 100 MTP joints of 20 healthy controls and assessed US, MRI and clinical examination for the detection of joint inflammation with MRI being regarded as the gold standard (Szkudlarek, Narvestad et al. 2004) The sensitivity, specificity, and accuracy of US

for the detection of synovitis were 0.87, 0.74, and 0.79 respectively, while for clinical examination; the corresponding values were 0.43, 0.89, and 0.71 respectively. For patients, US demonstrated synovitis in 36, while MRI and clinical examination revealed synovitis in 31 and 20 patients respectively. US and MRI synovitis showed intra-class correlation coefficients of 0.56-0.72 ($P < 0.0001$). The authors concluded that US was more sensitive and accurate than clinical examination and had good correlation with MRI. This study again demonstrates the relative lack of sensitivity of clinical examination to detect synovitis in the MTP joint, and also demonstrated concurrent validity for US.

This study compared the relationship between clinical detection of swelling and effusion with US findings in the elbows of 50 RA patients and 20 healthy controls (Luukkainen, Sanila et al. 2005). They found there was only fair agreement in assessments of 77 RA joints, resulting in a kappa coefficient of 0.371. There was one hundred percent concordance in the control group elbow assessments (40 elbows). The authors concluded that clinical assessment was not accurate at detecting elbow effusions.

This pioneering study compared clinical assessment of overall inflammatory activity in 94 patients with RA using gray-scale and PD US, comparing findings with inflammatory markers and joint counts (Naredo, Bonilla et al. 2005). Each patient had 60 joints examined by US and two rheumatologists reached a consensus for the presence of tender joints, swollen joints and subjective swelling score from 1 to 3. Similarly US joint effusion, synovitis, and PD signal were graded from 1 to 30 in all 60 joints. A 28 joint count for clinical and US variables was also calculated. Using the 60 joint count, US showed significantly more joints with effusion (mean 15.2) and synovitis (mean 14.6) than clinical examination (mean 11.5, $p < 0.05$). A

significant correlation was found between joint count and joint index for swelling, US effusion, synovitis, and PD signal. The reduced 28 joint count for effusion, synovitis, and PD signal all correlated highly with the corresponding 60 joint counts. US findings also correlated better with CRP and ESR than clinical measures. They concluded that US is more sensitive at detecting synovitis in RA and that the reduced 28 joint count is comparable to the 60 joint count. The same authors have subsequently completed a further analysis and concluded that a 12 joint count is comparable to the 60 joint count (Naredo, Gamero et al. 2005).

Spondyloarthropathy

In this study, US was compared with clinical assessment in detecting enthesal abnormalities in patients with SpA (Balint, Kane et al. 2002). Thirty five patients had US examination of both lower limbs at five enthesal sites to detect bursitis, structural thickness, bony erosion, and enthesophyte. All patients also had a separate independent clinical assessment. The study findings were, on clinical examination, 75/348 (22%) enthesal sites were abnormal compared with 195/348 (56%) using US. In 19 enthesal sites with bursitis on US, only five were detected by clinical examination. Compared with US, clinical examination had a low sensitivity (22.6%) and moderate specificity (79.7%). There was no significant correlation between the US score of enthesitis and acute phase parameters such as erythrocyte sedimentation rate (ESR) or C reactive protein (CRP). The authors concluded that US was better than clinical assessment for the assessment of enthesal abnormalities in patients with SpA and went on to propose an US enthesal score.

In another study of patients with SpA, D'Agostino and colleagues (D'Agostino, Said-Nahal et al. 2003) assessed the prevalence and severity of

peripheral enthesitis in SpA with US and PD US. One hundred and sixty-four consecutive patients with SpA and 64 control patients (34 with RA, 34 with mechanical low back pain) had US examination of major entheses. Evidence of vascularisation was documented, concentrating on the following sites; cortical bone insertion of entheses, junction between tendon and entheses, body of tendon, and bursa. US findings consistent with enthesitis were observed in 161/164 SpA patients (98%), affecting 1,131/2,952 entheses examined (38%). In contrast, only 132 of 1,152 entheses (11%) were found to be abnormal in 33 of 64 control patients (52%). Abnormal findings were most commonly distributed in the distal portion of the lower limbs. Regarding PD US, none of the abnormal entheses in control patients showed vascularisation, compared with 916 of 1,131 abnormal entheses in SpA patients (81%). Vascularisation was nearly always detected at the cortical bone insertion and sometimes also in the bursa. The authors concluded that US combined with PD allowed for the detection of peripheral enthesitis in the majority of SpA patients, but without falsely including other patient groups. This study, whilst not being compared with any gold standard, gives a better understanding of enthesal pathology and its prevalence in patients with SpA.

Oligoarthritis

This study set out to determine the prevalence of sub-clinical synovitis using US assessment of painful and asymptomatic joints in early, untreated oligoarthritis (≤ 5 joints) (Wakefield, Green et al. 2004). Eighty patients underwent a detailed clinical assessment by two physicians and all painful joints were identified and assessed by US. In the last 40 patients all painful joints were assessed, but also a preordained set of joints were included even if asymptomatic. In 80 patients, 644

painful joints (with and without clinical synovitis) were identified and each underwent a US assessment. Of these joints, 185 had clinical synovitis, of which, US detected synovitis in only 79% (147/185). In the other 38 joints US demonstrated tenosynovitis instead of synovitis in 12 joints and possible, but not definite, synovitis in 11 joints. Fifteen joints were, however, normal on US. In 459 joints that were not clinically synovitic, US detected synovitis in 33% (150/459). In 64% (51/80) of patients, US detected synovitis in more joints than clinical examination and in 36% (29/80) of patients, US detected a polyarthritis (>6 joints). Of the 826 asymptomatic (non-painful) joints scanned, 13% (107/826) had US detected synovitis. The authors concluded that US detected more synovitis than clinical examination in patients with oligoarthritis. In almost two thirds of patients there was evidence of sub-clinical disease while one third could be reclassified as polyarticular. They also concluded that the definition of oligoarthritis based on clinical findings may be inappropriate in many patients where US confirms polyarthritis.

8.8.3 Disease progression despite improvement

There is now more evidence that disease progression continues despite clinical assessment appearing to indicate disease improvement, or actual remission.

Rheumatoid arthritis

This study of 187 RA patients in clinical remission (modified ACR criteria) followed patients for two years (Molenaar, Voskuyl et al. 2004). Remission persisted in 52% of patients after two years; however the median Sharp/van der Heijde score for x-ray progression between baseline and 2 years was 0.5. Clinically relevant progression of damage occurred in 7% of patients with persistent remission,

leading the authors to conclude that even with a patient appearing to be in clinical remission, clinical vigilance and repeat x-ray measurement is required. This study adds to the work described earlier by Mulherin and colleagues (Mulherin, Fitzgerald et al. 1996).

Psoriatic arthritis

This study assessed 129 patients with PSA over a two year period (Kane, Stafford et al. 2003). They found that despite improvements in clinical parameters such as, HAQ and ESR, x-ray damage progressed.

8.8.4 Change in diagnosis

In a study of patients with a clinical diagnosis of chronic Achilles (24) or patellar (24) tendonitis, used US to guide either corticosteroid or placebo injection (Fredberg, Bolvig et al. 2004). At the baseline assessment US confirmed the clinical diagnosis in only one third of patients. This study whilst not setting out to assess the diagnostic input of US, again demonstrates the inaccuracy of clinical assessment.

8.8.5 Impact on planned foot injections

This study is similar to the work of this thesis in that patients referred for injection had US assessment blinded to clinical findings (d'Agostino, Ayral et al. 2005). This study used a better methodology by having two groups; in one group the physician was made aware of US findings and any change in management was documented, whereas in the second group the physician remained blinded to US findings until after injections were performed. In the group where the physician was informed of US findings this led to a change in the decision regarding local injection in 56 (82%) of 68 patients studied. Injection was cancelled in 37 (15%) of 242

proposed sites, whereas it was decided in 74 (8%) additional sites. Regarding outcome there was significant improvement in the unblinded group compared to the blinded group of patients which persisted to the end of the study at three months. This is an important study further investigating the impact of US on management, but also on outcome.

8.9 Summary

In this chapter we have demonstrated the clinical utility of US in patients who were referred by their attending consultant. Patients had a clinical assessment with the clinician documenting the likely pathologic diagnosis of the area in question, as well as the overall clinical diagnosis before US was performed. This study demonstrates that most referrals in our rheumatology practice were related to the assessment of small joints and the reason for referral is usually related to the detection of synovitis and tenosynovitis. In this study US altered the local SSD and overall management in half the patients assessed, and also led to a change in the overall diagnosis in approximately 1 out of 10 patients.

There have been many publications demonstrating the ability of US to detect changes in patients with specific conditions like RA and also for problems like plantar fasciitis and epicondylitis. This study also reflects the increasing trend of rheumatologists performing US, in the present case trained by musculoskeletal radiologists. Future investigations should include demonstrating outcomes between groups with access to US, and those without. This can be done for regional problems like those with injections in the ankle described by (d'Agostino, Ayril et al. 2005), in specific diagnostic groups like RA or involving all attendees to out-patient departments.

Chapter 9

9.1 Summary and Future Directions

In the last decade there has been a trend towards earlier more aggressive therapy for inflammatory arthritis using the adage that inflammation over time causes damage. This requires the assessing physician to be confident that they have made a reliable initial diagnosis prior to starting long-term potentially harmful treatment. This has inevitably led to physicians becoming interested in any modality that can be used to reliably detect a condition and then monitor response to therapy.

As the use of US has increased, there has been greater critical assessment of this technique particularly in academic units resulting in more evidence confirming its role in rheumatology practice. With increasing awareness of the technical requirements, and with portability of machines allowing direct visualisation of the area of interest to rheumatologists, more rheumatologists have taken on the role of performing US themselves. A good US assessment requires knowledge of the anatomy and potential pathology at the site of interest to avoid misinterpretation of normal anatomy, as well as an understanding of the clinical scenario leaving rheumatologists well placed to continue this work.

9.2 Summary of thesis

This thesis set out to determine the performance merits of US in rheumatology, by examining issues concerning validity, reliability and clinical utility.

9.2.1 Knee synovitis

In chapter 3 we confirm, using arthroscopy as the gold-standard, that US has a higher sensitivity, specificity, accuracy, positive- and negative-predictive value compared with clinical assessment. Ultrasonography also demonstrated good inter- and intra-reader reproducibility for detecting presence or absence of synovitis, as well as distinguishing the grade of synovitis, confirming that US is not only a valid and reproducible tool for detecting synovitis in the knee but also that it is more sensitive than clinical assessment. Another study by part of our group using the same arthroscopy technique as in this chapter on 60 patients with knee arthritis (32 with RA, 18 with PsA, and 10 with OA) demonstrated good correlation between global arthroscopic VAS for synovitis and synovial fluid matrix metalloproteinase 1 (Fraser, Fearon et al. 2003).

There is evidence that synovitis is common in knee OA (D'Agostino, Conaghan et al. 2005), US findings can relate to symptoms (Naredo, Cabero et al. 2005), and synovitis has a role in the symptoms and progression of knee arthritis (Ostergaard, Hansen et al. 1999; Ayril, Pickering et al. 2001; Ayril, Pickering et al. 2005).

Recent publications confirm the insensitivity of clinical assessment (Kane, Stafford et al. 2003; Conaghan, D'Agostino et al. 2005; D'Agostino, Conaghan et al. 2005), whilst demonstrating validity of US at detecting synovitis in the knee with

PD and bubble contrast (Fiocco, Ferro et al. 2003), and in large (Hermann, Backhaus et al. 2003) and small joints (Backhaus, Burmester et al. 2002; Terslev, Torp-Pedersen et al. 2003; Szkudlarek, Narvestad et al. 2004; Scheel, Hermann et al. 2006) including with contrast (Szkudlarek, Court-Payen et al. 2003) in RA. This suggests that US should be increasingly used in order to improve the diagnosis and management of patients with knee symptoms.

Further work in this area includes the need for more validation with histology for gray-scale and PD US, with and without bubble contrast, concentrating not only on the ability to measure small differences in synovial thickening or vascularity, but also the reliability to detect these particular changes. Semi-quantitative scoring is usually quicker than quantitative analysis and these need to be compared, so that semi-quantitative analysis allowing for quicker assessments could be used in the clinical setting. Longitudinal studies with reliability comparisons are required to properly assess the sensitivity of US to detect changes over time and monitor response to therapy. Work in assessing US pathology and corresponding sites of pain in OA, SPA and RA is very interesting and may lead to predictive validity studies in the longer term measure.

The clinical applicability of any gold standard is related to its pathogenic relevance, without which its prognostic capacity is diminished (Valenstein 1990). There is a paucity of studies to correlate arthroscopic synovitis with damage (Ayril, Pickering et al. 2001) and at present there is no firm evidence that correlates histological findings with clinical outcomes, in particular joint damage. While further validation with US is required, this too is an area that requires further investigation.

9.2.2 Accuracy of US-guided injections

In chapter 4 we confirm the accuracy of US-guided subacromial injections in patients with shoulder pain. In our study all our injections were intrabursal with 6/11 having a small extrabursal element as well, which we argue is the likely result of extravasation possibly related to the volume of injection (10mls).

Recent publications have added to the evidence for the accuracy of US placement (Esenyel, Esenyel et al. 2003), while novel ways of guiding injection are being demonstrated (Koski, Saarakkala et al. 2005), with US even being used to guide surgery (Testa, Capasso et al. 2002).

There is evidence suggesting that US-guided aspiration is better than clinical palpation-guided aspiration (Balint, Kane et al. 2002; Raza, Lee et al. 2003), and that US-guided injections are better than 'blind' injections in the shoulder (Galletti, Magnani et al. 2004; Naredo, Cabero et al. 2004; Chen, Lew et al. 2006) . This is not true for all sites with benefit from guided compared with 'blind' injections in one study (Tsai, Hsu et al. 2006) compared with no benefit in another (Kane, Greaney et al. 2001) for the injections of plantar fasciitis.

Further work needs to be done to determine the accuracy of injection technique using dissection and imaging modalities like CT including randomisation to guided or 'blind' injections to provide comparison. The volumes injected using 'blind' and guided techniques vary and this also requires further investigation to assess whether the volume of injection has an impact on the outcome. Thereafter, the impact of these more accurate injection techniques need to be assessed in randomised longitudinal studies using validated outcome measures.

9.2.3 Efficacy of US-guided hip injections

In chapter 5 we confirm that patients with moderate to severe hip OA can benefit in the medium-term from US-guided injection of corticosteroid. In this pilot study response was better in those with moderate OA. We also demonstrate that US findings, particularly effusion and lack of osteophytes, may predict those likely to respond. Subsequent work has confirmed the efficacy of corticosteroid in moderate, but not severe OA.

In an important study synovitis as defined by PD US (we used gray-scale only) correlated well with histology (Walther, Harms et al. 2002). In our study we indirectly guided and confirmed placement of injection with US. There is also evidence that us-guided hip injections are accurate from a study using contrast with CT to confirm 100% placement (Pourbagher, Ozalay et al. 2005).

The study by Margules and colleagues has found better outcomes in a larger group of patients (Margules 2001)), but their group while including patients with moderate and severe arthritis probably had less severe disease than our group who were all waiting hip replacement. It seems there is no role for corticosteroid injections at the other end of the severity spectrum, with no benefit in rapidly destructive hip OA (Villoutreix, Pham et al. 2006).

Future work should include a placebo-controlled randomised study of guided injection to remove 'placebo' response, and also include features that might predict response including highly sensitive CRP and also repeating US post injection to determine whether objective measures of synovitis change with symptoms. The data from our pilot study provide valuable baseline data for power calculations for future studies.

9.2.4 US synovitis in clinical remission

In chapter 6, we continue with one of the main themes of this thesis assessing the role of US in detecting synovitis in patients with low disease activity states or clinical remission. This study again demonstrates the insensitivity of clinical assessment and also the extent of sub-clinical disease present, even in this group in clinical remission, with widespread synovitis regardless of the type of remission criteria imposed. This in addition to reports that clinical measures of disease activity such as DAS do not always reflect clinical changes following therapy (Gardiner, Bell et al. 2005), suggests that US should be included in any future definition of remission.

The findings from this study may have a number of important pathophysiological implications. These data provide a possible pathological explanation for the paradoxical observation that patients in apparent remission may experience progression of joint damage (Mulherin, Fitzgerald et al. 1996; Molenaar, Voskuyl et al. 2004). In support of this a recent study has also demonstrated that US synovitis at baseline correlates with x-ray damage 1 year later in patients with RA receiving methotrexate (Taylor, Steuer et al. 2004).

Work is ongoing with this cohort to assess the long term outcome of sub-clinical disease. Healthy age-matched controls are required to differentiate between normal and abnormal perfusion, and while MRI has become the most common standard that US is compared with, findings should ideally be correlated with histology.

9.2.5 US synovitis is predictive of response

In chapter 7 we suggest a possible underlying inflammatory aetiology in many patients that present with symptoms, but no signs, to suggest inflammatory arthritis. In this study most had US-detected synovitis, the majority of whom had no evidence of synovitis on clinical assessment. Using the response to IM MP as a means of suggesting an underlying inflammatory process we demonstrated that US-detected synovitis was the best predictor of this response and also a predictor of subsequent response to HCQ.

This work provides an insight into the potential pathogenesis of this patient group suggesting along with other work in this thesis that clinical assessment is insensitive to subtle degrees of synovitis. The treatment algorithm we used is a practical way of managing this group of patients. A recent publication whilst demonstrating the short term efficacy of IM MP warns of the potential for adverse events with frequent injections (Choy, Kingsley et al. 2005).

Further work with this group of patients should include checking anti-ccp antibodies, and repeating highly sensitive CRP and US assessment to document any changes in these markers of inflammation following IM MP and determine whether any changes reflect response. Patients need to be randomised to receive placebo or IM MP to remove any placebo effect bias, and also to detect any significant side effects as described (Choy, Kingsley et al. 2005), and also to observe the natural progression and outcome of this group.

9.2.6 Clinical impact of US

In chapter 8 we demonstrate the clinical utility of US in patients who were referred by their attending consultant. Patients had a clinical assessment with the clinician documenting the likely pathologic diagnosis of the area in question, as well as the overall clinical diagnosis before US was performed. This study demonstrates that most referrals in our rheumatology practice were related to the assessment of small joints and the reason for referral is usually related to the detection of synovitis and tenosynovitis. In this study US altered the local site-specific diagnosis and overall management in half the patients assessed, and also led to a change in the overall diagnosis in approximately 1 out of 10 patients. This study also reflects the increasing trend of rheumatologists performing US, in the present case trained by musculoskeletal radiologists.

More recently the impact of US has been measured by blinding US reports in one group of patients (with the physician having access to reports and changing management if appropriate in the other) and comparing outcomes (d'Agostino, Ayril et al. 2005).

Further work is required with methods similar to the study above where under randomised control one cohort of patients receives the benefit of US input comparing outcome against validated measures. This can be performed for a specific area of interest like the ankle or shoulder, or in conditions like RA, and allows comparison with a control or 'placebo' group. In our study patients were originally referred for US due to a certain degree of clinical uncertainty so any outcome needs to take this into account. To avoid this referral bias and demonstrate the real impact of US in rheumatology practice requires all patients attending the service to be invited to take part in a study and be randomised to having their physician receiving

information gained from US or not. Long-term monitoring, particularly in chronic disease would be required using validated outcome measures to assess any impact on function.

9.3 What is the current role of US?

9.3.1 Synovitis

There is now increasing evidence in the literature to support the observation that US is superior to clinical assessment at detecting synovitis in small and large joints (Backhaus, Kamradt et al. 1999; Hau, Schultz et al. 1999; Kane, Balint et al. 2003; Luukkainen, Saltyshev et al. 2003; Szkudlarek, Court-Payen et al. 2003; Wakefield, Green et al. 2004; Luukkainen, Sanila et al. 2005; Naredo, Bonilla et al. 2005). Further studies have attempted to provide validation by comparison with other imaging techniques such as MRI, arthroscopy, scintigraphy and thermography (Ostergaard, Court-Payen et al. 1995; Backhaus, Kamradt et al. 1999; Backhaus, Burmester et al. 2002), including one which suggested that inflammatory arthritis US may even be more sensitive than MRI at detecting synovitis in finger joints (Backhaus, Kamradt et al. 1999).

More recently additional US techniques such as Power Doppler or contrast-enhanced Doppler have become available potentially improving the accuracy of US by differentiating between hypervascular (active) and fibrotic (inactive) synovial thickening or pannus in patients with established disease. Observational studies comparing PD with traditional gray-scale US and clinical disease activity assessments seemed to have confirmed this (Hau, Schultz et al. 1999; Weidekamm, Koller et al. 2003).

Validity has been assessed by comparison with histopathology in hip joints due for arthroplasty (Walther, Harms et al. 2002), in knee OA and RA (Schmidt, Volker et al. 2000; Walther, Harms et al. 2001); and with dynamic MRI in RA of the MCP (Szkudlarek, Court-Payen et al. 2001; Terslev, Torp-Pedersen et al. 2003) and MTP joints (Szkudlarek, Narvestad et al. 2004). Power Doppler has also been used

to assess disease activity in RA (Hau, Schultz et al. 1999; Qvistgaard, Rogind et al. 2001; Carotti, Salaffi et al. 2002; Weidekamm, Koller et al. 2003) as well as monitor response to treatment (Newman, Laing et al. 1996; Hau, Schultz et al. 1999; Stone, Bergin et al. 2001; Teh, Stevens et al. 2003; Terslev, Torp-Pedersen et al. 2003; Fiocco, Ferro et al. 2005).

Intravenous microbubble echo contrast agents increase the intensity of weak signals to a potentially detectable level, possibly further increasing the sensitivity of PD. Most studies that have assessed this have reported an increase in Doppler signal (Magarelli, Guglielmi et al. 2001; Qvistgaard, Rogind et al. 2001; Klauser, Frauscher et al. 2002; Fiocco, Ferro et al. 2003) with the exception of one notable study (Szkudlarek, Court-Payen et al. 2003). Contrast enhanced MRI has also been used and in one study (Magarelli, Guglielmi et al. 2001) confirmed concordance in all cases. In the knee echo contrast enhanced PD has been compared with arthroscopy demonstrating a higher sensitivity, but a lower specificity (Fiocco, Ferro et al. 2003).

There are to my knowledge only 2 reports of cohorts with any sequential assessment of synovitis with US. One group published results after 2 (Backhaus, Burmester et al. 2002) and 7 years (Scheel, Hermann et al. 2006). In this study reductions in levels of synovitis were documented which were comparable to MRI and also reflected in clinical and laboratory assessments. The other study with 6 months between assessments revealed conflicting data with US having less synovitis at base line, and more synovitis after 6 months compared with MRI, but detecting more effusions than MRI at both time points (Hoving, Buchbinder et al. 2004).

9.3.2 Erosions

X-ray documented bone erosions are used to help with a diagnosis of RA, but these changes are often absent in early disease. Ultrasonography has consistently demonstrated greater sensitivity than x-ray at detecting erosions in the hand, wrists, feet and shoulder (Alasaarela, Suramo et al. 1998; Backhaus, Kamradt et al. 1999; Wakefield, Gibbon et al. 2000; Grassi, Filippucci et al. 2001; Klocke, Glew et al. 2001; Szkudlarek, Court-Payen et al. 2001; Hermann, Backhaus et al. 2003; Weidekamm, Koller et al. 2003; Lopez-Ben, Bernreuter et al. 2004).

A particular benefit seems to be in early disease where US is able to detect 6.5 x more erosions in early disease, compared with 3.4 x more erosions in established disease compared with x-ray (Wakefield, Gibbon et al. 2000). This is possibly explained by the, relative to x-ray, high resolution and the multi planar nature of US assessment lending to it able to detect small lesions.

Other studies have shown that US may be less sensitive than MRI at detecting bony erosions in the shoulder (Alasaarela, Suramo et al. 1998; Hermann, Backhaus et al. 2003), and the knee (Ostergaard, Court-Payen et al. 1995) although this may be less important regarding diagnosis. Another study demonstrated that US was less sensitive than x-ray at detecting central erosions in the DIP joints of patients with inflammatory osteoarthritis (Iagnocco, Filippucci et al. 2005).

The same cohorts described in synovitis have been assessed for longitudinal progression of erosions. Over both the 2 (Backhaus, Burmester et al. 2002) and 7 year (Scheel, Hermann et al. 2006) period, progression of erosions was seen more often on US and MRI than x-ray. By 7 years many erosions previously undetected by x-ray, but present on US and MRI were detectable on x-ray. This suggests that while x-ray may be less sensitive at detecting erosions early in disease compared

with US and MRI, in time perhaps as the size of erosions increase x-ray detects these changes. Likewise US detected less erosions than MRI early on and many of these erosions were subsequently detected by US, suggesting that when MRI lesions erode cortical bone US where it has access will detect these. In the second cohort (Hoving, Buchbinder et al. 2004) erosions progressed over a 6 month period, however US identified less erosions than either MRI or x-ray.

That US is relatively less sensitive in established disease suggests either x-ray 'catches up' with US as erosions become larger, or that especially in a complex joint like the wrist as more damage occurs and the joint becomes disrupted it becomes more difficult for US to differentiate between additional bone and erosion. Our experience suggests US in the wrist becomes considerably difficult to monitor erosions in the extensively damaged wrist.

9.3.3 Monitoring response to therapy

Ultrasonography has been used to monitor outcome following the different treatment interventions in different cohorts of inflammatory arthritis patients. Many studies have shown a reduction in US markers of synovial inflammation including gray-scale and PD parameters after different treatments in the hand (Spiegel, King et al. 1987; Newman, Laing et al. 1996; Stone, Bergin et al. 2001; Hau, Kneitz et al. 2002; Teh, Stevens et al. 2003; Terslev, Torp-Pedersen et al. 2003) and knee (van Holsbeeck, van Holsbeeck et al. 1988; Rubaltelli, Fiocco et al. 1994; Fiocco, Cozzi et al. 1996; Newman, Laing et al. 1996; Gratz, Gobel et al. 1999; Salaffi, Carotti et al. 2004; Fiocco, Ferro et al. 2005). This suggests that US is sensitive enough to detect often subtle but clinically important changes in response to treatment, but without any studies confirming the reliability of detecting these changes (i.e. no evidence of discriminant validity).

9.3.4 Disease activity assessment

With the increasing conviction that imaging led disease activity scores are more sensitive and reliable, and more sensitive at detecting changes in assessment of synovitis and/or damage following therapy, some groups have suggested US assessment scores for inflammatory arthritis.

One such study set out to develop a simplified US assessment scoring system for assessment of the MCP and PIP joints in patients with RA (Scheel, Hermann et al. 2005). The authors conclude that US assessment of finger joint synovitis could be simplified by examining the palmar side of 2nd, 3rd and 4th MCP and PIP joints on one hand, applying a semi-quantitative grading measurement. Despite assessing just

under 50 patients this study demonstrated good concurrent validity with the semi-quantitative US method revealing high concordance with MRI.

A 12 joint assessment for overall disease activity in RA has also been proposed (Naredo, Gamero et al. 2005). In this study a 60 joint clinical and US scoring system in patients with RA were initially compared. Joint effusion, joint synovitis and PD signal were graded from 0 to 3 in all joints scored with US. Reduced US joints counts were then compared against the overall 60 joint count for correlation. The 60 joint US count was then compared against smaller joint count versions. They found that a 12 joint assessment for effusion, synovitis and PD signal which included wrists, knees, and bilateral second and third MCP, and bilateral second and third PIP joints correlated well with the overall 60 joint count.

In SpA, an enthesal pathology scoring system has been suggested (Balint, Kane et al. 2002). This study comparing clinical with US assessment of both lower limbs demonstrated that US was more sensitive at detecting enthesal changes than clinical assessment. The 5 sites they assessed were the common superior and inferior pole of patella, tibial tuberosity, achilles tendon, and plantar aponeurosis. At each site US was used to detect bursitis, structural thickness, bony erosion, and enthesophyte (bone spur). The intra-observer kappa value for US analysis was 0.9.

Wakefield and colleagues demonstrated a significant proportion of patients with a clinical diagnosis of oligoarthritis (≤ 5 joints) had US-detected polyarthritis (Wakefield, Green et al. 2004). They suggest a standard assessment technique including examination of all painful, but also certain other joints (e.g. MTP joints) even if asymptomatic. This work would suggest that US assessment has a significant role to play in the management of patients with clinical oligoarthritis. In this group further assessment of this role for US is required; including what impact US would

have on the patient's actual management, particularly its impact on injection or DMARD therapy, but also more importantly in the longer term, to assess whether this change will have any impact on long term outcome.

Regarding disease assessment the main issue in the longer term is to determine whether these assessments are accurate and reliable in detecting changes over time. A particular difficulty with this is to define the most appropriate standard with which to compare US. Histological analysis is the ideal, but requires an invasive procedure and for detecting synovitis MRI may be the most practical modality. For outcome, validated functional endpoints such as HAQ and RAQOL may be appropriate or otherwise pragmatic investigations may use specific outcomes such as work instability, unemployment or arthroplasty.

9.3.5 Prediction of outcome

There are limited data on the US findings as a predictor of future outcome. A study comparing US-detected synovitis with findings at arthroscopy in patients undergoing arthroscopic synovectomy, demonstrated that US joint effusion at baseline was significantly increased in patients who relapsed, suggesting US could be used to predict relapse following synovectomy (Fiocco, Cozzi et al. 1996). In another study in early RA (Taylor, Steuer et al. 2004), baseline US measurements of synovial thickening and vascularity in MCP joints correlated with degree of x-ray joint damage 1 year later. There have been interesting developments in the arena of sites of pain with US findings in knee OA correlating with severity of pain (Naredo, Cabero et al. 2005).

9.3.6 Reliability

A charge that is often made against US is that it is user dependent and outcome will depend on the level of skill of the operator. In response to this there are an increasing number of reliability studies in the literature. As with the findings of our study discussed in chapter 6, good levels of inter- and intra- observer reliability have been demonstrated for assessing synovitis in the wrist and small joints of the hands and feet (Ostergaard, Klarlund et al. 2001; Qvistgaard, Rogind et al. 2001; Ribbens, Andre et al. 2003; Szkudlarek, Court-Payen et al. 2003) as well as another study only assessing intra-observer reliability again with good correlation (Backhaus, Burmester et al. 2002). Two of these studies (Qvistgaard, Rogind et al. 2001; Szkudlarek, Court-Payen et al. 2003) assessed PD US. We have already described, in chapter 3, using gray-scale US with good inter-and intra-observer reliability. Using PD US good levels of inter-observer agreement for PD synovitis have also been demonstrated (Schmidt, Volker et al. 2000; Fiocco, Ferro et al. 2003).

Likewise for erosions in the hand there has been good correlation demonstrated for inter- and intra-observer reliability (Wakefield, Gibbon et al. 2000) and also for intra-observer reliability only (Backhaus, Burmester et al. 2002). In enthesitis good intra-observer reliability has been demonstrated (Balint, Kane et al. 2002), whereas in the shoulder for cuff tears agreement has varied depending on the degree of expertise in one study (O'Connor, Rankine et al. 2005), but with good inter-observer reliability in another study (Swen, Jacobs et al. 1999). Future work should improve the general reliability of US assessment and improve standardisation of assessment techniques, setting out agreed definitions of pathology as well as using standard US scoring criteria.

9.3.7 US pathology

Ultrasonography is not only demonstrating signs better than clinical assessment, but the technology being applied is also giving insight into pathogenesis of disease. One example is in a study of plantar fasciitis where hyperaemia was found with PD US in the plantar fascia and the surrounding soft tissue along the first cm distally from the insertion in patients not present in controls (Walther, Radke et al. 2004). A separate study demonstrated increased thickness and reduced echogenicity of the plantar fascia in symptomatic heels compared with asymptomatic heels (Kane, Greaney et al. 1998) giving some indication as to the underlying vascular and inflammatory component of the condition.

With the ever increasing improvements in resolution visualising the qualities of tendon, and nerve as well as the measurement of skin thickness are becoming a reality.

9.4 Future directions

While US has thus far demonstrated much promise in rheumatology practice, there are still many areas that require further investigation.

9.4.1 Standardised image acquisition, definitions of pathology

Key advances in this area were made when the EULAR working group published guidelines on set assessment techniques for US in Rheumatology addressing technical issues, training, and standardisation of image acquisition (Backhaus, Burmester et al. 2001). The OMERACT US specialist interest group have recently proposed for the first time a consensus set of US definitions for common pathological lesions seen in Rheumatology practice, which in conjunction with the EULAR assessment guidelines provide a template for future studies assessing these standardisations (Wakefield, Balint et al. 2005).

In the quest for ongoing training, standardisation of assessment techniques, and defining pathology, the EULAR working group for musculoskeletal US have been meeting and recently used a method of scoring stored images independent of each other, thereafter meeting and discussing scoring methods to develop consensus (Naredo, Moller et al. 2006). This allows standardisation of techniques at an expert level, hopefully allowing this to be disseminated as those experts return to their particular bases.

More needs to be done to ensure that methods of image acquisition are uniform, and of the highest quality. This requires an understanding of the physical principles of US, standardised assessment techniques and even standardised machine settings for specific assessments. The definitions that have only recently been agreed will no doubt require further modification with time, particularly after

more reliability data becomes available. Working groups like OMERACT are essential in ensuring that as more rheumatologists take on performing US that assessment techniques remain standardised and that widely accepted definitions are used. This will not only provide for more consistent diagnosis, but also allow easier comparison between studies.

9.4.2 Validation of new technologies

Newer techniques will require validation, preferably with histological analysis to determine the validity of US detected synovitis. A potential limitation of gray-scale US is that it primarily detects synovial hypertrophy which although reversible in early disease may not be so in established disease when the synovial membrane may become chronically thickened and fibrotic. For this reason, gray-scale US changes alone may not necessarily reflect active inflammation i.e. synovitis. The presence of increased PD signal signifies increased vascularity associated with active inflammation and may be more representative of true synovitis making it potentially more useful in established RA.

It remains to be seen whether the specificity of US for synovitis in established disease may be improved by performing simultaneous PD assessment. Longitudinal studies including reliability assessments are required to assess the sensitivity of US to small changes in activity, providing a true reflection of the discriminant validity of the combination of the US machine with technology like PD with bubble-contrast enhancement. Ideally machines would undergo a standardised assessment to determine the reliability of detecting the pathology in question which would then be documented as a feature of the machine much like axial resolution is currently noted.

9.4.3 Reliability of US machines

One of the key difficulties facing US is the many different types of equipment with very little data comparing ability to detect pathology and assessing reliability between machines. This is a problem facing most advancing technologies and with a profit driven industry it will be difficult to get companies to submit to truly independent standardised assessments.

9.4.4 How much synovitis does it take to damage?

The role of US in predicting sub-clinical synovitis has already been discussed in this thesis and is potentially one of the areas that US may have a big impact. The predictive ability of US in cohorts not dissimilar to ours, centred on synovitis and early erosion detection needs to be further evaluated. In practice we are now seeing that at every level of clinical inflammation US seems to be more sensitive, from patients with inflammatory hand pain, to clinical oligoarthritis being reclassified to polyarthritis with US assessment, to significant levels of synovitis detected in clinical remission. The question that needs answering is how much of this synovitis matters and if so, is there a particular cut off above which disease progression is likely, or below which this is unlikely. These are questions that only well planned longitudinal studies have the ability to answer.

9.4.5 Are the requirements for US the same for different conditions?

One of the issues that requires further clarification is whether the technical requirements and impact are similar in different conditions. A simple example is RA where pathology is primarily synovial and as such requires a small footprint transducer that can provide good access to the smaller joints as opposed to assessing patients with hip OA where a larger curvilinear probe maybe more appropriate. In early disease gray-scale detected synovitis is likely to be specific, although perhaps less sensitive than PD with or without contrast, whereas in established disease gray-scale has difficulty differentiating between fibrotic (inactive) and active pannus and should benefit from the addition of PD.

Being able to ascertain what the main function of the equipment is going to be is helpful in determining the type of equipment required; for ward work primarily used to detect and guide aspiration of effusion for example a portable machine with only moderate quality Doppler ability (to avoid vascular structures) is acceptable, but this is likely to be inadequate for monitoring small joints in inflammatory arthritis.

In oligoarthritis our group has already demonstrated that US alters the diagnosis to a polyarthritis in over a third of patients. This suggests that US is a useful standardised method for assessing this patient group (Wakefield, Green et al. 2004).

Likewise there are similar assessment techniques for monitoring disease activity in the hand (Walther, Radke et al. 2004) and overall disease in RA with a 12 joint US count representative of a 60 joint US count (Naredo, Gamero et al. 2005), as well as measures in SpA (Balint, Kane et al. 2002). Further studies are required to validate all these measures.

9.4.6 Are the requirements for US the same in clinical practice and research?

The same applies to different working environments. A rheumatologist working in a small group will find it difficult to use US routinely in their clinical setting unless consideration of the time this takes is made. The practical solution would be to have a set clinic for performing US which maximises the usefulness of the machine, and also allows sharing of equipment with other departments. The obvious disadvantage of this is that patients have to return for this investigation.

In a large academic unit it would be easier to have one operator using the machine while the rest of the team perform their outpatient work, and if clinical trials are part of the units' workload then specific time will need to be set aside for this bearing in mind clinical research assessments are usually longer. The technical requirement of the machine will also differ in this setting requiring a 'top-end' machine which in practice means a cost greater than £50, 000.

9.4.7 Other advances: what is the opposition?

Advances in technology are not limited to US and the last few years have seen massive advances in MRI technology with low-field MRI units becoming available. These usually are in the range of 0.2 -0.5 Tesla, compared with standard high field MRI of 1.5 Tesla. These have the advantage over high-field MRI of patient comfort (high-field MRI of MCP requires the patient lying prone in 'superman position' for up to 45 minutes), less noise, less contraindications, less space and shielding required, less maintenance, not to mention less cost!

The drawback of low field MRI is its low MR signal because the signal-to-noise ratio is proportional to the field strength; the stronger the field, the stronger the signal. Other disadvantages are reduced field of view (for example the 'Magnaview' can image only 2-3 MCPs), and less resolution.

As with US, improvements in technology are such that, using a high sensitivity radio frequency coil with high-temperature superconductors (better receiver) the problem of a weak signal can be overcome. This new technology can result in an increased signal to noise ratio of more than 100%. It is not unrealistic to expect that in a few years low-field units will be seen in outpatient departments in the UK.

Improvements in technology of another kind are likely to have an impact on US soon. Portable machines are improving all the time and with better technology transducer elements that 'plug and play' in modified laptops are not far away. The question regarding the future of US is not so much about competition from other modalities rather how much US itself will adapt to these changes in technology.

9.4.8 Who should perform US?

In the last decade there has been a trend towards earlier more aggressive therapy for inflammatory arthritis using the adage that inflammation over time causes damage. This requires the assessing physician to be confident that they have made a reliable initial diagnosis prior to starting long-term potentially harmful treatment. This has inevitably led to physicians becoming interested in any modality, imaging or otherwise, that can be used to detect a condition and then monitor response to therapy.

The specific role of US in standard rheumatological practice is increasing as a result of easier access due to portable US machines, lack of ionising radiation, relatively low costs and improved technology making US more amenable to assess smaller joints. Direct visualisation of the area of interest with US is extremely valuable for both diagnostic and therapeutic reasons. As the use of US becomes more widespread and machines become more portable, and interest, particularly in academic units increases, more rheumatologists are taking on the role of performing US themselves.

The technical requirements for US have already been discussed, but it is important to point out that in conjunction with quality US equipment, a good US assessment requires knowledge of the anatomy at the site of interest to avoid misinterpretation of normal anatomy, as well as understanding of the clinical scenario. This has led to clinicians claiming that they, rather than an independent radiologist are best suited to do this.

In the shoulder there is evidence that US performed by an experienced radiologist and rheumatologist is reliable in assessing the rotator cuff (Swen, Jacobs et al. 1999), although another study amongst radiologists suggests that experience is important for maintaining good reliability (O'Connor, Rankine et al. 2005); while in the small joints there is good reliability between an experienced radiologist and a rheumatologist with limited training, but working to predetermined definitions (Szkudlarek, Court-Payen et al. 2003) .

This confirms what is really important is not who should do it, but rather whether an individual is competent to perform US. Again standardised assessment and definitions seem to produce good results, even in a relatively inexperienced operator.

9.4.9 Training

As a result of the increasing use of US in rheumatology more Rheumatologists are requesting training (Wakefield, Goh et al. 2003) and organisations like the BSR and EULAR are now providing teaching programmes differentiated by operator expertise. Different training techniques have been suggested ranging from a self taught programme after a 2 hour introduction (Filippucci, Unlu et al. 2003) or an informal team approach (Taggart, Filippucci et al. 2006), to a more didactic focused system (D'Agostino, Maillefert et al. 2004). The study described in the previous paragraph is significant, and highlights the need for standardised assessment and clear definitions. One novel training programme involved the use of remote assistance to train non physician crew members how to perform US of the shoulder in space (Fincke, Padalka et al. 2005).

There have also been increasing efforts to determine exact requirements for rheumatology US training with collaboration from world-wide experts (Brown, O'Connor P et al. 2005) leading to the design of specific competency based educational outcomes (Brown, O'Connor et al. 2006). This takes into account criteria that all experts agree are a requirement for competency to be demonstrated. The next important phase of this work is to develop better clinical governance with means of certification, ongoing training, assessment and accountability.

9.5 Conclusion

In conclusion, the studies discussed in this thesis provide new insights into the role of US in the investigation and management of rheumatic conditions. This thesis explores different potential roles for US, from establishing criterion and construct validity to reproducibility and predictive validity of the technique. This thesis demonstrates that US, while still requiring further investigation, is important in the day to day running of a rheumatology practice.

References

- ACR subcommittee (2000). "Recommendations for the medical management of osteoarthritis of the hip and knee: 2000 update. American College of Rheumatology Subcommittee on Osteoarthritis Guidelines.[see comment]." Arthritis & Rheumatism **43**(9): 1905-15.
- Aisen, A. M., W. J. McCune, et al. (1984). "Sonographic evaluation of the cartilage of the knee." Radiology **153**(3): 781-4.
- Alasaarela, E., J. Leppilahti, et al. (1998). "Ultrasound and operative evaluation of arthritic shoulder joints." Annals of the Rheumatic Diseases **57**(6): 357-60.
- Alasaarela, E., I. Suramo, et al. (1998). "Evaluation of humeral head erosions in rheumatoid arthritis: a comparison of ultrasonography, magnetic resonance imaging, computed tomography and plain radiography." British Journal of Rheumatology **37**(11): 1152-6.
- Alasaarela, E., R. Takalo, et al. (1997). "Sonography and MRI in the evaluation of painful arthritic shoulder." British Journal of Rheumatology **36**(9): 996-1000.
- Alasaarela, E., O. Tervonen, et al. (1997). "Ultrasound evaluation of the acromioclavicular joint." Journal of Rheumatology **24**(10): 1959-63.
- Alasaarela, E. M. and E. L. Alasaarela (1994). "Ultrasound evaluation of painful rheumatoid shoulders." Journal of Rheumatology **21**(9): 1642-8.
- Altman, R., G. Alarcon, et al. (1991). "The American College of Rheumatology criteria for the classification and reporting of osteoarthritis of the hip.[see comment]." Arthritis & Rheumatism **34**(5): 505-14.
- American College of Rheumatology Subcommittee on Rheumatoid Arthritis, G. (2002). "Guidelines for the management of rheumatoid arthritis: 2002 Update.[see comment]." Arthritis & Rheumatism **46**(2): 328-46.
- Andonopoulos, A. P., S. Yarmenitis, et al. (1995). "Baker's cyst in rheumatoid arthritis: an ultrasonographic study with a high resolution technique." Clinical & Experimental Rheumatology **13**(5): 633-6.
- Arnett, F. C., S. M. Edworthy, et al. (1988). "The American Rheumatism Association 1987 revised criteria for the classification of rheumatoid arthritis." Arthritis & Rheumatism **31**(3): 315-24.
- Ayral, X., E. H. Pickering, et al. (2001). "Synovitis predicts the arthroscopic progression of medial tibiofemoral osteoarthritis." Arthritis & Rheumatism **44**: S101.
- Ayral, X., E. H. Pickering, et al. (2005). "Synovitis: a potential predictive factor of structural progression of medial tibiofemoral knee osteoarthritis -- results of a 1 year longitudinal arthroscopic study in 422 patients." Osteoarthritis & Cartilage **13**(5): 361-7.
- Backhaus, M., G. R. Burmester, et al. (2001). "Guidelines for musculoskeletal ultrasound in rheumatology." Annals of the Rheumatic Diseases **60**(7): 641-9.
- Backhaus, M., G. R. Burmester, et al. (2002). "Prospective two year follow up study comparing novel and conventional imaging procedures in patients with arthritic finger joints.[see comment]." Annals of the Rheumatic Diseases **61**(10): 895-904.

- Backhaus, M., T. Kamradt, et al. (1999). "Arthritis of the finger joints: a comprehensive approach comparing conventional radiography, scintigraphy, ultrasound, and contrast-enhanced magnetic resonance imaging." Arthritis & Rheumatism **42**(6): 1232-45.
- Baeten, D., P. Demetter, et al. (2000). "Comparative study of the synovial histology in rheumatoid arthritis, spondyloarthropathy, and osteoarthritis: influence of disease duration and activity.[see comment]." Annals of the Rheumatic Diseases **59**(12): 945-53.
- Balint, P. V., D. Kane, et al. (2002). "Ultrasound guided versus conventional joint and soft tissue fluid aspiration in rheumatology practice: a pilot study." Journal of Rheumatology **29**(10): 2209-13.
- Balint, P. V., D. Kane, et al. (2002). "Ultrasonography of enthesal insertions in the lower limb in spondyloarthropathy." Annals of the Rheumatic Diseases **61**(10): 905-10.
- Balsa, A., L. Carmona, et al. (2004). "Value of Disease Activity Score 28 (DAS28) and DAS28-3 compared to American College of Rheumatology-defined remission in rheumatoid arthritis.[see comment]." Journal of Rheumatology **31**(1): 40-6.
- Barnes, P. J. (1998). "Anti-inflammatory actions of glucocorticoids: molecular mechanisms." Clinical Science **94**(6): 557-72.
- Batalov, A., S. Kuzmanova, et al. (1999). "Ultrasound follow-up study of arthroscoped patients with gonitis." Folia Medica (Plovdiv) **41**(2): 63-70.
- Beals, T. C., D. T. Harryman, 2nd, et al. (1998). "Useful boundaries of the subacromial bursa." Arthroscopy **14**(5): 465-70.
- Blomley, M. J., J. C. Cooke, et al. (2001). "Microbubble contrast agents: a new era in ultrasound." BMJ **322**(7296): 1222-5.
- Blyth, T., J. A. Hunter, et al. (1994). "Pain relief in the rheumatoid knee after steroid injection. A single-blind comparison of hydrocortisone succinate, and triamcinolone acetonide or hexacetonide." British Journal of Rheumatology **33**(5): 461-3.
- Boers, M., P. J. Kostense, et al. (2001). "Inflammation and damage in an individual joint predict further damage in that joint in patients with early rheumatoid arthritis." Arthritis & Rheumatism **44**(10): 2242-6.
- Boers, M., A. C. Verhoeven, et al. (1997). "Randomised comparison of combined step-down prednisolone, methotrexate and sulphasalazine with sulphasalazine alone in early rheumatoid arthritis.[see comment][erratum appears in Lancet 1998 Jan 17;351(9097):220]." Lancet **350**(9074): 309-18.
- Brown, A., Z. Karim, et al. (2001). "The use of ultrasonography in soft tissue corticosteroid injection." Rheumatology **40**: S130.
- Brown, A. K., J. O'Connor P, et al. (2005). "Recommendations for musculoskeletal ultrasonography by rheumatologists: setting global standards for best practice by expert consensus.[see comment]." Arthritis & Rheumatism **53**(1): 83-92.
- Brown, A. K., P. J. O'Connor, et al. (2006). "Ultrasonography for rheumatologists: the development of specific competency based educational outcomes." Annals of the Rheumatic Diseases **65**(5): 629-36.
- Bryant, L. R., K. F. des Rosier, et al. (1995). "Hydroxychloroquine in the treatment of erosive osteoarthritis." Journal of Rheumatology **22**(8): 1527-31.

- Calis, M., K. Akgun, et al. (2000). "Diagnostic values of clinical diagnostic tests in subacromial impingement syndrome." Annals of the Rheumatic Diseases **59**(1): 44-7
- Carotti, M., F. Salaffi, et al. (2002). "Power Doppler sonography in the assessment of synovial tissue of the knee joint in rheumatoid arthritis: a preliminary experience.[see comment]." Annals of the Rheumatic Diseases **61**(10): 877-82.
- Chen, M. J., H. L. Lew, et al. (2006). "Ultrasound-guided shoulder injections in the treatment of subacromial bursitis." American Journal of Physical Medicine & Rehabilitation **85**(1): 31-5.
- Choy, E. H., G. H. Kingsley, et al. (2005). "A two year randomised controlled trial of intramuscular depot steroids in patients with established rheumatoid arthritis who have shown an incomplete response to disease modifying antirheumatic drugs." Annals of the Rheumatic Diseases **64**(9): 1288-93.
- Cicak, N., T. Matasovic, et al. (1992). "Ultrasonographic guidance of needle placement for shoulder arthrography." Journal of Ultrasound in Medicine **11**(4): 135-7.
- Clark, P., E. Casas, et al. (1993). "Hydroxychloroquine compared with placebo in rheumatoid arthritis. A randomized controlled trial.[see comment]." Annals of Internal Medicine **119**(11): 1067-71.
- Claudon, M., F. Tranquart, et al. (2002). "Advances in ultrasound." European Radiology **12**(1): 7-18.
- Conaghan, P., M. A. D'Agostino, et al. (2005). "EULAR report on the use of ultrasonography in painful knee osteoarthritis. Part 2: exploring decision rules for clinical utility." Annals of the Rheumatic Diseases **64**(12): 1710-4.
- Conaghan, P. G., P. O'Connor, et al. (2003). "Elucidation of the relationship between synovitis and bone damage: a randomized magnetic resonance imaging study of individual joints in patients with early rheumatoid arthritis." Arthritis & Rheumatism **48**(1): 64-71.
- Creamer, P. (1997). "Intra-articular corticosteroid injections in osteoarthritis: do they work and if so, how?" Annals of the Rheumatic Diseases **56**(11): 634-6.
- Cruickshank, B. (1952). "Interpretation of multiple biopsies of synovial tissue in rheumatic diseases." Ann Rheum Dis **11**: 137-145.
- d'Agostino, M. A., X. Ayril, et al. (2005). "Impact of ultrasound imaging on local corticosteroid injections of symptomatic ankle, hind-, and mid-foot in chronic inflammatory diseases." Arthritis & Rheumatism **53**(2): 284-92.
- D'Agostino, M. A., P. Conaghan, et al. (2005). "EULAR report on the use of ultrasonography in painful knee osteoarthritis. Part 1: prevalence of inflammation in osteoarthritis." Annals of the Rheumatic Diseases **64**(12): 1703-9.
- D'Agostino, M. A., J. F. Maillefert, et al. (2004). "Detection of small joint synovitis by ultrasonography: the learning curve of rheumatologists." Annals of the Rheumatic Diseases **63**(10): 1284-7.
- D'Agostino, M. A., R. Said-Nahal, et al. (2003). "Assessment of peripheral enthesitis in the spondylarthropathies by ultrasonography combined with power Doppler: a cross-sectional study.[see comment]." Arthritis & Rheumatism **48**(2): 523-33.

- de Jong, Z., D. van der Heijde, et al. (1997). "The reliability and construct validity of the RAQoL: a rheumatoid arthritis-specific quality of life instrument." British Journal of Rheumatology 36(8): 878-83.
- De Maeseneer, M., J. A. Jacobson, et al. (1998). "Elbow effusions: distribution of joint fluid with flexion and extension and imaging implications." Investigative Radiology 33(2): 117-25.
- Disler, D. G., E. Raymond, et al. (2000). "Articular cartilage defects: in vitro evaluation of accuracy and interobserver reliability for detection and grading with US." Radiology 215(3): 846-51.
- Donald I, M. J., Brown TG (1958). "Investigation of abdominal masses by pulsed ultrasound." Lancet: 1188-95.
- Dougados, M., S. van der Linden, et al. (1991). "The European Spondylarthropathy Study Group preliminary criteria for the classification of spondylarthropathy.[see comment]." Arthritis & Rheumatism 34(10): 1218-27.
- Dugowson, C. E., J. L. Nelson, et al. (1990). "Evaluation of the 1987 revised criteria for rheumatoid arthritis in a cohort of newly diagnosed female patients." Arthritis & Rheumatism 33(7): 1042-6.
- Eberhardt, K., E. Fex, et al. (1995). "Hip involvement in early rheumatoid arthritis." Annals of the Rheumatic Diseases 54(1): 45-8.
- Eberl, D. R., V. Fasching, et al. (1976). "Repeatability and objectivity of various measurements in rheumatoid arthritis. A comparative study." Arthritis & Rheumatism 19(6): 1278-86.
- Egsmose, C., B. Lund, et al. (1995). "Patients with rheumatoid arthritis benefit from early 2nd line therapy: 5 year followup of a prospective double blind placebo controlled study." Journal of Rheumatology 22(12): 2208-13.
- Emery, P. (1994). "The Roche Rheumatology Prize Lecture. The optimal management of early rheumatoid disease: the key to preventing disability." British Journal of Rheumatology 33(8): 765-8.
- Emery, P. and M. Salmon (1995). "Early rheumatoid arthritis: time to aim for remission?" Annals of the Rheumatic Diseases 54(12): 944-7.
- Esenyel, C. Z., M. Esenyel, et al. (2003). "[The correlation between the accuracy of steroid injections and subsequent shoulder pain and function in subacromial impingement syndrome]." Acta Orthopaedica et Traumatologica Turcica 37(1): 41-5.
- Eustace, J. A., D. P. Brophy, et al. (1997). "Comparison of the accuracy of steroid placement with clinical outcome in patients with shoulder symptoms." Annals of the Rheumatic Diseases 56(1): 59-63.
- Filippucci, E., Z. Unlu, et al. (2003). "Sonographic training in rheumatology: a self teaching approach." Annals of the Rheumatic Diseases 62(6): 565-7.
- Fincke, E. M., G. Padalka, et al. (2005). "Evaluation of shoulder integrity in space: first report of musculoskeletal US on the International Space Station." Radiology 234(2): 319-22.
- Fiocco, U., L. Cozzi, et al. (1996). "Arthroscopic synovectomy in rheumatoid and psoriatic knee joint synovitis: long-term outcome." British Journal of Rheumatology 35(5): 463-70.

- Fiocco, U., L. Cozzi, et al. (1996). "Long-term sonographic follow-up of rheumatoid and psoriatic proliferative knee joint synovitis." British Journal of Rheumatology 35(2): 155-63.
- Fiocco, U., F. Ferro, et al. (2003). "Contrast medium in power Doppler ultrasound for assessment of synovial vascularity: comparison with arthroscopy." Journal of Rheumatology 30(10): 2170-6.
- Fiocco, U., F. Ferro, et al. (2005). "Rheumatoid and psoriatic knee synovitis: clinical, grey scale, and power Doppler ultrasound assessment of the response to etanercept." Annals of the Rheumatic Diseases 64(6): 899-905.
- Fraser, A., U. Fearon, et al. (2003). "Turnover of type II collagen and aggrecan in cartilage matrix at the onset of inflammatory arthritis in humans: relationship to mediators of systemic and local inflammation." Arthritis & Rheumatism 48(11): 3085-95.
- Fredberg, U., L. Bolvig, et al. (2004). "Ultrasonography as a tool for diagnosis, guidance of local steroid injection and, together with pressure algometry, monitoring of the treatment of athletes with chronic jumper's knee and Achilles tendinitis: a randomized, double-blind, placebo-controlled study." Scandinavian Journal of Rheumatology 33(2): 94-101.
- Fries, J. F., P. Spitz, et al. (1980). "Measurement of patient outcome in arthritis." Arthritis & Rheumatism 23(2): 137-45.
- Galletti, S., M. Magnani, et al. (2004). "The echo-guided treatment of calcific tendinitis of the shoulder." Chirurgia Degli Organi di Movimento 89(4): 319-23.
- Gardiner, P. V., A. L. Bell, et al. (2005). "A potential pitfall in the use of the Disease Activity Score (DAS28) as the main response criterion in treatment guidelines for patients with rheumatoid arthritis." Ann Rheum Dis 64(3): 506-7.
- Genant, H. K., Y. Jiang, et al. (1998). "Assessment of rheumatoid arthritis using a modified scoring method on digitized and original radiographs.[see comment]." Arthritis & Rheumatism 41(9): 1583-90.
- Giovagnorio, F., C. Martinoli, et al. (2001). "Power Doppler sonography in knee arthritis--a pilot study." Rheumatology International 20(3): 101-4.
- Glattes, R. C., K. P. Spindler, et al. (2004). "A simple, accurate method to confirm placement of intra-articular knee injection." American Journal of Sports Medicine 32(4): 1029-31.
- Gormley, G., K. Steele, et al. (2001). "Can rheumatologists agree on a diagnosis of inflammatory arthritis in an early synovitis clinic?" Ann Rheum Dis 60(6): 638-9.
- Goupille, P., B. Roulot, et al. (2001). "Magnetic resonance imaging: a valuable method for the detection of synovial inflammation in rheumatoid arthritis." Journal of Rheumatology 28(1): 35-40.
- Grassi, W. (2003). "Clinical evaluation versus ultrasonography: who is the winner?[comment]." Journal of Rheumatology 30(5): 908-9.
- Grassi, W. and C. Cervini (1998). "Ultrasonography in rheumatology: an evolving technique." Annals of the Rheumatic Diseases 57(5): 268-71.
- Grassi, W., A. Farina, et al. (2001). "Sonographically guided procedures in rheumatology." Seminars in Arthritis & Rheumatism 30(5): 347-53.

- Grassi, W., A. Farina, et al. (2002). "Intralesional therapy in carpal tunnel syndrome: a sonographic-guided approach." Clinical & Experimental Rheumatology **20**(1): 73-6.
- Grassi, W., E. Filippucci, et al. (2000). "Sonographic imaging of tendons." Arthritis & Rheumatism **43**(5): 969-76.
- Grassi, W., E. Filippucci, et al. (2001). "Ultrasonography in the evaluation of bone erosions.[see comment]." Annals of the Rheumatic Diseases **60**(2): 98-103.
- Grassi, W., G. Lamanna, et al. (1999). "Synovitis of small joints: sonographic guided diagnostic and therapeutic approach." Annals of the Rheumatic Diseases **58**(10): 595-7.
- Grassi, W., E. Tittarelli, et al. (1995). "Finger tendon involvement in rheumatoid arthritis. Evaluation with high-frequency sonography." Arthritis & Rheumatism **38**(6): 786-94.
- Grassi, W., E. Tittarelli, et al. (1993). "Ultrasound examination of metacarpophalangeal joints in rheumatoid arthritis." Scandinavian Journal of Rheumatology **22**(5): 243-7.
- Gratz, S., D. Gobel, et al. (1999). "Correlation between radiation dose, synovial thickness, and efficacy of radiosynoviorthesis." Journal of Rheumatology **26**(6): 1242-9.
- Green, M., H. Marzo-Ortega, et al. (1999). "Persistence of mild, early inflammatory arthritis: the importance of disease duration, rheumatoid factor, and the shared epitope." Arthritis & Rheumatism **42**(10): 2184-8.
- Green, M., H. Marzo-Ortega, et al. (2001). "Predictors of outcome in patients with oligoarthritis: results of a protocol of intraarticular corticosteroids to all clinically active joints." Arthritis & Rheumatism **44**(5): 1177-83.
- Guillemin, F., T. Suurmeijer, et al. (1994). "Functional disability in early rheumatoid arthritis: description and risk factors." Journal of Rheumatology **21**(6): 1051-5.
- Gupta, S., S. Suri, et al. (1997). "Ilio-psoas abscesses: percutaneous drainage under image guidance." Clinical Radiology **52**(9): 704-7.
- Harrison, B. J., D. P. Symmons, et al. (1998). "The performance of the 1987 ARA classification criteria for rheumatoid arthritis in a population based cohort of patients with early inflammatory polyarthritis. American Rheumatism Association." Journal of Rheumatology **25**(12): 2324-30.
- Harrison, B. J., D. P. Symmons, et al. (1996). "Inflammatory polyarthritis in the community is not a benign disease: predicting functional disability one year after presentation." Journal of Rheumatology **23**(8): 1326-31.
- Hau, M., C. Kneitz, et al. (2002). "High resolution ultrasound detects a decrease in pannus vascularisation of small finger joints in patients with rheumatoid arthritis receiving treatment with soluble tumour necrosis factor alpha receptor (etanercept)." Annals of the Rheumatic Diseases **61**(1): 55-8.
- Hau, M., H. Schultz, et al. (1999). "Evaluation of pannus and vascularization of the metacarpophalangeal and proximal interphalangeal joints in rheumatoid arthritis by high-resolution ultrasound (multidimensional linear array)." Arthritis & Rheumatism **42**(11): 2303-8.
- Hauzeur, J. P., L. Mathy, et al. (1999). "Comparison between clinical evaluation and ultrasonography in detecting hydrarthrosis of the knee." Journal of Rheumatology **26**(12): 2681-3.

- Hermann, K. G., M. Backhaus, et al. (2003). "Rheumatoid arthritis of the shoulder joint: comparison of conventional radiography, ultrasound, and dynamic contrast-enhanced magnetic resonance imaging.[see comment]." Arthritis & Rheumatism 48(12): 3338-49.
- Hill, C. L., D. G. Gale, et al. (2001). "Knee effusions, popliteal cysts, and synovial thickening: association with knee pain in osteoarthritis." Journal of Rheumatology 28(6): 1330-7.
- Hochberg, M. C., R. D. Altman, et al. (1995). "Guidelines for the medical management of osteoarthritis. Part I. Osteoarthritis of the hip.American College of Rheumatology.[see comment]." Arthritis & Rheumatism 38(11): 1535-40.
- Hochberg, M. C., R. D. Altman, et al. (1995). "Guidelines for the medical management of osteoarthritis. Part II. Osteoarthritis of the knee.American College of Rheumatology.[see comment]." Arthritis & Rheumatism 38(11): 1541-6.
- Holm, S. (1979). "A simple sequentially rejective multiple test procedure." Scandinavian Journal of Statistics 6: 65-70.
- Hoving, J. L., R. Buchbinder, et al. (2004). "A comparison of magnetic resonance imaging, sonography, and radiography of the hand in patients with early rheumatoid arthritis.[see comment]." Journal of Rheumatology 31(4): 663-75.
- Howry, D. (1955). "Ultrasonic of visualisation of living organs and tissues." Geriatrics: 123-28.
- Huang, J., N. Stewart, et al. (2000). "A 1-year follow-up study of dynamic magnetic resonance imaging in early rheumatoid arthritis reveals synovitis to be increased in shared epitope-positive patients and predictive of erosions at 1 year." Rheumatology 39(4): 407-16.
- Hutton, C. W., C. Hinton, et al. (1987). "Intra-articular variation of synovial changes in knee arthritis: biopsy study comparing changes in patellofemoral synovium and the medial tibiofemoral synovium." British Journal of Rheumatology 26(1): 5-8.
- Iagnocco, A. and G. Coari (2000). "Usefulness of high resolution US in the evaluation of effusion in osteoarthritic first carpometacarpal joint." Scandinavian Journal of Rheumatology 29(3): 170-3.
- Iagnocco, A., E. Filippucci, et al. (2005). "High resolution ultrasonography in detection of bone erosions in patients with hand osteoarthritis." Journal of Rheumatology 32(12): 2381-3.
- Ihn, H., M. Shimozuma, et al. (1995). "Ultrasound measurement of skin thickness in systemic sclerosis." British Journal of Rheumatology 34(6): 535-8.
- Jacob, A. K. and P. I. Sallay (1997). "Therapeutic efficacy of corticosteroid injections in the acromioclavicular joint." Biomedical Sciences Instrumentation 34: 380-5.
- Jacobson, J. A., R. Andresen, et al. (1998). "Detection of ankle effusions: comparison study in cadavers using radiography, sonography, and MR imaging.[see comment]." AJR American Journal of Roentgenology 170(5): 1231-8.
- Jansen, L. M., D. van Schaardenburg, et al. (2002). "One year outcome of undifferentiated polyarthritis." Annals of the Rheumatic Diseases 61(8): 700-3.

- Jayson, M. I. and A. S. Dixon (1968). "Arthroscopy of the knee in rheumatic diseases." Annals of the Rheumatic Diseases 27(6): 503-11.
- Jiang, Y., H. K. Genant, et al. (2000). "A multicenter, double-blind, dose-ranging, randomized, placebo-controlled study of recombinant human interleukin-1 receptor antagonist in patients with rheumatoid arthritis: radiologic progression and correlation of Genant and Larsen scores." Arthritis & Rheumatism 43(5): 1001-9.
- Jones, A., N. Hopkinson, et al. (1992). "Evaluation of a method for clinically assessing osteoarthritis of the knee." Annals of the Rheumatic Diseases 51(2): 243-5.
- Jones, A., M. Regan, et al. (1993). "Importance of placement of intra-articular steroid injections." BMJ 307(6915): 1329-30.
- Kane, D., P. V. Balint, et al. (2003). "Ultrasonography is superior to clinical examination in the detection and localization of knee joint effusion in rheumatoid arthritis.[see comment]." Journal of Rheumatology 30(5): 966-71.
- Kane, D., G. Bruyn, et al. (2006). "A rheumatologist's perspective on musculoskeletal ultrasound in rheumatology: comment on the editorial by Roemer et al.[comment]." Arthritis & Rheumatism 55(2): 341-2; author reply 343-4.
- Kane, D., T. Greaney, et al. (1998). "Ultrasound guided injection of recalcitrant plantar fasciitis.[see comment]." Annals of the Rheumatic Diseases 57(6): 383-4.
- Kane, D., T. Greaney, et al. (1999). "Ultrasonography in the diagnosis and management of psoriatic dactylitis.[see comment]." Journal of Rheumatology 26(8): 1746-51.
- Kane, D., T. Greaney, et al. (2001). "The role of ultrasonography in the diagnosis and management of idiopathic plantar fasciitis." Rheumatology 40(9): 1002-8.
- Kane, D., L. Stafford, et al. (2003). "A prospective, clinical and radiological study of early psoriatic arthritis: an early synovitis clinic experience." Rheumatology 42(12): 1460-8.
- Karim, Z., A. K. Brown, et al. (2004). "Ultrasound-guided steroid injections in the treatment of hip osteoarthritis: comment on the letter by Margules.[comment]." Arthritis & Rheumatism 50(1): 338-9; author reply 339-40.
- Karim, Z., R. J. Wakefield, et al. (2001). "The impact of ultrasonography on diagnosis and management of patients with musculoskeletal conditions." Arthritis & Rheumatism 44(12): 2932-3.
- Karim, Z., R. J. Wakefield, et al. (2004). "Validation and reproducibility of ultrasonography in the detection of synovitis in the knee: a comparison with arthroscopy and clinical examination." Arthritis & Rheumatism 50(2): 387-94.
- Kay, J., C. B. Benson, et al. (1992). "Utility of high-resolution ultrasound for the diagnosis of dialysis-related amyloidosis." Arthritis & Rheumatism 35(8): 926-32.
- Kirwan, J. R. (2004). "The synovium in rheumatoid arthritis: evidence for (at least) two pathologies.[see comment][comment]." Arthritis & Rheumatism 50(1): 1-4.

- Klareskog, L., D. van der Heijde, et al. (2004). "Therapeutic effect of the combination of etanercept and methotrexate compared with each treatment alone in patients with rheumatoid arthritis: double-blind randomised controlled trial.[see comment]." Lancet **363**(9410): 675-81.
- Klarlund, M., M. Ostergaard, et al. (1999). "Finger joint synovitis in rheumatoid arthritis: quantitative assessment by magnetic resonance imaging." Rheumatology **38**(1): 66-72.
- Klauser, A., F. Frauscher, et al. (2002). "The value of contrast-enhanced color Doppler ultrasound in the detection of vascularization of finger joints in patients with rheumatoid arthritis." Arthritis & Rheumatism **46**(3): 647-53.
- Klinman, D. (2003). "Does activation of the innate immune system contribute to the development of rheumatoid arthritis?[comment]." Arthritis & Rheumatism **48**(3): 590-3.
- Klocke, R., D. Glew, et al. (2001). "Sonographic erosions of the rheumatoid little toe.[comment]." Annals of the Rheumatic Diseases **60**(9): 896-7.
- Klocke, R., T. Jenkinson, et al. (2003). "Sonographically guided caudal epidural steroid injections." Journal of Ultrasound in Medicine **22**(11): 1229-32.
- Korpela, M., L. Laasonen, et al. (2004). "Retardation of joint damage in patients with early rheumatoid arthritis by initial aggressive treatment with disease-modifying antirheumatic drugs: five-year experience from the FIN-RACo study.[see comment]." Arthritis & Rheumatism **50**(7): 2072-81.
- Koski, J. M. (1989). "Ultrasonographic evidence of hip synovitis in patients with rheumatoid arthritis." Scandinavian Journal of Rheumatology **18**(3): 127-31.
- Koski, J. M. (1990). "Ultrasonography of the elbow joint." Rheumatology International **10**(3): 91-4.
- Koski, J. M. (1990). "Ultrasonography of the metatarsophalangeal and talocrural joints." Clinical & Experimental Rheumatology **8**(4): 347-51.
- Koski, J. M. (1991). "Validity of axillary ultrasound scanning in detecting effusion of the glenohumeral joint." Scandinavian Journal of Rheumatology **20**(1): 49-51.
- Koski, J. M. (1992). "Ultrasonography in detection of effusion in the radiocarpal and midcarpal joints." Scandinavian Journal of Rheumatology **21**(2): 79-81.
- Koski, J. M. (1995). "Detection of plantar tenosynovitis of the forefoot by ultrasound in patients with early arthritis." Scandinavian Journal of Rheumatology **24**(5): 312-3.
- Koski, J. M. (2000). "Ultrasound guided injections in rheumatology." Journal of Rheumatology **27**(9): 2131-8.
- Koski, J. M., P. Anttila, et al. (1990). "Hip joint ultrasonography: correlation with intra-articular effusion and synovitis." British Journal of Rheumatology **29**(3): 189-92.
- Koski, J. M. and H. Hermunen (2001). "Intra-articular glucocorticoid treatment of the rheumatoid wrist. An ultrasonographic study." Scandinavian Journal of Rheumatology **30**(5): 268-70.
- Koski, J. M. and H. Isomaki (1990). "Ultrasonography may reveal synovitis in a clinically silent hip joint." Clinical Rheumatology **9**(4): 539-41.

- Koski, J. M., S. J. Saarakkala, et al. (2005). "Use of air-steroid-saline mixture as contrast medium in greyscale ultrasound imaging: experimental study and practical applications in rheumatology." Clinical & Experimental Rheumatology 23(3): 373-8.
- Landewe, R. B., M. Boers, et al. (2002). "COBRA combination therapy in patients with early rheumatoid arthritis: long-term structural benefits of a brief intervention.[see comment]." Arthritis & Rheumatism 46(2): 347-56.
- Lee, J., S. K. Lee, et al. (1997). "Magnetic resonance imaging of the wrist in defining remission of rheumatoid arthritis." Journal of Rheumatology 24(7): 1303-8.
- Lehtinen, A., P. Peltokallio, et al. (1994). "Sonography of Achilles tendon correlated to operative findings." Annales Chirurgiae et Gynaecologiae 83(4): 322-7.
- Lehtinen, A., M. Taavitsainen, et al. (1994). "Sonographic analysis of enthesopathy in the lower extremities of patients with spondylarthropathy." Clinical & Experimental Rheumatology 12(2): 143-8.
- Levin, D., L. N. Nazarian, et al. (2005). "Lateral epicondylitis of the elbow: US findings." Radiology 237(1): 230-4.
- Lindblad, S. and E. Hedfors (1985). "Intraarticular variation in synovitis. Local macroscopic and microscopic signs of inflammatory activity are significantly correlated." Arthritis & Rheumatism 28(9): 977-86.
- Lindblad, S. and E. Hedfors (1987). "Arthroscopic and immunohistologic characterization of knee joint synovitis in osteoarthritis." Arthritis & Rheumatism 30(10): 1081-8.
- Lopez-Ben, R., W. K. Bernreuter, et al. (2004). "Ultrasound detection of bone erosions in rheumatoid arthritis: a comparison to routine radiographs of the hands and feet." Skeletal Radiology 33(2): 80-4.
- Lund, P. J., A. Heikal, et al. (1995). "Ultrasonographic imaging of the hand and wrist in rheumatoid arthritis." Skeletal Radiology 24(8): 591-6.
- Luukkainen, R., M. T. Sanila, et al. (2005). "Relationship between clinically detected joint swelling and effusion diagnosed by ultrasonography in elbow joints in patients with rheumatoid arthritis." Clinical Rheumatology 24(3): 228-31.
- Luukkainen, R. K., M. Saltyshev, et al. (2003). "Relationship between clinically detected joint swelling and effusion diagnosed by ultrasonography in metatarsophalangeal and talocrural joints in patients with rheumatoid arthritis." Clinical & Experimental Rheumatology 21(5): 632-4.
- MacDonald, P. B., P. Clark, et al. (2000). "An analysis of the diagnostic accuracy of the Hawkins and Neer subacromial impingement signs." Journal of Shoulder & Elbow Surgery 9(4): 299-301.
- Magarelli, N., G. Guglielmi, et al. (2001). "Diagnostic utility of an echo-contrast agent in patients with synovitis using power Doppler ultrasound: a preliminary study with comparison to contrast-enhanced MRI." European Radiology 11(6): 1039-46.
- Makula, E., G. Pokorny, et al. (1996). "Parotid gland ultrasonography as a diagnostic tool in primary Sjogren's syndrome." British Journal of Rheumatology 35(10): 972-7.
- Manger, B. and J. R. Kalden (1995). "Joint and connective tissue ultrasonography--a rheumatologic bedside procedure? A German experience." Arthritis & Rheumatism 38(6): 736-42.

- Margules, K. R. (2001). "Fluoroscopically directed steroid instillation in the treatment of hip osteoarthritis: safety and efficacy in 510 cases.[see comment][comment]." Arthritis & Rheumatism 44(10): 2449-50; author reply 2455-6.
- Mariacher-Gehler, S. and B. A. Michel (1994). "Sonography: a simple way to visualize rib fractures." AJR American Journal of Roentgenology 163(5): 1268.
- Martino, F., G. Angelelli, et al. (1992). "[The normal aspect of the suprapatellar bursa in echography of the knee]." Radiologia Medica 83(1-2): 43-8.
- Martino, F., M. D'Amore, et al. (1991). "Echographic study of Tietze's syndrome." Clinical Rheumatology 10(1): 2-4.
- Mathews, P. V. and R. E. Glousman (2005). "Accuracy of subacromial injection: anterolateral versus posterior approach." Journal of Shoulder & Elbow Surgery 14(2): 145-8.
- Mc Gonagle, D., W. Gibbon, et al. (1999). "A preliminary study of ultrasound aspiration of bone erosion in early rheumatoid arthritis." Rheumatology 38(4): 329-31.
- McAuliffe, W. and G. Clarke (1994). "The diagnosis and treatment of psoas abscess: a 12 year review.[see comment]." Australian & New Zealand Journal of Surgery 64(6): 413-7.
- McCune, W. J., D. K. Dedrick, et al. (1990). "Sonographic evaluation of osteoarthritic femoral condylar cartilage. Correlation with operative findings." Clinical Orthopaedics & Related Research(254): 230-5.
- McGonagle, D., P. G. Conaghan, et al. (1999). "The relationship between synovitis and bone changes in early untreated rheumatoid arthritis: a controlled magnetic resonance imaging study.[see comment]." Arthritis & Rheumatism 42(8): 1706-11.
- McQueen, F. M., N. Benton, et al. (2003). "Bone edema scored on magnetic resonance imaging scans of the dominant carpus at presentation predicts radiographic joint damage of the hands and feet six years later in patients with rheumatoid arthritis." Arthritis & Rheumatism 48(7): 1814-27.
- McQueen, F. M., N. Stewart, et al. (1999). "Magnetic resonance imaging of the wrist in early rheumatoid arthritis reveals progression of erosions despite clinical improvement." Annals of the Rheumatic Diseases 58(3): 156-63.
- Mikkelsen, W. M. and H. Dodge (1969). "A four year follow-up of suspected rheumatoid arthritis: the Tecumseh, Michigan, Community Health Study." Arthritis & Rheumatism 12(2): 87-91.
- Miller, S. D., M. Van Holsbeeck, et al. (1996). "Ultrasound in the diagnosis of posterior tibial tendon pathology." Foot & Ankle International 17(9): 555-8.
- Molenaar, E. T., A. E. Voskuyl, et al. (2004). "Progression of radiologic damage in patients with rheumatoid arthritis in clinical remission.[see comment]." Arthritis & Rheumatism 50(1): 36-42.
- Mottonen, T., P. Hannonen, et al. (2002). "Delay to institution of therapy and induction of remission using single-drug or combination-disease-modifying antirheumatic drug therapy in early rheumatoid arthritis.[see comment]." Arthritis & Rheumatism 46(4): 894-8.

- Mulherin, D., O. Fitzgerald, et al. (1996). "Clinical improvement and radiological deterioration in rheumatoid arthritis: evidence that the pathogenesis of synovial inflammation and articular erosion may differ.[see comment]." British Journal of Rheumatology **35**(12): 1263-8.
- Nakamichi, K. and S. Tachibana (1997). "Ultrasonographically assisted carpal tunnel release." Journal of Hand Surgery - American Volume **22**(5): 853-62.
- Naredo, E., G. Bonilla, et al. (2005). "Assessment of inflammatory activity in rheumatoid arthritis: a comparative study of clinical evaluation with grey scale and power Doppler ultrasonography." Annals of the Rheumatic Diseases **64**(3): 375-81.
- Naredo, E., F. Cabero, et al. (2004). "A randomized comparative study of short term response to blind injection versus sonographic-guided injection of local corticosteroids in patients with painful shoulder." Journal of Rheumatology **31**(2): 308-14.
- Naredo, E., F. Cabero, et al. (2005). "Ultrasonographic findings in knee osteoarthritis: a comparative study with clinical and radiographic assessment." Osteoarthritis & Cartilage **13**(7): 568-74.
- Naredo, E., F. Gamero, et al. (2005). "Ultrasonographic assessment of inflammatory activity in rheumatoid arthritis: comparison of extended versus reduced joint evaluation." Clinical & Experimental Rheumatology **23**(6): 881-4.
- Naredo, E., I. Moller, et al. (2006). "Interobserver reliability in musculoskeletal ultrasonography: results from a "Teach the Teachers" rheumatologist course." Annals of the Rheumatic Diseases **65**(1): 14-9.
- Nazarian, L. N., N. M. Rawool, et al. (1995). "Synovial fluid in the hindfoot and ankle: detection of amount and distribution with US." Radiology **197**(1): 275-8.
- Neer, C. S., 2nd (1983). "Impingement lesions." Clinical Orthopaedics & Related Research(173): 70-7.
- Newman, J. S., T. J. Laing, et al. (1996). "Power Doppler sonography of synovitis: assessment of therapeutic response--preliminary observations.[see comment]." Radiology **198**(2): 582-4.
- O'Connor, P. J., J. Rankine, et al. (2005). "Interobserver variation in sonography of the painful shoulder." Journal of Clinical Ultrasound **33**(2): 53-6.
- O'Dell, J. R. (2002). "Treating rheumatoid arthritis early: a window of opportunity?[comment]." Arthritis & Rheumatism **46**(2): 283-5.
- O'Dell, J. R., R. Leff, et al. (2002). "Treatment of rheumatoid arthritis with methotrexate and hydroxychloroquine, methotrexate and sulfasalazine, or a combination of the three medications: results of a two-year, randomized, double-blind, placebo-controlled trial." Arthritis & Rheumatism **46**(5): 1164-70.
- O'Sullivan, J. B. and E. S. Cathcart (1972). "The prevalence of rheumatoid arthritis. Follow-up evaluation of the effect of criteria on rates in Sudbury, Massachusetts." Annals of Internal Medicine **76**(4): 573-7.
- Ostergaard, M., M. Court-Payen, et al. (1995). "Ultrasonography in arthritis of the knee. A comparison with MR imaging." Acta Radiologica **36**(1): 19-26.

- Ostergaard, M., M. Hansen, et al. (1999). "Magnetic resonance imaging-determined synovial membrane volume as a marker of disease activity and a predictor of progressive joint destruction in the wrists of patients with rheumatoid arthritis.[see comment]." Arthritis & Rheumatism **42**(5): 918-29.
- Ostergaard, M., M. Hansen, et al. (2003). "New radiographic bone erosions in the wrists of patients with rheumatoid arthritis are detectable with magnetic resonance imaging a median of two years earlier." Arthritis & Rheumatism **48**(8): 2128-31.
- Ostergaard, M., M. Klarlund, et al. (2001). "Interreader agreement in the assessment of magnetic resonance images of rheumatoid arthritis wrist and finger joints--an international multicenter study." Journal of Rheumatology **28**(5): 1143-50.
- Ostergaard, M., M. Stoltenberg, et al. (1997). "Magnetic resonance imaging-determined synovial membrane and joint effusion volumes in rheumatoid arthritis and osteoarthritis: comparison with the macroscopic and microscopic appearance of the synovium.[see comment]." Arthritis & Rheumatism **40**(10): 1856-67.
- Ostergaard, M. and C. Wiell (2004). "Ultrasonography in rheumatoid arthritis: a very promising method still needing more validation." Current Opinion in Rheumatology **16**(3): 223-30.
- Ozdemir, H., H. Atilla, et al. (1995). "Diagnosis of ocular involvement in Behcet's disease: value of spectral and color Doppler sonography.[see comment]." AJR American Journal of Roentgenology **164**(5): 1223-7.
- Parker, F. and C. S. Keefer (1935). "Gross and histological changes in knee joint in rheumatoid arthritis." Arch Pathol **20**: 507-522.
- Partington, P. F. and G. H. Broome (1998). "Diagnostic injection around the shoulder: hit and miss? A cadaveric study of injection accuracy." Journal of Shoulder & Elbow Surgery **7**(2): 147-50.
- Paulus, H. E. (2004). "Defining remission in rheumatoid arthritis: what is it? Does it matter?[comment]." Journal of Rheumatology **31**(1): 1-4.
- Pelletier, J. P., J. Martel-Pelletier, et al. (2001). "Osteoarthritis, an inflammatory disease: potential implication for the selection of new therapeutic targets.[see comment]." Arthritis & Rheumatism **44**(6): 1237-47.
- Petri, M., R. Dobrow, et al. (1987). "Randomized, double-blind, placebo-controlled study of the treatment of the painful shoulder." Arthritis & Rheumatism **30**(9): 1040-5.
- Pinals, R. S., J. Baum, et al. (1982). "Preliminary criteria for clinical remission in rheumatoid arthritis." Bulletin on the Rheumatic Diseases **32**(1): 7-10.
- Plant, M. J., A. L. Williams, et al. (2000). "Relationship between time-integrated C-reactive protein levels and radiologic progression in patients with rheumatoid arthritis." Arthritis & Rheumatism **43**(7): 1473-7.
- Pourbagher, M. A., M. Ozalay, et al. (2005). "Accuracy and outcome of sonographically guided intra-articular sodium hyaluronate injections in patients with osteoarthritis of the hip." Journal of Ultrasound in Medicine **24**(10): 1391-5.
- Prevoo, M. L., M. A. van 't Hof, et al. (1995). "Modified disease activity scores that include twenty-eight-joint counts. Development and validation in a prospective longitudinal study of patients with rheumatoid arthritis.[see comment]." Arthritis & Rheumatism **38**(1): 44-8.

- Prevo, M. L., A. M. van Gestel, et al. (1996). "Remission in a prospective study of patients with rheumatoid arthritis. American Rheumatism Association preliminary remission criteria in relation to the disease activity score.[see comment]." British Journal of Rheumatology **35**(11): 1101-5.
- Quinn, M. A., M. J. Green, et al. (2003). "Prognostic factors in a large cohort of patients with early undifferentiated inflammatory arthritis after application of a structured management protocol." Arthritis & Rheumatism **48**(11): 3039-45.
- Qvistgaard, E., H. Kristoffersen, et al. (2001). "Guidance by ultrasound of intra-articular injections in the knee and hip joints.[see comment]." Osteoarthritis & Cartilage **9**(6): 512-7.
- Qvistgaard, E., H. Rogind, et al. (2001). "Quantitative ultrasonography in rheumatoid arthritis: evaluation of inflammation by Doppler technique." Annals of the Rheumatic Diseases **60**(7): 690-3.
- Rankine, J. J., K. P. Gill, et al. (1998). "The therapeutic impact of lumbar spine MRI on patients with low back and leg pain." Clinical Radiology **53**(9): 688-93.
- Raza, K., C. Y. Lee, et al. (2003). "Ultrasound guidance allows accurate needle placement and aspiration from small joints in patients with early inflammatory arthritis." Rheumatology **42**(8): 976-9.
- Read, J. W. and M. Perko (1998). "Shoulder ultrasound: diagnostic accuracy for impingement syndrome, rotator cuff tear, and biceps tendon pathology." Journal of Shoulder & Elbow Surgery **7**(3): 264-71.
- Redelmeier, D. A. and K. Lorig (1993). "Assessing the clinical importance of symptomatic improvements. An illustration in rheumatology." Archives of Internal Medicine **153**(11): 1337-42.
- Ribbens, C., B. Andre, et al. (2003). "Rheumatoid hand joint synovitis: gray-scale and power Doppler US quantifications following anti-tumor necrosis factor-alpha treatment: pilot study." Radiology **229**(2): 562-9.
- Robertson, C. R., J. R. Rice, et al. (1993). "Treatment of erosive osteoarthritis with hydroxychloroquine." Arthritis Rheum **36**: S167.
- Rubaltelli, L., U. Fiocco, et al. (1994). "Prospective sonographic and arthroscopic evaluation of proliferative knee joint synovitis." Journal of Ultrasound in Medicine **13**(11): 855-62.
- Salaffi, F., M. Carotti, et al. (2004). "Contrast-enhanced power Doppler sonography of knee synovitis in rheumatoid arthritis: assessment of therapeutic response." Clinical Rheumatology **23**(4): 285-90.
- Scheel, A. K., K. G. Hermann, et al. (2005). "A novel ultrasonographic synovitis scoring system suitable for analyzing finger joint inflammation in rheumatoid arthritis.[see comment]." Arthritis & Rheumatism **52**(3): 733-43.
- Scheel, A. K., K. G. Hermann, et al. (2006). "Prospective 7 year follow up imaging study comparing radiography, ultrasonography, and magnetic resonance imaging in rheumatoid arthritis finger joints." Annals of the Rheumatic Diseases **65**(5): 595-600.
- Schmidt, W. A., H. E. Kraft, et al. (1995). "Colour Doppler sonography to diagnose temporal arteritis.[see comment]." Lancet **345**(8953): 866.

- Schmidt, W. A., L. Volker, et al. (2000). "Colour Doppler ultrasonography to detect pannus in knee joint synovitis." Clinical & Experimental Rheumatology 18(4): 439-44.
- Schumacher, H. R. (2002). "Early arthritis clinics. Much early arthritis is unclassified.[see comment][comment]." Journal of Rheumatology 29(11): 2258-60.
- Senall, J. A., J. M. Failla, et al. (2004). "Ultrasound for the early diagnosis of clinically suspected scaphoid fracture." Journal of Hand Surgery - American Volume 29(3): 400-5.
- Sethi, P. M. and N. El Attrache (2006). "Accuracy of intra-articular injection of the glenohumeral joint: a cadaveric study." Orthopedics 29(2): 149-52.
- Spiegel, T. M., W. King, 3rd, et al. (1987). "Measuring disease activity: comparison of joint tenderness, swelling, and ultrasonography in rheumatoid arthritis." Arthritis & Rheumatism 30(11): 1283-8.
- Spiegel, T. M., J. S. Spiegel, et al. (1987). "The joint alignment and motion scale: a simple measure of joint deformity in patients with rheumatoid arthritis." Journal of Rheumatology 14(5): 887-92.
- Stenger, A. A., M. A. Van Leeuwen, et al. (1998). "Early effective suppression of inflammation in rheumatoid arthritis reduces radiographic progression." British Journal of Rheumatology 37(11): 1157-63.
- Stone, M., D. Bergin, et al. (2001). "Power Doppler ultrasound assessment of rheumatoid hand synovitis." Journal of Rheumatology 28(9): 1979-82.
- Strizak, A. M., L. Danzig, et al. (1982). "Subacromial bursography. An anatomical and clinical study." Journal of Bone & Joint Surgery - American Volume 64(2): 196-201.
- Swen, W. A., J. W. Jacobs, et al. (1999). "Sonography and magnetic resonance imaging equivalent for the assessment of full-thickness rotator cuff tears." Arthritis & Rheumatism 42(10): 2231-8.
- Swen, W. A., J. W. Jacobs, et al. (2001). "Carpal tunnel sonography by the rheumatologist versus nerve conduction study by the neurologist.[see comment]." Journal of Rheumatology 28(1): 62-9.
- Swen, W. A., J. W. Jacobs, et al. (2000). "Comparison of sonography and magnetic resonance imaging for the diagnosis of partial tears of finger extensor tendons in rheumatoid arthritis." Rheumatology 39(1): 55-62.
- Swen, W. A., J. W. Jacobs, et al. (1998). "Is sonography performed by the rheumatologist as useful as arthrography executed by the radiologist for the assessment of full thickness rotator cuff tears?" Journal of Rheumatology 25(9): 1800-6.
- Szkudlarek, M., M. Court-Payen, et al. (2003). "Interobserver agreement in ultrasonography of the finger and toe joints in rheumatoid arthritis.[see comment]." Arthritis & Rheumatism 48(4): 955-62.
- Szkudlarek, M., M. Court-Payen, et al. (2001). "Power Doppler ultrasonography for assessment of synovitis in the metacarpophalangeal joints of patients with rheumatoid arthritis: a comparison with dynamic magnetic resonance imaging." Arthritis & Rheumatism 44(9): 2018-23.
- Szkudlarek, M., M. Court-Payen, et al. (2003). "Contrast-enhanced power Doppler ultrasonography of the metacarpophalangeal joints in rheumatoid arthritis.[see comment]." European Radiology 13(1): 163-8.

- Szkudlarek, M., E. Narvestad, et al. (2004). "Ultrasonography of the metatarsophalangeal joints in rheumatoid arthritis: comparison with magnetic resonance imaging, conventional radiography, and clinical examination." Arthritis & Rheumatism 50(7): 2103-12.
- Taggart, A., E. Filippucci, et al. (2006). "Musculoskeletal ultrasound training in rheumatology: the Belfast experience.[see comment]." Rheumatology 45(1): 102-5.
- Tan, A. L., R. J. Wakefield, et al. (2003). "Imaging of the musculoskeletal system: magnetic resonance imaging, ultrasonography and computed tomography." Best Practice & Research in Clinical Rheumatology 17(3): 513-28.
- Taylor, P. C., A. Steuer, et al. (2004). "Comparison of ultrasonographic assessment of synovitis and joint vascularity with radiographic evaluation in a randomized, placebo-controlled study of infliximab therapy in early rheumatoid arthritis." Arthritis & Rheumatism 50(4): 1107-16.
- Teh, J., K. Stevens, et al. (2003). "Power Doppler ultrasound of rheumatoid synovitis: quantification of therapeutic response." British Journal of Radiology 76(912): 875-9.
- Terslev, L., S. Torp-Pedersen, et al. (2003). "Effects of treatment with etanercept (Enbrel, TNRF:Fc) on rheumatoid arthritis evaluated by Doppler ultrasonography." Annals of the Rheumatic Diseases 62(2): 178-81.
- Terslev, L., S. Torp-Pedersen, et al. (2003). "Doppler ultrasound and magnetic resonance imaging of synovial inflammation of the hand in rheumatoid arthritis: a comparative study." Arthritis & Rheumatism 48(9): 2434-41.
- Testa, V., G. Capasso, et al. (2002). "Management of Achilles tendinopathy by ultrasound-guided percutaneous tenotomy." Medicine & Science in Sports & Exercise 34(4): 573-80.
- Tsai, W. C., C. C. Hsu, et al. (2006). "Plantar fasciitis treated with local steroid injection: comparison between sonographic and palpation guidance." Journal of Clinical Ultrasound 34(1): 12-6.
- Tsakonas, E., A. A. Fitzgerald, et al. (2000). "Consequences of delayed therapy with second-line agents in rheumatoid arthritis: a 3 year followup on the hydroxychloroquine in early rheumatoid arthritis (HERA) study." Journal of Rheumatology 27(3): 623-9.
- Valenstein, P. N. (1990). "Evaluating diagnostic tests with imperfect standards." American Journal of Clinical Pathology 93(2): 252-8.
- van der Heijde, D. M., M. A. van 't Hof, et al. (1990). "Judging disease activity in clinical practice in rheumatoid arthritis: first step in the development of a disease activity score." Annals of the Rheumatic Diseases 49(11): 916-20.
- van der Horst-Bruinsma, I. E., I. Speyer, et al. (1998). "Diagnosis and course of early-onset arthritis: results of a special early arthritis clinic compared to routine patient care." British Journal of Rheumatology 37(10): 1084-8.
- van Holsbeeck, M., K. van Holsbeeck, et al. (1988). "Staging and follow-up of rheumatoid arthritis of the knee. Comparison of sonography, thermography, and clinical assessment." Journal of Ultrasound in Medicine 7(10): 561-6.

- van Leeuwen, M. A., M. H. van Rijswijk, et al. (1997). "Individual relationship between progression of radiological damage and the acute phase response in early rheumatoid arthritis. Towards development of a decision support system." Journal of Rheumatology **24**(1): 20-7.
- van Moppes, F. I., O. Veldkamp, et al. (1995). "Role of shoulder ultrasonography in the evaluation of the painful shoulder." European Journal of Radiology **19**(2): 142-6.
- Veale, D. J., R. J. Reece, et al. (1999). "Intra-articular primatised anti-CD4: efficacy in resistant rheumatoid knees. A study of combined arthroscopy, magnetic resonance imaging, and histology." Annals of the Rheumatic Diseases **58**(6): 342-9.
- Vecchio, P. C., B. L. Hazleman, et al. (1993). "A double-blind trial comparing subacromial methylprednisolone and lignocaine in acute rotator cuff tendinitis." British Journal of Rheumatology **32**(8): 743-5.
- Villoutreix, C., T. Pham, et al. (2006). "Intraarticular glucocorticoid injections in rapidly destructive hip osteoarthritis." Joint, Bone, Spine: Revue du Rhumatisme **73**(1): 66-71.
- Wakefield, R. J., P. V. Balint, et al. (2005). "Musculoskeletal ultrasound including definitions for ultrasonographic pathology." Journal of Rheumatology **32**(12): 2485-7.
- Wakefield, R. J., A. K. Brown, et al. (2004). "Musculoskeletal ultrasonography: what is it and should training be compulsory for rheumatologists?[comment]." Rheumatology **43**(7): 821-2.
- Wakefield, R. J., W. W. Gibbon, et al. (2000). "The value of sonography in the detection of bone erosions in patients with rheumatoid arthritis: a comparison with conventional radiography.[see comment]." Arthritis & Rheumatism **43**(12): 2762-70.
- Wakefield, R. J., W. W. Gibbon, et al. (1999). "The current status of ultrasonography in rheumatology." Rheumatology **38**(3): 195-8.
- Wakefield, R. J., E. Goh, et al. (2003). "Musculoskeletal ultrasonography in Europe: results of a rheumatologist-based survey at a EULAR meeting." Rheumatology **42**(10): 1251-3.
- Wakefield, R. J., M. J. Green, et al. (2004). "Should oligoarthritis be reclassified? Ultrasound reveals a high prevalence of subclinical disease.[see comment]." Annals of the Rheumatic Diseases **63**(4): 382-5.
- Walther, M., H. Harms, et al. (2001). "Correlation of power Doppler sonography with vascularity of the synovial tissue of the knee joint in patients with osteoarthritis and rheumatoid arthritis." Arthritis & Rheumatism **44**(2): 331-8.
- Walther, M., H. Harms, et al. (2002). "Synovial tissue of the hip at power Doppler US: correlation between vascularity and power Doppler US signal." Radiology **225**(1): 225-31.
- Walther, M., S. Radke, et al. (2004). "Power Doppler findings in plantar fasciitis." Ultrasound in Medicine & Biology **30**(4): 435-40.
- Ward, E. E., J. A. Jacobson, et al. (2001). "Sonographic detection of Baker's cysts: comparison with MR imaging." AJR American Journal of Roentgenology **176**(2): 373-80.

- Weidekamm, C., M. Koller, et al. (2003). "Diagnostic value of high-resolution B-mode and doppler sonography for imaging of hand and finger joints in rheumatoid arthritis.[see comment]." Arthritis & Rheumatism **48**(2): 325-33.
- Wells, G. A., P. Tugwell, et al. (1993). "Minimum important difference between patients with rheumatoid arthritis: the patient's perspective." Journal of Rheumatology **20**(3): 557-60.
- Whalley, D., S. P. McKenna, et al. (1997). "Quality of life in rheumatoid arthritis." British Journal of Rheumatology **36**(8): 884-8.
- Whittingham, T. A. (1997). "New and future developments in ultrasonic imaging." British Journal of Radiology **70 Spec No**: S119-32.
- Williams, H. J., M. J. Egger, et al. (1994). "Comparison of hydroxychloroquine and placebo in the treatment of the arthropathy of mild systemic lupus erythematosus." Journal of Rheumatology **21**(8): 1457-62.
- Winters, J. C., J. S. Sobel, et al. (1997). "Comparison of physiotherapy, manipulation, and corticosteroid injection for treating shoulder complaints in general practice: randomised, single blind study.[see comment]." BMJ **314**(7090): 1320-5.
- Wolfe, F. and M. A. Cathey (1991). "The assessment and prediction of functional disability in rheumatoid arthritis.[erratum appears in J Rheumatol 1991 Nov;18(11):1774]." Journal of Rheumatology **18**(9): 1298-306.
- Wolfe, F., K. Ross, et al. (1993). "The prognosis of rheumatoid arthritis and undifferentiated polyarthritis syndrome in the clinic: a study of 1141 patients.[see comment]." Journal of Rheumatology **20**(12): 2005-9.
- Worth, W. D., E. Hermann, et al. (1986). "[Value of arthrosonography in the evaluation of exudative and proliferative synovitis]." Zeitschrift fur Rheumatologie **45**(5): 263-6.
- Yamakado, K. (2002). "The targeting accuracy of subacromial injection to the shoulder: an arthrographic evaluation." Arthroscopy **18**(8): 887-91.
- Yates, D. B. and J. T. Scott (1975). "Rheumatoid synovitis and joint disease. Relationship between arthroscopic and histological changes." Annals of the Rheumatic Diseases **34**(1): 1-6.
- Zingas, C., J. M. Failla, et al. (1998). "Injection accuracy and clinical relief of de Quervain's tendinitis." Journal of Hand Surgery - American Volume **23**(1): 89-96.